

**GILDA CARDENOSA, MD, MS**Section of Breast Imaging, Division of Radiology,  
Cleveland Clinic**WILLIAM A. CHILCOTE, MD**Section of Breast Imaging, Division of Radiology,  
Cleveland Clinic**MARY A. BARRY, RN**Section of Breast Imaging, Division of Radiology,  
Cleveland Clinic**CHRISTINE A. QUINN, MD**Section of Breast Imaging, Division of Radiology,  
Cleveland Clinic**MARY G. FOGLIETTI, RN**Section of Breast Imaging, Division of Radiology,  
Cleveland Clinic

# How new technology is changing mammography and breast cancer management

## ■ ABSTRACT

Breast-imaging technology has improved in ways that allow one not only to detect breast cancer earlier, but also to distinguish benign from malignant lesions better. These capabilities are influencing the approach to breast cancer. We review current trends and issues for the non-radiologist.

## ■ KEY POINTS

The aim of a screening mammogram is to distinguish normal from "potentially abnormal." Separate diagnostic studies are done to characterize potentially abnormal findings.

The radiologist reviewing a diagnostic mammogram must categorize the study as: 1) normal, 2) benign, 3) probably benign, 4) suspicious, or 5) highly suggestive of malignancy.

Ultrasonography of the breast helps to corroborate the findings from the clinical examination and mammogram, especially in women with dense breasts, in whom mammography may be less helpful.

**T**HANKS TO IMPROVEMENTS in breast-imaging techniques—ie, mammography and ultrasonography—physicians are changing the way they approach the diagnosis of breast cancer. More patients are being diagnosed early, before any lump can be palpated, and radiologists can often distinguish benign from malignant findings. Thus, the old approach of "feel it, biopsy it, remove it" is giving way to a more tailored response in which watchful waiting is an option for some patients.

## ■ NEW EQUIPMENT IS BETTER

To produce images, early mammography machines (ie, those used in the 1970s and early 1980s) relied on a process called xerography—the same photoelectric process used in copy machines. Newer machines use photographic film with an intensifying screen: "film-screen" mammography.

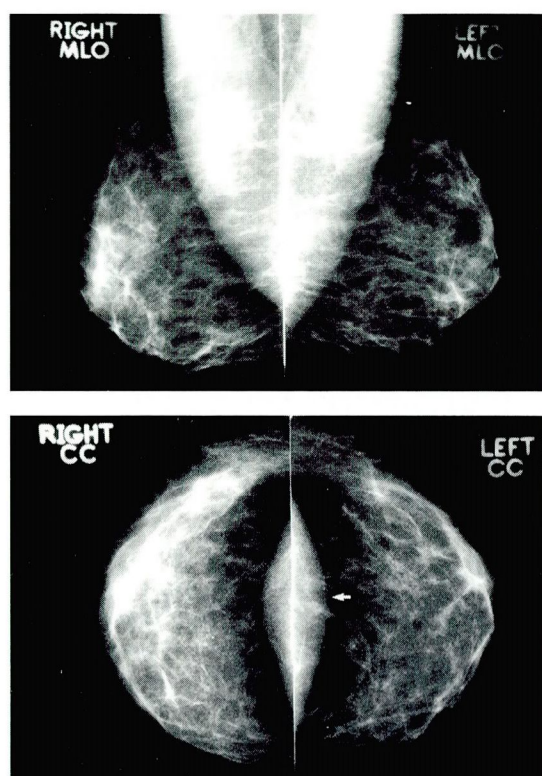
Film-screen mammography has several advantages over xeromammography. Image quality is clearer: contrast is enhanced and glandular tissue shows up more clearly. Radiation doses are lower. The greatest gain, however, is the ability to obtain additional, workup images (eg, spot compression and spot magnification views) to evaluate potentially abnormal areas detected on screening mammograms (see "Diagnostic mammography" below).

## ■ SCREENING MAMMOGRAPHY

By definition, screening mammograms are done in asymptomatic women. Women can be considered asymptomatic even if they have a

**PATIENT INFORMATION**  
**Mammography**, page 203





**FIGURE 1.** Normal screening mammogram. By convention the right and left metallic markers are placed closest to the axilla. **Top**, right and left mediolateral oblique (MLO) views back-to-back. This is how the images are reviewed. On well-positioned MLO views, the pectoral muscle is seen to the level of the nipple and its anterior margin is convex, as in this patient. **Bottom**, right and left craniocaudal views back-to-back. Pectoral muscle is seen on craniocaudal views in 30% to 40% of patients (arrow).

**We recommend  
annual  
mammograms  
from age 40**

family history of breast cancer or of mastectomy for breast cancer, or have had prior biopsy findings of benign proliferative changes or lobular neoplasia (lobular carcinoma in situ).

#### Should women in their 40s be screened?

The value of mammography as a screening test has been a contentious issue, and particularly the value of screening in 40-to-49-year-old women.<sup>1</sup> We believe that mammography, performed at regular intervals, reduces breast cancer mortality rates in women age 40 to 49 and in women age 50 and older.<sup>2</sup>

In seven of eight randomized controlled trials, women who were offered mammograph-

ic screening had a significantly lower rate of breast cancer mortality than did women who were not. All of the trials included women in their 40s. Four of these trials—the ones with the longest follow-up data—have now also reported statistically significant decreases in breast cancer mortality specifically among women 40 to 49 years of age when enrolled: 25% reductions in the Health Insurance Plan trial and the Two-County Swedish trial, 44% in the Gothenberg trial,<sup>3</sup> and 36% in the Malmö trial.<sup>4</sup>

#### How often to screen?

If the interval is too long (or if the threshold for intervention is set too high), small, non-palpable lesions have time to grow and potentially metastasize, and the benefit of screening may be lost.<sup>5</sup> In premenopausal women, the sojourn time (the time for cancers to progress from a lesion detectable only by mammography to a palpable lesion) is about 1.8 years.<sup>6,7</sup> In postmenopausal women, sojourn times vary according to histologic type and patient age; the reported average, however, is 3.5 years.<sup>7</sup> Annual mammograms are therefore particularly indicated in premenopausal women.<sup>8</sup> The American Cancer Society,<sup>8</sup> and the Cleveland Clinic Breast Center recommend annual screening starting at age 40.

In the general population, widespread use of mammographic screening is having an effect on the types of patients physicians are now seeing. More women are being diagnosed with mammographically detected, clinically occult, node-negative disease.<sup>9–11</sup> Ductal carcinoma in situ, considered an unusual disease as recently as 1986,<sup>12</sup> now constitutes 15% to 45% of all mammographically detected breast cancers.<sup>13,14</sup>

#### Technique for screening mammography

During the procedure, the breast tissue must be compressed. Compression serves several purposes. It thins the breast tissue so that less radiation can be used. It also reduces scatter radiation, a deterrent to high-contrast images. It optimizes exposure of dense glandular areas. Immobilizing the breast reduces the likelihood of blurring and helps separate overlapping tissue, which can make the difference between finding or missing an early cancer.<sup>15,16</sup>

We generally obtain two views (**FIGURE 1**):



## Algorithm for breast cancer screening

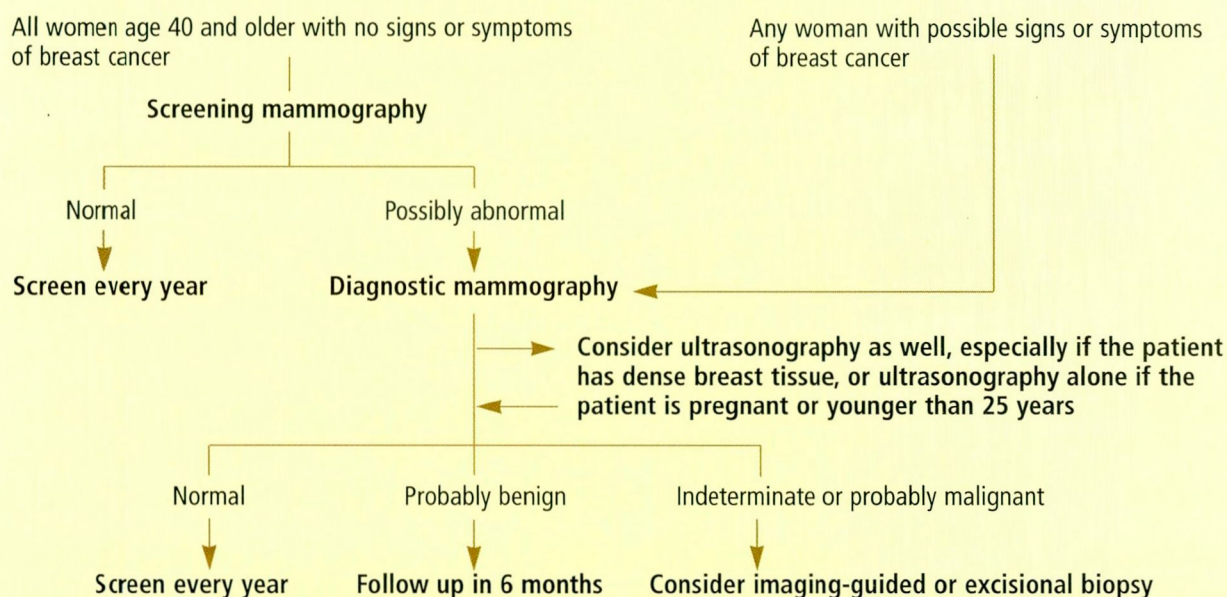


FIGURE 2

- **Craniocaudal (CC)**, ie, with the x-ray source placed cranially to the breast and the film placed caudally.
- **Mediolateral oblique (MLO)**, ie, with the x-ray source placed above the upper inner quadrant of the breast and the film positioned on the lower, outer aspect of the breast.

In addition, approximately 10% of women need a third image to evaluate lateral tissue: the **exaggerated craniocaudal (XCC)** view.

### Interpreting screening mammograms

In reviewing a screening mammogram, the radiologist must answer one question: Is the study normal or potentially abnormal? It is a mistake to try to characterize a lesion on the basis of a screening mammogram. Time and again, what seems like a true lesion does not persist, or a benign-appearing area turns out to be a malignancy. Screening mammography is simply about detecting a lesion, not characterizing it as benign or malignant (FIGURE 2).

Another mistake, in our opinion, is to try to review each screening mammogram while the patient is still there. True, the patient receives the results immediately, and any additional studies needed can be done then and there. However, we believe it is better to review

mammograms in batches, for two reasons.

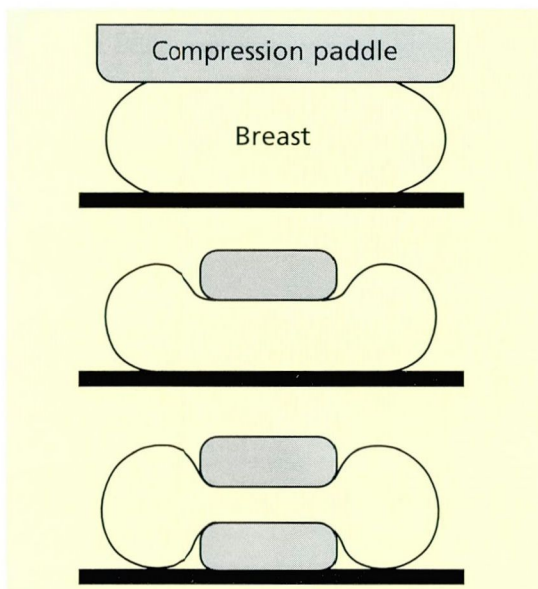
First is efficiency. As patient volumes increase or outpatient sites are added, it is not realistic to expect immediate interpretation of screening mammograms and evaluation of patients with potential abnormalities. Given the low rates of reimbursement for screening mammograms, it is necessary to have an efficient, cost-effective, and streamlined method of moving patients through mammographic rooms in high volumes.

This should not and does not imply substandard quality imaging or impersonal service. Our technologists are trained to review all images for positioning, contrast, optimal exposure, and resolution (no blurring) before the patient leaves the department.

The second reason is quality. Error rates can be minimized if films are systematically presented with comparison studies. Right and left CC views and right and left MLO views are placed back-to-back for comparison. Attention is focused on the films, not paperwork or dictation. Interruptions need to be kept to a minimum. The only light in a mammographic interpretation room must be coming from high-intensity viewboxes through the mammographic images.

**A screening mammogram can detect lesions, but not tell benign from malignant**





**FIGURE 3.** Diagrams illustrating differences in compression paddles. **Top**, large compression paddle used for compression of the entire breast (ie, for mediolateral and craniocaudal views). **Middle**, spot compression paddle used for focal compression. Compression is applied to the area of concern. More compression can be applied, bringing the area of concern closer to the film, which improves resolution. **Bottom**, double spot compression. Applying focal compression from below and from above improves resolution even further by increasing the amount of compression applied to the area of interest.

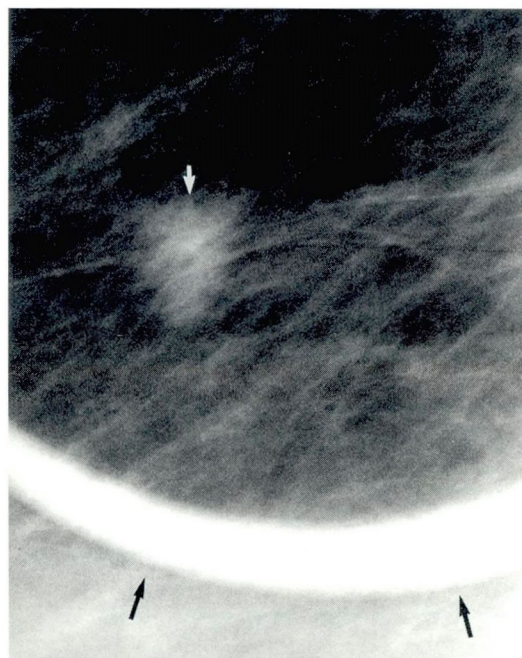
## ■ DIAGNOSTIC MAMMOGRAPHY

If a woman has a potentially abnormal finding on a screening mammogram or has signs or symptoms that could reflect breast cancer, the next step is a diagnostic mammographic evaluation.

### Diagnostic mammography after a potentially abnormal screening mammogram

Depending on the findings on the screening mammogram, the diagnostic evaluation could include additional mammographic views, an ultrasound study, or both.

**Spot compression views** are the starting point if a density, parenchymal asymmetry, architectural distortion, or possible mass is perceived. A small, round compression paddle



**FIGURE 4.** Infiltrating ductal carcinoma, spot compression view. Mass with ill-defined margins and spiculation (white arrow); no associated microcalcifications (to suggest ductal carcinoma in situ) or satellite lesions. Additional views are critical in characterizing lesions detected on screening mammograms. With complete evaluations, lesions can be characterized into several levels of concern (likelihood of malignancy) with good accuracy. The rim of the compression paddle is seen partially (black arrows).

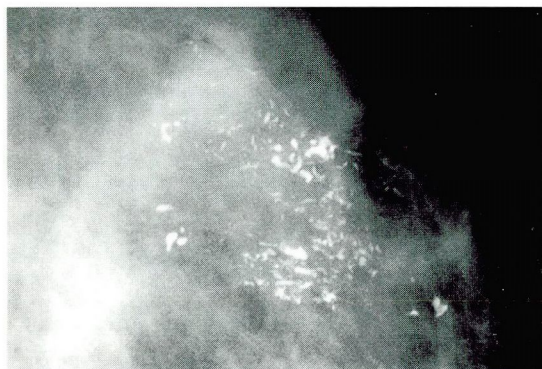
**Compression improves the image quality**

is used to focally compress the area of concern. This maximally thins out the tissue and brings the area of concern close to the film, resulting in improved resolution (**FIGURES 3 AND 4**).

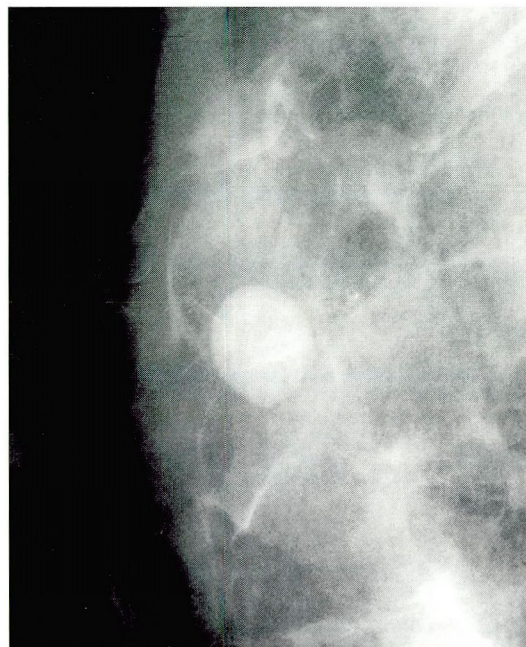**Rolled or change-of-angle views** help in confirming the presence of a mass or architectural distortion or both. Breast cancers are three-dimensional. As tissue is rolled or the angle of the incident x-ray beam is changed, cancers maintain their three-dimensional shape. Normal breast tissue, however, changes in configuration as tissue is rolled or the angle of the x-ray beam is changed.

**Spot magnification views** are used in evaluating any mass or calcifications found on a screening study. These views demonstrate more accurately the shape of the mass, its margins, whether associated calcifications are pre-





**FIGURE 5.** Ductal carcinoma in situ (DCIS), high nuclear grade; spot magnification view. The most common manifestation of DCIS is the presence of microcalcifications on screening mammograms. Microcalcifications are best characterized with magnification views. On screening images the morphology of calcifications is difficult to establish and their extent is underestimated. Linear calcification forms, pleomorphism, and differences in density are features associated with calcifications developing in areas of DCIS.



**FIGURE 6.** Probably-benign lesion; well-circumscribed mass. The reported probability of malignancy with a well-circumscribed mass is less than 2% regardless of mass size and patient age.

**In diagnostic mammograms, one must classify the lesion**

sent (and their morphology and distribution), and whether satellite lesions are present. Magnification is obtained by moving the breast away from the film, closer to the x-ray tube. The largest magnification factor available is 1.8x. A small round paddle is used for focal compression (FIGURE 5).

Ultrasonography is particularly useful in women with dense tissue, in whom mammography may be limited. It can reveal even small lesions (4–5 mm) in dense tissue. Conversely, it is less useful in women with predominantly fatty breasts. Sizable lesions (1–2 cm) may be indistinguishable (isoechoic) from surrounding fat on ultrasound. In these patients however, mammography can detect even small lesions.

### Interpreting diagnostic mammograms

Diagnostic mammography is about problem-solving, analysis, and decision-making. The radiologist must establish the presence, location, and characteristics of a lesion and classify it in one of the following ways:

**Normal.**

**Benign.** The patient can return to annual screening.

**Probably benign.** Several types of lesions are “probably benign”:

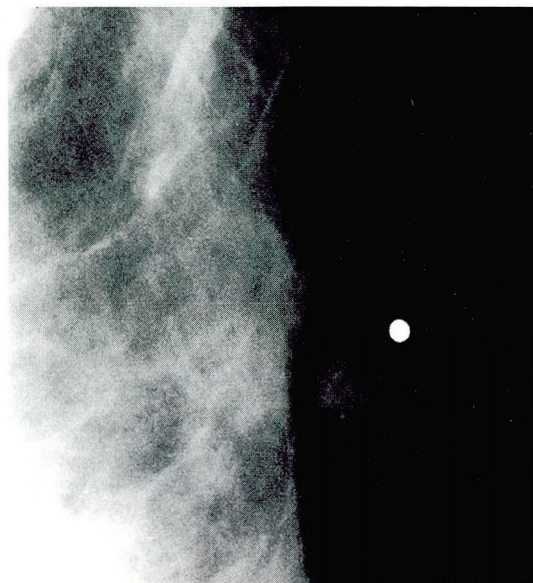
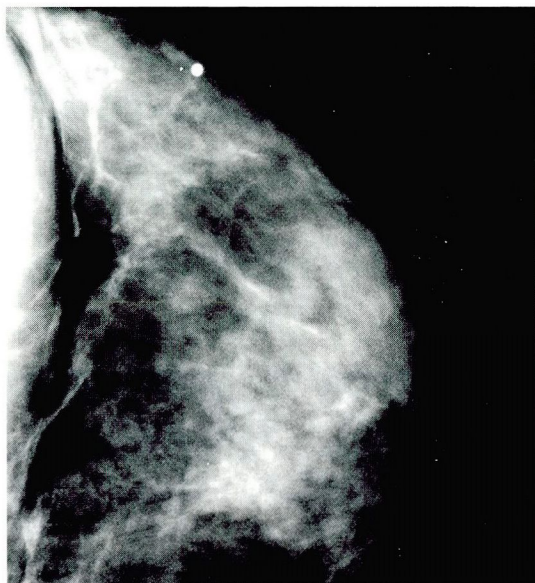- Well-circumscribed, noncalcified nonpalpable masses, regardless of size (FIGURE 6)
- Clusters of round, pearl-like calcifications
- Focal asymmetric breast tissue
- A generalized distribution of multiple (three or more) similar lesions (multiple, well-circumscribed masses or multiple clusters of round calcifications).

Although the term “probably benign” is sometimes misused, if strict criteria are applied in classifying lesions, only approximately 0.5% of these lesions prove to be malignant. The percentage is slightly higher for well-circumscribed solid masses—1.4% to 2.0%—but less than 0.5% for all other findings.<sup>17–20</sup> Also, the cancers diagnosed on follow-up studies are mostly stage 0 or 1.<sup>17–20</sup>

Women with probably-benign lesions can be managed conservatively, with mammographic follow-ups at 6, 12, and 24 months.

**Suspicious or highly suggestive of malignancy.** This situation brings up two more





**FIGURE 7.** Patient presenting with a palpable mass. **Left**, left craniocaudal view. A BB pellet marks the site of the lump. No definite lesion is seen. **Right**, tangential view of the same area demonstrates features consistent with a probably-benign lesion.

questions: Can an imaging-guided biopsy be done at this time to expedite the diagnosis?<sup>21</sup> Or does the patient potentially have a lesion that is best managed with excisional biopsy (ie, a complex sclerosing lesion or low-nuclear-grade ductal carcinoma in situ) and is surgical referral warranted?

#### Diagnostic mammography in symptomatic women

Signs or symptoms of breast cancer include a palpable lump, focal tenderness, spontaneous nipple discharge, or skin or nipple changes.

If the patient is older than 40 years and has not had a mammogram within the last year, craniocaudal and mediolateral oblique views of each breast are done; if the patient has had a mammogram within the last year, only the symptomatic breast is evaluated.

If the patient has a lump or focal tenderness, we place a metal “BB” at the site of concern when we perform the mammograms. This marker allows us to verify that the area of concern is included in the field of view. In addition to craniocaudal and mediolateral oblique views, a tangential view of the lump or area of focal tenderness is done. For a tangential view, the area of concern is placed in tangent to the x-ray beam (FIGURE 7).

#### BREAST ULTRASONOGRAPHY

If a patient with signs or symptoms of breast cancer is younger than 25 years or pregnant, ultrasonography of the breast, focused on the area of concern, is recommended for initial evaluation. It is also recommended as an adjunct to diagnostic mammography, unless the tangential mammographic image discloses fatty tissue in the area of concern.

In the past, ultrasonography was used inconsistently only to characterize masses as either cystic or solid. With the newer ultrasound equipment, however, mammographically or clinically detected (palpable) areas can be characterized with higher degrees of accuracy.<sup>20</sup>

Our ability to image small, normal breast structures has increased our understanding of breast anatomy and has led to improvements in imaging protocols. High-quality breast ultrasound requires a transducer of 7.5 MHz or higher and meticulous technique.

The advantage of ultrasonography is its ability to obtain images and manipulate them in real time, while the operator solicits the patient’s input (eg, “this is where it hurts”), compares the ultrasound image with the mammogram image, and palpates the area of concern (FIGURE 8). This correlation of mammo-

**Consider  
ultrasound for  
young women  
with breast  
symptoms**



graphic, sonographic, and clinical findings allows us to address and possibly overcome the finite false-negative rates (currently not known) associated with each of these diagnostic methods. A disadvantage of ultrasonography is that it is operator-dependent. Cysts can be made to appear solid, normal fat lobules can be made to look like lesions, and solid masses can be made to look like cysts or normal tissue, depending on operator technique.

### ■ DO ALL PALPABLE MASSES NEED A BIOPSY?

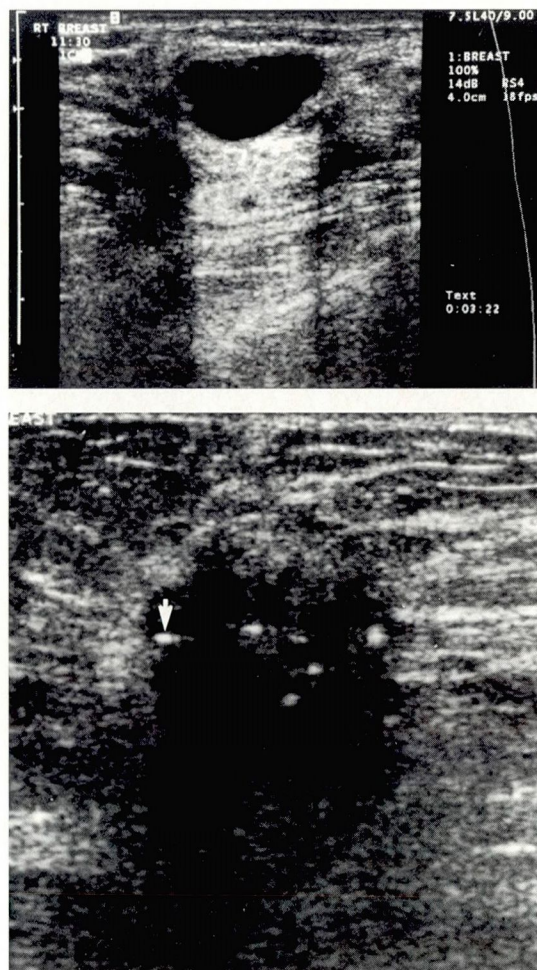
We need to reconsider the traditional teaching that a biopsy should be performed on all palpable breast masses. Sometimes, physicians proceed to biopsy a palpable mass without obtaining any diagnostic imaging beforehand, especially if the patient is young. Yet, if a mammographically detected mass appears to be benign on the basis of mammography and ultrasonography, we routinely manage it with a follow-up protocol, ie, a repeat mammogram in 6 months. Why should we treat a similar mass any differently simply because it is closer to the skin and therefore palpable?

If a benign-appearing lesion is imaged and palpated as well-defined and easily mobile, could it not be followed even though it is palpable? If sonographically dense fibrous tissue or a fibrocystic complex is correlated directly with the palpable area, a biopsy is not indicated. Similarly, if a simple cyst is imaged and the patient is otherwise asymptomatic, aspiration is not necessary.

We do not wish to dismiss the importance of physical examination. Rather, we advocate augmenting it by combining it with breast ultrasonography. In this way, clinical findings and features are incorporated into a more complete and meaningful evaluation.

### ■ SPONTANEOUS NIPPLE DISCHARGE

Spontaneous nipple discharge needs to be distinguished from expressed (nonspontaneous) nipple discharge. With vigorous breast compression, nipple discharge can be elicited in most women. This physiologic discharge is thin, milky, bilateral, and arises from multiple ducts. In contrast, women with spontaneous



**FIGURE 8.** Breast ultrasound. **Top**, cyst. Well-circumscribed anechoic mass with posterior acoustic enhancement and thin edge shadows are the ultrasound features of a cyst. Unless the patient is symptomatic, these do not need to be aspirated. **Bottom**, infiltrating ductal carcinoma with associated ductal carcinoma in situ. Irregular mass with shadowing. High specular echoes (arrow) are consistent with calcifications associated with the intraductal component of this tumor.

**Not all palpable lesions call for biopsy**

nipple discharge describe small dark spots on their bra cups or nightclothes; some will notice the discharge after a hot bath or shower (when nipple musculature is relaxed). Physical examination does not usually disclose a palpable mass; however, crusting may be seen overlying the secreting duct orifice, and in some women a trigger point can be





identified. When this trigger point is compressed, nipple discharge (often abundant and projectile) is obtained from a single duct. As the palpating hand moves away from the trigger point the discharge stops.

Approximately 45% to 50% of women with spontaneous nipple discharge have intraductal papillomas, 30% to 35% have fibrocystic changes, 1% to 5% have duct ectasia, and 5% to 13% have breast cancer.<sup>22-26</sup> Although the lesion causing the discharge may be focal and located close to the nipple in some patients, in others it can be several cm from the nipple in a non-dilated or arborized duct or it may diffusely involve the duct for several cm.

The traditional approach has included cytologic analysis of the discharge and surgical excision. However, a negative cytologic study does not exclude significant pathology, and positive results need histologic confir-

mation. Surgical excision without preoperative guidance presumes that ductal anatomy and lesion location and extent are predictable and that the pathologist will know what portion of the specimen to examine histologically.

**Ductography** is therefore recommended.<sup>22-25</sup> This procedure is safe, simple, and easy and involves injecting a water-soluble contrast agent into the duct orifice and obtaining mammographic views. Ductography can demonstrate the ductal anatomy and the location of intraductal lesions, including multiple lesions. If the study is done before surgery, it can increase the chances of identifying a definitive lesion accounting for the discharge. The yield can be increased further if preoperative ductograms are done with methylene blue to stain the abnormal duct for the surgeon and pathologist.<sup>27</sup>



## REFERENCES

1. Kerlikowske K, Grady D, Rubin SM, Sandrock C, Ernster VL. Efficacy of screening mammography. A meta-analysis. *JAMA* 1995; 273:149-154.
2. Cardenosa G, Eklund GW. Screening mammography in women 40-49 years old [Commentary]. *AJR* 1995; 164:1104-1106.
3. Bjurstam N, Bjornel L, Duffy SW. The Gothenberg breast cancer screening trial: results from 11 years follow up. In NIH Consensus Development Conference: Breast Cancer Screening for Women ages 40-49, Program and Abstracts. Bethesda MD, National Institutes of Health, 1997.
4. Andersson I. Results from the Malmö breast screening trial, in NIH Consensus Development Conference: Breast Cancer Screening for Women ages 40-49, Program and Abstracts. Bethesda MD, National Institutes of Health, 1997.
5. Moskowitz M. Breast cancer: age-specific growth rates and screening strategies. *Radiology* 1986; 161:37-41.
6. Tabar L, Fagerberg G, Chen HH, et al. Efficacy of breast cancer screening. *Cancer* 1995; 75:1507-1517.
7. Moskowitz M. Guidelines for screening for breast cancer. *Radiol Clin North Am* 1992; 30:221-233.
8. Leitch AM, Dodd GD, Constanza M. American Cancer Society guidelines for the early detection of breast cancer: update 1997. *CA Cancer J Clin* 1997; 47:150-153.
9. Sickles EA. Auditing your practice. *RSNA Syllabus Categorical Course in Breast Imaging* 1995:81-91.
10. Linver MN, Osuch JR, Brenner RJ, Smith RA. The mammographic audit: a primer for the Mammography Quality Standards Act (MQSA). *AJR* 1995; 165:19-25.
11. Sickles EA. Quality assurance: how to audit your own mammography practice. *Radiol Clin North Am* 1992; 30:265-275.
12. Haagensen CD. Intraductal breast carcinoma. In *Diseases of the Breast*. 3rd ed. Philadelphia: W.B. Saunders Co, 1986:782-797.
13. Poplack SP, Wells WA. Ductal carcinoma in situ of the breast: mammographic-pathologic correlation. *AJR* 1998; 170:1543-1549.
14. Stomper PC, Connolly JL, Mayer JE, Harris JR. Clinically occult ductal carcinoma in situ detected with mammography: analysis of 100 cases with radiologic-pathologic correlation. *Radiology* 1989; 172:235-241.
15. Eklund GW, Cardenosa G. The art of mammographic positioning. *Radiol Clin North Am* 1992; 30:21-53.
16. Eklund GW, Cardenosa G, Parsons W. Assessing adequacy of mammographic image quality. *Radiology* 1994; 190:297-307.
17. Sickles EA. Periodic mammographic follow-up of probably benign lesions: results in 3,184 consecutive cases. *Radiology* 1991; 179:463-468.
18. Varas X, Leborgne F, Leborgne JH. Nonpalpable, probably benign lesions: role of follow-up mammography. *Radiology* 1992; 184:409-414.
19. Sickles EA. Nonpalpable, circumscribed, noncalcified solid breast masses: likelihood of malignancy based on lesion size and age of patient. *Radiology* 1994; 192:439-442.
20. Stavros AT, Thickman D, Rapp CL, Dennis MA, Parker SH, Sisney GA. Solid breast nodules: use of sonography to distinguish benign and malignant lesions. *Radiology* 1995; 196:123-134.
21. Parker SH, Jobe WE, Dennis MA, et al. US-guided automated large-core breast biopsy. *Radiology* 1993; 187:507-511.
22. Cardenosa G, Doudna C, Eklund GW. Ductography of the breast: technique and findings. *AJR* 1994; 162:1081-1087.
23. Cardenosa G, Eklund GW. Ductography. *Appl Radiol* 1992 Sept; 24-29.
24. Cardenosa G, Eklund GW. Interventional procedures in breast imaging (part II): ductography, cyst aspiration and pneumocystography and fine needle aspiration. In Taveras JM, Ferrucci JT, editors. *Radiology*. Philadelphia: JB Lippincott, 1993.
25. Cardenosa G, Eklund GW. Ductography. In Dershaw DD, editor. *Interventional Breast Procedures*. New York: Churchill Livingstone, 1996.
26. Leis HP, Cammarata A, LaRaja RD. Nipple discharge: significance and treatment. *Breast* 1985; 11:6-12.
27. Van Zee KJ, Ortega Perez G, Minnard E, Cohen MA. Preoperative galactography increases the diagnostic yield of major duct excision for nipple discharge. *Cancer* 1998; 82:1874-1880.

**ADDRESS:** Gilda Cardenosa, MS, MD, Clinic Radiology, A10, The Cleveland Clinic Foundation, 9500 Euclid Avenue, Cleveland, OH 44195, e-mail cardeng@ccf.org.