

**SHAMIK AIKAT, MD**

Department of Cardiology, Cleveland Clinic

SASAN GHAFARI, MD

Department of Cardiology, Cleveland Clinic

A review of pericardial diseases: Clinical, ECG and hemodynamic features and management

ABSTRACT

Pericardial diseases are common, have multiple causes, and are often misdiagnosed. Physicians need to recognize the characteristic and distinguishing features of the three most important pericardial conditions: acute pericarditis, cardiac tamponade, and constrictive pericarditis. In these conditions, proper diagnosis and appropriate management can significantly reduce morbidity and mortality.

KEY POINTS

Acute pericarditis is an important part of the differential diagnosis of chest pain syndromes and needs to be distinguished from acute myocardial infarction both clinically and electrocardiographically.

Suspect pericardial tamponade in any patient with acute dyspnea, especially in the presence of a pericardial rub, elevated jugular venous pressure, and hypotension.

Two-dimensional echocardiography with Doppler is essential for a rapid and accurate confirmation of pericardial tamponade and for safe and effective therapeutic pericardiocentesis.

Constrictive pericarditis is often a diagnostic challenge and requires a high index of clinical suspicion. Elevated jugular venous pressures distinguish it from primary liver disease, but echocardiography, magnetic resonance imaging, computed tomography, hemodynamic studies, and even endomyocardial biopsy are often needed.

BECAUSE PERICARDIAL DISEASES are common and often misdiagnosed, physicians need to be familiar with their presentations and distinguishing features.

This article reviews the clinical features, diagnosis, and management of acute pericarditis, cardiac tamponade, and constrictive pericarditis.

THE PERICARDIUM

The pericardium envelopes the heart, extending on to the adventitia of the great vessels. It is 1 to 2 mm thick and consists of an outer and an inner layer. The tough, fibrous outer layer is called the parietal pericardium, and the serous inner layer is called the visceral pericardium. The parietal and visceral pericardium are separated by fluid: 15 to 50 mL of an ultrafiltrate of plasma that acts as a lubricant.^{1,2}

The pericardium limits excessive cardiac movement and acute cardiac distension. By providing a nondistensible outer layer, it generates a negative intrapericardial pressure during inspiration, which contributes to chamber filling and establishes ventricular interdependence in maintaining parity between right and left heart filling and cardiac output. In addition, the pericardium acts as a barrier to infection and the extension of cancer.^{3–5}

ACUTE PERICARDITIS

Acute pericarditis is common, but its true incidence is not precisely known because it often goes unrecognized and has a self-limiting course. In different autopsy series, pericarditis

TABLE 1

Causes of acute pericarditis**Idiopathic****Infection**

Viral: coxsackievirus B (most common viral cause),
coxsackievirus A, echovirus, human immunodeficiency virus
Bacterial: *Staphylococcus aureus*, *Pneumococcus* species,
Mycoplasma
Mycobacterial: tuberculosis (most common cause worldwide)
Fungal: *Histoplasma*, *Aspergillus*
Protozoal: *Toxoplasma*
Other: *Rickettsia*, anaerobes, parasites

Malignancy

Secondary neoplasms (common): breast, lung, lymphoma,
leukemia, melanoma
Primary neoplasms (rare): pericardial mesothelioma,
angiosarcoma

Connective tissue disease

Systemic lupus erythematosus, rheumatoid arthritis, sarcoidosis,
scleroderma

Myocardial infarction**Radiation therapy****Cardiac surgery****Uremia****Myxedema****Aortic dissection****Drugs** (as part of drug-induced systemic lupus erythematosus)

Hydralazine
Methyldopa
Procainamide
Others: cromolyn sodium, doxorubicin, penicillin

ADAPTED FROM REFERENCES 1,5,7,8,24

was detected in 2% to 6% of the sample groups. Acute pericarditis is estimated to be clinically present in 1 of every 1,000 hospitalized patients.⁴

Acute pericarditis runs a time course of less than 6 weeks. If pericarditis lasts 6 weeks to 6 months, it is termed "subacute."⁴ It is considered chronic when it has been present 6 months or longer.⁴

Causes of acute pericarditis

Inflammation of the pericardium has a variety of causes (TABLE 1).

Idiopathic. In most cases of acute pericarditis the cause is unknown. A Spanish study⁶ followed 100 consecutive patients admitted to a university hospital because of acute pericarditis, and the investigators were able to determine a cause in only 22%.

Viral infections. Patients with idiopathic pericarditis are often thought to have been infected by a cardiotropic virus such as coxsackievirus B. Other known viral pathogens are echovirus 8, mumps, influenza, and Epstein-Barr virus. However, investigations to prove a viral cause, even in patients with a typical viral prodrome, have an extremely low yield.⁷

Neoplastic pericardial involvement is seen at autopsy in up to 10% of patients with a known malignancy.⁷ The most common malignancies that affect the pericardium are lung and breast cancers, melanomas, lymphomas, and leukemias. Primary pericardial tumors are rare and usually take the form of benign pericardial cysts.^{5,7,8}

Symptoms and signs of acute pericarditis


Chest pain is the cardinal symptom of acute pericarditis. The pain:

- Is often located retrosternally or precordially
- Is sharp, knifelike, and pleuritic
- Worsens with inspiration and in the supine position
- Is relieved on sitting and leaning forward
- Sometimes alters or recurs with each beat of the heart
- Can radiate to the left shoulder, the arm, neck, back, or epigastric region. Radiation of the pain to the trapezius ridge is an uncommon but specific sign of acute pericarditis.⁵

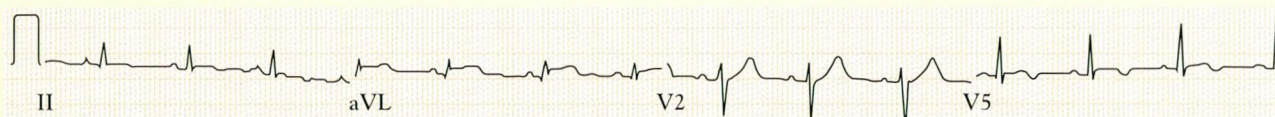
Dyspnea is the other prominent symptom, though not always present.

Other symptoms may include fever, cough, hoarseness, nausea, vomiting, palpitations, dizziness, and lightheadedness. Certain symptoms depend on the cause of the pericarditis: eg, flulike symptoms (fever, myalgias) in viral pericarditis or a fulminant and rapid course with prominent systemic septic features in purulent bacterial pericarditis. Chronic cough, history of weight loss, night sweats, and generalized malaise may represent tuberculous pericarditis.

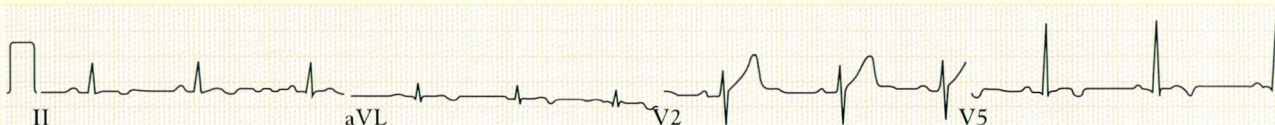
Acute pericarditis progresses through stages



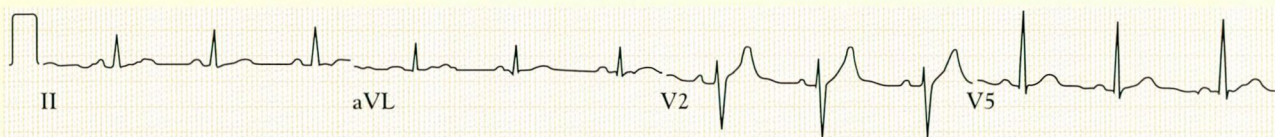
Stage 1 begins with the onset of chest pain, and lasts several days. Note the concave upward ST elevations seen in the precordial and limb leads. The T waves remain upright in those leads with ST-segment elevation.



Stage 2. The ST segments return to the baseline, T waves become flat, and the PR segment may become depressed.



Stage 3. T-wave inversion may be seen. This may persist for weeks, or even indefinitely.



Stage 4. Normalization.

FIGURE 1. The electrocardiographic stages of acute pericarditis

A **friction rub** is the pathognomonic sign of acute pericarditis. This is a scratchy, superficial, “Velcro-like” sound, best heard with the diaphragm of the stethoscope applied firmly to the left lower sternal border with the patient leaning forward and momentarily holding his or her breath at end-expiration. The rub is often evanescent and may be triphasic, having an atrial systolic, a ventricular systolic, and a diastolic component.⁵ It is uncommon for all three phases to be present; often only a monophasic or biphasic rub may be heard. When an effusion develops, the rub may become subdued or may even disappear, but occasionally the rub persists even when the effusion is large.

Diagnostic studies for acute pericarditis

Electrocardiography. Serial electrocardiograms commonly show four stages of

changes in acute pericarditis (**FIGURE 1**).^{5,8}

Note: the first stage is dominated by ST-segment elevation, which can also be seen in acute myocardial infarction or early repolarization. It is vital to distinguish between acute myocardial infarction and acute pericarditis, since thrombolytic therapy can result in hemorrhagic cardiac tamponade in patients with pericarditis. The distinction can be difficult. Important differentiating features are outlined in **TABLE 2** and **FIGURE 2**.

Chest radiography may be normal, but the cardiac silhouette may be enlarged if enough fluid (at least 200–250 mL) accumulates in the pericardial sac.^{1,9}

Echocardiography. A pericardial effusion may accompany acute pericarditis. The presence of a significant effusion or accumulation of an effusion on serial echocardiographic

TABLE 2

Electrocardiographic features of acute pericarditis, acute myocardial infarction, and early repolarization

ELECTROCARDIOGRAPHIC FEATURE	ACUTE PERICARDITIS	ACUTE MYOCARDIAL INFARCTION	EARLY REPOLARIZATION
ST-segment concavity	Upward	Downward	Upward
Loss of R wave, presence of Q wave, reciprocal changes	Absent	Present	Absent
Location of ST-segment elevation	Limb and precordial leads (except V ₁ , aVR)	In leads corresponding to the infarct territory	Precordial leads
PR-segment elevation	Specific to acute pericarditis, especially when seen in aVR	Absent	Absent
ST-to-T amplitude ratio in V ₆	> 0.25, helps to distinguish acute pericarditis from acute myocardial infarction	< 0.25	< 0.25
T-wave inversion	In leads exhibiting ST-segment elevation after the ST segment has normalized to baseline	In leads exhibiting ST-segment elevation	Absent
Arrhythmias	Sinus tachycardia common Supraventricular tachyarrhythmias, including atrial fibrillation or flutter	Any type may occur	Do not occur in the absence of underlying myocardial disease

ADAPTED FROM REFERENCES 1,4,7,8

studies supports the diagnosis. Echocardiography is the most sensitive technique to detect fluid in the pericardial sac, as it can detect as little as 15 mL.¹

Computed tomography of the chest may be a sensitive method to detect an effusion or pericardial thickening, especially in those who do not have a good echocardiographic “window” (eg, patients with chronic obstructive pulmonary disease, thoracic skeletal deformities).¹

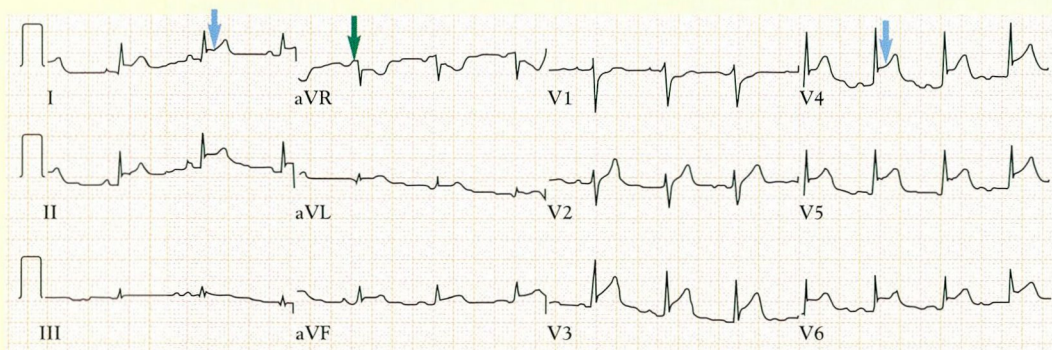
Laboratory studies. Nonspecific markers of acute inflammation such as C-reactive protein and the erythrocyte sedimentation rate are usually elevated. Nonspecific leukocytosis may also be seen. A mild increase in the creatine kinase MB isozyme (CK-MB) may be seen.^{1,10} If CK-MB is significantly elevated, a perimyocarditis should be strongly consid-

ered in the differential diagnosis.

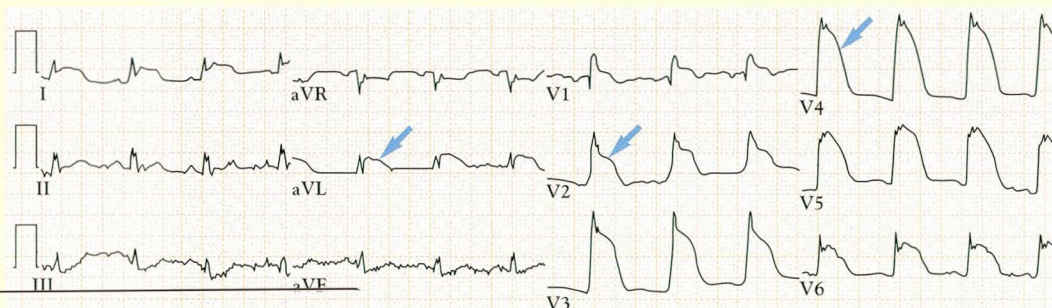
Pericardiocentesis and pericardial biopsy are not routinely indicated for diagnosing suspected acute pericarditis. However, when pericardiocentesis is performed therapeutically, it may yield diagnostic information. A serous (nonhemorrhagic, nonpurulent) effusion is associated with idiopathic or viral pericarditis. A serohemorrhagic or hemorrhagic effusion may indicate an idiopathic, viral, tuberculous, uremic, neoplastic, or posttraumatic cause.⁶

High adenosine deaminase (ADA) activity levels in the effusion may denote a tuberculous process.⁶ Cytologic study of the fluid and histopathologic study of the pericardium may help determine a specific infective agent or a neoplastic or connective-tissue disease process.

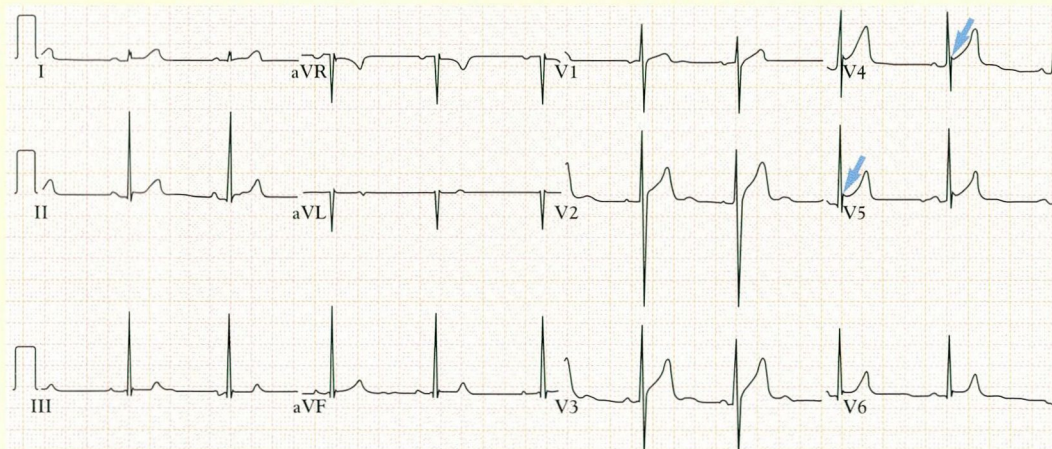
Acute pericarditis: Differential diagnosis



Acute pericarditis. Note the upward-concavity ST elevations in limb leads I, II, aVF, and aVL and in precordial leads V₃, V₄, V₅ and V₆ (blue arrows) and the PR-segment elevation in aVR (green arrow).



Acute myocardial infarction. Note the concavity-downward ST elevation in leads I, aVL, V₁, V₂, V₃, V₄, V₅, and V₆ (blue arrows), indicating a large anterior myocardial infarction.



Early repolarization. Note the elevation of the J point (blue arrows) with pseudo-elevation of the ST segment in V₄, V₅, and V₆.

The shape of the ST elevation helps distinguish acute pericarditis from acute MI

FIGURE 2

Treatment

of uncomplicated acute pericarditis

The underlying cause should always be treated if known. In addition:

Nonsteroidal anti-inflammatory drugs (NSAIDs) relieve symptoms and suppress further inflammation. Aspirin 650 mg by mouth four times a day, naproxen 250 to 500 mg by mouth twice a day, or indomethacin 50 to 75 mg by mouth three times a day are all acceptable.⁷

Corticosteroids are controversial in the treatment of simple acute pericarditis. Prednisone 60 mg by mouth daily for 2 to 3 days followed by a rapid taper can be used in patients whose condition does not respond to NSAIDs or who have contraindications to NSAIDs.¹¹ Corticosteroids are also of value in treating recurrent or relapsing pericarditis.¹¹

Colchicine has demonstrated efficacy in acute or recurrent pericarditis in patients with familial Mediterranean fever, and it also has shown benefit in a few studies in idiopathic recurrent pericarditis.^{4,12}

Complications of acute pericarditis

Potential complications of acute pericarditis include recurrent pericarditis, pericardial effusion, cardiac tamponade, and chronic pericarditis.

Recurrent pericarditis occurs in an estimated 15% to 30% of patients who suffer acute pericarditis. Recurrences can cause bouts of disabling chest pain and may even be complicated by myocarditis, pericardial effusions, pericardial tamponade, and sometimes, chronic constrictive pericarditis. Recurrent pericarditis and acute pericarditis share common causes; however, recurrences are more common when the pericarditis is due to a connective-tissue disease, radiation therapy, or neoplastic pericardial involvement.⁵

Pericardial effusion is a nonspecific response of the pericardium to any insult, and it may develop slowly and silently.¹³ Effusions often resolve spontaneously.

Large effusions of up to 2 L of fluid can cause symptoms related to compression of mediastinal structures. Pressure on the bronchi can cause dyspnea and cough, compression of the esophagus can cause dysphagia, and compression of the left recurrent laryngeal

nerve can cause hoarseness. Rapid accumulation of an effusion, especially if the pericardial sac is diseased, nonsupple, nonyielding, or fibrotic, may result in the dreaded complication of cardiac tamponade, pulseless electrical activity, and death.

■ PERICARDIAL TAMPONADE

Cardiac tamponade occurs when enough fluid accumulates within the pericardial sac to compress the heart and impair diastolic filling.

Animal experimentation by means of intrapericardial fluid instillation and concomitant hemodynamic monitoring reveal evolving stages of hemodynamic compromise. Initially, the cardiac stroke volume falls but the cardiac output is maintained by a compensatory tachycardia. With further instillation of fluid, the cardiac output starts to diminish; however, blood pressure is maintained by increased systemic arterial resistance. At this critical juncture, small increases in the amount of the effusion result in dramatic increases in the intrapericardial pressure and decreases in cardiac output.^{4,14}

The blood-pressure response also is greatly influenced by the state of suppleness of the pericardium, the rate of fluid accumulation, the state of the myocardial contractility, and the intravascular volume.^{4,14} A rapid accumulation of effusion in a fibrotic pericardium, combined with impaired left ventricular function and a hypovolemic state, can precipitate pericardial tamponade even if the effusion is small.¹⁴

Symptoms and signs of pericardial tamponade

Acute dyspnea is the most common symptom of pericardial tamponade. Orthopnea, precordial pain, and diminished urine output are other symptoms. The condition should be suspected in any patient with sudden, unexplained dyspnea, especially in the presence of a pericardial rub, elevated jugular venous pulses, or hypotension.

The three cardinal clinical signs in tamponade, as described by Beck in 1935, are:

- Hypotension
- Raised jugular venous pressure
- Muffled heart sounds.¹

The triad is typical of acute tamponade caused

Acute pericarditis is often viral, but this is often difficult to confirm



Pericardial tamponade: Electrical alternans

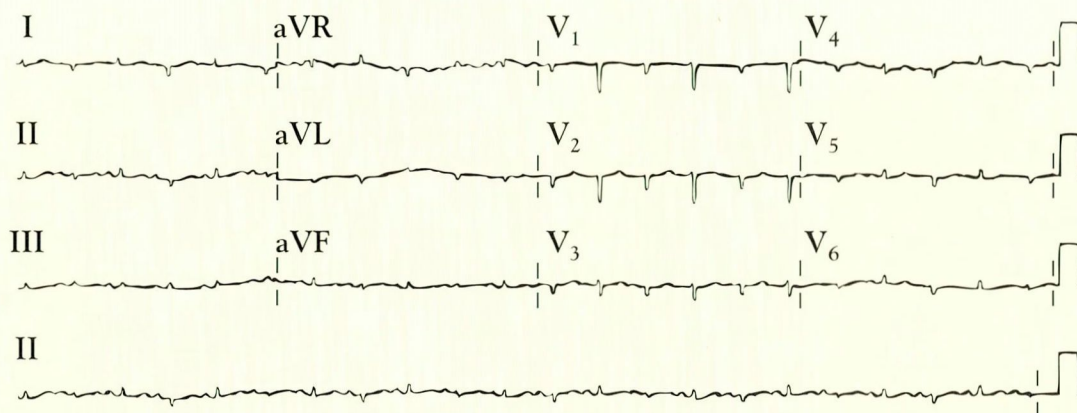


FIGURE 3. Electrical alternans in pericardial tamponade due to the swinging of the heart within the pericardial space.

FROM LONGO MJ, JAFFE CC. IMAGES IN CLINICAL MEDICINE. ELECTRICAL ALTERNANS N ENGL J MED 1999; 341:2060, USED WITH PERMISSION

by intrapericardial hemorrhage following a ruptured ventricular aneurysm or a pericardial extension of an aortic dissection.

Other important signs are tachycardia, tachypnea, and pulsus paradoxus.

Pulsus paradoxus is an exaggeration of the normal decrease in left ventricular stroke volume and blood pressure that occurs during inspiration. Patients may not exhibit this sign if they have left ventricular dysfunction, an atrial septal defect, severe aortic regurgitation, or a pulmonary embolus. Conversely, those with obstructive airway disease may exhibit pulsus paradoxus and an elevated jugular venous pressure in the absence of pericardial tamponade.⁷

Measurement of pulsus paradoxus. With the patient respiring normally in a semirecumbent position, the blood pressure is manually measured. The pressure at which the Korotkoff sounds first become intermittently audible represents the systolic blood pressure during expiration. The cuff is then slowly deflated, and the pressure at which all the Korotkoff sounds are audible represents the systolic pressure during inspiration. The pulsus paradoxus equals the difference between the expiratory systolic pressure and the inspiratory systolic pressure.⁷

A difference in the systolic blood pressure of up to 10 mm Hg between inspiration and

expiration by sphygmomanometry is usually considered normal. However, sphygmomanometry can be inaccurate: a 10-mm Hg decrease by sphygmomanometry can correspond to a 25-mm Hg decrease by intra-arterial blood pressure measurement. Therefore, in an appropriate clinical setting, a 10-mm Hg sphygmomanometric difference should be considered significant.⁷

Diagnostic studies for pericardial tamponade

Electrocardiography. Common electrocardiographic findings include tachycardia, low-voltage QRS complexes, T-wave flattening, and electrical alternans (FIGURE 3).¹⁵

Echocardiography. Two-dimensional Doppler echocardiography confirms the diagnosis of pericardial tamponade. The main echocardiographic findings are outlined in TABLE 3. The Doppler findings are based on a characteristic disproportionate rise in right-sided intracardiac pressure and fall in left-sided intracardiac pressure on inspiration.

Swan-Ganz catheterization can confirm that the systemic venous pressures are elevated and the right heart diastolic pressures are equalized. (Right atrial, pulmonary arterial diastolic, and pulmonary capillary wedge pressures within 5 mm Hg of each other strongly suggest pericardial tamponade.)

2-D Doppler confirms the diagnosis of pericardial tamponade

TABLE 3

Echocardiographic features of pericardial tamponade

Two-dimensional echocardiography

- An echo-free space throughout the cardiac cycle, seen when the pericardial effusion is > 25 mL
- Late diastolic right atrial compression and right ventricular early diastolic collapse
- Dilated inferior vena cava without inspiratory collapse
- Decreased mitral valve excursion and ejection fraction slope
- Swinging of heart (seen when the pericardial effusion is large)

Doppler echocardiography

- Abnormal increase ($\geq 40\%$) in inspiratory flow velocity across the tricuspid valve
- Abnormal decrease ($\geq 25\%$) in inspiratory flow velocity across the mitral valve
- Delayed inspiratory mitral valve opening with subsequent lengthening of the "isovolumic relaxation time" (IVRT) and decreased mitral E velocity (reciprocal changes on the right side of the heart)
- In the pulmonary vein, decreased diastolic forward flow during inspiration and increased diastolic flow during expiration
- In the hepatic vein, increased reverse hepatic flow during expiration

ADAPTED FROM REFERENCES 4,22,23

Treatment of pericardial tamponade

Pericardial tamponade is a medical emergency. Hemodynamically unstable patients should be managed in an intensive care unit.

Leg elevation, volume expansion with wide-open intravenous infusion of 0.9% normal saline or colloids, and immediate echocardiographically guided **pericardiocentesis** are the most important measures in the management of pericardial tamponade. Note: positive-pressure ventilation can further critically diminish cardiac return and decrease cardiac output in this setting.

Pericardiocentesis. In a patient with pulseless electrical activity and suspected pericardial tamponade, emergency bedside pericardiocentesis can be life-saving. The sub-xiphoid approach is considered the safest because its route is extrapleural and avoids the

coronary arteries (FIGURE 4).⁴ Emergency pericardiocentesis can be performed "blindly" (ie, without echocardiographic guidance), but echocardiographic guidance is preferred. Blind pericardiocentesis is associated with mortality rates of up to 6% and with complication rates of up to 50%. Complications include trauma to the liver, myocardium, coronary vessels, and lungs.^{16,17}

If the pericardial effusion is loculated in the posterolateral region and is inaccessible by pericardiocentesis or the cardiac tamponade is recurrent, then the surgical creation of a **pericardial window** is indicated.

Treat the underlying cause. The underlying cause of the pericardial effusion should always be sought and appropriately treated to eliminate the risk of recurrence.

■ CONSTRUCTIVE PERICARDITIS

In constrictive pericarditis, the pericardial sac becomes fibrotic and thickened, resulting in impaired diastolic filling of the heart. Sometimes a tense, chronic pericardial effusion can restrict diastolic filling, a condition for which Hancock popularized the term chronic "effusive constrictive" pericarditis.^{18,19} Constrictive pericarditis leads to a congestive state with peripheral interstitial ("third-space") accumulation of fluid.

The differential diagnosis of constrictive pericarditis includes congestive heart failure, restrictive cardiomyopathy, cirrhosis, nephrotic syndrome, and chronic malabsorption states.

Causes of constrictive pericarditis

Any of the conditions that cause acute pericarditis may also lead to constrictive pericarditis. TABLE 4 outlines the etiologies.

Idiopathic. Because acute pericarditis is often self-limiting and clinically missed, it is not surprising that idiopathic constrictive pericarditis without any antecedent pericarditic episode heads the list of causes of constrictive pericarditis. The second most important cause is constrictive pericarditis following acute idiopathic pericarditis.

Tuberculosis continues to be a leading cause of constrictive pericarditis worldwide, but its incidence has declined in western



Technique for emergency pericardiocentesis

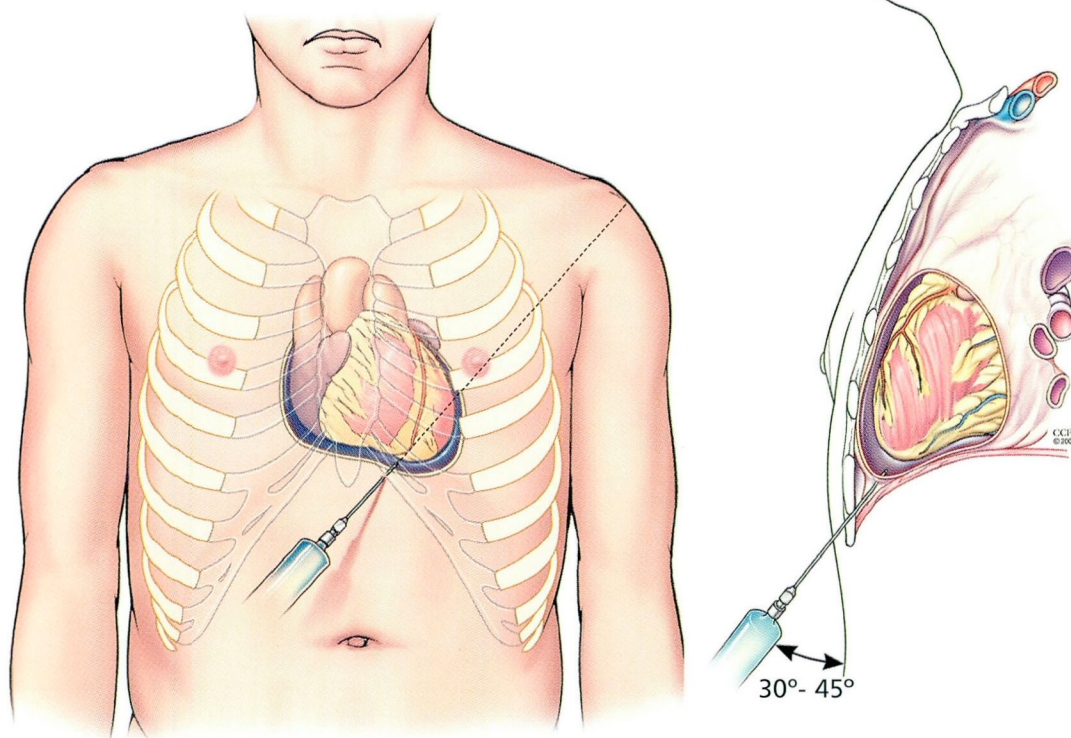


FIGURE 4. In cardiac tamponade, pericardiocentesis can be lifesaving but poses the risk of puncturing the ventricle and coronary arteries. Ideally, the procedure is done in a procedure room with echocardiographic monitoring. In an emergency, however, it can be done at the bedside. Insert a 16-gauge or 18-gauge needle into the left xiphocostal angle, 30° to 45° to the skin, towards the left shoulder.

**Emergency
bedside
pericardiocentesis
can be
life-saving**

countries and now accounts for fewer than 6% of all cases.^{18,19} Tuberculosis accounted for only 0.7% of all patients who underwent surgery for constrictive pericarditis at the Mayo Clinic between 1985 and 1995.²⁰

Cardiac surgery is complicated by constrictive pericarditis in fewer than 0.5% of all cases; however, with more than 700,000 cardiac surgeries performed in the United States annually, this is emerging as an important cause of constrictive pericarditis.²⁰

Other important causes of constrictive pericarditis are mediastinal irradiation²¹ and connective-tissue diseases.²⁰ Uremia is a less common cause. Rarer causes include asbestosis and mulibrey nanism, an exotic hereditary multisystem disorder associated with a dwarfism seen most commonly in Finns.^{18,22,23} (Mulibrey is a mnemonic acronym for the

organs commonly affected: *muscle, liver, brain, and eye.*)

Symptoms and signs of constrictive pericarditis

Constrictive pericarditis tends to develop and progress over many months and years.

Common symptoms are:

- Exertional dyspnea (the most common symptom)
- Pitting peripheral edema
- Abdominal swelling
- Fatigue
- Weight gain
- Abdominal discomfort (often associated with nausea and vomiting).

Less-common symptoms are chest pain, orthopnea, paroxysmal nocturnal dyspnea, and right upper-quadrant pain.

TABLE 4

Causes of constrictive pericarditis**Idiopathic** (no history of recent acute pericarditis)**Acute idiopathic pericarditis****Cardiac surgery, trauma****Radiotherapy****Infection**

Tuberculosis

Coxsackievirus B

Bacteria

Fungi (histoplasmosis)

Parasites (echinococcosis)

Connective tissue disease

Rheumatoid arthritis

Systemic lupus erythematosus

Uremia**Dressler syndrome****Hereditary (mulibrey dwarfism)****Drug-induced lupus****Rare causes**

Asbestosis, Whipple disease, actinomycosis, Lassa fever

ADAPTED FROM REFERENCES 6, 17, 20, 21

Increased abdominal girth is often seen on physical examination. First described by Pick in 1896, the common presence of ascites and hepatomegaly at presentation of these patients led to the use of the eponym Pick's disease or pseudocirrhosis in the past.¹⁹

Elevated jugular venous pressure distinguishes constrictive pericarditis from primary liver disease. Careful bedside interpretation of the jugular venous pulsations may reveal a rapid, often deep Y descent. This constitutes the right atrial W (or M) wave form first described by Bloomfield.¹⁸

Kussmaul's sign, first described by Kussmaul in 1873, is a paradoxical inspiratory rise in jugular venous pulsation, or failure of the jugular venous pulsations to fall with inspiration.²³ The pathophysiologic basis of Kussmaul's sign may be that the rigid, nondistensible pericardium fails to transmit intrathoracic pressure changes to the cardiac chambers, and the increased inspiratory return results in elevated central venous pressures.

Abnormal heart sounds. The cardiac apical impulse is often absent, and the heart

sounds are muffled. A pericardial "knock" may be heard. This is a higher-pitched early diastolic variant of the S3, occurring just after the second heart sound, best audible with the diaphragm of the stethoscope. It was first described by Corrigan in 1842 and is thought to be due to the sudden diastolic restriction of left ventricular filling by the pericardium.²³

Diagnostic studies for constrictive pericarditis

Chest radiography. Typically, the cardiopericardial silhouette is normal-sized in constrictive pericarditis, and the lung fields are clear. The cardiopericardial silhouette may be enlarged in cases of "effusive-constrictive" pericarditis. Left atrial enlargement, "eggshell"-shaped pericardial calcification, and pleural effusions may also be seen. Pulmonary edema is reported in 5% to 10% of cases.^{18,23}

Electrocardiography. The electrocardiogram is often abnormal. Left atrial enlargement, P mitrale (abnormally wide, notched P waves), nonspecific T-wave changes, and low-voltage QRS complexes may be seen.²³ Atrial arrhythmias such as atrial flutter and fibrillation can occur in up to one third of cases.

Echocardiography. M-mode, two-dimensional, and Doppler studies provide important supportive information when diagnosing constrictive pericarditis. M-mode and two-dimensional echocardiographic findings include the following:

- Pericardial thickening (which often goes undetected)
- Premature pulmonary valve opening due to elevated right ventricular diastolic pressures
- Enlargement of both atria
- Paradoxical systolic septal movement (septal bounce)
- Diastolic flattening of the left ventricular posterior wall
- Dilated inferior vena cava with minimal respiratory variation
- Well-preserved left ventricular size and function.

Doppler studies may reveal respiratory variation in right and left ventricular filling velocities similar to those seen in pericardial



Constrictive pericarditis: Hemodynamic signs

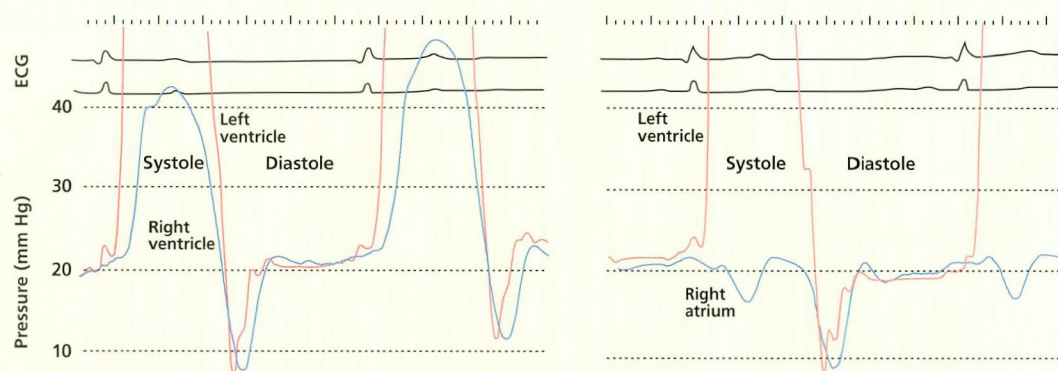


FIGURE 5. Ventricular hemodynamics in constrictive pericarditis. **Left**, the left ventricular and right ventricular pressure curves show early diastolic dips with a sharp transition to a plateau—the “square root” sign. The waves also show diastolic equilibration. **Right**, right atrial pressure curve shows the “W” wave form.

tamponade. After inspiration, the velocity of flow through the mitral valve and the pulmonary veins decreases; on expiration, the velocity increases. Across the tricuspid valve and the hepatic veins the pattern is reversed: the flow velocity increases after inspiration and decreases on expiration. The deceleration time of the early filling wave (E) of the mitral and tricuspid valves shows the following changes:

- Mitral inflow: inspiratory E is less than expiratory E (> 25% change); deceleration time is usually less than 160 ms
- Hepatic venous flow: diastolic forward flow is markedly decreased on expiration.²⁴

Hemodynamic studies. Patients suspected of having constrictive pericarditis should undergo simultaneous right and left heart catheterization. In the right ventricle, pressure tracings show elevated pressures with an early dip and a plateau (“square-root” wave form; **FIGURE 5**). Pressure is also elevated in the left ventricle. In the right atrium, elevated pressure with prominent X and Y descents results in the “M” or “W” wave form classically described in constrictive pericarditis.¹⁹ This waveform may also be seen in mixed restrictive-constrictive diseases.

Magnetic resonance imaging and computed tomography. In 1982 Isner^{18,19} demon-

ed the value of computed tomography in the diagnosis of constrictive pericarditis.^{18,19} The normal pericardium is less than 3 mm thick.²¹ In a patient with a hemodynamic pattern compatible with constrictive pericarditis, a firm diagnosis may be made if the pericardial thickness is more than 3 mm by computed tomography or magnetic resonance imaging.²³ However, this feature may be absent in up to 25% of patients with constrictive pericarditis.¹⁹

Endomyocardial biopsy may be helpful when a specific cardiomyopathic process is detected. Nonspecific histopathologic findings favor the diagnosis of constrictive pericarditis. Sometimes both the pericardium and the myocardium may be involved in the disease process, as in sarcoidosis, and it may be quite difficult to determine the predominant pathophysiological process.²³

Surgical inspection. Despite all the diagnostic studies listed above, constrictive pericarditis may be a difficult diagnosis to confirm. Surgical inspection is the gold standard for the diagnosis and, in some patients, may be the only way to differentiate it from restrictive cardiomyopathy.²⁰

Treatment of constrictive pericarditis

The underlying cause should be sought and treated appropriately: eg, antituberculous chemotherapy for a patient with tuberculous

Surgery can cure constrictive pericarditis, but it carries a substantial risk with deterioration in NYHA class



chronic constrictive pericarditis. In addition:

Loop diuretics, used judiciously, can provide symptom relief of peripheral edema and ascites. However, because patients with constrictive pericarditis have impaired biventricular filling, excess diuresis increases the risk for hypotension and syncope.

Corticosteroids can sometimes relieve subacute cases of constrictive pericarditis.²³

Pericardial resection, first performed by Churchill in 1929, can cure constrictive pericarditis but carries substantial risk: the overall operative mortality rate is around 6%.⁶ Late mortality is estimated at 20% at 5 years and 40% at 10 years.²⁰

The mortality risk is directly proportional to the patient's New York Heart Association (NYHA) functional class, age, and a prior history of radiotherapy.^{18–20} Patients in NYHA class I or II have an operative mortality rate of approximately 1%, those in class III approximately 10%, and those in class IV up to 45%.

Patients operated on in the last decade are older than those in the previous era, and their constrictive pericarditis is often secondary to postmediastinal radiotherapy and cardiac surgery.²⁰

Pericardectomy provides excellent relief of symptoms in those who overcome the early mortality risk. However, in up to one third of patients who survive the surgery, new or recurrent NYHA class III or IV symptoms develop; in some, this may be due to incomplete surgical resection, pulmonary interstitial disease, or recurrence of primary or secondary neoplasms after chemotherapy.²⁰

Therefore, patients with stable symptoms and with NYHA class I or II function can be managed conservatively and surgery can be deferred. On the other hand, patients with progressive symptoms and late NYHA class II function should undergo surgery as soon as possible to reduce excessive early postoperative mortality risk from a low-output state.²⁰ The low-output syndrome is felt to result from inadequate decortication and progressive myocardial atrophy.¹⁹

Pericardial resection offers the hope of a cure for patients with constrictive pericarditis, especially for younger patients without postirradiation pericarditis or poor NYHA function. However, older, more debilitated patients may have a less favorable outcome. Cardiac transplantation may be a better alternative for some of these unfortunate patients.

REFERENCES

- PawSAT D, Lee JY, et al. Inflammatory disorders of the heart. *Emerg Med Clin North Am* 1998; 16:665–681.
- Olson TR. A.D.A.M. Student atlas of anatomy. Baltimore: Williams and Wilkins, 1996.
- Fukuda N, Oki T, Iuchi TA, et al. Pulmonary and systemic venous flow patterns assessed by transesophageal Doppler echocardiography in congenital absence of the pericardium. *Am J Cardiol* 1995; 75:1286–1288.
- Lorell BH. Pericarditis. In Braunwald E, editor. *Heart Disease*, 5th edition, W.B. Saunders, 1997:1478–1534.
- Marinella MA. Electrocardiographic manifestations and differential diagnosis of acute pericarditis. *Am Fam Physician* 1998; 57:699–704.
- Zayas R, Anguita M, Torres F, et al. Incidence of specific etiology and role of methods for specific etiologic diagnosis of primary acute pericarditis. *Am J Cardiol* 1995; 75:378–382.
- Sternbach GL. Pericarditis. *Ann Emerg Med* 1994; 17:214–220.
- Roberts WC. Primary and secondary neoplasms of the heart [editorial]. *Am J Cardiol* 1997; 80:671–682.
- Wang K, Hughes M. Detection of normal pericardium and of pericardial effusion in the lateral chest radiograph. *Circulation* 1996; 93:1254.
- Ilan Y, Oren R, Ben-Chetrit E. Acute pericarditis: etiology, treatment, and prognosis. A study of 115 patients. *Jpn Heart J* 1991; 32:315–321.
- Marcolongo R, Russo R, Leveder F, Noventa F, Agostini C. Immunosuppressive therapy prevents recurrent pericarditis. *J Am Coll Cardiol* 1995; 26:1276–1279.
- Adler Y, Finkelstein Y, Guindo J, et al. Colchicine treatment for recurrent pericarditis: A decade of experience. *Circulation* 1998; 97:2183–2185.
- Corey RG, Campbell PT, Van Trigt P, et al. Etiology of large pericardial effusions. *Am J Med* 1993; 95:209–213.
- Fowler NO. Cardiac tamponade: A clinical or an echocardiographic diagnosis? *Circulation* 1993; 87:1738–1741.
- Longo MJ, Jaffe CC. Images in clinical medicine. Electrical alternans. *N Engl J Med* 1999; 341:2060.
- Tsang TS, Freeman WK, Sinak LJ, Seward JB. Echocardiographically guided pericardiocentesis. Evolution and state-of-the-art technique. *Mayo Clin Proc* 1998; 73:647–652.
- Seward JB, Callahan JA, et al. 500 Consecutive echo-directed pericardiocenteses [abstract]. *J Am Coll Cardiol* 1992; 19(suppl):356A.
- Mehta A, Mehta M, Jain AC. Constrictive pericarditis. *Clin Cardiol* 1999; 22:334–344.
- Osterberg L, Vagellos R, Atwood JE. Case presentation and review: Constrictive pericarditis. *West J Med* 1998; 169:232–239.
- Lieng LH, Oh JK, Schaff HV, et al. Constrictive pericarditis in the modern era. *Circulation* 1999; 100:1380–1386.
- Benoff LJ, Schweitzer P. Radiation therapy-induced cardiac injury. *Am Heart J* 1995; 129:1193–1196.
- Trogrlic S, Gevenois PA, Schroeven M, De Vuyst P. Pericardial effusion associated with asbestos exposure. *Thorax* 1997; 52:1097–1098.
- Fowler NO. Constrictive pericarditis: Its history and current status. *Clin Cardiol* 1995; 18:341–350.
- Oh JK, Seward JB, Tajik AJ. *The echo manual: from the Mayo Clinic*. Boston: Little, Brown and Company, 1994.

ADDRESS: Sasan Ghaffari, MD, Department of Cardiology, F15, The Cleveland Clinic Foundation, 9500 Euclid Avenue, Cleveland, OH 44195; e-mail ghaffas@ccf.org.