



JEFFREY M. ROBBINS, DPM

Professor of Podiatric Medicine, Ohio College of Podiatric Medicine; Director of Podiatric Services, Veterans Affairs National Headquarters; Chief, Podiatry Section, Cleveland VA Medical Center

Recognizing, treating, and preventing common foot problems

■ ABSTRACT

The incidence, prevalence, and severity of foot conditions increase with age. Teaching patients simple preventive techniques is crucial. Recognition, treatment, and prevention of common foot complaints—ie, toenail problems, infections, corns and calluses, injuries, flat feet, bunions, arthritis of the toes, and toe and joint deformities—are reviewed.

P HYSICIANS NEED TO EDUCATE and encourage patients of all ages to take practical measures to prevent common foot problems. Once foot problems develop, physicians can apply treatments aimed at retarding the progression of the condition, relieving pain, and improving function. This paper reviews the signs and symptoms of the most common foot problems, prevention and treatment, and selection of footwear.

■ SCREENING FOR FOOT PROBLEMS

Examination of the feet to screen for disease precursors is important throughout the patient's life. The focus of the examination shifts depending on the age of the patient.

What to look for in all patients

Examine all patients for the following problems:

- Ingrown toe nails (onychocryptosis)

- Fungal disease of the nails and skin (tinea pedis)
- Fungal disease of the nails (onychomycosis)
- Plantar warts (verruca plantaris) and other viral skin lesions
- Excessive pronation (flat foot)
- Functional equinus (toe walking)
- Bunion deformity (hallux valgus)
- Lesser toe deformities (deformed and contracted toes with or without corns)
- Metatarsal deformities (prominent metatarsal heads with or without calluses).

Other problems to look for in adult and older patients

In addition to the above conditions, watch for the following conditions in adult and older patients:

- Interphalangeal joint inflammation and sublesional bursitis
- Metatarsal joint inflammation and sublesional capsulitis
- Diminished pedal pulses (dorsalis pedis, posterior tibial)
- Sensory neuropathy, evidenced by lack of "protection sensation" on the monofilament wire test.

Monofilament testing for sensory neuropathy

The 5.07 log (10-g) monofilament test is used to screen for sensory neuropathy in diabetic patients or other patients at risk. The tip of the monofilament is pressed against the skin until it bends (FIGURE 1). This applies 10 g of pressure to the skin and should normally be felt by the patient. The absence of feeling indicates

The patient's age dictates the focus of the foot examination



PATIENT INFORMATION

Keeping your feet healthy, page 57

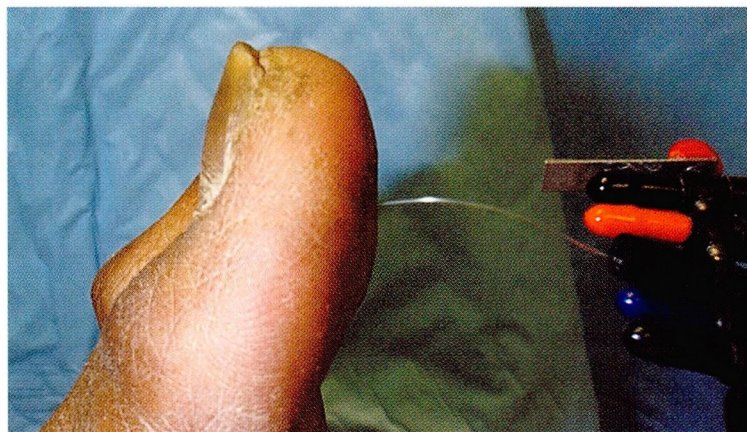

FIGURE 1. Monofilament testing. A monofilament is placed on the skin and pressed until it bends. If no pressure is felt, the limb has no protection sensation and the risk for ulceration and infection is increased.

that the patient has lost protection sensation and is therefore at risk for the development of limb-threatening ulceration and infection.

■ FUNGAL INFECTION OF TOENAILS

Fungal infection of the toe nails, or onychomycosis, is one of the most common foot conditions and is especially common in older patients (FIGURE 2). It results from the invasion of the nail and nail bed by a dermatophyte. The most common organisms causing onychomycosis are *Trichophyton rubrum*, *Trichophyton mentagrophytes*, and *Candida albicans*.

Signs of fungal infection include onycholysis (loosening or separation of all or part of the nail), hypertrophy, and discoloration (white, yellow, brown, or green), crumbling, and hyperkeratosis of subungual tissues.

Onychomycosis is classified according to the level of involvement.

- **Total dystrophic onychomycosis** affects the entire nail and nail bed
- **Distal subungual onychomycosis** affects the distal and sometimes lateral aspects of the nail and nail bed initially and often progresses to total dystrophic onychomycosis
- **Proximal subungual onychomycosis** affects the proximal nail fold and nail bed initially and progresses distally if untreated; this type is seen commonly in patients with HIV infection

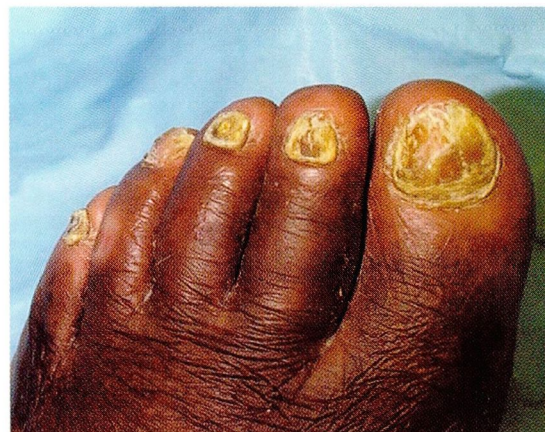

FIGURE 2. Onychomycosis. Control the infection, reduce painful nail thickness, and prevent secondary skin infections. Periodic debridement and regular use of topical antifungal creams and powders are recommended. If these are ineffective, consider oral antifungal agents and permanent surgical removal of the nail.

- **Superficial white onychomycosis** affects the superior aspect of the nail and may not affect the nail bed at all.

Treatment

Attempt to control the infection, reduce painful nail thickness, and prevent secondary skin infections. Periodic debridement and the use of topical antifungal creams and powders should accomplish this.

If this treatment is ineffective, try oral antifungal agents with or without permanent surgical removal of the nail. Oral agents such as terbinafine, fluconazole, itraconazole, and ketoconazole are now available to treat onychomycosis. Some of these agents can be given in pulsed doses to decrease the potential for side effects and adverse reactions.

■ INGROWN TOENAIL

Ingrown nails most frequently involve the hallux nails, although any nail can be affected. They can be caused by ill-fitting shoes, onychomycosis, familial incurvated nails, improper trimming, and other forms of trauma. The nail of the involved margin can lacerate the tissues in the nail groove, resulting in infection (paronychia). The ingrown nail causes

Control the infection, reduce painful nail thickness, prevent secondary infection

severe pain and discomfort and, as does a foreign body, requires excision.

Treatment

This condition is generally benign and is easily treated unless complicated by a systemic condition that places the patient at risk, eg, diabetes, peripheral vascular disease, immunodeficiency, neuropathy, or any other condition that interferes with wound healing.

Initial episodes are treated with partial temporary nail avulsion of the affected side with incision and drainage of paronychia or abscess. This must be followed up with patient education on proper nail cutting to avoid subsequent episodes.

In cases involving patients with a compromising condition such as diabetes or severe cellulitis, an antibiotic can be used in addition to removing the nail spicule. If the ingrown nail recurs despite proper nail cutting, permanent partial avulsion of the nail is recommended.

■ TINEA PEDIS

Fungal infection of the skin of the foot, or tinea pedis, is classified as acute or chronic (FIGURE 3). Signs and symptoms of acute tinea pedis may include one or more of the following: macerated web spaces, vesicles, bulla, and pruritus that can be severe at times. The causative organism is usually *Trichophyton mentagrophytes*. More severe cases can exhibit fissures in the web spaces and local erythema and cellulitis. When cellulitis is present, bacterial infection must be suspected.

Chronic tinea pedis is characterized by a moccasin-type distribution of scaling and dry skin. The web spaces may also be involved. The symptoms are generally not uncomfortable to the patient and may persist untreated for years. The causative organism is usually *Trichophyton rubrum*. Although this diagnosis is most often made clinically, potassium hydroxide slide preparation and culture help to confirm the diagnosis of tinea pedis.

Treatment

Treat acute tinea pedis with commonly available topical antifungal agents, as well as with local skin care consisting of warm saline soaks (except in diabetic and other compromised

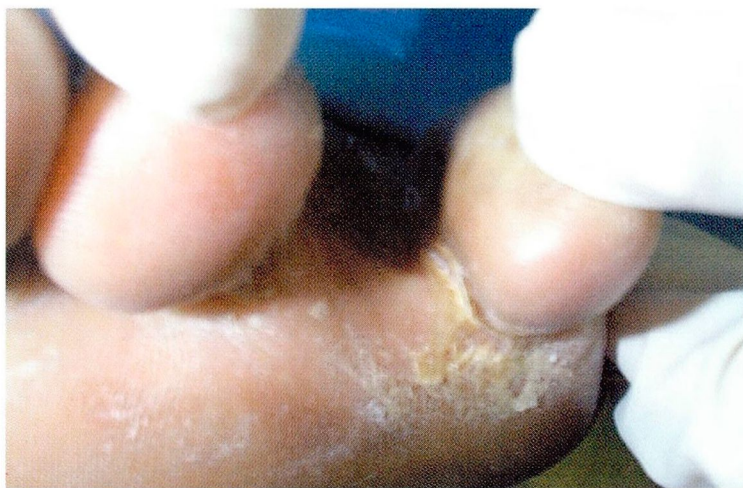

FIGURE 3. Acute tinea pedis. Treat with topical antifungal agents and warm saline soaks (except in diabetic and other compromised patients), and encourage proper foot hygiene. Oral antibiotics directed at staphylococcal and streptococcal organisms may be used in secondary infections. Treat chronic tinea pedis similarly but longer.

patients), proper foot hygiene, and avoidance of trauma that could result in secondary bacterial infection.

In acute vesicular or pustular tinea infection, a short course of an oral antifungal agent (eg, griseofulvin, terbinafine, fluconazole, itraconazole, ketoconazole) is indicated. If a secondary bacterial infection is suspected, an oral antibiotic directed at staphylococcal and streptococcal organisms is recommended.

In diabetic patients infections should always be suspected of being polymicrobial, and this should guide antibiotic selection.

Treat chronic tinea pedis similarly, but for a longer time. Following resolution, instruct the patient about measures to prevent recurrence: proper hygiene, daily use of antifungal foot powder, and disinfectant spray (eg, Lysol) to shoes at least once weekly.

■ DEFORMITIES

The biomechanical effects of years of walking on hard, flat, unyielding surfaces can combine with inherited foot structure or with years of wearing inappropriately tight or constricting footwear, or both—all of which can lead to a compensatory muscular imbalance that results in progressive deformity.

Infections in diabetic patients should be suspected of being polymicrobial

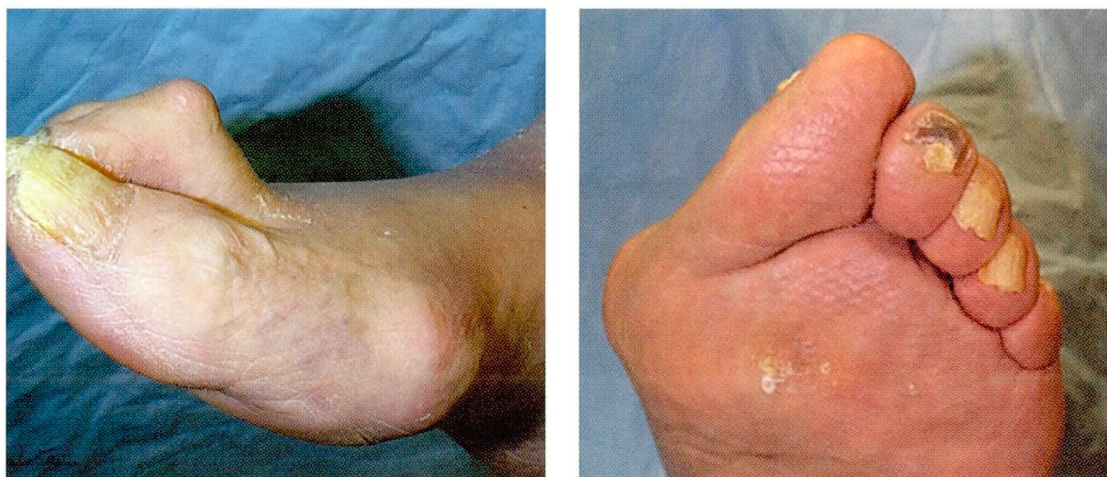

FIGURE 4. Hammer toe (left) and hallux valgus (right). Treat by protecting the foot, relieving pain, and improving function. Advise patients to consider extra-depth or custom-molded shoes, foot padding, foot taping, foot exercises, nonsteroidal anti-inflammatory drugs, intra-articular injections, physical therapy, or orthotics. Consider surgery only when these measures fail.

Hammer toe, claw toe, mallet toe

Three distinct types of so-called lesser deformity have been identified: hammer toe (**FIGURE 4**), claw toe, and mallet toe. Lesser toe deformities are progressive and can begin during early adolescence, but they most often become symptomatic only after the third decade of life.

Hammer toe involves extension of the proximal phalanx on the metatarsal head and flexion of the middle phalanx. The distal phalanx is neither extended nor flexed.

Claw toe differs from hammer toe in that the distal phalanx is also flexed.

Mallet toe appears straight, but the distal phalanx is flexed.

Hallux valgus or bunion

Hallux valgus (**FIGURE 4**) is a deformity of the first ray (hallux and first metatarsal) and can occur in the transverse, frontal, or sagittal plane. In the transverse plane, the hallux can deviate laterally, while the first metatarsal migrates medially. In the frontal plane the hallux can rotate. In the sagittal plane the first ray may be extended or flexed.

When the first metatarsal phalangeal joint becomes prominent, a bursal sac may develop medially, and this sac can become inflamed and painful. Arthritis in the first

metatarsal phalangeal joint can result in pain during movement, restricted range of motion, or joint fusion, making ambulation difficult because of pain.

Tailor's bunion (bunionette)

This condition involves the fifth ray, specifically medial migration of the fifth toe and lateral migration of the fifth metatarsal. The fifth metatarsal phalangeal joint is then subjected to the development of painful bursitis, joint arthritis, and loss of normal range of motion and function.

Treatment

Conservative therapy attempts to accommodate deformities, protect the foot, relieve pain, and improve function. Conservative measures include a change in footwear (eg, extra-depth shoes or custom-molded shoes), foot padding or taping or both, foot exercises, nonsteroidal anti-inflammatory drugs, intra-articular injections, physical therapy, and accommodative and biomechanical foot orthotic devices (rigid, semi-rigid, root type, UCBL [University of California-Berkeley laboratory] type).

Surgical intervention is considered only when conservative therapy fails to relieve pain, fails to improve function, or fails to prevent the progression of deformity.

Walking on hard, flat, unyielding surfaces leads to deformity, trauma, and infections

■ PLANTAR FASCIITIS

Plantar fasciitis is caused by repetitive mechanical trauma and is characterized by morning pain and stiffness of the heel and plantar fascia, which improves with weight-bearing after getting up in the morning and becomes progressively more painful by the end of the day. Returning to weight-bearing after short periods of rest during the day can cause the pain and stiffness to return. Although often mistakenly nicknamed "heel spur syndrome," several other causes have been suggested and include prolonged weight-bearing or walking on hard flat surfaces, abnormal pressure on the plantar fascia from such activities as ladder climbing, abnormal subtalar joint pronation, and excessive body weight.

Treatment

Conservative care is directed toward pain relief and control of the mechanical causes: daily stretching exercises, padding, taping, over-the-counter shoe inserts, ultrasound, electrical stimulation, NSAIDs, and biomechanical foot orthotic devices.

Steroid injections should be used with caution, as rupture of the plantar fascia has been reported.

Surgical intervention is considered only after all conservative therapy has failed to relieve symptoms or improve foot function.

■ NEUROMA

Shoes and abnormal biomechanics of the foot can lead to excessive irritation of the nerves of the foot, resulting in benign hypertrophy of the nerve, which can cause distal pain, burning, and tingling in the areas served by the involved nerve. The most commonly affected nerve is the intermetatarsal nerve in the third interspace, although any nerve subjected to chronic irritation can be affected.

Treatment

Treatment for neuroma consists of pain relief and reducing the size of the neuroma by decreasing trauma to the nerve. Conservative management for neuroma includes wider shoes, interlesional steroid injections, padding,

taping, NSAIDs, ultrasound, electrical stimulation, and biomechanical orthotic devices.

Surgical intervention is an option only after conservative therapy has failed to relieve symptoms.

■ HYPERKERATOSIS

Pressure and friction to the skin overlying osseous structures produce hyperkeratotic tissue as the body acts to protect itself. In time, the subcutaneous tissues develop an adventitious bursa, which act as an additional "buffer" to protect the underlying bone. As this condition progresses, local nerves can hypertrophy within both the soft tissues and the capsular structures, causing entrapments and painful ambulation. The presenting symptoms of most hyperkeratotic lesions are pain and discomfort. Hyperkeratotic tissue, by itself, is not painful. The underlying bursitis of neuroma or neuritis is responsible for the pain associated with hyperkeratotic lesions.

The most common types of hyperkeratosis are:

- Helomas—corns, usually found on the digits
- Tylomas—calluses, usually found under or over metatarsal heads or over other bony prominence
- Intractable plantar keratoma, a cone-shaped keratotic plug found within a tyloma.

Treatment

Treatment for hyperkeratotic conditions includes wider shoes that reduce pressure and friction on a bony prominence, periodic debridement, and accommodative or biomechanical orthosis. Foot orthotic devices can be especially helpful with plantar lesions, as they balance foot pressure on a bony prominence, whereas wider shoes are most beneficial for interdigital and lateral fifth toe heloma (corns).

Surgical intervention is considered only after all conservative therapy has failed.

■ PROMOTING LIFELONG PREVENTION

Prevention through foot hygiene and proper shoe selection should begin in the office of the pediatrician and continue throughout

Teaching older patients prevention is especially important



TABLE 1

Common foot problems in older patients

CONDITION	SIGNS, AND SYMPTOMS	PREVENTION	TREATMENT
Oncychomycosis	Thick, crumbling, discolored nails	Daily hygiene Antifungal foot powder Disinfect shoes	Regular debridement Topical agents to control infection Oral agents to resolve infection Surgical excision of nail and nail matrix
Onychocryptosis	Incurvated nail margin, may lacerate tissues causing infection (paronychia)	Proper, regular cutting of nails	Avulsion of nail margin Incision and drainage of paronychia, if present Permanent nail repair if problem recurs
Tinea pedis	Acute: macerated web space, vesicles, bulla, pruritis Chronic: moccasin-type distribution of scaling and dry skin	Daily hygiene Antifungal foot powder Disinfect shoes	Topical antifungal creams Topical antifungal powders Oral agents if severe (antibiotics for secondary infection)
Hammer toe, mallet toe, claw toe	Contracture of toe with or without hyperkeratosis and sublesional bursitis Pain, cramping, difficulty walking	Properly fitting shoes during growth and development Appropriate shoes for activity during adult life Biomechanical orthotic may prevent this development	Protective padding for sublesional bursitis Debridement of hyperkeratotic skin Extra-depth or custom-molded shoes Surgical repair
Hallux valgus	Prominent first metatarsal phalangeal joint, perhaps with inflamed, painful bursal sac medially	Same as for hammer toe	Extra-depth or custom-molded shoes Padding, taping Foot exercises NSAIDs, intra-articular injections Physical therapy Orthotics

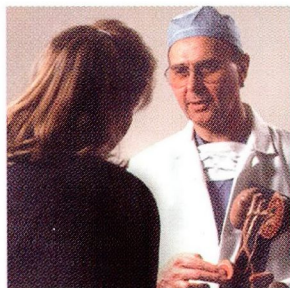
the patient's life, in the office of the internist and the geriatrician. Promoting good foot health and screening early for problems can reduce morbidity associated with foot problems. Teaching older patients prevention is especially important, because chronic conditions such as diabetes, peripheral vascular disease, and severe arthritis increase the risk for foot problems (TABLE 1). People over age 65 have more foot problems than the general population, except for infections and injuries,¹⁻¹⁰ and women tend to have more toenail problems, corns, calluses, bunions, arthritis of the toes, and toe and joint defor-

mities than men do.

On page 57 is a patient education page that you can copy and give to patients to educate them about proper foot hygiene.

■ SELECTING SHOES THAT FIT

In selecting shoes, comfort should come before fashion. Unfortunately, many of our patients have this backwards, usually out of concern about fashion trends. Advising patients about proper footwear is best done while keeping this psychosocial component in mind.





LET US HEAR FROM YOU

- Let us hear your opinions about the *Cleveland Clinic Journal of Medicine*.
- Do you like current articles and sections?
- What topics would you like to see covered and how can we make the Journal more useful to you?

PHONE 216.444.2661
FAX 216.444.9385
E-MAIL ccjm@ccf.org
WWW <http://www.ccjm.org>

CLEVELAND CLINIC JOURNAL OF MEDICINE
The Cleveland Clinic Foundation
9500 Euclid Avenue, NA32
Cleveland, Ohio 44195



DEDICATED TO LIFELONG LEARNING
**CLEVELAND
CLINIC
JOURNAL OF
MEDICINE**



Shoes do not, in and of themselves, cause foot problems, including deformities. Individual foot structure is the chief cause. Furthermore, the normal aging process can result in neuropathy, ischemia, immunopathy, and atrophy of the protective plantar fat pad. Improper footwear can exacerbate foot problems related to these processes, and to the chronic conditions mentioned above.

On page 57 is a patient education page that you can copy and give to patients whose foot problems you believe are caused or exacerbated by poor shoe selection.

REFERENCES

1. Greenberg L. Analysis of foot care data from the 1990 National Health Interview Survey, September 1992. HRSA 92-204 (P), Rockville, Maryland.
2. Robbins JM, editor. Primary podiatric medicine. Philadelphia: W.B. Saunders; 1994.
3. Helfand AE. Public health and podiatric medicine. Baltimore: Williams and Wilkins; 1987.
4. Robbins JM, editor. Clinics in podiatric medicine and surgery: peripheral vascular disease in the lower extremity. Philadelphia: W.B. Saunders; 1992.
5. Weber G, Cardile MA. Diabetic neuropathies. In: Weber G, editor. Clinics in podiatric medicine and surgery: neurologic disorders affecting the lower extremity II. Philadelphia: W.B. Saunders; 1990.
6. Joseph WS. Treatment of lower extremity infections in diabetics. J Am Podiatr Med Assoc 1992; 82: 361-370.
7. Joseph WS. Handbook of lower extremity infections. New York: Churchill Livingstone; 1990.
8. Fairbairn JF, Juergens JL, Spittell JA. Peripheral vascular disease. 5th ed. Philadelphia: W.B. Saunders; 1980.
9. Yale J. Yale's podiatric medicine. 3rd ed. Baltimore: Williams and Wilkins; 1987.
10. Levy L, Hetherington V, editors. Principles and practice of podiatric medicine. New York: Churchill Livingstone; 1990.

ADDRESS: Jeffrey M. Robbins, DPM, Cleveland VA Medical Center, 10701 East Boulevard, Cleveland, OH 44106, e-mail jefrey.robbs@med.va.gov.

CME ANSWERS



Answers to the credit test on page 71 of this issue

1 E 2 B 3 D 4 C 5 E 6 B 7 B 8 A 9 B 10 D
11 A 12 C

CORRECTION

The answer key to the CME Credit Test in the October 1999 issue contained a typographical error. The answer to question 3 should have been A (ibuprofen), not C (naproxen). We apologize for the error.