

**VASANT B. PATEL, MD**

Department of Cardiology, Cleveland Clinic

**ERIC J. TOPOL, MD**Chairman, Department of Cardiology,  
Cleveland Clinic; Principal Investigator,  
Global Utilization of Strategies to Open  
Occluded Coronary Arteries (GUSTO) trials

# The pathogenesis and spectrum of acute coronary syndromes: From plaque formation to thrombosis

## ■ ABSTRACT

Acute coronary syndromes occur when an unstable atherosclerotic plaque erodes or ruptures, exposing the highly thrombogenic material inside the plaque to the circulating blood and triggering rapid formation of a thrombus that occludes the artery. This understanding is leading to a wide variety of new therapies. It is hoped that further research into the pathogenesis of acute coronary syndromes will lead to more accurate markers of risk and more specific preventions and treatments.

## ■ KEY POINTS

In distinguishing among the acute coronary syndromes, cardiologists have come to rely less on creatine kinase elevations alone and more on the electrocardiographic findings and abnormal troponin levels.

Although for many years non-Q-wave MI was considered prognostically similar to unstable angina, evidence from recent studies suggests it is prognostically similar to Q-wave MI.

Plaque rupture may be the predominant trigger for thrombosis in men, and plaque erosion may be the more frequent causative factor in women.

The degree of vessel wall injury and the balance between activation of the coagulation system and endogenous fibrinolysis at the time of plaque disruption determine the clinical course in acute coronary insufficiency.

Markers of MI include elevations in creatine kinase, the CK-MB fraction, troponin I, troponin T, and myoglobin.

**O**UR UNDERSTANDING of acute coronary syndromes—from unstable angina to myocardial infarction (MI)—has been transformed in recent years. We now have a clearer understanding of how plaque forms, from the first subtle change in the arterial endothelium to a cascade of molecular changes involving white blood cells, smooth muscle cells, platelets, and a vast array of inflammatory molecules. Further, we now understand how vulnerable plaque is eroded or abruptly ruptures, leading to rapid formation of a thrombus and occlusion of the artery.

Although researchers have made tremendous progress in understanding acute coronary syndromes, which has already yielded novel, more effective therapies, we need to understand this process better. Acute coronary syndromes are still the leading cause of death in the Western world. Moreover, they often strike unpredictably: in many cases an artery that appears to be perfectly normal on angiography can become completely occluded in only a few months. In fact, two thirds of cases of acute coronary syndromes may arise from small plaques.<sup>1</sup>

This article discusses the classification of the acute coronary syndromes (unstable angina, non-Q-wave MI, and Q-wave MI), what is now known about their pathophysiology, and the impact of this new knowledge on their diagnosis and treatment.

## ■ WHAT ARE THE ACUTE CORONARY SYNDROMES?

The acute coronary syndromes—unstable angina, non-Q-wave MI, and Q-wave MI—



TABLE 1

### Braunwald classification system for unstable angina

#### Severity

- I Symptoms with exertion beginning in past 2 months
- II Symptoms at rest in the past month but not the past 48 hours
- III Symptoms at rest within the past 48 hours

#### Precipitant

- A Secondary (extrinsic conditions aggravating symptoms)
- B Primary (no contribution of extrinsic conditions)
- C Postinfarction (within 2 weeks of index MI)

#### Treatment during symptoms

- 1 No treatment
- 2 Usual angina treatment
- 3 Maximal treatment

SOURCE: BASED ON BRAUNWALD E. UNSTABLE ANGINA. A CLASSIFICATION. CIRCULATION 1989; 80:410-414

### Incipient lesions are present even in infants

are a continuum, all involving occlusion of a coronary artery. The difference is the degree and duration of the occlusion and the damage it causes. In unstable angina, occlusion is brief and no myocardial necrosis occurs. In non-Q-wave MI, blockage is more prolonged and necrosis occurs but does not extend to the full thickness of the myocardium. In Q-wave MI, necrosis extends through the full thickness of the myocardium.

In distinguishing among the acute coronary syndromes, cardiologists have come to rely less on creatine kinase elevations and more on the electrocardiographic findings (ST-segment elevation, ST-segment depression, or T-wave inversion)<sup>2,3</sup> and on more sensitive serum markers of myocardial necrosis (eg, the creatine kinase-MB fraction, troponin I, troponin T).<sup>4,5</sup> As a result, many patients who would have been diagnosed with unstable angina because they had no creatine kinase elevation are now known to have had MIs and to be at increased risk for future events.

#### Unstable angina

Unstable angina has a range of presentations. Initially, Braunwald<sup>6</sup> divided it into three classes according to its severity and clinical presentation (TABLE 1). In 1994, the National Heart, Lung, and Blood Institute (NHLBI)

practice guidelines<sup>7</sup> defined it as having three possible presentations:

- Angina at rest (usually lasting more than 20 minutes)
- Exertional angina of new onset (within 2 months) of at least class III in severity by the criteria of the Canadian Cardiovascular Society Classification (CCSC)
- Recent (within 2 months) worsening of angina as reflected by an increase in severity of at least one CCSC class to at least CCSC class III.<sup>7</sup>

Both classification systems are currently in use. Although the Braunwald system is quoted more often, the NHLBI system is easier to follow. Both have similar merit.

In addition, unstable angina can be classified as primary or secondary. **Primary unstable angina** results from progressive mechanical obstruction (ie, a nonocclusive thrombus) or dynamic obstruction (ie, vasoconstriction). In contrast, **secondary unstable angina** is due to increased myocardial oxygen demand caused by tachycardia in conjunction with coronary stenosis or chronic stable angina.<sup>8</sup>

In clinical terms, unstable angina implies symptoms of myocardial ischemia of new onset or a change from the usual pattern of chest pain, and it serves as a herald of infarction.

#### Non-Q-wave MI (ST-segment depression MI)

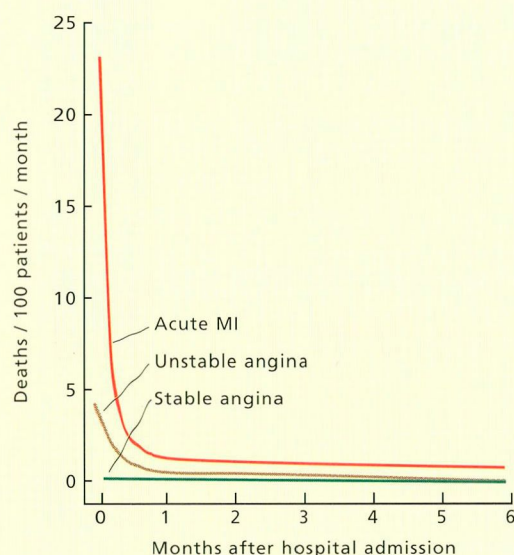
In ST-segment depression MI, commonly called non-Q-wave MI, there is objective evidence of myocardial necrosis. The clinical presentation is similar to that of unstable angina; however, the pain may last longer, with occlusion lasting up to an hour.<sup>9,10</sup> It can arise spontaneously or following procedures such as percutaneous coronary intervention or noncardiac surgery.

The diagnosis is based on the clinical presentation and on objective evidence such as the electrocardiographic findings and elevations in plasma levels of creatine kinase, the creatine kinase-MB fraction, troponin I, or troponin T.

Although for many years non-Q-wave MI was considered relatively benign, with a prognosis similar to that of unstable angina, evidence from recent studies suggests it is prognostically similar to Q-wave MI (FIGURE 1).<sup>7,11</sup>

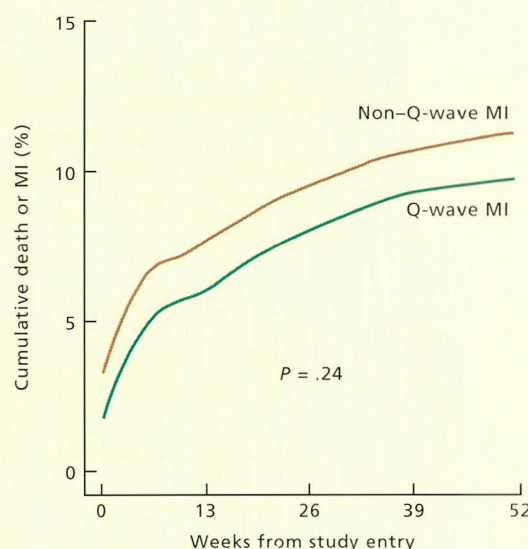


## Non-Q-wave myocardial infarction is not as benign as once thought



**FIGURE 1A.** Cumulative 6-month mortality from ischemic heart disease based on diagnosis on admission to hospital. Acute MI includes non-Q-wave and Q-wave MI.

SOURCE: REPRODUCED WITH PERMISSION FROM THEROUX P, FUSTER V. ACUTE CORONARY SYNDROMES: UNSTABLE ANGINA AND NON-Q-WAVE MYOCARDIAL INFARCTION. CIRCULATION 1998; 97:1195-1206.



**FIGURE 1B.** Cumulative 1-year death or MI in patients with non-Q-wave and Q-wave MI treated with fibrinolytic therapy.

SOURCE: REPRODUCED WITH PERMISSION FROM AGUIRRE FV, YOUNIS LT, CHAITMAN BR, ET AL. EARLY AND 1-YEAR CLINICAL OUTCOME OF PATIENTS' EVOLVING NON-Q-WAVE VERSUS Q-WAVE MYOCARDIAL INFARCTION AFTER THROMBOLYSIS. RESULTS FROM THE TIMI II STUDY. CIRCULATION 1995; 91:2541-2548.

### Q-wave MI (ST-segment elevation MI)

ST-segment elevation MI, often called Q-wave MI, refers to transmural myocardial necrosis due to total occlusion of a coronary vessel. In more than 80% of patients the occlusion lasts longer than 1 hour.<sup>10</sup>

On the electrocardiogram, ST-segment elevations appear rapidly with progression to Q-waves if rapid reperfusion fails to occur. This process can be curtailed if prompt therapy is given and complete reperfusion is established either by pharmacologic or catheter-based therapy.

### ATHEROSCLEROTIC LESIONS PROGRESS THROUGH STAGES

In a large series of autopsy studies, Stary<sup>12</sup> found that intimal thickening was present even in infants, and identified five types of lesions that were present in successively older

groups of patients, suggesting that these types represented stages of progression.

#### Type I: Endothelial damage

Atherosclerosis begins with functional alterations of endothelial cells without significant morphologic changes.<sup>12</sup> The endothelium becomes more "porous" and "sticky," allowing lipids to accumulate and monocytes to adhere to the intima.<sup>12,13</sup>

#### Type II: Fatty streak

As monocyte-derived macrophages release inflammatory products, smooth muscle cells migrate into the lesion and begin to proliferate, and a capsule begins to surround the lesion.

#### Type III: Preatheroma

With time, a lipid core forms in the musculo-elastic layer. Extracellular lipid droplets and



particles disrupt the coherence of some intimal smooth muscle cells.

#### Type IV: Atheroma

The lipid core enlarges and further disrupts the intimal smooth muscle cells. This is a cellular lesion with a great deal of extracellular lipid.

#### Type V: Fibroatheroma

A fibrous cap forms. The lesion now consists of a lipid core with thick layers of fibrous connective tissue or with a thin capsule that can be easily disrupted, leading to thrombus formation and more extensive smooth muscle cell proliferation.<sup>12</sup> If the thrombi are small, then they can become organized and contribute to the growth of the atherosclerotic plaque. When the thrombi are large, they can occlude the arterial lumen and lead to acute coronary syndromes.<sup>14</sup>

### ■ WHAT FACTORS TRIGGER AND PROMOTE ATHEROSCLEROSIS?

Plaques often develop at sites of high shear stress and high oscillation, such as the outer wall of a coronary bifurcation, the inner wall of a curved segment of an artery, and proximal to areas of myocardial bridging.<sup>15–17</sup> This observation suggests that the type I lesion is a result of chronic minimal injury to the endothelium mainly due to a disturbance in blood flow. Secondary factors such as smoking, hyperlipidemia, infection, and vasoactive amines potentiate the process.<sup>12,18</sup>

#### Is atherosclerosis an inflammatory process?

The role of inflammation and infection in acute coronary syndromes is currently being investigated. Studies in patients with unstable angina have shown systemic activation of inflammatory cells and the following changes:

- **Increased blood neutrophil elastase levels.**
- **Increased expression of adhesion molecules** such as CD11b/18, intercellular adhesion molecule-1, vascular cell adhesion molecule-1, endothelial selectin, and leukocyte selectin.
- **Increased acute-phase reactants** such as C-reactive protein and fibrinogen.<sup>19,20</sup> C-

reactive protein may prove to be a good clinical predictor for future adverse events in patients with acute coronary syndromes. C-reactive protein levels have been reported to be higher in patients with unstable angina and myocardial infarction than in those with stable angina.<sup>21</sup> Further, no increase in C-reactive protein was detected in patients with primary vasospastic angina or after percutaneous transluminal coronary angioplasty in stable patients. Also, patients with unstable angina and elevated levels of C-reactive protein before angioplasty exhibited a further striking increase in C-reactive protein levels peaking at 24 hours after the procedure.<sup>22,23</sup>

- **Endothelial activation.** Adhesion molecules can activate the endothelium, which is normally antiadhesive and anticoagulant, making it more adhesive and procoagulant. The activated endothelium subsequently can promote expression of genes important in the atherogenic process by means of transcription factors such as nuclear factor- $\kappa$ B and release mediators of smooth muscle hyperreactivity such as endothelin-1. Endothelin-1, expressed by the activated endothelium, is a potent vasoconstrictor and also potentiates the effects of other vasoconstrictors such as catecholamines, serotonin, and angiotensin II.<sup>24</sup>

- **Nuclear factor- $\kappa$ B activation.** Nuclear factor- $\kappa$ B normally resides in an inactive form, bound to the inhibitory protein I $\kappa$ B in the cytoplasm of lymphocytes, monocytes, endothelial cells, and smooth muscle cells. Once stimulated, nuclear factor- $\kappa$ B transcriptionally activates interleukins, interferons, tumor necrosis factor alpha, and adhesion molecules, hence promoting the ongoing process of rapid atherogenesis.<sup>25</sup> A recent study<sup>26</sup> reported that nuclear factor- $\kappa$ B was selectively and markedly activated in patients with unstable angina. Furthermore, available evidence suggests that expression of nuclear factor- $\kappa$ B in unstable angina is a causative factor rather than a casual association.<sup>25,26</sup> Therefore, nuclear factor- $\kappa$ B could also serve as a marker of coronary disease activity.

#### Does infection cause atherosclerosis?

Infections with organisms such as *Chlamydia pneumoniae*, *Helicobacter pylori*, and

**C-reactive protein is a predictor of future adverse events**



cytomegalovirus have been implicated as triggering or contributing to inflammation in acute coronary syndromes.<sup>26–29</sup> Specifically, high titers of antibodies to *C pneumoniae* have been shown in patients with symptomatic atherosclerotic coronary disease.<sup>30</sup> A recent study confirmed the association of increased *Chlamydia* titers in patients with acute coronary syndromes.<sup>31</sup> In addition, there was an independent association between increased *C pneumoniae* IgA antibody titers and fibrinogen levels (an acute-phase reactant), suggesting that infection was promoting inflammation.

The role of antibiotic therapy to prevent acute coronary syndromes remains unclear. In a clinical trial,<sup>32</sup> azithromycin therapy reduced the levels of inflammatory markers (C-reactive protein, interleukin 1, interleukin 6, and tumor necrosis factor alpha) at 6 months compared with placebo, but did not have any significant effect on clinical events.

## ■ THE DISRUPTION OF VULNERABLE PLAQUE

Acute coronary syndromes arise when a vulnerable plaque develops fissures or erosions or when it completely ruptures.<sup>33</sup> Vulnerable plaques commonly contain a lipid core in the intima and inflammatory cells at the site of disruption, which frequently occurs at the junction of the fibrous cap with the adjacent normal arterial wall.<sup>1,14,15</sup>

Although a variety of terms are used to describe plaque disruption (rupture, intimal fissures, tears, rents, and ulcers<sup>34</sup>), they are not all synonymous.

**Plaque fissure or erosion** refers to superficial ulceration of the endothelium covering the plaque and further erosion of a portion of the fibrous cap without exposure of the lipid core to the circulating blood.

**Plaque rupture** refers to a complete breach of the fibrous cap over a lipid core resulting in direct communication between the circulation and the lipid core.<sup>34,35</sup>

Angiographic and pathologic studies have demonstrated an association between primary plaque erosion or rupture and development of unstable angina.<sup>36,37</sup> Postmortem angiographic analysis of 166 patients whose death was

caused by coronary artery thrombosis demonstrated plaque rupture as the precipitating factor in 124 of the cases, while superficial erosion of the endothelium overlying the plaque accounted for the remaining 42 cases.<sup>38</sup> More recent studies suggest that plaque rupture may be the predominant trigger for thrombosis in men,<sup>39</sup> and erosion of the endothelium to be the more frequent causative factor in women.<sup>35</sup> The coronary vasa vasorum—tiny blood vessels within the artery wall itself—can also rupture and hemorrhage into the plaque, contributing to the process.

## Culprit lesions are often small

Remarkably, the lesions responsible for acute coronary syndromes are often small. Retrospective studies of angiograms performed before patients suffered acute coronary syndromes demonstrated that, before the acute event, the culprit lesion had been causing less than 50% stenosis in two thirds of cases.<sup>38,40</sup> In patients with acute MI who received fibrinolytic therapy, a considerable number had underlying lesions with less than 70% stenosis after fibrinolysis, even with residual thrombus partially occluding the lumen.<sup>41</sup>

## Degree of plaque disruption determines the clinical symptoms

The degree of plaque disruption influences the size of the thrombus that forms and hence the clinical symptoms.<sup>42</sup>

With superficial plaque erosion, a nonocclusive mural thrombus forms that in most cases does not cause a clinical event. However, in some cases, plaque erosion leads to a transiently occlusive thrombus or prolonged occlusion, resulting in acute ischemia or infarction. Furthermore, studies have shown that coronary stenoses of unstable angina are the result of repeated episodes of plaque ulceration and healing resulting in a gradual increase in plaque volume with incorporation and organization of mural thrombi.<sup>43,44</sup>

Postinfarction angina following pharmacologic or spontaneous thrombolysis can result from incomplete resolution of thrombus, the presence of a residual mural thrombus, or local vasoconstriction, increasing the likelihood of reocclusion.

**A study found high *Chlamydia* titers in patients with acute coronary syndromes**



In contrast, with deep plaque rupture, the lipid core with its highly thrombogenic atheromatous gruel is exposed, leading to platelet activation and often rapid thrombotic occlusion of an artery.

Other factors that influence the clinical presentation include the blood viscosity, platelet aggregability, distal vasoconstriction, and the balance between endogenous hemostatic and thrombolytic factors.

### What makes a plaque vulnerable to disruption?

Extrinsic factors such as emotional stress, physical activity, sympathetic overactivity, elevated diastolic blood pressure, blood flow shear stress, and circumferential wall stress might potentially trigger an acute event. However, factors intrinsic to the plaque itself make the plaque vulnerable in the first place. These include the consistency and contents of the atheromatous plaque, the thickness of the fibrous cap, and the balance between inflammation and the repair process of the fibrous cap.

#### Consistency and contents of the plaque.

Plaques that are prone to disruption are relatively soft, predominantly due to a high concentration of cholesteryl esters.

**Thickness of the fibrous cap.** Vulnerable plaques have thin fibrous caps and are often eccentric in shape.<sup>39</sup> The fibrous cap varies in thickness, strength, cellularity, and stiffness. The tensile strength and thickness of the fibrous cap depend on the interplay between smooth muscle cells, collagen synthesis, factors that inhibit collagen synthesis, matrix metalloproteinases, and macrophages (which produce inflammatory cytokines).

Accumulation of smooth muscle cells contributes prominently to plaque growth and fibrous cap formation.<sup>45</sup> Pathologic studies of rupture-prone plaques have shown a paucity of smooth muscle cells at the site of rupture.<sup>46</sup> Collagen, proteoglycan, and elastin are vital components of the plaque matrix, and smooth muscle cells are the source of these molecules. The relative paucity of smooth muscle cells may promote thinning of the fibrous cap by reducing collagen and other matrix proteins. The potential mechanisms that lead to paucity of smooth muscle cells in a plaque include

inhibition of smooth muscle cell replication by gamma interferon, and the process of apoptosis influenced by tumor necrosis factor alpha and interleukin-1.<sup>47,48</sup>

In addition, degradation of fibrillar collagen by proteolytic enzymes such as interstitial collagenase further weakens the fibrous cap. Collagenase, gelatinase, and stromelysin are metalloenzymes—enzymes of the matrix metalloproteinase family that require a zinc atom for their activity. Under normal circumstances, cells in human arteries have negligible amounts of active metalloenzymes. However, in vulnerable regions of human atherosclerotic plaques, these active proteolytic enzymes are highly expressed, leading to breakdown of fibrillar collagen in the fibrous cap.<sup>49</sup>

**Inflammation** appears to be an important component in the pathogenesis of acute coronary syndromes. Inflammatory molecules influence macrophages, endothelial cells, and smooth muscle cells, leading to weakening of plaque integrity (plaque rupture), release of procoagulant factors (thrombosis), and endothelial dysfunction (vasoconstriction).

Macrophages play a pivotal role in the rapid progression of an atherosclerotic plaque to result in acute coronary syndromes. An *in vivo* study revealed that plaques from patients with acute coronary syndromes had significantly more macrophages than those with stable angina.<sup>50</sup> A recent study demonstrated thermal heterogeneity (increased temperature) in rupture-prone plaques, possibly indicating heat released by activated macrophages and ongoing inflammation.<sup>51</sup>

Macrophages are activated by:

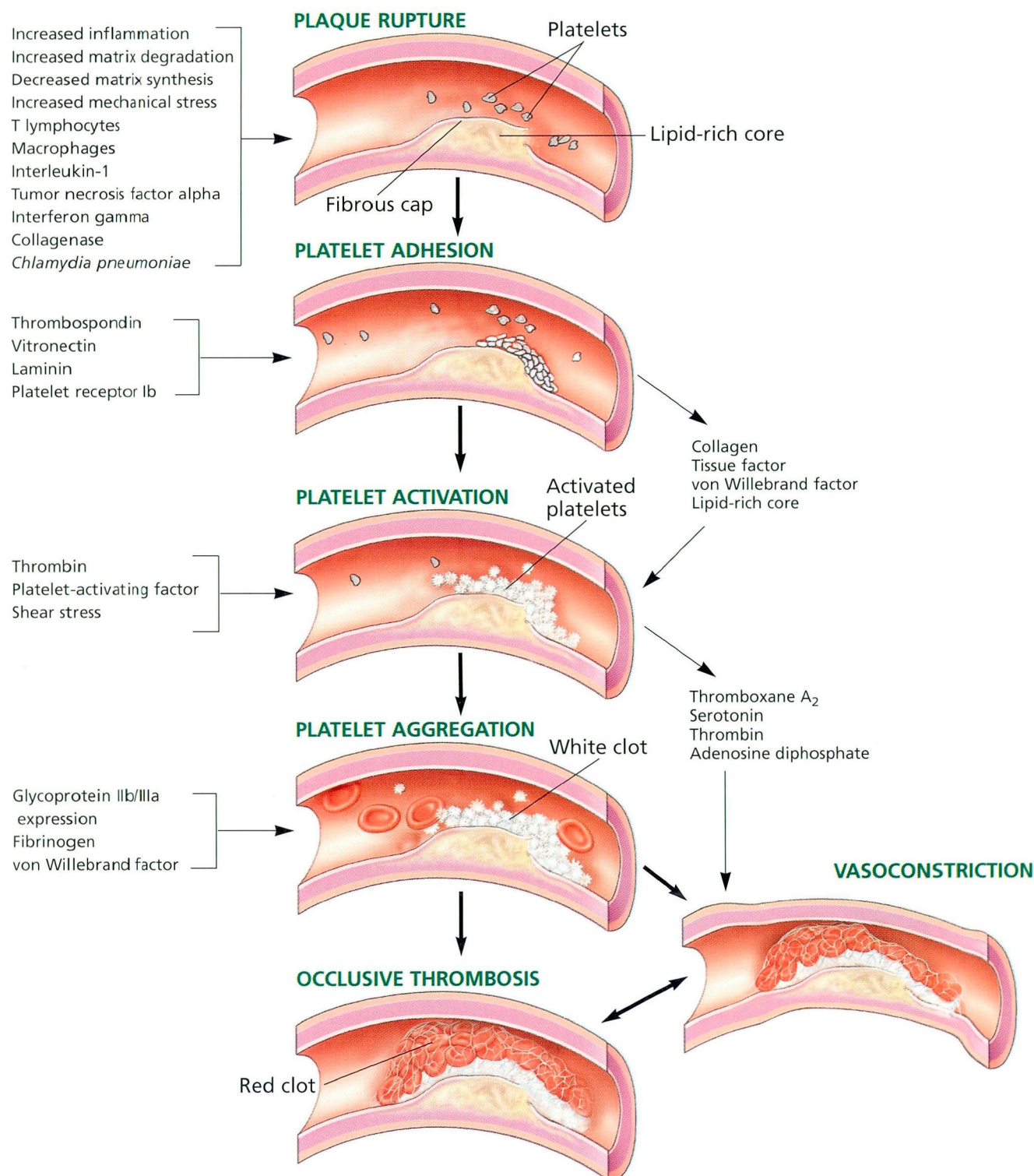
- Interferon gamma secreted by T lymphocytes
- CD40 ligand expressed on the surface of T lymphocytes
- Tumor necrosis factor alpha
- Macrophage-colony stimulating factor
- Macrophage chemoattractant protein-1.<sup>52</sup>

Activated macrophages weaken the fibrous cap by secreting matrix metalloproteinases, mitogenic factors such as platelet-derived growth factor, and toxic products of lipid oxidation.

**Plaques in acute coronary syndromes have more macrophages**



## How plaque rupture leads to coronary thrombosis



**FIGURE 2.** A schematic representation of the pathogenesis of acute coronary syndromes. Plaque rupture leads to a cascade of events resulting in coronary thrombosis.



## ■ THE CASCADE OF EVENTS IN THROMBUS FORMATION

Disruption of a plaque leads to formation of a thrombus through several steps, which transpire within a few minutes (FIGURE 2).

### Platelets adhere to the vessel wall

When platelets are exposed to components of the subendothelial matrix such as collagen, von Willebrand factor, and tissue factor, surface receptors on the platelets, primarily glycoprotein Ib, recognize these components, and the platelets adhere to the vessel wall, at first in a single layer.

### Platelets become activated

As the platelets adhere, they become activated and secrete from their alpha-granules various substances (eg, thromboxane A<sub>2</sub>, serotonin, thrombin, adenosine diphosphate, fibrinogen, platelet-activating factor, and platelet-derived growth factor) that lead to chemotaxis, vasoconstriction, and activation of other platelets.<sup>53,54</sup>

### Platelets aggregate and form a "white" clot

Activated platelets change shape and express glycoprotein IIb/IIIa surface receptors, which allow them to bind to one another and aggregate. The single layer of platelets recruits more platelets and grows into a platelet-rich "white" thrombus.<sup>55–57</sup> (Later, as the thrombus grows, red blood cells are recruited).

### Thrombin begets more thrombin

Platelet aggregation and other cofactors promote conversion of prothrombin to thrombin. In addition, tissue factor, released during plaque disruption, combines with coagulation factor VII, activating the extrinsic coagulation cascade to form more thrombin. Thrombin, in turn, is a potent agonist for further platelet activation and thus further promotes the process of thrombus formation.<sup>58</sup> It also mediates the conversion of fibrinogen to fibrin, which stabilizes the thrombus (FIGURE 3).

Several studies offer evidence that platelet activation, thrombin generation, and thrombosis take place in acute coronary syn-

dromes.<sup>55,57,59,60</sup> Fitzgerald et al<sup>60</sup> reported increased urinary levels of thromboxane B<sub>2</sub> in patients with anginal episodes, suggesting platelet activation. Merlini et al<sup>59</sup> demonstrated increased levels of prothrombin fragment 1+2 (suggesting increased activity of factor Xa and thrombin formation) and fibrinopeptide A (suggesting increased activity of thrombin and fibrin formation) during anginal episodes. Angiographic and angioscopic studies have confirmed the correlation between acute coronary syndromes and intracoronary thrombus.<sup>57,61</sup>

Protective mechanisms such as spontaneous lysis of thrombus (via endogenous tissue plasminogen activator) and vasorelaxation (via prostaglandin I<sub>2</sub> and nitric oxide) attempt to halt or reverse the procoagulant and vasoconstrictive mediators during acute coronary syndromes. The balance of these factors determines the clinical presentation and degree of myocardial injury.

## ■ THE ROLE OF VASOCONSTRICTION IN ISCHEMIA

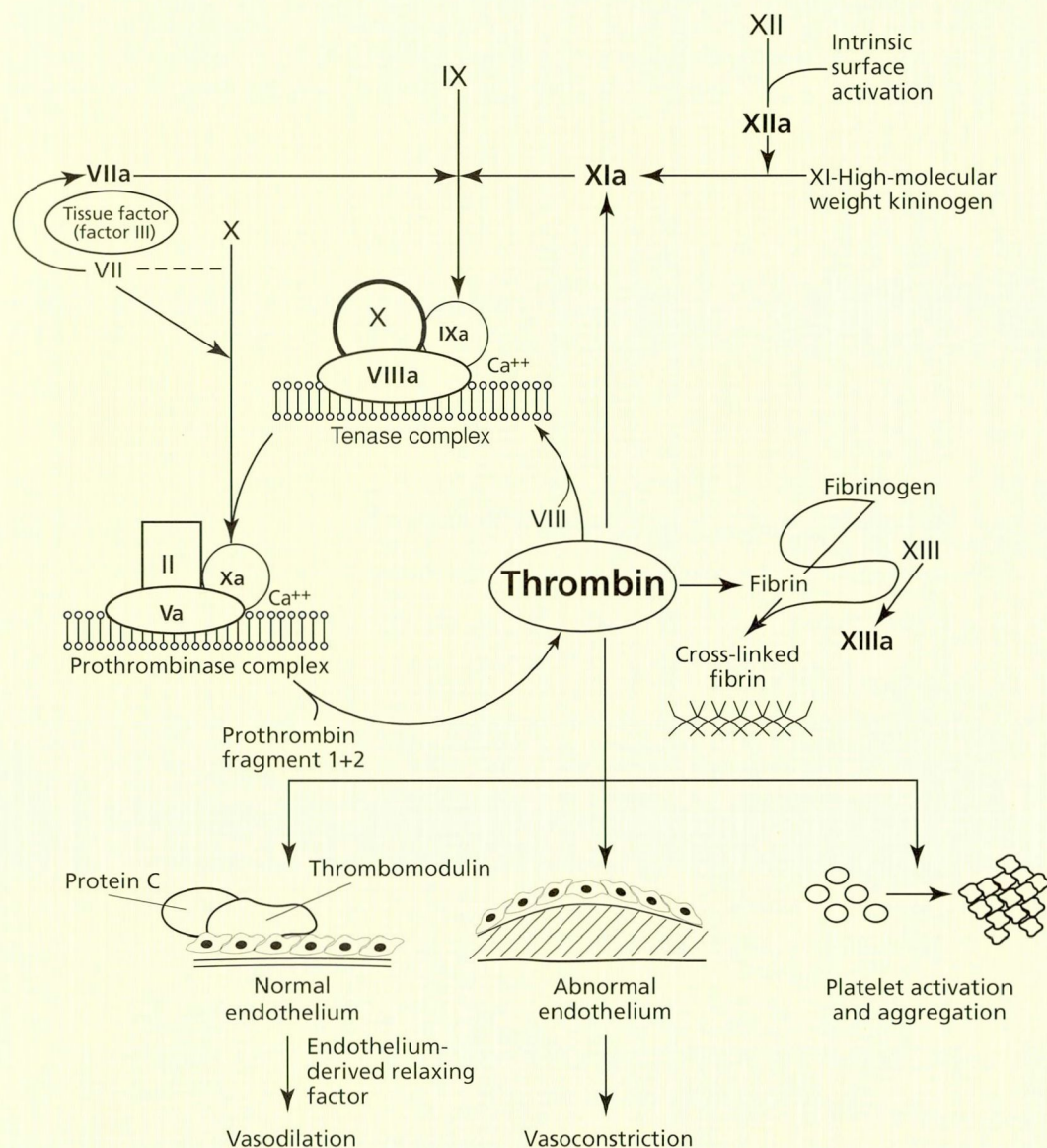
Coronary vasoconstriction also contributes to reducing coronary blood flow and causing ischemia.<sup>62</sup> In acute coronary syndromes, activated platelets release serotonin, thromboxane A<sub>2</sub>, adenosine diphosphate, and thrombin which, in addition to promoting thrombosis, are potent vasoconstrictors.<sup>54</sup> In addition, atherosclerosis and endothelial dysfunction further promote vasoconstriction, as evidenced by release of endothelin-1 and by paradoxical vasoconstriction upon administration of acetylcholine. Overall, the heightened vasomotor tone in acute coronary syndromes appears to depend on platelets and thrombin.<sup>63</sup> The degree and duration of vasoconstriction at or distal to the site of plaque disruption and thrombosis contribute to clinical symptoms of angina.

## ■ FUTURE TREATMENT POSSIBILITIES

Tremendous strides have been made thus far in understanding the pathogenesis of acute coronary syndromes. Inflammation, vascular injury, platelets, and thrombin play a crucial role. Various antiplatelet drugs (aspirin, clopi-

**Plaque rupture  
or erosion is  
the trigger for  
thrombosis**





**Thrombin plays a central role in coagulation**

**FIGURE 3.** Simplified diagram of the coagulation cascade and the central role of thrombin. In addition to converting fibrinogen to fibrin, thrombin plays a central role in platelet activation and endothelial function and indirectly autocatalyzes its own production.

SOURCE: ADAPTED WITH PERMISSION FROM MOLITERNO DJ. ANTICOAGULANTS AND THEIR USE IN ACUTE CORONARY SYNDROMES. IN: TOPOL EJ, EDITOR. TEXTBOOK OF INTERVENTIONAL CARDIOLOGY, 3RD ED. PHILADELPHIA, W.B. SAUNDERS, 1999:25-51.

dogrel, ticlopidine, and glycoprotein IIb/IIIa antagonists) and antithrombin drugs (unfractionated heparin, low molecular-weight heparin, and direct thrombin inhibitors) are already in clinical use.

Tissue factor contributes substantially to the thrombogenic potential of ruptured plaques, and therapy that inhibits coagulation higher up in the extrinsic pathway may limit thrombosis and the likelihood of a clinical



event after plaque rupture. Progress is being made in better understanding the role of inflammation, infection, cytokines, and gene promoters.

These new insights into the mechanism of plaque progression and plaque rupture will aid in more accurately identifying a vulnerable plaque using magnetic resonance imaging, thermal detection, and serum markers of inflammation. Advances in detecting vulner-

able plaques will allow physicians to use therapeutic strategies such as gene therapy to stabilize the plaque at risk for rupture using tissue inhibitors of matrix metalloproteinases, anti-sense strategies to inhibit proinflammatory molecules (nuclear factor- $\kappa$ B), and overexpression of nitric oxide synthase or prostacyclin synthase to ameliorate endothelial dysfunction and the associated procoagulant state.



## REFERENCES

- Falk E, Shah PK, Fuster V. Coronary plaque disruption. *Circulation* 1995; 92:657-671.
- Nyman I, Areskog M, Areskog NH, Swahn E, Wallentin L. Very early risk stratification by electrocardiogram at rest in men with suspected unstable coronary heart disease. The RISC Study Group. *J Intern Med* 1993; 234:293-301.
- Langer A, Freeman MR, Armstrong PW. ST segment shift in unstable angina: pathophysiology and association with coronary anatomy and hospital outcome. *J Am Coll Cardiol* 1989; 13:1495-1502.
- Ohman EM, Armstrong PW, Christenson RH, et al. Cardiac troponin T levels for risk stratification in acute myocardial ischemia. GUSTO IIA Investigators. *N Engl J Med* 1996; 335:1333-1341.
- Antman EM, Tanasijevic MJ, Thompson B, et al. Cardiac-specific troponin I levels to predict the risk of mortality in patients with acute coronary syndromes. *N Engl J Med* 1996; 335:1342-1349.
- Braunwald E. Unstable angina. A classification. *Circulation* 1989; 80:410-414.
- Braunwald E, Jones RH, Mark DB, et al. Diagnosing and managing unstable angina. Agency for Health Care Policy and Research. *Circulation* 1994; 90:613-622.
- Braunwald E. Unstable angina: an etiologic approach to management [editorial]. *Circulation* 1998; 98:2219-2222.
- Fuster V, Badimon L, Badimon JJ, Chesebro JH. The pathogenesis of coronary artery disease and the acute coronary syndromes (2). *N Engl J Med* 1992; 326:310-318.
- Fuster V, Badimon L, Badimon JJ, Chesebro JH. The pathogenesis of coronary artery disease and the acute coronary syndromes (1). *N Engl J Med* 1992; 326:242-250.
- Aguirre FV, Younis LT, Chaitman BR, et al. Early and 1-year clinical outcome of patients' evolving non-Q-wave versus Q-wave myocardial infarction after thrombolysis. Results from The TIMI II Study. *Circulation* 1995; 91:2541-2548.
- Stary HC. Evolution and progression of atherosclerotic lesions in coronary arteries of children and young adults. *Arteriosclerosis* 1989; 9:119-132.
- Ross R. The pathogenesis of atherosclerosis—an update. *N Engl J Med* 1986; 314:488-500.
- Fuster V, Stein B, Ambrose JA, Badimon L, Badimon JJ, Chesebro JH. Atherosclerotic plaque rupture and thrombosis. Evolving concepts. *Circulation* 1990; 82:1147-1159.
- Richardson PD, Davies MJ, Born GV. Influence of plaque configuration and stress distribution on fissuring of coronary atherosclerotic plaques. *Lancet* 1989; 2:941-944.
- Kimura BJ, Russo RJ, Bhargava V, McDaniel MB, Peterson KL, DeMaria AN. Atheroma morphology and distribution in proximal left anterior descending coronary artery: in vivo observations. *J Am Coll Cardiol* 1996; 27:825-831.
- Asakura T, Karino T. Flow patterns and spatial distribution of atherosclerotic lesions in human coronary arteries. *Circ Res* 1990; 66:1045-1066.
- Ip JH, Fuster V, Badimon L, Badimon J, Taubman MB, Chesebro JH. Syndromes of accelerated atherosclerosis: role of vascular injury and smooth muscle cell proliferation. *J Am Coll Cardiol* 1990; 15:1667-1687.
- Crea F, Biasucci LM, Buffon A, et al. Role of inflammation in the pathogenesis of unstable coronary artery disease. *Am J Cardiol* 1997; 80:10E-16E.
- Ghaisas NK, Shahi CN, Foley B, et al. Elevated levels of circulating soluble adhesion molecules in peripheral blood of patients with unstable angina. *Am J Cardiol* 1997; 80:617-619.
- Berk BC, Weintraub WS, Alexander RW. Elevation of C-reactive protein in "active" coronary artery disease. *Am J Cardiol* 1990; 65:168-172.
- Liuzzo G, Biasucci LM, Gallimore JR, et al. The prognostic value of C-reactive protein and serum amyloid A protein in severe unstable angina. *N Engl J Med* 1994; 331:417-424.
- Liuzzo G, Biasucci LM, Rebuzzi AG, et al. Plasma protein acute-phase response in unstable angina is not induced by ischemic injury. *Circulation* 1996; 94:2373-2380.
- Stewart DJ. Impact of endothelin-1 on vascular structure and function. *Am J Cardiol* 1998; 82:145-165.
- Barnes PJ, Karin M. Nuclear factor- $\kappa$ B: a pivotal transcription factor in chronic inflammatory diseases. *N Engl J Med* 1997; 336:1066-1071.
- Ritchie ME. Nuclear factor- $\kappa$ B is selectively and markedly activated in humans with unstable angina pectoris. *Circulation* 1998; 98:1707-1713.
- Speir E, Yu ZX, Ferrans VJ. Infectious agents in coronary artery disease: viral infection, aspirin, and gene expression in human coronary smooth muscle cells. *Rev Port Cardiol* 1998; 17 Suppl 2:1133-1139.
- Gurfinkel E, Bozovich G. Chlamydia pneumoniae: inflammation and instability of the atherosclerotic plaque. *Atherosclerosis* 1998; 140 Suppl 1:S31-S35.
- Ossei-Gerning N, Moayyedi P, Smith S, et al. *Helicobacter pylori* infection is related to atheroma in patients undergoing coronary angiography. *Cardiovasc Res* 1997; 35:120-124.
- Muhlestein JB, Hammond EH, Carlquist JF, et al. Increased incidence of *Chlamydia* species within the coronary arteries of patients with symptomatic atherosclerotic versus other forms of cardiovascular disease. *J Am Coll Cardiol* 1996; 27:1555-1561.
- Toss H, Gnarp J, Gnarp H, Siegbahn A, Lindahl B, Wallentin L. Increased fibrinogen levels are associated with persistent *Chlamydia pneumoniae* infection in unstable coronary artery disease. *Eur Heart J* 1998; 19:570-577.
- Anderson JL, Muhlestein JB, Carlquist J, et al. Randomized secondary prevention trial of azithromycin in patients with coronary artery disease and serological evidence for *Chlamydia pneumoniae* infection: The Azithromycin in Coronary Artery Disease: Elimination of Myocardial Infection with *Chlamydia* (ACADEMIC) study.

Someday, we may be able to detect and treat vulnerable lesions





- Circulation 1999; 99:1540–1547.
33. **Davies MJ, Thomas AC.** Plaque fissuring—the cause of acute myocardial infarction, sudden ischaemic death, and crescendo angina. *Br Heart J* 1985; 53:363–373.
  34. **Falk E.** Morphologic features of unstable atherothrombotic plaques underlying acute coronary syndromes. *Am J Cardiol* 1989; 63:114E–120E.
  35. **Farb A, Burke AP, Tang AL, et al.** Coronary plaque erosion without rupture into a lipid core. A frequent cause of coronary thrombosis in sudden coronary death. *Circulation* 1996; 93:1354–1363.
  36. **Barger AC, Beeuwkes RD.** Rupture of coronary vasa vasorum as a trigger of acute myocardial infarction. *Am J Cardiol* 1990; 66:41G–43G.
  37. **Ambrose JA, Tannenbaum MA, Alexopoulos D, et al.** Angiographic progression of coronary artery disease and the development of myocardial infarction. *J Am Coll Cardiol* 1988; 12:56–62.
  38. **Davies MJ.** A macro and micro view of coronary vascular insult in ischemic heart disease. *Circulation* 1990; 82:1138–1146.
  39. **Burke AP, Farb A, Malcom GT, Liang YH, Smialek J, Virmani R.** Coronary risk factors and plaque morphology in men with coronary disease who died suddenly. *N Engl J Med* 1997; 336:1276–1282.
  40. **Little WC.** Angiographic assessment of the culprit coronary artery lesion before acute myocardial infarction. *Am J Cardiol* 1990; 66:44G–47G.
  41. **Kereiakes DJ, Topol EJ, George BS, et al.** Myocardial infarction with minimal coronary atherosclerosis in the era of thrombolytic reperfusion. The Thrombolysis and Angioplasty in Myocardial Infarction (TAMI) Study Group. *J Am Coll Cardiol* 1991; 17:304–312.
  42. **Fuster V, Lewis A.** Conner Memorial Lecture. Mechanisms leading to myocardial infarction: insights from studies of vascular biology. *Circulation* 1994; 90:2126–2146.
  43. **Moise A, Theroux P, Teymans Y, et al.** Unstable angina and progression of coronary atherosclerosis. *N Engl J Med* 1983; 309:685–689.
  44. **Falk E.** Unstable angina with fatal outcome: dynamic coronary thrombosis leading to infarction and/or sudden death. Autopsy evidence of recurrent mural thrombosis with peripheral embolization culminating in total vascular occlusion. *Circulation* 1985; 71:699–708.
  45. **Gordon D, Schwartz SM.** Replication of arterial smooth muscle cells in hypertension and atherosclerosis. *Am J Cardiol* 1987; 59:44A–48A.
  46. **van der Wal AC, Becker AE, van der Loos CM, Das PK.** Site of intimal rupture or erosion of thrombotic coronary atherosclerotic plaques is characterized by an inflammatory process irrespective of the dominant plaque morphology. *Circulation* 1994; 89:36–44.
  47. **Hansson GK, Jonasson L, Holm J, Clowes MM, Clowes AW.** Gamma-interferon regulates vascular smooth muscle proliferation and Ia antigen expression in vivo and in vitro. *Circ Res* 1988; 63:712–719.
  48. **Geng YJ, Wu Q, Muszynski M, Hansson GK, Libby P.** Apoptosis of vascular smooth muscle cells induced by in vitro stimulation with interferon-gamma, tumor necrosis factor-alpha, and interleukin-1 beta. *Arterioscler Thromb Vasc Biol* 1996; 16:19–27.
  49. **Galis ZS, Sukhova GK, Lark MW, Libby P.** Increased expression of matrix metalloproteinases and matrix degrading activity in vulnerable regions of human atherosclerotic plaques. *J Clin Invest* 1994; 94:2493–2503.
  50. **Moreno PR, Falk E, Palacios IF, Newell JB, Fuster V, Fallon JT.** Macrophage infiltration in acute coronary syndromes. Implications for plaque rupture. *Circulation* 1994; 90:775–778.
  51. **Casscells W, Hathorn B, David M, et al.** Thermal detection of cellular infiltrates in living atherosclerotic plaques: possible implications for plaque rupture and thrombosis. *Lancet* 1996; 347:1447–1451.
  52. **Libby P.** Molecular bases of the acute coronary syndromes. *Circulation* 1995; 91:2844–2850.
  53. **Fuster V.** Mechanisms of arterial thrombosis: foundation for therapy. *Am Heart J* 1998; 135:S361–S366.
  54. **Willerson JT, Golino P, Eidt J, Campbell WB, Buja LM.** Specific platelet mediators and unstable coronary artery lesions. Experimental evidence and potential clinical implications. *Circulation* 1989; 80:198–205.
  55. **Mizuno K, Arakawa K, Isojima K, et al.** Angioscopy, coronary thrombi and acute coronary syndromes. *Biomed Pharmacother* 1993; 47:187–191.
  56. **Sherman CT, Litvack F, Grundfest W, et al.** Coronary angiography in patients with unstable angina pectoris. *N Engl J Med* 1986; 315:913–919.
  57. **Van Belle E, Lablanche JM, Bauters C, Renaud N, McFadden EP, Bertrand ME.** Coronary angiographic findings in the infarct-related vessel within 1 month of acute myocardial infarction: natural history and the effect of thrombolysis. *Circulation* 1998; 97:26–33.
  58. **Ruggeri ZM.** Mechanisms initiating platelet thrombus formation. *Thromb Haemost* 1997; 78:611–616.
  59. **Merlini PA, Bauer KA, Oltrona L, et al.** Persistent activation of coagulation mechanism in unstable angina and myocardial infarction. *Circulation* 1994; 90:61–68.
  60. **Fitzgerald DJ, Roy L, Catella F, Fitzgerald GA.** Platelet activation in unstable coronary disease. *N Engl J Med* 1986; 315:983–989.
  61. **Freeman MR, Williams AE, Chisholm RJ, Armstrong PW.** Intracoronary thrombus and complex morphology in unstable angina. Relation to timing of angiography and in-hospital cardiac events. *Circulation* 1989; 80:17–23.
  62. **Maseri A, L'Abbate A, Baroldi G, et al.** Coronary vasospasm as a possible cause of myocardial infarction. A conclusion derived from the study of "preinfarction" angina. *N Engl J Med* 1978; 299:1271–1277.
  63. **Bogaty P, Hackett D, Davies G, Maseri A.** Vasoreactivity of the culprit lesion in unstable angina. *Circulation* 1994; 90:5–11.
- ADDRESS:** Eric J. Topol, MD, Chairman, Department of Cardiology, F25, The Cleveland Clinic Foundation, 9500 Euclid Avenue, Cleveland, OH 44195, e-mail [topole@ccf.org](mailto:topole@ccf.org).

**Coming in  
November**

**Aspirin, ticlopidine, and clopidogrel  
in acute coronary syndromes**  
Walter A. Tan, MD and David J. Moliterno, MD