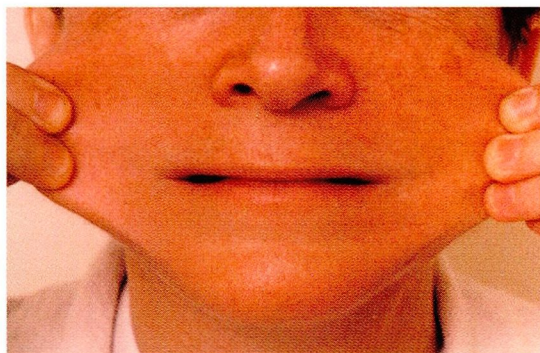
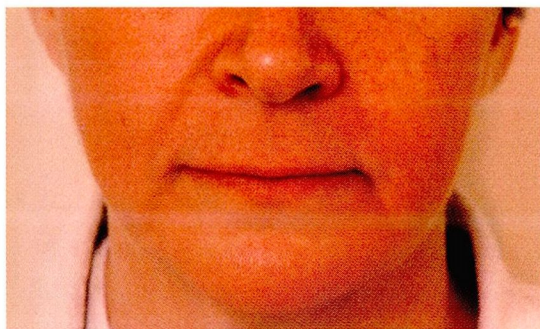
**ALBERTO S. SANTOS-OCAMPO, MD**Department of Rheumatic and Immunologic Diseases,  
Cleveland Clinic**GARY S. HOFFMAN, MD**Chairman, Department of Rheumatic and Immunologic  
Diseases, Cleveland Clinic

# Aneurysms and hypermobility in a 45-year-old woman

**A** 45-YEAR-OLD, previously healthy woman was referred to the Cleveland Clinic for evaluation of multiple visceral aneurysms. In March 1997, evaluation of progressive left upper quadrant pain led to arteriographic demonstration of a splenic artery aneurysm. Splenectomy was accomplished without complications. Angiography of mesenteric vessels revealed an asymptomatic hepatic artery aneurysm that was successfully embolized with Gelfoam. Magnetic resonance imaging and magnetic resonance angiography of her brain showed no intracranial aneurysms. At the time of consultation at the Cleveland Clinic she was asymptomatic.



**FIGURE 1.** Demonstration of skin hyperextensibility of the face in this patient.

She reported a history of being “double-jointed,” in the absence of dislocations, hernias, or difficulty with wound healing. She had three normal term pregnancies. Each birth was a spontaneous vaginal delivery. A sister had similar hypermobilities, and her mother (still living) has had “arthritis” since her 40s.

Physical examination showed the woman to be in good health, with mildly hyperextensible skin affecting the face (**FIGURE 1**) and areas over bony prominences. She had no delicate, thin, abnormal scars. She was able to touch the tip of her nose with her tongue (positive Gorlin sign), and she had symmetric hyperextensibility of both large and small joints that was most notable in the distal and proximal interphalangeal joints of both hands (**FIGURE 2**). Cardiovascular and peripheral vascular examinations were normal. An echocardiogram showed normal valvular anatomy.

## ■ WHAT IS THE DIAGNOSIS?

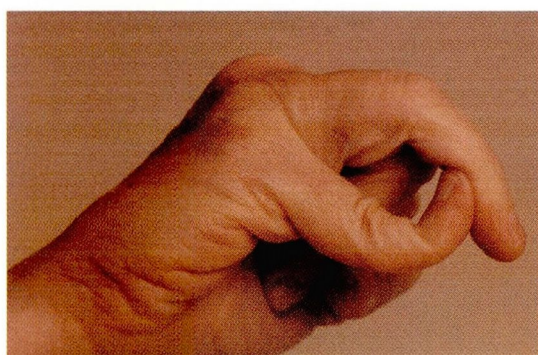
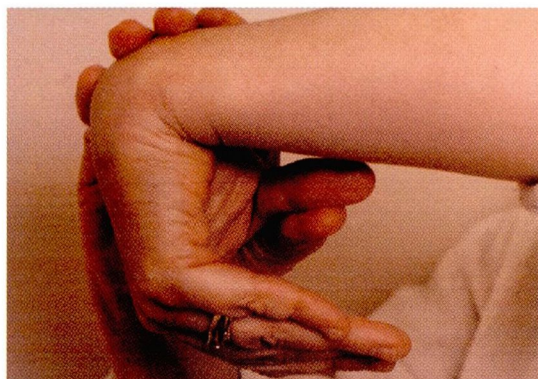**1** Given the patient’s symptoms and history, which of the following diagnoses was made?

- ☐ Marfan syndrome
- ☐ Ehlers-Danlos syndrome (EDS)
- ☐ Familial articular hypermobility syndrome
- ☐ Systemic vasculitis

A diagnosis of EDS type IV was made on the basis of joint hypermobility, hyperextensible skin, and multiple visceral aneurysms. Gorlin sign, which is found in only 10% of normal subjects, is reportedly present in 50% of EDS patients.<sup>1</sup> Examination of the patient’s three sons (ages 9, 16, and 17) revealed that each had features of joint hypermobility.

This patient did not have a marfanoid





**FIGURE 2.** Demonstration of small joint hypermobility. Top, thumb apposition to flexor aspect of forearm. Bottom, hyperextension of the distal interphalangeal joint of the fifth finger.

habitus. Although cardiovascular complications are common in Marfan syndrome, these typically involve the mitral valve and aorta. Skin and vascular complications are not typical of the familial articular hypermobility syndrome. The absence of constitutional symptoms and laboratory or target-organ abnormalities argues against a systemic vasculitis.

The etiologic differential diagnosis of multiple visceral aneurysms has been addressed by the International Society for Cardiovascular Surgery (TABLE 1).<sup>2</sup> Diagnostic criteria for joint hypermobility are summarized in TABLE 2.

This case illustrates the most common presentation of EDS type IV, ie, a vascular, gastrointestinal, or obstetric complication.<sup>3–14</sup> Fortunately, this patient had a mild form of EDS type IV and did not experience severe visceral or vascular morbidity or mortality. Laparotomy and angiography were uncomplicated. The degree of joint hypermobility noted at presentation was said to be consider-

**TABLE 1**

### Etiologic classification of arterial aneurysms

#### Congenital (developmental)

Ehlers-Danlos syndrome  
Marfan syndrome

#### Mechanical (hemodynamic)

Poststenotic, arteriovenous fistula-associated  
Traumatic (blunt or penetrating)

#### Inflammatory (noninfectious)

Takayasu disease  
Behçet disease  
Kawasaki disease  
Microvascular disorders (ie, polyarteritis)  
Periarterial inflammatory disease (ie, pancreatitis)

#### Infectious

Bacterial, fungal, spirochetal

#### Degenerative

Nonspecific (commonly considered arteriosclerotic)  
Dysplastic

#### Surgical (anastomotic)

Postarteriotomy (refers to postsurgical "anastomotic aneurysms," ie, those secondary to infections, arterial wall failures, suture failures, graft failures, or failure from unknown causes)

SOURCE: FROM JOHNSTON KW, RUTHERFORD RB, TILSON MD, ET AL. SUGGESTED STANDARDS FOR REPORTING ON ARTERIAL ANEURYSMS. J VASC SURG 1991; 13:452–458, WITH PERMISSION.

ably less than during her childhood. This reflects the natural decrease in joint laxity seen with age.<sup>15</sup> The history and findings of joint hypermobility in the patient's mother, sister, and children reinforce the familial nature of EDS and its variable degrees of expression.

### ■ WHAT ARE THE EHLERS-DANLOS SYNDROMES?

#### 2 Which of the following statements is true?

- ☐ The Ehlers-Danlos syndromes are characterized by an inherited quantitative or qualitative defect in collagen synthesis
- ☐ Skin hyperelasticity, bruising, and joint hypermobility are the principal symptoms in most subtypes of EDS

**The patient's sister and children had similar joint hypermobility**



**TABLE 2****A clinical test for joint hypermobility****Scoring**

A score of 0 or 1 is assigned to each criterion, with 1 point each for the right and left side in the first four criteria. The highest possible score is 9. A score of 5 indicates hypermobility.

**Criteria**

Passive dorsiflexion of the fifth finger beyond 90 degrees at the metacarpophalangeal joint with the forearm flat on the examining table

Passive apposition of the thumb to the flexor aspect of the forearm

Hyperextension of the elbow beyond 10 degrees

Hyperextension of the knee beyond 10 degrees

Forward flexion of the trunk so that the palms of the hands rest easily on the floor

- ☐ The most severe subtype of EDS is the vascular form, EDS type IV
- ☐ All of the above

All are true. EDS, which has at least nine variants, is a remarkably heterogeneous group of connective tissue disorders. The different types have in common abnormalities of collagen, including defects in collagen synthesis, secretion, or posttranslational modification.<sup>4,14-30</sup>

EDS is among the most common heritable disorders of connective tissue. For all phenotypes, prevalence has been estimated to range from 1 per 50,000 to 1 per 500,000.<sup>3,4,14,18,31</sup> The Berlin classification includes nine types of EDS (**TABLE 3**). Types I and II each account for 40% of all cases of EDS. Type III is the third most common, accounting for 10%.

Although 90% of all EDS patients demonstrate principal abnormalities of skin and joint hypermobility (types I, II, and III in the Berlin classification) and have fairly benign prognoses,<sup>15,21</sup> approximately 4% of patients have the potentially catastrophic vas-

cular type of EDS (type IV).<sup>3,15,21</sup> These patients often experience severe vascular, intracranial, gastrointestinal, and obstetric complications (**TABLE 4**).<sup>3,15</sup>

### ■ WHAT ARE THE CLINICAL MANIFESTATIONS OF EDS TYPE IV?

**3** Which of the following findings are characteristic of EDS type IV?

- ☐ Small joint hypermobility
- ☐ Minimal or absent skin hyperextensibility
- ☐ Aneurysms of the small, medium, and large arteries
- ☐ All of the above

All of the above are true. Classical stigmata of EDS type IV include joint hypermobility often limited to the digits; minimal or absent skin hyperextensibility; thin, pale skin with a prominent venous network; and deeply pigmented scars.<sup>15</sup> However, phenotypes are variable and may resemble other forms of EDS, eg, type I or type VIII. Skin manifestations may range from normal-appearing skin to the more typical acrogeric form characterized by large eyes, peaked nose, and premature aging of the hands.<sup>15,20,24,26</sup> In children, signs and symptoms include low birth weight, prematurity (as a result of maternal EDS type IV), congenital hip dislocations, and inappropriate bruising, which may lead to suspicions of battery and child abuse.<sup>26</sup>

Patients with EDS type IV are generally short. "Classical" or "acrogeric" facies refers to large eyes, thin nose, lobeless ears, and small lips. This hollowed-out, cachectic appearance results in part from diminished subcutaneous adipose tissue.<sup>1,4,15,18,20,24-26,30</sup>

The term "vascular EDS" describes the propensity of patients with EDS type IV for easy bruisability and bleeding, which may be spontaneous or post-traumatic. Aneurysms may occur in small, medium, and large arteries. Morbidity and mortality may result from spontaneous or traumatic vascular dissection or rupture, or from iatrogenic complications in the course of angiographic or surgical procedures. A number of reviews summarize these complications.<sup>3,6,9,12,31,32</sup>

**The easy bruising in children with undiagnosed EDS may lead to false suspicions of child abuse**



**TABLE 3****Clinical diagnostic features of Ehlers-Danlos syndromes by the Berlin classification**

TYPE (SYNONYM)	DIAGNOSTIC FEATURES
<b>All types</b>	<b>Principal signs:</b> <b>Skin hyperextensibility with soft, velvety, doughy texture</b> <b>Dystrophic scarring</b> <b>Easy bruising</b> <b>Joint hypermobility</b> <b>Connective tissue fragility</b>
I (gravis)*	Principal signs severe Widespread scarring and bruising, especially of the head, chin, and shins Molluscoid pseudotumors
II (mitis)*	Principal signs mild, similar to type I but less severe
III (hypermobile)*	Marked joint hypermobility Moderate skin hyperextensibility No cutaneous scars
IV (vascular) Acrogeric subtypes A* and B† Ecchymotic subtype C*	Variable stigmata Severe bruising Hyperpigmentation with or without scarring Thin skin with prominent venous plexus Risk of vascular rupture higher with acrogeric subtypes A and B Colonic perforation Characteristic facial appearance
V (X-linked)	Principal signs moderate Resembles types I, II, and III
VI (ocular-scoliotic)† Subtype A with low lysyl hydroxylase levels Subtype B with normal lysyl levels	Principal signs severe Ocular: microcornea, scleral perforation, retinal detachment Muscular hypotonia, muscular dystrophy often suspected due to delayed motor milestones Persistent premature scoliosis
VII (arthrochalasia multiplex congenita) Subtypes A*, B*, and C†	Marked joint hypermobility Short stature Micrognathia Mild facial cutis laxa In subtype C, severe generalized cutis laxa
VIII (periodontitis)*	Principal signs moderate Aggressive periodontitis, gingival recession Early tooth loss Allelic variation with variable expression
IX	Now considered a disorder of copper transport
X (fibronectin abnormality)†	Principal signs seen, but with normal skin texture Petechiae Striae distensae Platelet aggregation defect corrected by fibronectin
XI	Now considered a familial articular hypermobility syndrome

\*Autosomal dominant

†Autosomal recessive

**EDS is a remarkably heterogeneous group of diseases**

TABLE 4

### Complications of Ehlers-Danlos syndrome type IV ('vascular EDS')

#### Vascular

Aortic aneurysm  
Aortic dissection  
Coronary aneurysm  
Visceral vessel aneurysm

#### Gastrointestinal

Colonic perforation most frequently of the sigmoid, but also in the descending, ascending, and transverse colon and rectum  
Paraesophageal hernias  
Colonic ileus

#### Neurovascular

Aneurysm (carotid, vertebral)  
Dissection (carotid, cerebellar, vertebral)  
Fistula (carotid-cavernous)

#### Obstetric

Death  
Miscarriage  
Premature rupture of membranes  
Menorrhagia  
Postpartum complications including excessive bleeding, cervical tears, fourth-degree episiotomy, uterine prolapse  
Hysterectomy  
Preterm birth  
Uterine rupture  
Vascular rupture (vena cava, aorta, pulmonary artery)  
Vaginal laceration  
Induced abortion

lagen abnormalities are either unknown or incompletely characterized.<sup>4,14–21,23,25,27–30,33</sup> A defect in type III collagen is the unifying abnormality in patients with EDS type IV.<sup>4,15,19–21,23,25,27,29,34</sup> This was first demonstrated by Pope, Martin, and Lichtenstein<sup>27</sup> in 1975 and was historically the second defect of collagen synthesis identified in a subtype of EDS. Type III collagen is a triple helical protein consisting of three identical monomers (alpha chains) synthesized from the *COL3A1* gene. In connective tissues, it is organized end-to-end into "fibrils" and belongs to the family of fibrillar collagens. It is found in stretchable tissues: skin, vascular walls, gastrointestinal tract, but not in bone or cartilage.<sup>14,20,21,23,25,29</sup> Type III collagen predominates in skin blood vessels and ligaments,<sup>25</sup> accounting for the easy bruisability and hypermobility seen in these patients. It is not the predominant collagen in skin per se, which may explain the mild or absent skin findings.

#### Genetic defects in collagen synthesis

Genetic defects in collagen synthesis include point mutations, splicing errors, and deletions.<sup>20,21,23,25</sup> This wide variety of mutations results in numerous abnormal collagen alpha chains being synthesized. Consequently, type III collagen becomes defective. Gene studies of individual families with EDS type IV show molecular abnormalities in type III collagen synthesis unique to each family.<sup>24,30</sup> The result is phenotypic variability ranging from mild (almost absent clinical signs) to severe (acrogeric form of EDS type IV). Consequently, a single form of gene therapy is not likely to be applicable for all patients with EDS type IV.<sup>20,25</sup>

#### ■ WHAT ARE THE MOLECULAR DEFECTS IN EDS?

**4** Which of the following statements is true?

- ☐ Type III collagen is deficient or defective in EDS type IV
- ☐ The specific collagen abnormality has been identified in all subtypes of EDS
- ☐ Since the defect in EDS type IV is known to involve the type III collagen gene, gene replacement therapy will likely play a future role in treatment
- ☐ None of the above

EDS types I, II, IV, VI, and VII have well-defined defects in collagen synthesis identified (TABLE 1). In the remaining subtypes, col-

#### ■ HOW IS THE DIAGNOSIS OF EDS TYPE IV CONFIRMED?

**5** Which of the following statements is false?

- ☐ Tissue cultures of skin fibroblasts are useful in demonstrating defects in collagen synthesis
- ☐ Light microscopy findings of skin biopsies are not diagnostic
- ☐ Interventional angiograms should be



done in all cases of EDS type IV with a suspected arterial aneurysm

☐ None of the above

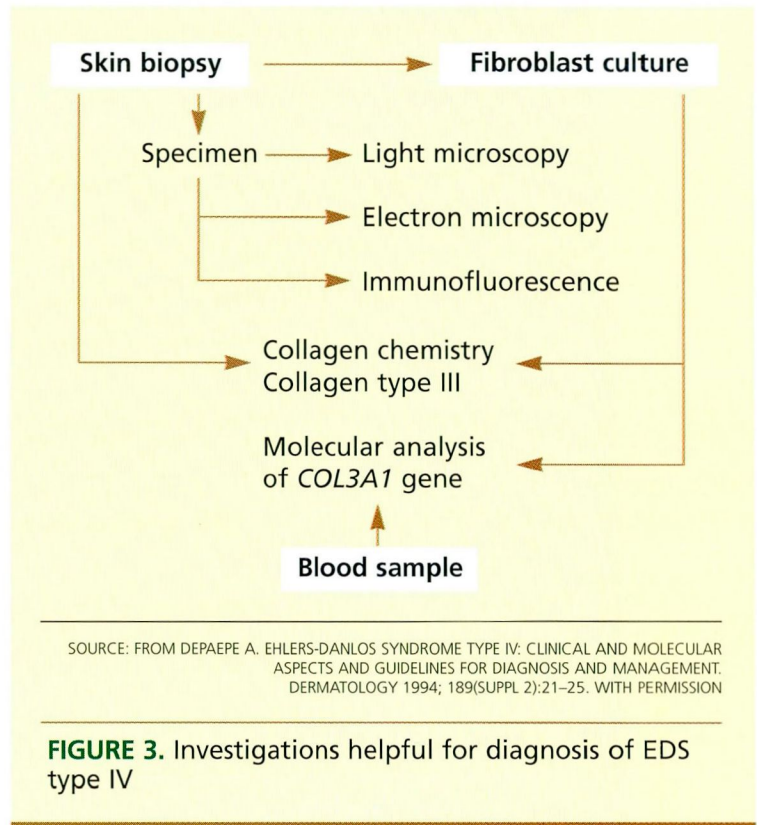
Interventional angiograms are potentially dangerous and should not be done routinely in all patients with EDS type IV who present with visceral aneurysms. Less invasive methods should first be attempted (eg, magnetic resonance imaging, magnetic resonance angiography, digital subtraction angiography, ultrasonography) when pursuing a vascular complication. If invasive diagnostic and especially surgical therapeutic interventions are performed without appreciation of abnormal tissue fragility, outcome and survival will be compromised.<sup>3,5-8,10-13,20,34-38</sup>

The diagnosis of EDS is based upon the previously noted clinical features. In less clear-cut cases, skin biopsies may demonstrate thinning of the dermis to half or one third of normal, with a relative decrease in elastic material.<sup>20</sup> However, skin biopsies done with routine techniques are generally nondiagnostic.<sup>4</sup> Immunofluorescence with antihuman antibodies to normal type III collagen may show absence or depletion of type III collagen. Electron microscopy may show thin and irregular collagen fibers. Studies of collagen from patient-derived skin fibroblast cultures may demonstrate quantitative or qualitative abnormalities on gel electrophoresis. Molecular analysis of the *COL3A1* gene from a patient's fibroblast culture can be compared with genes isolated from peripheral blood leukocytes of family members to identify relatives at risk (FIGURE 3).<sup>20</sup>

#### ■ HOW ARE PATIENTS WITH EDS TYPE IV BEST MANAGED?

**6** Which of the following statements is true?

- ☐ Surgical repair is preferred over bracing for unstable joints
- ☐ Partial vessel dissections are best managed conservatively
- ☐ Vascular stenting has become the preferred treatment for aneurysms and rupture in EDS
- ☐ All of the above



**FIGURE 3.** Investigations helpful for diagnosis of EDS type IV

In the event of partial vascular dissection or self-limiting rupture, conservative noninvasive diagnostic modalities and supportive therapy (ie, bed rest, fluid replacement and management, trials of synthetic vasopressin for improved hemostasis) have been advocated. If vascular surgery is required, ligation is the procedure of choice if feasible (ie, medium vessel dissections). Reconstruction and graft placement may be associated with suture dehiscence and recurrent bleeding,<sup>3,5,6,8</sup> and patients who receive such procedures (ie, life-threatening aortic dissections) should be monitored very closely postoperatively. In the event of colonic perforation, total abdominal colectomy appears to be the safest means of avoiding reperforation. It is noteworthy that primary repair and reanastomosis of small intestine perforations rarely result in reperforation or anastomotic leaks.<sup>11</sup>

Collagen-specific treatment does not exist. As previously emphasized, singular gene therapy is unlikely to be of benefit, given the heterogeneity of gene defects causing this syndrome.

**In EDS type IV, interventional angiograms should not be done routinely**



Prophylactic measures include avoidance of contact sports, bracing unstable joints (especially the knees), and analgesics for strains, tears and secondary osteoarthritis. Stool softeners may reduce the risks of intestinal perforation or reperforation following bowel surgery.<sup>3,13,20</sup>

### ■ WHAT IS THE PROGNOSIS OF THESE PATIENTS?

**7** Which of the following statements about EDS type IV is true?

- ☐ With the exception of EDS type IV, the lifespan of most EDS patients is normal
- ☐ Colonic rupture is the most common cause of gastrointestinal morbidity and mortality
- ☐ Half of EDS type IV patients die by their fourth decade of life
- ☐ All of the above

All of the above are true. In published reports, overall mortality from vascular complications in patients with EDS type IV ranged from 30% to 63%.<sup>3,5,6,8</sup> The former figure is from a more recent series, and probably reflects greater awareness of this disease and improved surgical and interventional techniques. Gastrointestinal complications (mostly colonic rupture) may cause high mortality as well (23.3%).<sup>6</sup> Pregnancy-related death may be significant (26%).<sup>9</sup> There is often little or no warning of the premorbid catastrophic event. Lifespan is uniformly decreased, with half of affected patients dying before the age of 40.<sup>4</sup> Although uncommon, lifespans into the fifth and sixth decades have been reported.<sup>3,4,6</sup> Prognosis appears to be worse for patients with the acrogeric form of EDS type IV.<sup>20</sup>

Phenotypic penetrance of traits for any form of EDS is extremely variable. Consequently, projections about prognosis and counseling of families need to be individualized. Fortunately, in our patient and her family, disease expression has been relatively mild. Among the most important aspects of this family's care will be regular follow-up by physicians familiar with EDS.

### ■ SUMMARY

EDS type IV presents a diagnostic and therapeutic challenge to the primary care physician, surgeon, and rheumatologist. In patients for whom the diagnosis is known, avoidance of trauma, contact sports, or strenuous activities, joint bracing and protection, and counseling on contraception are helpful preventive strategies. In patients presenting with vascular, gastrointestinal, or obstetric complications, a history of hypermobility and skin fragility (easy bruising, abnormal scarring, poor wound healing) should lead to a suspicion of this diagnosis, and to caution in the use of certain invasive diagnostic and operative techniques. Efforts should be made to examine family members. Most importantly, when caring for such patients, the acute onset of headaches, chest pain, shortness of breath, and abdominal pain should arouse suspicion of a potentially catastrophic vascular or visceral event. ■

### ■ REFERENCES

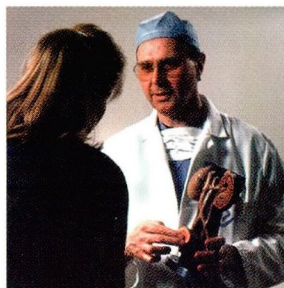
- Beighton P, Price A, Lord J, Dickson E. Variants of the Ehlers-Danlos syndrome: clinical, biochemical, haematological, and chromosomal features of 100 patients. *Ann Rheum Dis* 1969; 28:228-242.
- Johnston KW, Rutherford RB, Tilson MD, et al. Suggested standards for reporting on arterial aneurysms. *J Vasc Surg* 1991; 13:452-458.
- Bergqvist D. Ehlers-Danlos Type IV syndrome: A review from a vascular surgical point of view. *Eur J Surg* 1996; 162:163-170.
- Byers PH. Ehlers-Danlos syndrome Type IV: A genetic disorder in many guises (editorial). *J Invest Dermatol* 1995; 105:311-313.
- Cikrit DF, Miles JH, Silver D. Spontaneous arterial perforation: The Ehlers-Danlos specter. *J Vasc Surg* 1987; 5:248-255.
- Freeman RK, Swegle J, Sise MJ. The surgical complications of Ehlers-Danlos syndrome. *Am Surg* 1996; 62: 869-873.
- Hunter GC, Malone JM, Moore WS, Misiowski RI, Chvapil M. Vascular manifestations in patients with Ehlers-Danlos syndrome. *Arch Surg* 1982; 117:495-498.
- Mattar SG, Kumar AG, Lumsden AB. Vascular complications in Ehlers-Danlos syndrome. *Am Surg* 1994; 60: 827-831.
- Rudd NL, Holbrook KA, Nimrod C, Byers PH. Pregnancy complications in type IV Ehlers-Danlos syndrome. *Lancet* 1983; 1:50-53.
- Serry C, Agomuo O, Goldin MD. Review of Ehlers-Danlos syndrome. *J Cardiovasc Surg* 1988; 29:530-534.
- Solomon JA, Abrams L, Lichtenstein GR. GI manifestations of Ehlers-Danlos syndrome. *Am J Gast* 1996; 91:2282-2288.
- Sorokin Y, Johnson MP, Rogowski N, et al. Obstetric and gynecologic dysfunction in the Ehlers-Danlos syndrome. *J Reprod Med* 1994; 39:281-284.
- Stillman AE, Painter R, Hollister DW. Ehlers-Danlos syndrome type IV: diagnosis and therapy of associated bowel perforation. *Am J Gast* 1991; 86:360-362.
- Tilstra DJ, Byers PH. Molecular basis of hereditary disorders of connective tissue. *Ann Rev Med* 1994; 45:149-163.

**Try to examine the family members of patients with EDS**




15. Beighton P. The Ehlers-Danlos syndromes. In Beighton P, editor. *McKusick's Heritable Disorders of Connective Tissue*. St. Louis: Mosby, 1993:189-251.
16. Beighton P, de Paeppe A, Danks D, et al. International nosology of heritable disorders of connective tissue, Berlin 1986. *Am J Med Genet* 1988; 29:581-594.
17. Beighton P, de Paeppe A, Hall JG, et al. Molecular nosology of heritable disorders of connective tissue. *Am J Med Genet* 1992; 42:431-448.
18. Byers PH. Ehlers-Danlos syndrome: recent advances and current understanding of the clinical and genetic heterogeneity. *J Invest Dermatol* 1994; 103:475-525.
19. Cole WG. Etiology and pathogenesis of heritable connective tissue diseases. *J Ped Orthopaed* 1993; 13:392-403.
20. De Paeppe A. Ehlers-Danlos syndrome type IV: clinical and molecular aspects and guidelines for diagnosis and management. *Dermatology* 1994; 189(suppl 2):21-25.
21. De Paeppe A. The Ehlers-Danlos syndrome: A heritable collagen disorder as cause of bleeding. *Thromb Haemost* 1996; 75:379-386.
22. Hausser I, Anton-Lamprecht I. Differential ultrastructural aberration of collagen fibrils in Ehlers-Danlos syndromes type I-IV as a means of diagnostics and classification. *Hum Genet* 1994; 3:394-407.
23. Kivirikko KI. Collagens and their abnormalities in a wide spectrum of diseases. *Ann Med* 1993; 25:113-126.
24. Pope FM. Ehlers-Danlos syndrome. *Baillieres Clin Rheumatol* 1991; 5:321-349.
25. Pope FM, Burrows NP. Ehlers-Danlos syndrome has varied molecular mechanisms. *J Med Genet* 1997; 34:400-410.
26. Pope FM, Narcisi P, Nicholls AC, Liberman M, Oorthuys JW. Clinical presentations of Ehlers-Danlos syndrome type IV. *Arch Dis Child* 1988; 63:1016-1025.
27. Pope FM, Martin GR, Lichtenstein JR, et al. Patients with Ehlers-Danlos syndrome type IV lack type III collagen. *Proc Natl Acad Sci USA* 1975; 72:1314-1316.
28. Rowe DW, Shapiro JR. Heritable disorders of structural proteins. In: Kelley WN, editor. *Textbook of rheumatology*. 5th ed. Philadelphia: W.B. Saunders, 1997:1546-1554.
29. Vandenburg P. Molecular basis of heritable connective tissue disease. *Biochem Med Metabol Biol* 1993; 49:1-12.
30. Yeowell HN, Pinnell SR. The Ehlers-Danlos syndromes. *Semin Dermatol* 1993; 12:229-240.
31. Ainsworth SR, Aulicino PL. A survey of patients with Ehlers-Danlos syndrome. *Clin Orthop* 1993; 286:250-256.
32. North KN, Whiteman DAH, Pepin MG, Byers PH. Cerebrovascular complications in Ehlers-Danlos syndrome type IV. *Ann Neurol* 1995; 38:960-964.
33. Sidhu-Malik NK, Wenstrup RJ. The Ehlers-Danlos syndromes and Marfan syndrome: Inherited diseases of connective tissue with overlapping clinical features. *Semin Dermatol* 1995; 14:40-46.
34. Witz M, Lehmann JM. Aneurysmal arterial disease in a patient with Ehlers-Danlos syndrome. *J Cardiovasc Surg* 1997; 38:161-163.
35. Berney T, La Scala G, Vettorel D, et al. Surgical pitfalls in a patient with type IV Ehlers-Danlos syndrome and spontaneous colonic rupture. *Dis Colon Rectum* 1994; 37:1038-1042.
36. Salam TA, Lumsden AB, Martin LG, Smith RB. Nonoperative management of visceral aneurysms and pseudoaneurysms. *Am J Surg* 1992; 164:215-219.
37. Silva R, Cogbill TH, Hansbrough JF, et al. Intestinal perforation and vascular rupture in Ehlers-Danlos syndrome. *Int Surg* 1986; 71:48-50.
38. Snyder RR, Gilstrap LC, Hauth JC. Ehlers-Danlos syndrome and pregnancy. *Obstet Gynecol* 1983; 61:649-650.

**ADDRESS:** Gary S. Hoffman, MD, Department of Rheumatic and Immunologic Diseases, A50, The Cleveland Clinic Foundation, 9500 Euclid Avenue, Cleveland, OH 44195.



## LET US HEAR FROM YOU

- Let us hear your opinions about the *Cleveland Clinic Journal of Medicine*.
- Do you like current articles and sections?
- What topics would you like to see covered and how can we make the Journal more useful to you?



PHONE 216.444.2661  
FAX 216.444.9385  
E-MAIL [ccjm@ccf.org](mailto:ccjm@ccf.org)  
WWW <http://www.ccjm.org>

CLEVELAND CLINIC JOURNAL OF MEDICINE  
The Cleveland Clinic Foundation  
9500 Euclid Avenue, NA32  
Cleveland, Ohio 44195

