

**ARLENE LOBO, MD**Department of Pulmonary and Critical Care Medicine,
Cleveland Clinic**RAED A. DWEIK, MD**Department of Pulmonary and Critical Care Medicine,
Cleveland Clinic

A 57-year-old woman with pulmonary infiltrates and eosinophilia

A 57-YEAR-OLD WOMAN with a history of asthma for many years presents because of fever, dyspnea, and cough (productive of yellow sputum), lasting several weeks. She also reports generalized weakness, fatigue, anorexia, and night sweats for the same duration. She has never smoked. She was immunocompetent, and a purified protein derivative (PPD) skin test was negative. She had been treated with several oral and intravenous antibiotics without improvement.

Physical examination, diagnostic tests

The patient is afebrile and in mild respiratory distress. Lung auscultation reveals bilateral scattered wheezes. Otherwise, the physical examination is normal.

On presentation, chest radiography demonstrates bilateral peripheral infiltrates with a small right pleural effusion (FIGURE 1). Her complete blood count is as follows:

- Hemoglobin 10.0 g/dL
- Hematocrit 30%
- Platelet count $389 \times 10^9/L$
- White blood cell count $4.94 \times 10^9/L$ (neutrophils 43%, lymphocytes 15%, eosinophils 38%).

CAUSES OF PULMONARY INFILTRATES WITH EOSINOPHILIA

1 What is the diagnosis?

- ☐ Acute eosinophilic pneumonia
- ☐ Chronic eosinophilic pneumonia
- ☐ Allergic bronchopulmonary aspergillosis
- ☐ Churg-Strauss syndrome
- ☐ Fungal pneumonia

All the disease processes listed above can

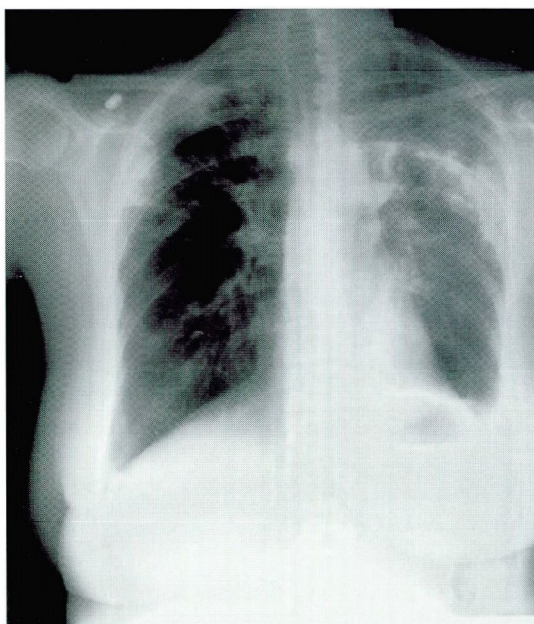


FIGURE 1. Presenting posteroanterior chest radiograph. Notice the bilateral peripheral alveolar infiltrates involving the upper lung zones predominantly on the left side.

cause pulmonary infiltrates with peripheral eosinophilia (arbitrarily defined as greater than 6% eosinophils on the differential white blood cell count).

DIFFERENTIAL DIAGNOSIS: EOSINOPHIL INVOLVEMENT IN LUNG DISEASE

TABLE 1 lists common causes of the syndrome of pulmonary infiltrates with eosinophilia. Of note: These are distinct disorders that generally have little clinical relationship to one another except for the presence of eosinophils. In some (ie, those in the top part

TABLE 1

Differential diagnosis of pulmonary infiltrates with eosinophilia

EOSINOPHILIC LUNG DISEASES

Simple pulmonary eosinophilia (Löffler syndrome)
 Parasitic infection
 Drug reaction
 Toxins, allergins
 Acute eosinophilic pneumonia
 Chronic eosinophilic pneumonia
 Hypereosinophilic syndrome
 Pulmonary eosinophilia with asthma
 Allergic bronchopulmonary aspergillosis
 Tropical pulmonary eosinophilia
 Vasculitis
 Churg-Strauss syndrome

LUNG DISEASES SOMETIMES ASSOCIATED WITH EOSINOPHILS

Fungal infection
 Mycobacterial infection
 Malignancy
 Idiopathic pulmonary fibrosis

Chronic and acute eosinophilic pneumonia are two completely distinct diseases

of TABLE 1), eosinophilia is part of the definition of the disease or is thought to be of pathogenetic importance.

In the other lung diseases listed in TABLE 1, eosinophil involvement is variable, and eosinophils are not considered an integral part of the disease process.

Simple pulmonary eosinophilia

Simple pulmonary eosinophilia (Löffler syndrome) is characterized by transient pulmonary infiltrates with peripheral eosinophilia and minimal or no pulmonary symptoms. Löffler syndrome is usually secondary to parasitic infection (eg, *Ascaris lumbricoides*), allergens, or drugs or toxins (eg, sulfonamides). Acute and chronic eosinophilic pneumonias are discussed in more detail below.

Acute eosinophilic pneumonia

Acute eosinophilic pneumonia must be differentiated from chronic eosinophilic pneumonia. Although the nomenclature is similar, they are two completely different diseases.

Patients with acute eosinophilic pneumonia may be of any age and may present with an acute febrile illness of 1 to 5 days' duration accompanied by myalgias, pleuritic chest pain, and hypoxemic respiratory failure, often requiring mechanical ventilation. The earliest chest radiographic findings show only subtle amounts of interstitial infiltrate, often with Kerley B lines. This is followed within hours to a few days by extensive mixed alveolar and interstitial infiltrates involving all lobes. Computed tomography (CT) of the chest usually shows diffuse parenchymal alveolar infiltrates, pleural effusions, and pronounced septal markings, but no adenopathy.

The percentage of eosinophils is usually normal in the peripheral blood. In contrast, it is elevated in the bronchoalveolar lavage fluid. The percentages of lymphocytes and neutrophils in lavage fluid are also elevated. Lung biopsy reveals eosinophils and edema within the alveolar space, the bronchial walls, and the interstitial space.

Pulmonary function testing in the acute phase shows a low diffusing capacity and a restrictive pattern. After treatment, pulmonary function tests usually return to normal.

Patients with acute eosinophilic pneumonia respond rapidly to high doses of corticosteroids, usually within 24 to 48 hours. A commonly used regimen is 60 to 125 mg of methylprednisolone intravenously every 6 hours until respiratory failure resolves, usually in 1 to 3 days, followed by oral prednisone 40 to 60 mg/day tapered over the next 2 to 4 weeks. Unlike patients with chronic eosinophilic pneumonia, patients with acute eosinophilic pneumonia do not relapse after discontinuation of corticosteroids.

Chronic eosinophilic pneumonia

Patients with chronic eosinophilic pneumonia are often in their 50s, and women outnumber men by 2 to 1. The onset of symptoms is often insidious over several weeks or months. Common symptoms include cough (90%), fever (87%), dyspnea (57%), and weight loss (57%). Other symptoms include malaise, wheezing, night sweats, sputum production, myalgias, and chest pain. Asthma is present in about 50% of cases.

Peripheral blood eosinophilia (> 6%) is usually mild or moderate. Eosinophils can be found in the sputum in about half of the patients. Serum IgE levels are increased in two thirds of patients, and rheumatoid factor or immune complexes may also be present. The erythrocyte sedimentation rate is usually elevated, and peripheral blood thrombocytosis has been reported.

Pulmonary function tests can be normal in mild cases, but usually show restrictive defects with a reduction in diffusing capacity. Obstructive defects are most likely due to concurrent asthma. All patients have an increased alveolar-arterial oxygen gradient.

Chest radiography demonstrates peripheral-based infiltrates located in the outer two thirds of the lung fields in about 65% of patients. A chest CT scan (**FIGURE 2**) shows peripheral air space disease. Bronchoalveolar lavage fluid demonstrates high percentages of eosinophils (> 25%) in the acute stage of chronic eosinophilic pneumonia.

Hypereosinophilic syndrome

Hypereosinophilic syndrome is a rare and often fatal disorder defined as an eosinophil count of $1.5 \times 10^9/L$ for at least 6 months. Hypereosinophilic syndrome can involve any organ system, but the major source of mortality and morbidity is cardiac involvement. The lungs are involved in 40% of patients.

Allergic bronchopulmonary aspergillosis

Allergic bronchopulmonary aspergillosis is an asthmatic syndrome that also occurs in 10% of patients with cystic fibrosis. Diagnostic criteria include asthma, eosinophilia, immediate skin sensitivity to *Aspergillus fumigatus* antigen, and elevated immunoglobulin E levels. Chest radiographs in allergic bronchopulmonary aspergillosis may reveal the classic “gloved finger” infiltrates that suggest bronchiectasis and mucoid impaction.

Tropical pulmonary eosinophilia

Tropical pulmonary eosinophilia is seen in areas of endemic filariasis and is thought to be secondary to infection with the human filarial species *Wuchereria bancrofti* or *Brugia malayi*. For a more detailed discussion of the clinical features of these entities, the reader is referred

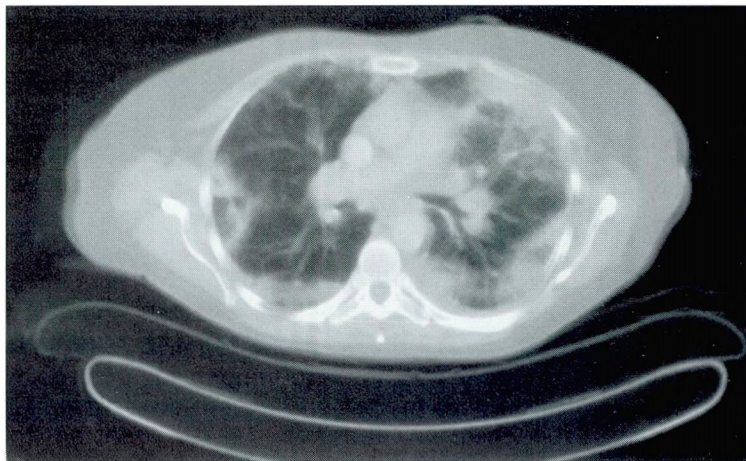


FIGURE 2. The peripheral nature of the infiltrates in chronic eosinophilic pneumonia can be well appreciated on this CT scan of the chest (same patient as in **FIGURE 1**). A CT scan of the chest, however, is neither necessary nor sufficient to make the diagnosis of chronic eosinophilic pneumonia.

to the excellent reviews on the topic given in the reading list at the end of this article.

Churg-Strauss syndrome

Churg-Strauss syndrome, also known as allergic angiitis and granulomatosis, is a rare syndrome of asthma, eosinophilia, and systemic vasculitis. Churg-Strauss syndrome involves the small arteries and veins and must be differentiated from polyarteritis nodosa, which involves the medium-size vessels and is not associated with asthma or eosinophilia.

■ HOW TO PROCEED

The patient's chest radiograph (**FIGURE 1**) has the classic features of chronic eosinophilic pneumonia, which is often described as the “photographic negative of pulmonary edema” and results from the peripheral nature of the infiltrates. Although this patient's clinical presentation combined with the radiographic features strongly suggests chronic eosinophilic pneumonia, other causes of the syndrome of pulmonary infiltrates with eosinophilia (particularly infection) must be excluded before initiating therapy. Since many entities that can cause this syndrome (**TABLE 1**) can have nonspecific clinical presentations, the clinical picture alone is not always sufficient to reach a final diagnosis without further testing.

Chronic eosinophilic pneumonia is the “photographic negative of pulmonary edema”

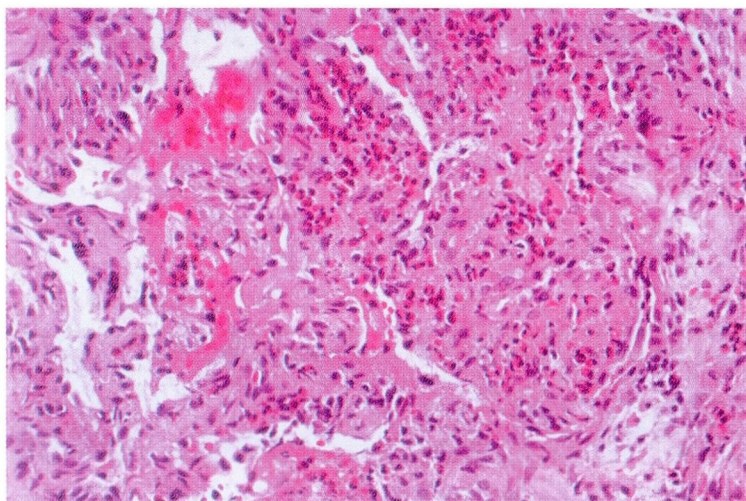


FIGURE 3. Transbronchial lung biopsy specimen demonstrating an acute and organizing pneumonia with intense eosinophilic infiltrate.

■ SELECTING A MINIMALLY INVASIVE, HIGH-YIELD DIAGNOSTIC METHOD

2 What would you do next to reach a diagnosis?

- ☐ Computed tomography (CT) of the chest
- ☐ Open lung biopsy
- ☐ Bronchoscopy with bronchoalveolar lavage and transbronchial biopsy

A CT scan of the chest may help better define the infiltrates and may indicate whether lymphadenopathy is present, but it will not help to make a firm diagnosis.

Although open lung biopsy is the “gold standard” and may have the highest yield for making the diagnosis, it is invasive and carries the risk of a surgical procedure.

Flexible bronchoscopy with bronchoalveolar lavage and transbronchial biopsy is the procedure of choice because it is safe and minimally invasive and can have a reasonably high diagnostic yield, especially by effectively excluding infectious etiologies.

■ CASE CONTINUED: BRONCHOSCOPIC FINDINGS

Bronchoscopy was performed in this patient, and the bronchoalveolar lavage fluid revealed a total white blood cell count of $2.25 \times 10^9/L$

with 1% neutrophils, 5% lymphocytes, 2% monocytes, 4% macrophages, and 87% eosinophils (normal < 1%). Transbronchial biopsy demonstrated an eosinophilic infiltrate (**FIGURE 3**). Stains and cultures for bacteria, tuberculosis, and fungi in the bronchoalveolar lavage fluid were all negative. Stool tests for ova and parasites were repeatedly negative.

The high level of eosinophilia in the lavage fluid and the presence of numerous eosinophils on transbronchial biopsy, combined with the clinical and radiographic features, strongly suggests chronic eosinophilic pneumonia in this patient.

■ TREATMENT OF CHRONIC EOSINOPHILIC PNEUMONIA

3 What is the treatment of choice?

- ☐ Antibiotics
- ☐ Antifungals
- ☐ Corticosteroids

Treatment of chronic eosinophilic pneumonia consists of systemic (oral or intravenous) corticosteroids. Although the mechanism of action of corticosteroids is not fully understood, they lead to rapid sequestration of eosinophils within the circulation and may block eosinophil production by the bone marrow. Corticosteroids can also inhibit eosinophil adherence and chemotaxis and reduce eosinophil survival. Commonly used doses of steroids are 40 to 80 mg of prednisone daily tapered slowly over 6 to 12 months.

There is a high relapse rate if steroid therapy is discontinued in the first 6 months, and some patients require steroid therapy indefinitely.

Patient's treatment course

Our patient was treated with prednisone 40 mg twice a day for a week, and her symptoms improved markedly. She was prescribed maintenance therapy consisting of prednisone 40 mg daily, with complete resolution of her peripheral eosinophilia and pulmonary infiltrates (**FIGURE 4**). Steroids were tapered slowly over 6 months, with no recurrence of the symptoms at 1 year.

Relapses are common if corticosteroids are stopped too soon

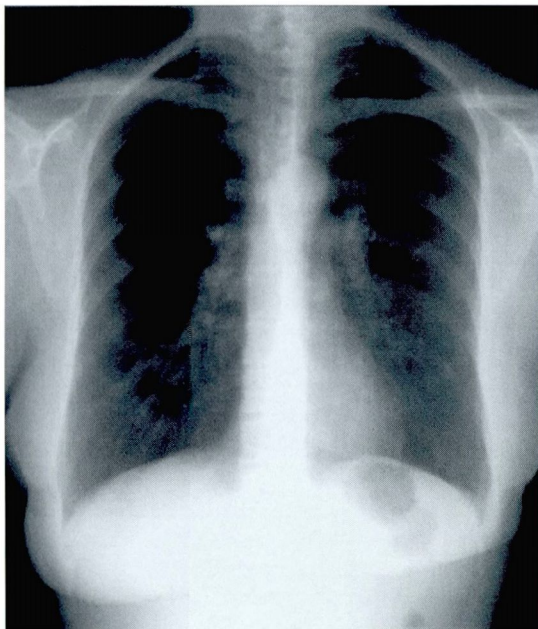



FIGURE 4. Chest radiograph from patient in **FIGURES 1** and **3** after 2 months of oral corticosteroid therapy. Notice the complete resolution of the infiltrates seen in **FIGURE 1**.

■ WHEN TO CONSIDER A DIAGNOSIS OF CHRONIC EOSINOPHILIC PNEUMONIA

Although chronic eosinophilic pneumonia is uncommon, it is important to consider it in the differential diagnosis of pulmonary infiltrates, especially in patients who do not improve with antibiotic therapy. Early appropriate diagnostic evaluation and proper treatment (as outlined above) are important to achieve a good outcome. 

■ SUGGESTED READING

Allen JN, Davis WB. Eosinophilic lung diseases. *Am J Respir Crit Care Med* 1994; 150:1423–1438.

Meeker DP. Pulmonary infiltrates and eosinophilia revisited. *Cleve Clin J Med* 1989; 56:199–211.

Naughton M, Fahy J, FitzGerald MX. Chronic eosinophilic pneumonia: a long-term follow-up of 12 patients. *Chest* 1993; 103:162–165.

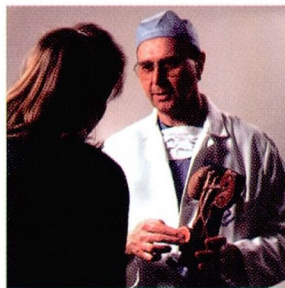
Tazelaar HD, Linz LJ, Colby TV, Meyers JL, Limper AH. Acute eosinophilic pneumonia: findings in nine patients. *Am J Respir Crit Care Med* 1997; 155:296–302.

ADDRESS: Raed A. Dweik, MD, Department of Pulmonary and Critical Care Medicine, A90, The Cleveland Clinic Foundation, 9500 Euclid Avenue, Cleveland, OH 44195; e-mail: dweikr@ccf.org.

CME ANSWERS


Answers to the CREDIT TEST on page 383 of this issue

1 E 2 D 3 C 4 E 5 C 6 B 7 D 8 E 9 E 10 B 11 D



LET US HEAR FROM YOU

- Let us hear your opinions about the *Cleveland Clinic Journal of Medicine*.
- Do you like current articles and sections?
- What topics would you like to see covered and how can we make the Journal more useful to you?



PHONE 216.444.2661
FAX 216.444.9385
E-MAIL ccjm@ccf.org
WWW <http://www.ccjm.org>

CLEVELAND CLINIC JOURNAL OF MEDICINE
The Cleveland Clinic Foundation
9500 Euclid Avenue, NA32
Cleveland, Ohio 44195

