



CHRISTI A. MATTEONI, MD  
Department of Gastroenterology, Cleveland Clinic

JOHN J. VARGO II, MD  
Department of Gastroenterology, Cleveland Clinic

# A 42-year-old man with microcytic anemia and hypocalcemia

**A** 42-YEAR-OLD MAN is referred for evaluation of iron-deficiency anemia. His only symptom is fatigue.

**Medical history.** The patient recalls that 5 years ago his primary care physician at another institution told him he had thalassemia minor. He has never required a blood transfusion and has no history of melena, hematochezia, or abdominal pain. No records are available from his local hospital regarding this diagnosis.

The patient has had microcytic anemia and iron studies consistent with iron deficiency for several years. Laboratory values are listed in **TABLE 1**. Normal hemoglobin A<sub>2</sub> and F values along with indices suggesting iron deficiency essentially rule out the beta thalassemia trait, and the alpha thalassemia trait is unlikely. A trial of multivitamins

with iron did not improve his iron indices.

The patient recalls two episodes of diarrhea that required medical attention. The first was 2 years ago after a trip to China, when he had loose stool, irregular bowel habits, bloating, upper abdominal pain, and a low-grade fever that improved after a trial of metronidazole. The second episode occurred 1 month after taking clarithromycin for sinusitis. During this episode he experienced no nocturnal symptoms, nausea, vomiting, fever, or chills. He was prescribed kaolin and pectin, and the diarrhea improved.

**Present medications** include clarithromycin (which he takes for his recurrent sinusitis), loratadine D, triamcinolone nasal spray, and, occasionally, ibuprofen.

**Family history** is notable for colon polyps and polycystic kidney disease.

**Physical examination** reveals nothing remarkable. The stool is hemoccult negative.

**TABLE 1**

## The patient's laboratory values

TEST	2 YEARS PREVIOUSLY	PRESENT VALUE	NORMAL RANGE
Hemoglobin, g/dL	—	11.8	13.5–17.5
Hemoglobin A <sub>2</sub> , %	2.0	—	1.5–3.5
Hemoglobin F, %	0.74	—	0–0.9
Hematocrit, %	—	39.8	40–52
Red blood cell count, × 10 <sup>9</sup> /L	—	6.43	4.5–6.0
Mean corpuscular volume, fL	—	61.9	80–100
Mean corpuscular hemoglobin, %	—	29.6	32–36
Serum iron, µg/dL	17	24	30–140
Total iron-binding capacity, µg/dL	291	348	210–415
Iron saturation, %	6	7	11–46
Ferritin, ng/mL	—	3.8	18.0–300.0
Vitamin B <sub>12</sub> , pg/mL	—	502	251–900
Albumin, g/dL	—	4.2	3.5–5.0
Calcium, mg/dL	—	7.9	8.5–10.5

## DIFFERENTIAL DIAGNOSIS

**1** What is the most likely cause of this patient's iron-deficiency anemia?

- ☐ Gastroenteropathy induced by non-steroidal anti-inflammatory drugs (NSAIDs)
- ☐ Celiac sprue
- ☐ Tropical sprue
- ☐ Occult gastrointestinal neoplasm

All of the above are plausible.

**NSAID-induced gastroenteropathy.** Occult gastrointestinal bleeding due to NSAID use may be so mild that it may not be detected on standard fecal occult blood tests. NSAIDs can produce superficial damage, endoscopic ulcers, or clinical ulcers. Injury



from this class of medications is not limited to the stomach and duodenum and may occur more distally.

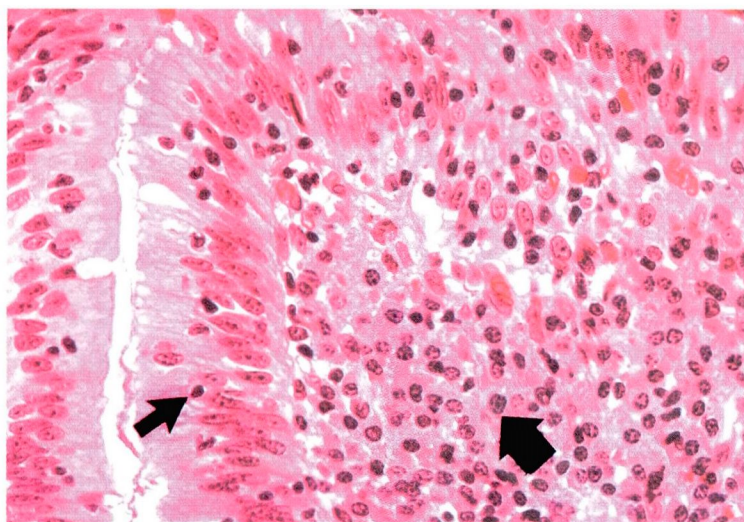
**Celiac sprue** can vary markedly in its clinical presentation. The spectrum may include diarrhea, abdominal distention, cramping, and marked weight loss. Alternatively, patients may have no symptoms or may complain of malaise and weakness. Many of the symptoms reflect the extent of small bowel involvement.

Anemia due to iron or folate deficiency is common in celiac sprue with proximal small bowel involvement.<sup>1,2</sup> However, vitamin B<sub>12</sub> deficiency can be seen (but rarely) when the disease involves the distal small bowel.

Other findings associated with celiac sprue are thrombocytosis and hyposplenism, as evidenced by Howell-Jolly bodies or target cells on a peripheral blood smear. In one study, Bullen et al<sup>3</sup> reviewed all blood films at their hospital for 1 year to look for features of hyposplenism. They then performed biopsies of the small intestine in 85% of the patients identified with hyposplenism and discovered that 70% had celiac sprue.

**Tropical sprue.** The patient's travel to China raises the question of postinfectious malabsorption causing tropical sprue. However, 90% to 96% of patients diagnosed with tropical sprue have diarrhea, weight loss, and megaloblastic anemia. Iron deficiency is not typically part of the clinical scenario. Furthermore, although tropical sprue can occur within days to weeks after arrival in an endemic area, this is infrequent. In general, one must live in an endemic area for more than 1 year to acquire tropical sprue. Before tetracycline and folic acid therapy were available, the mortality rate was high among those residing in endemic areas, and expatriates were left with a chronic disability.

**Occult gastrointestinal neoplasm.** Iron-deficiency anemia in a patient with a family history of colon polyps raises the question of occult polyps or neoplasm. However, our patient's iron deficiency has existed for several years without evidence of alarm symptoms or frank gastrointestinal bleeding, making neoplasm less likely but still possible.



**FIGURE 1.** Photomicrograph of the duodenal biopsy. The small arrow points to an intraepithelial lymphocyte; the large arrow points to a plasma cell (hematoxylin-eosin,  $\times 40$ ).

## ■ DIAGNOSTIC WORKUP

**2** What is your first step in the management of this patient?

- ☐ Upper GI series with small bowel follow through barium enema radiography
- ☐ Colonoscopy
- ☐ Upper endoscopy and colonoscopy
- ☐ Trial of empiric iron therapy

With iron-deficiency anemia and a family history of colon polyps, the patient should have a colonoscopy as part of his workup. In addition, he should undergo upper endoscopy to look for NSAID-induced lesions (even though his stool is hemoccult-negative) and a small bowel biopsy to address any malabsorptive syndromes as a cause of iron deficiency and hypocalcemia.<sup>4,5</sup>

The patient underwent upper and lower endoscopy. The colon was normal as far as the cecum. The upper GI tract also appeared normal, but a duodenal biopsy revealed abnormal villous architecture, prominent plasma cell infiltration, and intraepithelial lymphocytes (**FIGURE 1**), which are consistent with celiac sprue. However, the biopsy did not rule out tropical sprue, as it can be difficult to distinguish between celiac and tropical sprue.

**Iron-deficiency anemia is common in celiac sprue**





### ■ CONFIRMATORY STUDIES

**3** What other studies can be done to confirm the diagnosis of celiac sprue?

- ☐ Antiendomysial antibodies
- ☐ Antigliadin antibodies
- ☐ Both antiendomysial and antigliadin antibodies
- ☐ Gluten challenge and repeat small bowel biopsy

If a patient's history and physical examination suggest celiac sprue and the patient does not have steatorrhea, it is cost-effective to check for both antiendomysial and antigliadin antibodies. If these are positive, the patient should have a small bowel biopsy to confirm the diagnosis. (Our patient underwent the tests in reverse order.)

**Antiendomysial antibodies (EMA)** are immunoglobulin (Ig)A autoantibodies directed against the fibrous tissue surrounding smooth muscle bundles. The test for antiendomysial antibodies has a sensitivity approaching 99% and a specificity of 100% in diagnosing celiac sprue.<sup>2</sup> However, the test may be falsely negative in the 2% of patients with celiac sprue who have IgA deficiency.

**Antigliadin antibodies (AGA)** are also important in diagnosing celiac sprue. The exact tissue component against which antigliadin antibodies are directed has not been determined. The antigliadin antibody assay is easier to perform than the antiendomysial antibody assay, but less accurate (sensitivity 92%, specificity 90%).<sup>2</sup> Both IgG and IgA levels are reported, but IgG is less specific.

**Gluten challenge** with repeat small bowel biopsy is no longer needed to diagnose celiac sprue.

#### Case continued

Before the antibody studies returned, a radiographic study of the small bowel was ordered to further rule out an occult source for blood loss. This revealed an intussusception in the middle small bowel with suggestion of a 4-cm mass as the lead point. Exploratory laparoscopy and laparotomy were performed. However, the bowel was normal. The patient's antibody stud-

ies returned and were: antiendomysial IgA > 1:40 (normal < 1:5), antigliadin IgG 46 U (normal < 10; indeterminate 10–15), and antigliadin IgA > 120 U (normal < 15).

These results confirmed the diagnosis of celiac sprue. The patient met with a nutritionist, who taught him how to follow a gluten-free diet. After 3 months of the new diet, his antibody and iron studies were: antiendomysial IgA < 1:5, antigliadin IgG 61 U, antigliadin IgA > 120 U, ferritin 3.1 ng/mL, serum iron 29 µg/dL, and iron saturation 7%.

Cataldo et al<sup>6</sup> found IgA antigliadin antibodies disappeared by 6 months in celiac patients following a strict gluten-free diet, while antiendomysial antibodies disappeared by 12 to 18 months. This patient's antiendomysial antibodies were already negative at 3 months, but his IgA antigliadin antibodies remained high. In this situation, rechecking the IgA antigliadin antibodies at 6 months may prove helpful in determining dietary compliance or unintentional gluten ingestion.

Iron therapy was restarted, and the patient was encouraged to review his diet for gluten. After 2 months of iron therapy, the ferritin increased to 16.8 ng/mL and the serum iron increased to 79 µg/dL. The patient contacted the Celiac Sprue Association for dietary support and is doing well. (For a list of support groups nationwide, see <http://www.celiac.com/contacts2.html>.) Iron supplementation will be stopped once his iron indices have normalized.

### ■ REFERENCES

1. Trier JS. Celiac sprue. *N Engl J Med* 1991; 325:1709–1719.
2. Corazza GR, Valentini RA, Andreani ML, et al. Subclinical coeliac disease is a frequent cause of iron-deficiency anaemia. *Scand J Gastroenterol* 1995; 30:153–156.
3. Bullen A, Hall R, Gowland G, Rajah S, Losowsky M. Hyposplenism, adult coeliac disease, and autoimmunity. *Gut* 1980; 21:28–33.
4. Rockey DC, Cello JP. Evaluation of the gastrointestinal tract in patients with iron-deficiency anemia. *N Engl J Med* 1993; 329:1691–1695.
5. Ackerman Z, Eliakim R, Stalnikowicz R, Rachmilewitz D. Role of small bowel biopsy in the endoscopic evaluation of adults with iron deficiency anemia. *Am J Gastroenterol* 1996; 91:2099–2102.
6. Cataldo F, Ventura A, Lazzari R, Balli F, Nassimbeni G, Marino V. Antiendomysium antibodies and coeliac disease: solved and unsolved questions. An Italian multicentre study. *Acta Paediatr* 1995; 84:1125–1131.

**ADDRESS:** John J. Vargo II, MD, Department of Gastroenterology, 540, The Cleveland Clinic Foundation, 9500 Euclid Avenue, Cleveland, OH 44195.

**Antiendomysial and antigliadin antibodies are sensitive and specific for celiac sprue**