

**CHRISTOPHER L. TISDEL, MD**Department of Orthopaedic Surgery,  
Cleveland Clinic**BRIAN G. DONLEY, MD**Department of Orthopaedic Surgery,  
Cleveland Clinic**JAMES J. SFERRA, MD**Department of Orthopaedic Surgery,  
Cleveland Clinic

# Diagnosing and treating plantar fasciitis: A conservative approach to plantar heel pain

## ABSTRACT

Plantar fasciitis is the most common cause of pain at the weight-bearing surface of the heel, and may coexist with other sources of heel pain. This has led to a confusing array of treatment strategies, including surgery. We offer a simple, effective diagnostic and treatment algorithm that emphasizes nonsurgical treatment options for this often frustrating condition.

## KEY POINTS

Plantar fasciitis, the most common cause of plantar heel pain, is an overuse injury causing inflammation at the attachment of the plantar fascia to the medial tubercle of the calcaneus.

Physical examination of a patient with plantar heel pain often reveals a tight Achilles tendon, as noted by limited ankle dorsiflexion with the knee in extension. Swelling of the heel is not common and, when associated with painful medial-lateral compression of the calcaneus, may suggest a stress fracture.

Regular stretching of the Achilles tendon and plantar fascia is the critical part of any treatment program for plantar fasciitis. Stretching three to five times a day eventually rehabilitates the tight, chronically inflamed fascia.

**A**LTHOUGH CLINICIANS TRY many different approaches to relieve heel pain associated with plantar fasciitis, the most common cause of plantar heel pain in adults, we encourage a conservative treatment approach in these patients, one that emphasizes protection and rehabilitation of the affected tissue in the heel.

Surgery is a treatment option in plantar fasciitis; however, it is usually not necessary because of the success of nonsurgical techniques. We have found that offering a safe and effective treatment scheme to an informed patient commonly resolves this frustrating condition without surgery.

## CAUSES OF HEEL PAIN

Plantar heel pain has many potential causes,<sup>1–5</sup> including:

- Plantar fasciitis
- Calcaneal stress fracture
- Fat pad atrophy
- Compressive and metabolic neuropathy
- Infection
- Ischemia
- Tumors.

## Plantar fasciitis

The most common cause of heel pain is plantar fasciitis, an overuse injury causing inflammation. It occurs at the attachment of the plantar fascia to the medial tubercle of the calcaneus (**FIGURE 1**) and has been associated with excessive walking or running, as well as with middle age, obesity, and biomechanical disorders such as pes cavus, pes planus, and tight



Achilles tendon. Repeated stress to the plantar fascia origin leads to micro-tears and chronic inflammatory changes (necrosis, fibrosis, chondroid metaplasia).<sup>2,5</sup> The normally resilient fascia becomes stiffened and prone to re-injury, thus setting up a vicious circle of persistent pain.

### Other causes of plantar heel pain

**Nerve impingement.** The nerve to the abductor digitorum quinti muscle, which courses just superior to the origin of the plantar fascia, may become impinged. This can lead to pain that is often mistaken for plantar fasciitis. However, complicating the differential diagnosis, nerve impingement can also coexist with plantar fasciitis.<sup>4,6</sup>

**Fat pad atrophy.** Atrophy of the plantar heel fat pad, secondary to aging or to overzealous corticosteroid use, can produce a more central heel pain, often a separate entity from plantar fasciitis.

**Bone spur.** Many patients visit their physician complaining of pain caused by a "bone spur" (calcaneal osteophyte), and many physicians presume that bone spurs are the cause of plantar heel pain. However, this is misleading: 50% of patients with heel pain do not have a bone spur, and 15% of non-painful adult heels do have a spur.

Although rarely the cause of plantar heel pain, a bone spur within the flexor digitorum brevis muscle dorsal to the plantar fascia (FIGURE 1) is present radiographically in about 50% of patients with heel pain.<sup>2,5</sup> Pathologic changes have been observed at the origin of the plantar fascia from surgical specimens, located just plantar to the region of spur formation.<sup>2,5</sup> However, even if a bone spur is present, it should not influence the treatment protocol.

## ■ DIAGNOSIS

### Detailed history

A detailed history will often provide enough information to make the diagnosis of plantar fasciitis, and physical examination will confirm it. A complete description of the pain is essential. Patients typically describe their plantar heel pain in the following ways:

- **Deep aching pain** (like a "bruise") under the heel brought on by standing or

walking and relieved with rest.

- **"Start-up pain,"** ie, pain exacerbation with initial weight-bearing in the morning or when rising from a chair, is typical of plantar fasciitis. Start-up pain is improved after a few minutes of walking, but pain will worsen again with prolonged standing.

- **Pain of gradual onset.** Patients often describe a gradual onset of pain, present for weeks to months prior to seeking attention.

- **Acute trauma or swelling** is not common; however, further questioning may indicate a change of activity level or a change of shoe wear preceding pain onset. Pain associated with significant swelling, occurring primarily at rest or without "start-up" qualities, is not suggestive of plantar fasciitis. A complete history may elicit conditions associated with heel pain, such as diabetes, inflammatory arthropathies, and spinal disorders.<sup>1-3,7</sup>

### Examination of the foot and ankle: seeking sources of pain

The physical examination in suspected plantar fasciitis begins with observing the exposed foot and ankle during gait and stance. Record any deviations from a normal foot type and gait.

In the directed foot examination of patients with plantar heel pain, the clinician can elicit pain by palpating the origin of the plantar fascia (FIGURE 1). Pain may be exacerbated by dorsiflexing the ankle and the metatarsal phalangeal joints, which stretches the plantar fascia. Pain may also be noted more medially, near the origin of the abductor hallucis muscle, and may extend distally along the plantar fascia.

A tight Achilles tendon, as noted by limited ankle dorsiflexion with the knee in extension, is commonly seen with this condition.<sup>1-3</sup>

Swelling is not common and, when associated with painful medial-lateral compression of the calcaneus, suggests a stress fracture.

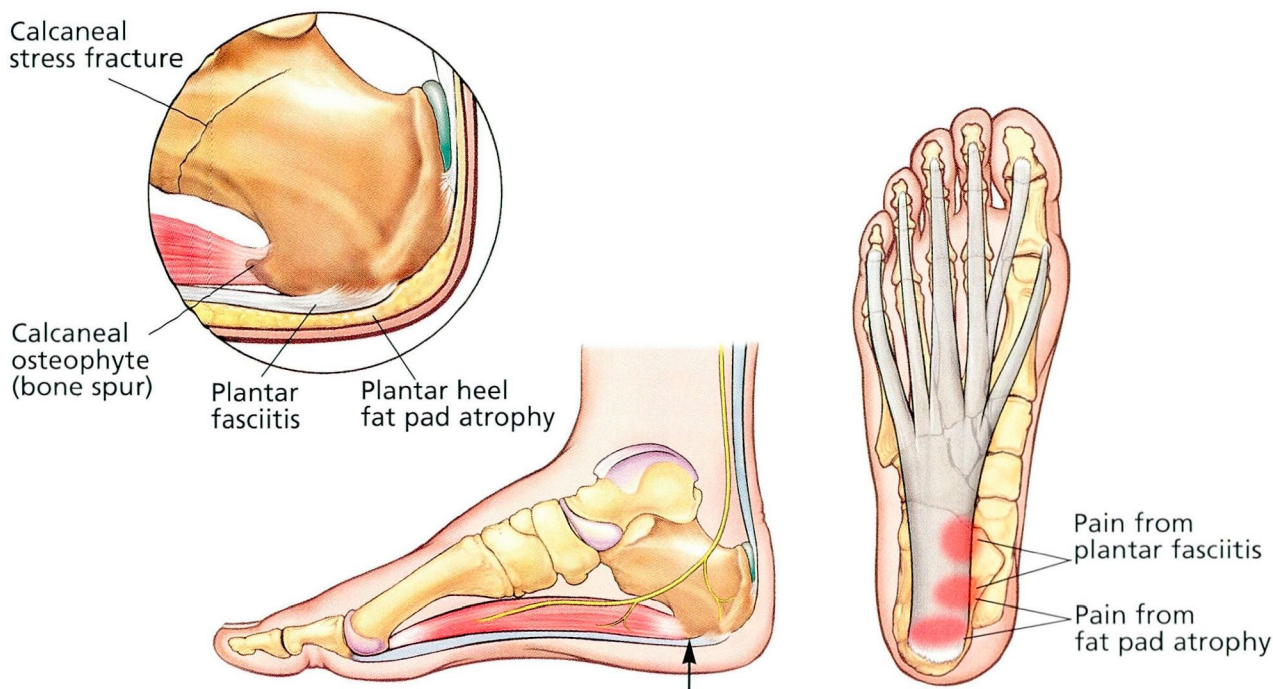
Pain posterior to the origin of the plantar fascia is more likely secondary to fat pad atrophy or periostitis.

A complete foot and ankle examination that includes neurovascular assessment should rule out most other causes of heel pain. An exam of other organ systems (ie, eyes, mouth, spine, joints) is appropriate when other pain etiologies are suspected.

**Plantar fasciitis  
is usually an  
overuse injury**



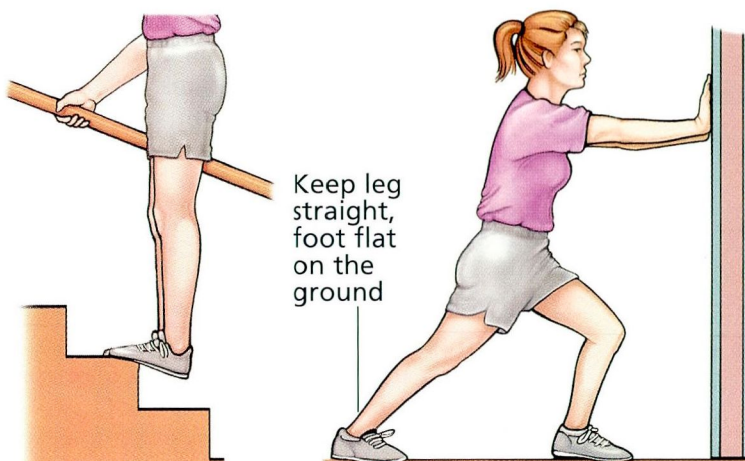
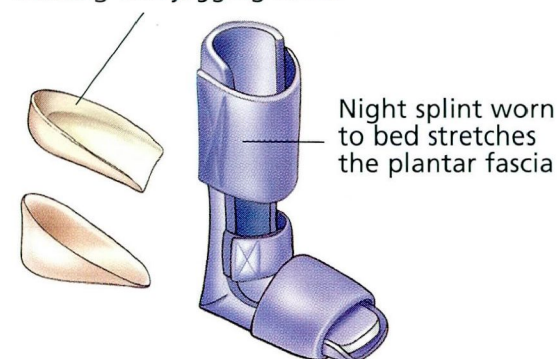
## ■ Plantar fasciitis: Anatomy, diagnosis, treatment



**ANATOMY** Heel pain has many possible causes, including calcaneal bone spurs, stress fractures, and atrophy of the calcaneal fat pad. However, the most common cause is plantar fasciitis, a combination of overuse injury and an inflammatory process, occurring at the attachment of the plantar fascia to the medial tubercle of the calcaneus (arrow).

**DIAGNOSIS** Palpation of the origin of the plantar fascia elicits the pain of plantar fasciitis; dorsiflexion of the ankle and the metatarsal phalangeal joints may exacerbate the pain. Pain posterior to the origin of the plantar fascia is more likely secondary to fat pad atrophy or periostitis.

Silicone or plastic heel pad or cup adds comfort to walking and jogging shoes



**TREATMENT** Options for plantar fasciitis are primarily conservative and include plastic heel pads or cups, a splint to be worn at night, and stretching exercises to be done three to five times a day.

FIGURE 1



**Diagnostic studies:****When is further investigation appropriate?**

Plantar fasciitis is a diagnosis made by the history and physical examination. When other sources of pain are possible, ancillary tests may be appropriate. Lateral and axial radiographs of the heel are typically normal but may be used to rule out fractures, rheumatologic conditions, or tumors.<sup>8</sup>

**Bone scan.** When patients present with atypical or chronic symptoms, a triple-phase bone scan may provide useful information. Plantar fasciitis is confirmed by uptake at the origin of the fascia.<sup>1-3</sup> Calcaneal stress fractures will reveal intense uptake throughout the bone. A negative scan may suggest neurogenic or other extraskeletal pain sources.

**Blood work** may be helpful when considering inflammatory arthropathies or infection.<sup>1-3</sup> A standard rheumatoid panel that includes a complete blood count with differential, erythrocyte sedimentation rate, antinuclear antibodies, and rheumatoid factor can supplement findings of the history and examination.

**Electromyography** and nerve conduction studies can provide objective information regarding nerve involvement when dysesthesias are prominent; however, these tests can be uncomfortable and are often negative until late nerve pathology develops.<sup>4</sup>

## ■ TREATMENT OF PLANTAR FASCIITIS

Treatment options for plantar fasciitis vary widely, but treatment should always begin with a combination of nonsurgical modalities. Treatment guidelines are available, based on recent studies that asked patients to rate various techniques.<sup>2,7,9,10</sup> We recommend the following treatment scheme, which usually resolves pain in 2 to 6 months.<sup>2,7,10</sup>

**Initial conservative strategies**

**Inform the patient.** Begin treatment by educating the patient as to the cause of plantar heel pain and how he or she can actively participate in its cure, such as performing specific exercises (FIGURE 1).

**Supportive shoes.** First, emphasize a change to more supportive shoes (eg, walking or jogging shoes) for routine activities. Patients can insert over-the-counter soft, pli-

able plastic (Silastic) heel pads or protective heel cups into these shoes for more comfort (FIGURE 1). Walking barefoot or in slippers should be avoided.

**Non-weight-bearing exercise.** Suggest that patients change their activities to avoid aggravating factors until the pain resolves. Switching from weight-bearing activities (eg, walking, jogging) to non-weight-bearing aerobic exercise (eg, biking, swimming) can be helpful.

**Stretching.** We believe stretching is the critical part of any treatment program for plantar fasciitis. Regularly stretching the Achilles tendon and plantar fascia eventually rehabilitates the tight, chronically inflamed fascia. Prescribe patients a simple stretching routine, which they should do three to five times a day (FIGURE 1).<sup>2,10</sup> Be sure to warn patients that stretching may exacerbate symptoms for 1 to 3 weeks, but encourage them to continue until the pain resolves.

**Nonsteroidal anti-inflammatory drugs** often help speed pain relief. The patient may need to take the medication for several weeks or months until pain resolves, so monitoring against side effects (eg, gastritis, peptic ulcers) is important.

**Nighttime splint.** If morning start-up pain is significant or resistant to the above treatments, a splint can be worn to bed to maintain plantar fascia stretch (FIGURE 1).

**What to do if initial treatment fails**

**Corticosteroid injection.** For patients slow to improve, a corticosteroid injection near the plantar fascia origin may provide adequate pain relief. However, multiple injections are discouraged as they may cause fat pad atrophy or plantar fascia rupture.<sup>11</sup> In recalcitrant cases, patients may need to take time off work or use a walking cast for 4 to 6 weeks,<sup>10</sup> or both.

**Custom orthotic.** If the patient has coexisting biomechanical foot problems such as pes planus or cavus, a custom foot orthotic may be beneficial. We recommend a semirigid orthotic that supports the longitudinal arch, takes some of the weight-bearing load away from the plantar calcaneus, and absorbs weight-bearing stresses. However, only very few patients with plantar fasciitis require custom orthotics.<sup>10</sup>

**Multiple injections of corticosteroids may cause fat pad atrophy or plantar fascia rupture**



**Surgical options.** Nonsurgical techniques are successful in over 90% of our patients. If pain persists after 6 to 12 months of an exhaustive conservative program, then surgery may be recommended.

When indicated, a partial release of the medial plantar fascia, along with decompression of the nerve to the abductor digiti quinti may effect a cure. Advise the patient that a prolonged recovery after surgery may be expected, with cure rates in the 80% to 90% range.<sup>1-3,5</sup>

## REFERENCES

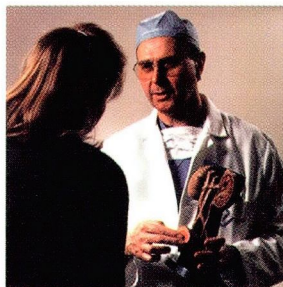
1. **Bordelon RL.** Heel pain. In: Mann RA, Coughlin MJ, editors. *Surgery of the Foot and Ankle*, 6th ed. St. Louis: Mosby-Year Book, Vol 2, 1993:837-857.
2. **Gill LH.** Plantar fasciitis: Diagnosis and conservative management. *J Am Acad Orthopaed Surg* 1997; 5:109-117.
3. **Schepesis AA, Leach RE, Gorzyca J.** Plantar fasciitis. Etiology, treatment, surgical results and review of literature *Clin Orthop* 1991; 266:185-196.
4. **Schon LC, Glennon TP, Baxter DE.** Heel pain syndrome: Electrodiagnostic support for nerve entrapment. *Foot Ankle* 1993; 14:129-135.
5. **Tountas AA, Fornasier VL.** Operative treatment of subcalcaneal pain. *Clin Orthop* 1996; 332:170-178.
6. **Baxter DE, Pfeffer GB.** Treatment of chronic heel pain by surgical release of the first branch of the lateral plantar nerve. *Clin Orthop* 1992; 279:229-236.
7. **Wolgin M, Cook C, Graham C, Mauldin D.** Conservative treatment of plantar heel pain: Long term follow-up. *Foot Ankle Int* 1994; 15:97-102.
8. **Amis J, Jennings L, Graham D, Graham CE.** Painful heel syndrome: Radiographic and treatment assessment. *Foot Ankle* 1988; 9:91-95.
9. **Tisdell CL, Harper MC.** Chronic plantar heel pain: Treatment with a short leg walking cast. *Foot Ankle Int* 1996; 17:41-42.
10. **Pfeffer G.** AOFAS Heel Pain Study Group. Paper presented at: Winter Meeting of the American Orthopaedic Foot and Ankle Society; March 1997; San Francisco.
11. **Sellman JR.** Plantar fascia rupture associated with corticosteroid injection. *Foot Ankle Int* 1994; 15(7):376-381.

**ADDRESS:** Christopher L. Tisdell, MD, Department of Orthopaedic Surgery, A41, The Cleveland Clinic Foundation, 9500 Euclid Avenue, Cleveland, OH 44195.

## CME ANSWERS

Answers to the CREDIT TEST on page 255 of this issue

1 D 2 A 3 C 4 B 5 D 6 C 7 A 8 A 9 C 10 C




# LET US HEAR FROM YOU

■ Let us hear your opinions about the *Cleveland Clinic Journal of Medicine*.

■ Do you like current articles and sections?

■ What topics would you like to see covered and how can we make the Journal more useful to you?




PHONE 216.444.2661

FAX 216.444.9385

E-MAIL [ccjm@cesmtp.ccf.org](mailto:ccjm@cesmtp.ccf.org)

WWW <http://www.ccf.org/ed/ccjm/ccjhome.htm>

CLEVELAND CLINIC JOURNAL OF MEDICINE  
The Cleveland Clinic Foundation  
9500 Euclid Avenue, EE37  
Cleveland, Ohio 44195



DEDICATED TO LIFELONG LEARNING  
CLEVELAND CLINIC JOURNAL OF MEDICINE

