

J. BRAD MORROW, MD

Department of Gastroenterology, Cleveland Clinic

DARWIN L. CONWELL, MD

Director, Pancreas Clinic, Department of
Gastroenterology, Cleveland Clinic

A 55-year-old man with idiopathic recurrent pancreatitis

A 55-FIVE-YEAR-OLD male business executive presents to the gastroenterology clinic for further evaluation of recurrent episodes of acute pancreatitis.

In the previous 18 years, he has had seven separate bouts of severe abdominal pain diagnosed both clinically and biochemically as acute pancreatitis. These included two episodes of acute pancreatitis in the prior 8 months. Each time, he was treated with supportive therapy, including intravenous fluids, bowel rest, and parenteral narcotics, and his symptoms resolved completely. None of the episodes were accompanied by jaundice.

Several ultrasound scans of the abdomen were done during the course of these attacks, and each time they were negative for gallstones or biliary ductal dilatation. Computed tomographic (CT) scans of the abdomen during these episodes revealed only pancreatic edema and mild pancreatic ductal dilatation in the head of the pancreas. Endoscopic retrograde cholangiopancreatography (ERCP) performed 15 years earlier revealed nothing remarkable.

Other than the recurrent bouts of pancreatitis, the past medical history is unremarkable. The patient denies any recent weight loss, and he is asymptomatic at the time of his evaluation. His only medication is ranitidine, which he takes occasionally for symptoms of dyspepsia. There is no family history of pancreatitis or pancreatic carcinoma. He denies any ethanol consumption. He does not smoke tobacco or use illicit drugs.

■ PHYSICAL EXAMINATION

On examination, the patient is a well-appearing man, without scleral icterus. Examinations of the heart and lung are normal. The abdomen

is soft and nontender with no palpable masses. The liver and spleen are not enlarged. The extremities are without clubbing or edema. Neurologic examination is normal.

■ LABORATORY DATA

The results of a complete blood count and blood chemistry panel (including liver biochemistries) are within normal limits.

■ DIFFERENTIAL DIAGNOSIS

1 Which of the following is *not* a possible cause of this patient's recurrent pancreatitis?

- ☐ Sphincter of Oddi dysfunction
- ☐ Biliary microlithiasis
- ☐ Hypertriglyceridemia
- ☐ Diabetes mellitus
- ☐ Hypercalcemia

Gallstones and alcohol abuse are the two most common causes of acute pancreatitis, accounting for approximately 70% of all cases. Another 10% of cases can be explained by miscellaneous causes such as sphincter of Oddi dysfunction, hypertriglyceridemia, or hypercalcemia (**TABLE 1**). This leaves up to 20% of patients presenting with acute pancreatitis that is characterized as "idiopathic."

Recently, biliary sludge (or microlithiasis) has been implicated as the most common cause of idiopathic recurrent pancreatitis. Biliary sludge consists of a suspension of either cholesterol monohydrate crystals or calcium bilirubinate granules in liquid bile (**FIGURE 1**). It often appears on ultrasonography as layered, low-amplitude echoes without the shadowing associated with true gallstones. Clinically,

Up to 20% of
cases of acute
pancreatitis are
idiopathic

physicians should suspect microlithiasis in any patient with unexplained acute pancreatitis, especially in those with advanced age or abnormal liver chemistries during an acute episode.

Diabetes mellitus is not known to cause acute pancreatitis.

EVALUATION FOR MICROLITHIASIS

2 If you suspect microlithiasis, what is the single best test to make this diagnosis?

- ☐ Magnetic resonance imaging (MRI) of the abdomen
- ☐ Hepatobiliary scintigraphy
- ☐ Serum lipid profile
- ☐ Bile collection for microscopic analysis
- ☐ Ultrasonography of the abdomen

Microscopic evaluation of the bile for cholesterol crystals or calcium bilirubinate granules is the gold standard for diagnosing microlithiasis or biliary sludge. Ultrasonography is a noninvasive and important initial test; however, it may miss up to 50% of cases of clinically important microlithiasis. MRI, scintigraphy, and lipid tests have no role in the evaluation for microlithiasis.

Bile can be collected endoscopically or via duodenal intubation with a Dreiling tube. In either case, the patient must fast overnight and then receive an intravenous dose of cholecystokinin to stimulate gallbladder emptying before bile is collected. The collected bile is then sent to the laboratory for microscopic inspection for crystals.

As part of our standard approach, our patient underwent ERCP to evaluate his pancreatic ductal anatomy and rule out a structural etiology of his recurrent episodes of acute pancreatitis. During the procedure, biliary fluid was collected as described above. Microscopic analysis of the bile revealed numerous cholesterol monohydrate crystals (FIGURE 1). Based on this analysis, the etiology of this patient's recurrent pancreatitis was felt to be microlithiasis.

THERAPY

3 Which of the following is *not* a therapeutic option to prevent recurrent episodes of

TABLE 1

Causes of acute pancreatitis

Structural

Gallstones
Microlithiasis
Pancreas divisum
Ampullary tumor
Periampullary diverticula
Sphincter of Oddi dysfunction

Toxins

Ethanol
Medications
Methanol
Scorpion venom
Organophosphate poisoning

Metabolic

Hypertriglyceridemia
Hypercalcemia

Traumatic

Endoscopic retrograde
cholangiopancreatography
Blunt abdominal trauma

Miscellaneous

Infection (viruses, parasites, bacteria)
Crohn's disease
Idiopathic

pancreatitis due to microlithiasis?

- ☐ Cholecystectomy
- ☐ Endoscopic biliary sphincterotomy
- ☐ Medical dissolution therapy with ursodiol
- ☐ Gemfibrozil

Cholecystectomy, endoscopic biliary sphincterotomy, and ursodiol therapy are all reasonable options once microlithiasis has been detected, as they have all been shown to significantly reduce the recurrence rate of acute pancreatitis in patients with biliary microlithiasis.

Cholecystectomy is considered the treatment of choice for patients who are good surgical candidates. It is the best studied option and can usually be performed laparoscopically with minimal morbidity.

Lee et al¹ described 21 patients with recurrent pancreatitis and microlithiasis, of whom 6 underwent cholecystectomy and 4 underwent biliary sphincterotomy. The other 11 patients had no intervention. *None* of the 6 cholecystectomy patients and only 1 of the 4

**Ultrasound
will detect only
50% of cases of
microlithiasis**

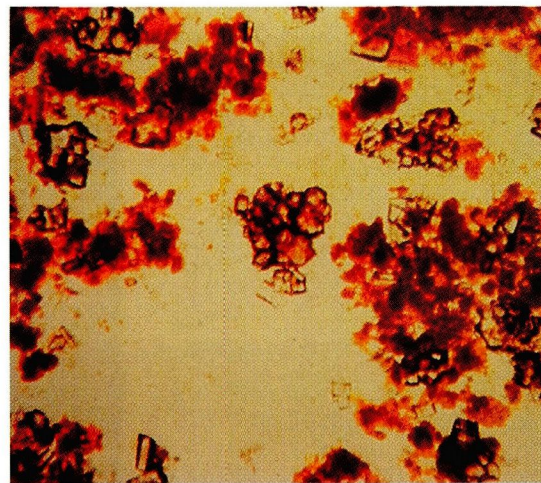
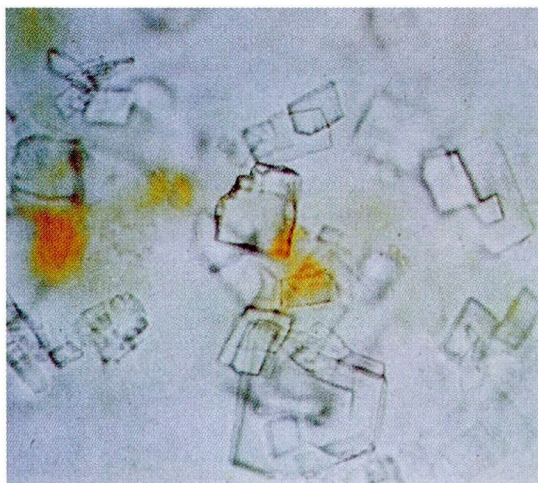


FIGURE 1. Microscopic features of biliary sludge ($\times 200$). Left, biliary sludge consisting predominantly of cholesterol crystals. Note the typical rhomboidal plates. Right, biliary sludge containing predominantly calcium bilirubinate granules. Some cholesterol crystals are present, but they are outnumbered by the many reddish-brown granules composed of calcium bilirubinate.

SOURCE: LEE SP, NICHOLLS JF, PARK HZ. BILIARY SLUDGE AS A CAUSE OF ACUTE PANCREATITIS. *N ENGL J MED* 1992; 326:589–593. COPYRIGHT 1992 MASSACHUSETTS MEDICAL SOCIETY. ALL RIGHTS RESERVED.

sphincterotomy patients had recurrent episodes of pancreatitis on follow-up (up to 7 years). In contrast, 8 (73%) of the 11 patients who had no therapy suffered recurrent bouts of acute pancreatitis.

In a similar series of patients, Ros et al² reported that 17 (94%) of 18 patients who underwent cholecystectomy did not have any recurrent bouts of acute pancreatitis at a mean follow-up of 36 months.²

Ursodiol is a naturally occurring bile acid used clinically to dissolve radiolucent gallstones. It has been used successfully to prevent further episodes of acute pancreatitis in patients whose collected bile contained cholesterol crystals.² However, ursodiol therapy requires several months to dissolve crystals and stones, and stones recur within 5 years in up to 50% of patients. We therefore recommend its use only in patients not felt to be candidates for cholecystectomy.

Gemfibrozil is a lipid-modulating agent used in patients with pancreatitis from hypertriglyceridemia, but not in cases of pancreatitis due to biliary crystals.

■ FOLLOW-UP

Our patient successfully underwent laparoscopic cholecystectomy and had no further

episodes of acute pancreatitis at 12 months follow-up.

■ SUMMARY POINTS

- Gallstones and alcohol abuse account for 70% of cases of acute pancreatitis.
- Microlithiasis (or biliary sludge) is a common, yet often unrecognized cause of “idiopathic” pancreatitis.
- The diagnosis of microlithiasis can be made by either ultrasonography or microscopic examination of collected bile, but ultrasonography is less sensitive.
- Once microlithiasis has been detected, cholecystectomy should be performed to prevent further attacks of acute pancreatitis.
- Endoscopic biliary sphincterotomy or oral dissolution therapy with ursodiol are options in patients not felt to be surgical candidates.

■ REFERENCES

1. Lee SP, Nicholls JF, Park HZ. Biliary sludge as a cause of acute pancreatitis. *N Engl J Med* 1992; 326:589–593.
2. Ros E, Bru C, Garcia-Puges A, Valderrama R. Occult microlithiasis in idiopathic acute pancreatitis: prevention of relapses by cholecystectomy or ursodeoxycholic acid therapy. *Gastroenterol* 1991; 101:1701–1709.

ADDRESS: Darwin L. Conwell, MD, Department of Gastroenterology, S40, The Cleveland Clinic Foundation, 9500 Euclid Avenue, Cleveland, OH 44195.

Cholecystectomy prevents further attacks of pancreatitis due to microlithiasis