



The Clinical Picture

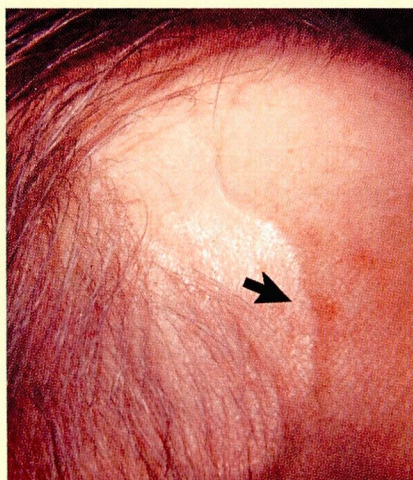

FIGURE 1 Swollen temporal artery (arrow), occasionally seen in giant cell arteritis.

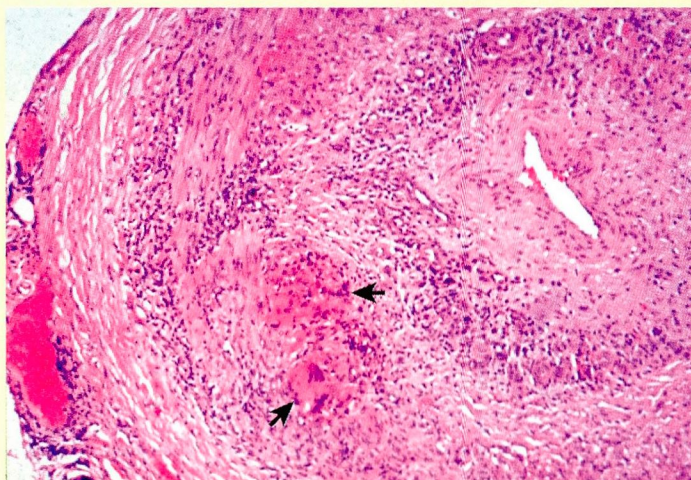


FIGURE 2 Inflammatory changes in all the layers of the vessel wall, intimal proliferation, and giant cells (arrows) can be seen in this biopsy sample from the tunica media.

Giant cell arteritis: Biopsy may not be diagnostic

PRESENTATION

Polymyalgia rheumatica and giant cell arteritis generally occur in patients over age 50, with the mean age at occurrence being approximately 70 years. From 15% to 50% of patients with polymyalgia rheumatica develop giant cell arteritis, for which the most common symptom is severe uncharacteristic headache. A minority of patients exhibit swollen temporal arteries, as seen in the patient shown (FIGURE 1).

BIOPSY AND DIAGNOSIS

Many cases of giant cell arteritis in elderly patients can be diagnosed clinically, on the basis of signs and symptoms such as atypical headaches, tender temporal artery, visual aberration or blindness, pain on chewing, and a high erythrocyte sedimentation rate. Biopsy can confirm the diagnosis of giant cell arteritis (FIGURE 2), but it is diagnostic in only approximately 50% of cases. Part of the reason for this low diagnostic yield is that the inflammation of the vessel is often not uniform, with normal and abnormal areas interspersed.