



ROSSANA D. DANESE, MD
Dr. Danese is a staff member of the
Department of Endocrinology at the
Cleveland Clinic.

Evaluating adrenal incidentalomas

Adrenal incidentalomas are detected on 1% to 2% of all abdominal CT scans

The development of computed tomographic (CT) scanning made it possible to clearly see the adrenal glands radiographically for the first time. However, CT scanning and magnetic resonance imaging (MRI) often reveal unsuspected adrenal masses during evaluation for nonadrenal disease. These incidentally detected masses have been dubbed “adrenal incidentalomas.” Adrenal incidentalomas are common and are detected on approximately 1% to 2% of all abdominal CT scans (FIGURE 1).

What constitutes the appropriate evaluation of adrenal incidentalomas is controversial. In the absence of clear guidelines, we need to answer two initial questions:

- Is this lesion malignant, and if so, is it primary or metastatic cancer?
- Is it secretory (producing excess hormone) or nonsecretory?

To answer these questions, a thorough history and physical examination, appropriate biochemical testing, and radiographic imaging are all essential (FIGURE 2).

BENIGN OR MALIGNANT?

Benign adenomas, either functioning (ie, secreting hormones) or nonfunctioning, account for approximately 50% of all adrenal incidentalomas. Other lesions such as myelolipomas and cysts are not clinically significant. Pseudoadrenal masses (lesions arising from the pancreas, spleen, or kidney) may be clinically insignificant. The differential diagnosis, however, includes lesions with high morbidity and mortality rates: pheochromocytoma, metastases, and adrenal carcinoma.¹

Such lesions account for about 25% of incidentalomas.

Pheochromocytoma is discussed in the section on hormone-secreting tumors, below.

Metastases from malignant melanoma or from cancers of the breast, lung, kidney, and gastrointestinal tract often develop in the adrenal gland. Therefore, most experts recommend a mammogram, chest radiograph, and at least guaiac card testing for all patients with adrenal incidentalomas who have no known malignant disease.

Primary cancers of the adrenal gland are much less common than metastatic disease and are usually quite large when detected—it is not unusual for an adrenal carcinoma to be 10 cm in diameter when detected.² In contrast, adrenal adenomas are usually no larger than 4 cm. However, if size is used as the only criterion, smaller carcinomas, metastases, and pheochromocytoma can be mistaken for adenoma.

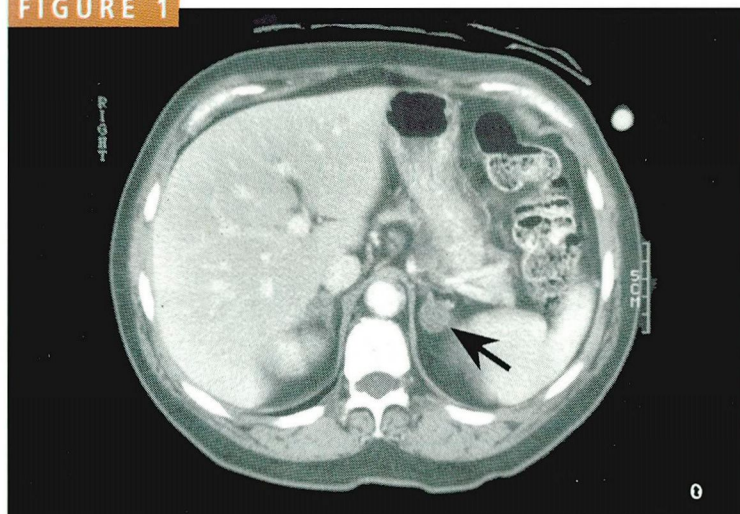
Although physicians vary in what they consider a “large” mass, in general, resection is recommended for any mass larger than 4 cm.^{3–6}

IS THERE EXCESS HORMONE PRODUCTION?

All patients with an adrenal incidentaloma should be clinically evaluated for evidence of excess catecholamines, mineralocorticoids, glucocorticoids, and androgens. If the history and physical suggest excess hormone production (see below), the patient should undergo



FIGURE 1



An abdominal CT scan with an adrenal incidentaloma (arrow).

Even in the absence of signs or symptoms, all patients with adrenal incidentalomas should be screened for pheochromocytoma.

appropriate laboratory tests. However, even in the absence of signs or symptoms, all patients with adrenal incidentalomas should be screened for pheochromocytoma.

Diseases of excess androgen production

DHEA-S, a sulfuric acid ester of dehydroepiandrosterone (DHEA), is the androgen primarily secreted by the adrenal glands. Excess secretion is readily apparent clinically in women—acne, hirsutism, and menstrual irregularities suggest a high DHEA-S level—but signs are absent in men. Patients need to be screened only if the clinical signs and symptoms suggest a high level.

Adrenal hyperplasia, carcinoma, and adenoma can all cause excess androgen production.

Primary hyperaldosteronism

If a patient with an incidentaloma is hypertensive and is hypokalemic, including while taking diuretics, he or she should have renin and aldosterone levels measured, followed by a salt-loading test. If the patient has primary aldosteronism, the aldosterone response will not be suppressed.

Patients with normal blood pressure almost never have hyperaldosteronism, and screening for the condition is not necessary.

Pheochromocytoma

Patients with pheochromocytoma may have the classic symptoms of paroxysmal hypertension, headaches, palpitations, and diaphoresis. Other symptoms include weight loss, tachycardia, anxiety, and orthostasis. However, pheochromocytoma is often clinically silent.

Because pheochromocytoma has a high rate of morbidity and mortality, all patients with an incidentaloma should provide a 24-hour urine specimen for measurement of metanephrines and catecholamines.⁷

Cushing's syndrome

Cushing's syndrome occurs when the adrenal gland produces excess cortisol. Some of the clinical signs are central obesity with atrophy of the extremities, bruising, moon facies, hirsutism, and supraclavicular fat.

If one suspects Cushing's syndrome clinically, a 24-hour urine sample for a free-cortisol assay should be obtained. Another screening test is the overnight 1-mg dexamethasone suppression test. The patient takes 1 mg dexamethasone at 11 PM, and the plasma cortisol level is measured at 8 AM the next morning. A cortisol level above 5 µg/dL suggests that the mass may be functioning, although false-positive results are not uncommon.

Preclinical Cushing's syndrome. Patients with preclinical Cushing's syndrome lack overt signs or symptoms of Cushing's syndrome, but do have one or more indications of hypothalamic-pituitary-adrenal axis dysfunction:

- Absent diurnal rhythm (failure to decrease cortisol secretion at night).
- Abnormal dexamethasone suppression test results.
- Elevated urine free cortisol levels.
- Increased uptake of NP-59 (radio-labeled cholesterol), on the same side as the mass.
- Adrenal insufficiency after adrenalectomy.⁸⁻¹³

Several investigators have recommended that *all* patients with incidentalomas undergo an overnight dexamethasone suppression test to exclude preclinical Cushing's syndrome. Unlike in Cushing's syndrome, the urinary

FIGURE 2

ALGORITHM FOR EVALUATING ADRENAL INCIDENTALOMAS

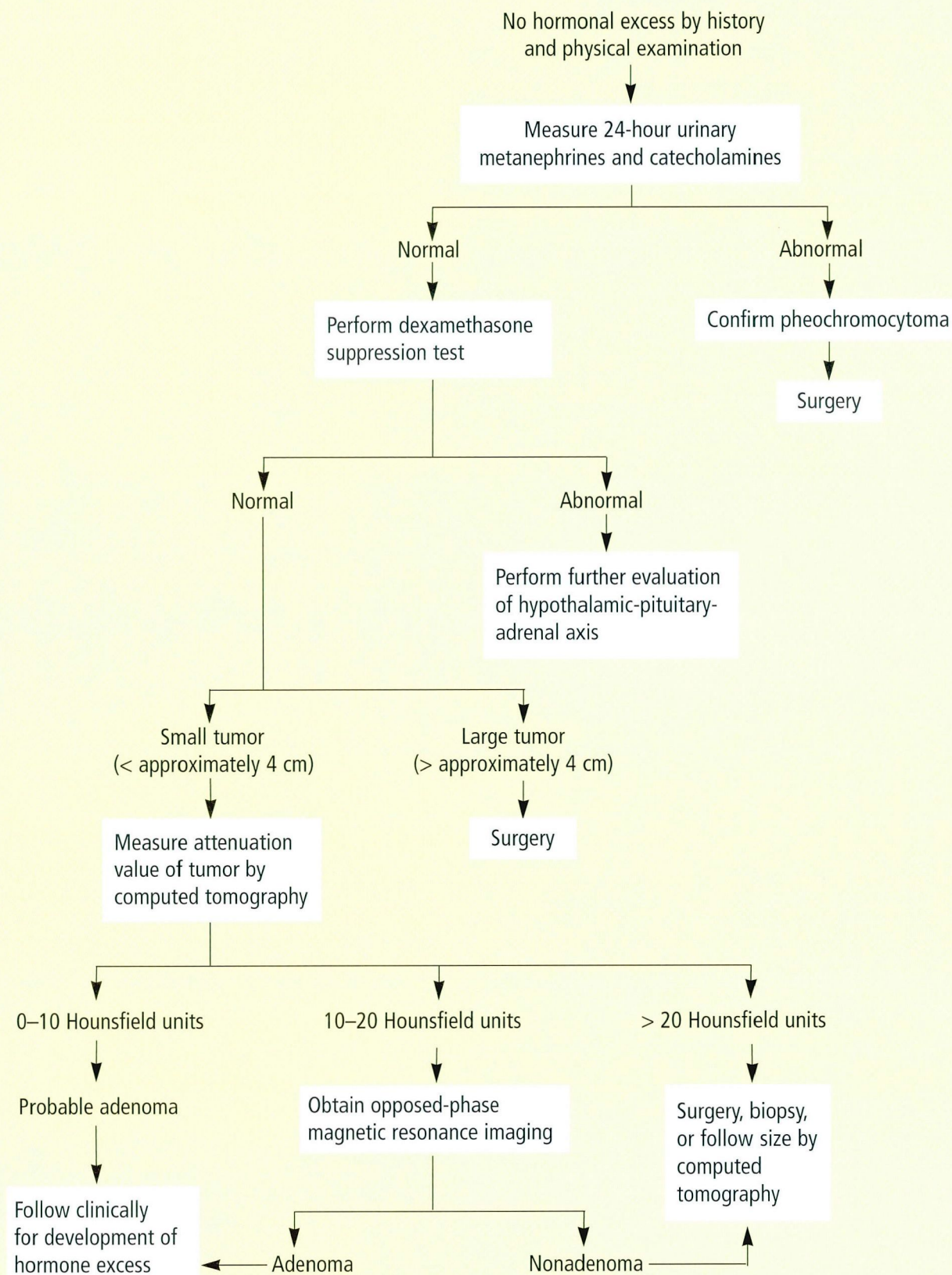
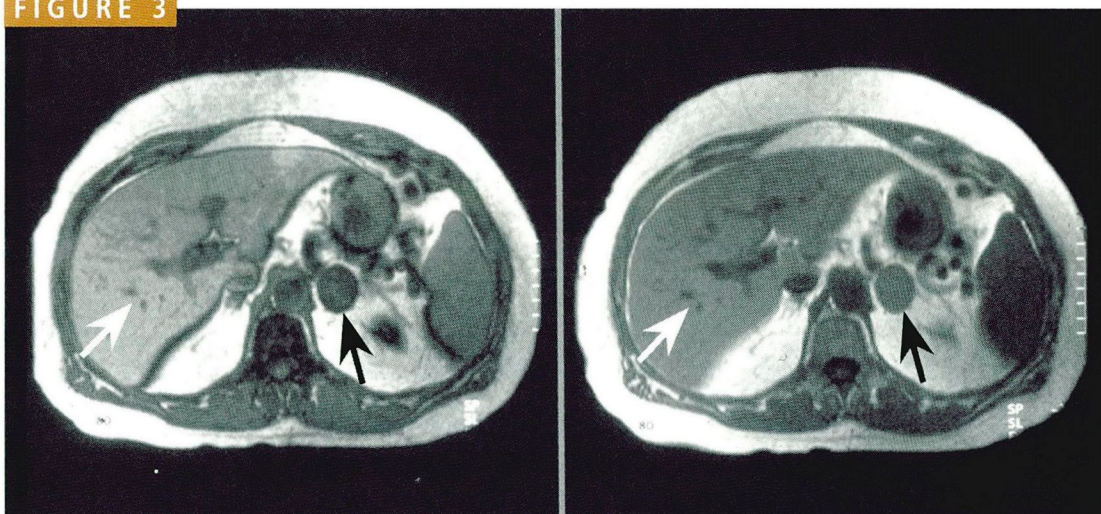




FIGURE 3



Opposed-phase chemical shift imaging of the abdomen. First an “in-phase” image (left) is taken, followed by an “opposed-phase” image (right). Note that on the opposed-phase image, there is a reduction of signal intensity of the incidentaloma (black arrow) relative to the liver (white arrow), suggesting a mass with a high lipid content, such as an adenoma.

Obtain further radiographic images if clinical and laboratory evaluations are not diagnostic

free cortisol level is often normal. Whether to use a low (1-mg) or high (8-mg) dexamethasone dose is controversial, but the literature favors the high-dose test.

Although preclinical Cushing's syndrome can lead to adrenal insufficiency after adrenalectomy, its long-term implications are uncertain. Some patients with diabetes mellitus or hypertension have been reported to improve after adrenalectomy.¹² The possible effects on osteoporosis and progression to overt Cushing's syndrome are unknown.

Congenital adrenal hyperplasia

Patients with congenital adrenal hyperplasia caused by 21-hydroxylase deficiency have a high incidence of adrenal nodules.¹⁴ The diagnosis of congenital adrenal hyperplasia can be established by giving synthetic adrenocorticotrophic hormone, which induces an exaggerated 17 α -hydroxyprogesterone (17-OHP) response. 21-hydroxylase catalyzes the reaction from 17-OHP to 11-deoxycortisol; consequently, when this enzyme is deficient, 17-OHP accumulates.¹⁴ Recently, an exaggerated 17-OHP response that reverts to normal after adrenalectomy has been reported, suggesting that a deficiency in 21-hydroxylase activity can be inherent in certain adenomas.¹⁵

Therefore, not all patients with an elevated 17-OHP response have congenital adrenal hyperplasia.

Other biochemical markers

Aldosterone precursors have been studied as indicators of primary adrenal malignancy.¹⁶

Low DHEA-S levels have been evaluated as an indicator of a nonfunctioning adenoma.^{17–19} The clinical utility of these precursors and hormones has yet to be established.

■ WHAT IF THE CLINICAL AND LABORATORY EVALUATION IS INDETERMINATE?

If the clinical and biochemical evaluation is indeterminate, further radiographic imaging and perhaps biopsy are indicated to determine whether the lesion is malignant or benign.

CT scanning

Conventional management calls for CT scanning at 3, 6, 12, and 18 months after an adrenal mass is discovered, and surgery if the mass grows. Recent findings suggest, however, that without contrast enhancement, a CT attenuation value less than 10 Hounsfield units is approximately 96% specific and 73% sensitive

for adenoma and may eliminate the need for follow-up CT scanning.²⁰ Attenuation values greater than 10 Hounsfield units are indeterminate.

These attenuation values are reliable only if scanning is done without contrast dye. Also, tumor necrosis, calcification, or hemorrhage falsely elevate the attenuation value. Most scanning machines calculate the attenuation automatically, and operator error is highly unlikely.

MRI scanning

Several MRI techniques are also under study for evaluating adrenal incidentalomas.

Opposed-phase chemical shift imaging is the most promising of these techniques.^{21,22} This method is highly specific for distinguishing between malignant and benign disease. Two images are made, an "in-phase" image and an "opposed-phase" image. If, on the opposed-phase image, there is a reduction of signal intensity of the incidentaloma relative to the liver, it suggests a mass with a high lipid content, such as an adenoma (FIGURE 3). Because of its higher cost, MRI is generally reserved for patients with indeterminate CT attenuation values.

Scintigraphic imaging with NP-59 is currently under investigation in the United States but approved for use in Canada. NP-59 scanning is similar to radioactive iodine thyroid scanning in that only functioning tissue (here, adrenal tissue) takes up the isotope. Concordant uptake, in which NP-59 accumulates only on the same side as the mass seen on a CT scan, suggests a functioning adrenal adenoma. This pattern results because the normal tissue atrophies if the tumor is functioning, while the more active tumor takes up the NP-59.

NP-59 scanning is limited by cost and the time needed for imaging (5 to 7 days). Also, it does not identify lesions smaller than 2 cm.

Fine-needle aspiration biopsy

Masses that remain indeterminate despite clinical, biochemical and radiographic imaging may require fine-needle aspiration biopsy—particularly in patients with a suspected malignant disease. Needle aspiration is particularly specific for metastases but may not distinguish adrenal carcinoma from adenoma. Potential complications include pneumothorax, hemorrhage, and, rarely, pancreatitis. ■

Masses that remain indeterminate may require biopsy

REFERENCES

- Gross MD, Shapiro B. Clinical review 50: clinically silent adrenal masses. *J Clin Endocrinol Metab* 1993; 77:885–888.
- Bitter D, Ross DS. Incidentally discovered adrenal masses. *Am J Surg* 1989; 158:159–161.
- Belldgrun A, Hussain S, Seltzer SE, Loughlin KR, Gittes RF, Richie JP. Incidentally discovered mass of the adrenal gland. *Surg Gynecol Obstet* 1986; 163(3):203–208.
- Copeland PM. The incidentally discovered adrenal mass. *Ann Intern Med* 1983; 98:940–945.
- Prinz RA, Brooks MH, Churchill R, et al. Incidental asymptomatic adrenal masses detected by computed tomographic scanning: Is operation required? *JAMA* 1982; 248:701–704.
- Staren ED, Prinz RA. Selection of patients with adrenal incidentalomas for operation. *Surg Clin North Am* 1995; 75(3):499–509.
- Ross NS, Aron DC. Hormonal evaluation of the patient with an incidentally discovered adrenal mass. *N Engl J Med* 1990; 323:1401–1405.
- Ambrosi B, Peverelli S, Passini E, et al. Abnormalities of endocrine function in patients with clinically "silent" adrenal masses. *Eur J Endocrinol* 1995; 132:422–428.
- Charbonnel B, Chatal JF, Ozanne P. Does the corticoadrenal adenoma with "Pre-Cushing's syndrome" exist? *J Nucl Med* 1981; 22:1059–1061.
- Fernandez-Real JM, Ricart-Engel W, Simo R. Pre-clinical Cushing's syndrome: report of three cases and literature review. *Horm Res* 1994; 41:230–235.
- McLeod MK, Thompson NW, Gross MD, Bondeson AG, Bondeson L. Sub-clinical Cushing's syndrome in patients with adrenal gland incidentalomas: pitfalls in diagnosis and management. *Am Surg* 1990; 56:398–403.
- Reincke M, Niekke J, Krestin GP, Saeger W, Allolio B, Winkelmann W. Preclinical Cushing's syndrome in adrenal "incidentalomas": comparison with adrenal Cushing's syndrome. *J Clin Endocrinol Metab* 1992; 75:826–832.
- Rosen HN, Swartz SL. Subtle glucocorticoid excess in patients with adrenal incidentaloma. *Am J Med* 1992; 92:213–216.
- Jaresch S, Kornely E, Kley HK, Schlaghecke R. Adrenal incidentaloma and patients with homozygous or heterozygous congenital adrenal hyperplasia. *J Clin Endocrinol Metab* 1992; 74(3):685–689.
- Del Monte P, Bernasconi D, Bertolazzi L, et al. Increased 17 alpha-hydroxyprogesterone response to ACTH in silent adrenal adenoma: cause or effect? *Clin Endocrinol* 1995; 42:273–277.
- Aupetit-Faisant B, Blanchouin-Emeric N, Tenenbaum F, et al. Plasma levels of aldosterone versus aldosterone precursors: a way to estimate the malignancy of asymptomatic and nonsecretory adrenal tumors. A French Retrospective Multicentric Study. *J Clin Endocrinol Metab* 1995; 80:2715–2721.
- Osella G, Terzolo M, Borretta G, et al. Endocrine evaluation of incidentally discovered adrenal masses (incidentalomas). *J Clin Endocrinol Metab* 1994; 79:1532–1539.
- Bencsik Z, Szabolcs I, Kovacs Z, et al. Low DHEA-S level is not a good predictor of hormonal activity in nonselected patients with incidentally detected adrenal tumors. *J Clin Endocrinol Metab* 1996; 81:1726–1729.
- Flecchia D, Mazza E, Carlini M, et al. Reduced serum levels of dehydroepiandrosterone sulphate in adrenal incidentalomas: a marker of adrenocortical tumor. *Clin Endocrinol* 1995; 42:129–134.
- Korobkin M, Brodeur FJ, Yutzy GG, et al. Differentiation of adrenal adenomas from nonadenomas using CT attenuation values. *Am J Roentgenol* 1996; 166:531–536.
- Boland GW, Lee MJ. Magnetic resonance imaging of the adrenal gland. *Crit Rev Diagn Imaging* 1995; 36:115–174.
- McLoughlin RF, Bilbey JH. Tumors of the adrenal gland: findings on CT and MR imaging. *Am J Roentgenol* 1994; 163:1413–1418.

ADDRESS: Rossana Danese, MD, Department of Endocrinology, A30, The Cleveland Clinic Foundation, 9500 Euclid Avenue, Cleveland, OH 44195.