

DAVID L. LONGWORTH, MD, AND JAMES K. STOLLER, MD

## A 36-year-old woman with progressive shortness of breath and chylous pleural effusion

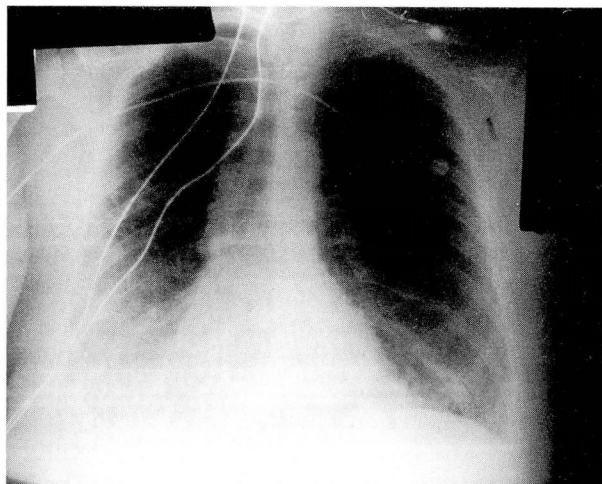
**A** 36-YEAR-OLD WHITE WOMAN who has never smoked presents with progressive shortness of breath that developed over the preceding year. She also gives a history of mild intermittent hemoptysis. Physical examination reveals no clubbing of the fingers but does reveal decreased air entry and dullness to percussion in the posterior right lung base. Her chest radiograph is shown in *Figure 1*.

A thoracentesis is performed, and 480 mL of milky pleural fluid is removed. Analysis of the pleural fluid reveals a protein concentration of 3.6 g/dL (serum value 4.8 g/dL), lactate dehydrogenase 280 U/L (serum value 166 U/L), glucose 93 mg/dL (serum value 115 mg/dL), total cholesterol 81 mg/dL, and triglycerides 3355 mg/dL.

**1** What is your diagnosis?

- ☐ Eosinophilic granuloma
- ☐ Sarcoidosis
- ☐ Lymphangioleiomyomatosis
- ☐ Tuberous sclerosis

All the diseases listed above can cause interstitial lung disease with preserved or increased lung volumes. A chylous pleural effusion (pleural triglyceride level > 110 mg/dL) favors the diagnosis of lymphangioleiomyomatosis (LAM), a unique disease that primarily affects the lungs of women of childbearing age. In this disease, immature smooth muscle cells proliferate in various interstitial compartments, and cystic lesions and hemosiderosis de-



**FIGURE 1.** Chest roentgenogram, posterior-anterior view. Note the bilateral interstitial infiltrates (more prominent on the right), right pleural effusion, and preserved lung volumes. Also note the transtracheal oxygen catheter.

velop in the lungs (*Figure 2*). The *Table* outlines clinical features of LAM.

At presentation, 88% of patients have progressive dyspnea, 61% have a cough, 28% have intermittent hemoptysis, 7% to 39% have a chylous pleural effusion, and 39% have recurrent pneumothorax. Dyspnea, the major presenting symptom, is caused by interstitial lung disease, chylous pleural effusion, or obstruction of small airways. Intermittent hemoptysis results when small pulmonary veins become obstructed and rupture, owing to the smooth muscle proliferation that is characteristic of

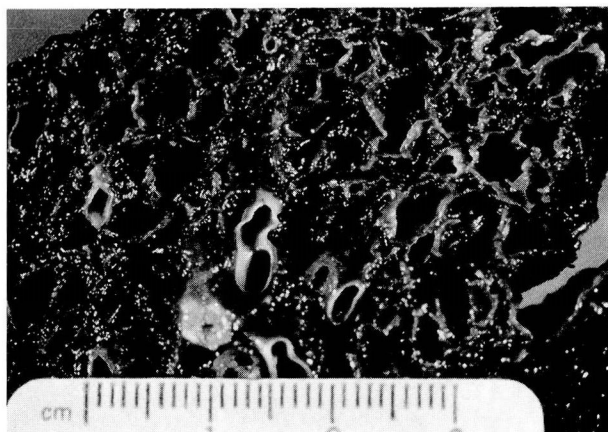


FIGURE 2. Gross appearance of lung tissue from a patient with pulmonary lymphangioleiomyomatosis. Note the diffusely distributed cystic airspaces.

LAM. Pneumothorax results from rupture of parenchymal cysts that form after the distal airways become obstructed. Other, rare clinical manifestations include chyluria, chylopericardium, chyloptysis, and lower-extremity edema. Interestingly, the patient described here presented later in the course of her disease with a cough productive of milky white sputum. The triglyceride level in the sputum was 2079 mg/dL, confirming the clinically suspected chyloptysis.

The chest radiographic findings are variable and include bilateral interstitial infiltrates (present in 98%), cysts or bullae (present in 56%), hyperinflation (present in 48%), and pneumothorax and chylous pleural effusions, as mentioned above. In advanced cases, computed tomography of the chest typically reveals multiple, well-defined, thin-walled cysts distributed diffusely throughout both lungs. Other less-frequent computed tomographic findings include ground-glass opacities or nodular densities.

**2** Which pulmonary function test result is associated with poor survival?

- ☐ Low forced expiratory volume in 1 second ( $FEV_1$ )
- ☐ High percentage of predicted forced vital capacity (%FVC)
- ☐ High percentage of predicted total lung capacity (%TLC)
- ☐ High ratio of residual volume (RV) to TLC

**TABLE**  
CLINICAL FEATURES  
OF LYMPHANGIOLEIOMYOMATOSIS\*

**Symptoms**

Dyspnea  
Cough  
Chest pain  
Hemoptysis  
Chyloptysis

**Signs**

Crackles  
Rhonchi  
Pleural effusion (chylothorax)  
Clubbing  
Ascites (chylous)

**Chest radiographic findings**

Bilateral infiltrates  
Reticulonodular shadows  
Cysts and bullae  
Hyperinflation  
Pneumothorax  
Effusion (chylous)

**Pulmonary function test findings**

Decreased diffusing capacity for carbon monoxide  
Hypoxemia  
Increased ratio of residual volume to total lung capacity  
Combined restrictive and obstructive pattern  
Increased percentage of predicted total lung capacity  
Obstructive pattern  
Restrictive pattern

\*Features are listed in descending order of frequency in each category

Patients with LAM may have a multitude of abnormalities of pulmonary function. A restrictive ventilatory pattern, characterized by a reduction in lung volumes, may be seen early in LAM, due to interstitial lung disease or pleural effusions. However, the most frequent ventilatory pattern seen in patients with LAM is that of progressive obstructive lung disease, characterized by a progressive decrease in  $FEV_1$ , hyperinflation, and a reduced diffusing capacity for carbon monoxide. One of the unusual features of LAM is that many patients (36%) exhibit features of restrictive lung disease and obstructive lung disease simultaneously.

A reduction in the  $FEV_1/FVC$  ratio (which reflects the severity of the obstruction) and an increase in the %TLC have been associated with poor outcome. Other pulmonary function tests such as the percentage of predicted vital capacity (%VC), %FVC, % $FEV_1$ , RV/TLC ratio,  $PaO_2$ ,  $PaCO_2$ , and the alveolar-arterial oxygen difference do not seem to correlate with survival.



### 3 What is the treatment of choice?

- ☐ Medroxyprogesterone
- ☐ Oral or parenteral corticosteroids
- ☐ Oophorectomy and tamoxifen
- ☐ Cyclophosphamide

There is currently no uniformly effective treatment for LAM, and most patients die within 10 years of the onset of symptoms. Since LAM occurs almost exclusively in premenopausal women, hormones (particularly estrogen) are thought to play a major role in its pathogenesis. Therefore, most therapies aim at reducing circulating estrogen levels. Therapies include medroxyprogesterone (the initial treatment of choice), oophorectomy, tamoxifen, gonadotropin-releasing hormone agonists, and luteinizing hormone-releasing hormone. Lung transplantation offers a promising therapeutic alternative; our patient underwent a left single lung transplantation.

A pathologically related disease is tuberous sclerosis. This autosomal dominant systemic disease is characterized by hamartomas in one or multiple organs, particularly the skin, central nervous system (presenting as mental retardation), and kidneys (presenting as renal failure). When tuberous sclerosis involves the lung, it has a clinical, radiographic, and physiologic picture very similar to that of LAM. However, in tuberous sclerosis, 20% of patients are men, chylous pleural effusions are rare, and anties-trogen treatment is not helpful.

RAED A. DWEIK, MD  
ALEJANDRO C. ARROLIGA, MD  
Department of Pulmonary and  
Critical Care Medicine  
The Cleveland Clinic Foundation

#### SUGGESTED READING


Kitaichi M, Nishimura K, Itoh H, Izumi T. Pulmonary lymphangioleiomyomatosis: a report of 46 patients including a clinico-pathologic study of prognostic factors. *Am J Respir Crit Care Med* 1995; 151:527-533.

Taylor JR, Ryu J, Colby TV, Raffin TA. Lymphangioleiomyomatosis. Clinical course in 32 patients. *N Engl J Med* 1990; 323:1254-1260.

Silverstein EF, Ellis K, Wolff M, Jaretzki A 3rd. Pulmonary lymphangioleiomyomatosis. *Am J Roentgenol* 1974; 120:832-850.

Corrin B, Leibow AA, Friedman PJ. Pulmonary lymphangioleiomyomatosis. A review. *Am J Pathol* 1975; 79:348-382.

Castro M, Shepherd CW, Gomez MR, Lie JT, Ryu JH. Pulmonary tuberous sclerosis. *Chest* 1995; 107:189-195.



## CME CREDIT TEST

**T**HE CLEVELAND CLINIC *Journal of Medicine*, published by The Cleveland Clinic Foundation as part of its program of continuing medical education, is dedicated to fulfilling the educational needs of practicing internists. The Cleveland Clinic Foundation is accredited by the Accreditation Council for Continuing Medical Education (ACCME) to sponsor continuing medical education for physicians. The Cleveland Clinic Foundation certifies that this continuing medical education offering meets the criteria for 2 hours of Category 1 of the Physician's Recognition Award of the American Medical Association if it is used and completed as designed. A letter of accreditation will be provided by The Cleveland Clinic Foundation Department of Continuing Education. This offering was planned and produced in accordance with ACCME's policy, "Accreditation for Interpreting the Essentials as Applied to Continuing Medical Education Enduring Materials."

The following test includes questions based on selected clinical articles in this issue. Please complete the form by placing an X in the box next to the correct answer (choose only one, unless otherwise instructed).

- Instructions for submitting this form are at the end of the test. Completed tests must be received by May 14, 1996. Answers will be published in the following issue.

### COLON POLYPS: DIAGNOSIS, TREATMENT, SURVEILLANCE, page 84

**1** True or false? Once a patient is found to have adenomas in the colon, he or she needs a colonoscopy yearly until no polyps are found.

- ☐ A. True
- ☐ B. False

**2** True or false? A plain or single-contrast barium enema is not an adequate test to screen for polyps or colon cancer.

- ☐ A. True
- ☐ B. False

### OUTPATIENT MANAGEMENT OF SYSTEMIC LUPUS ERYTHEMATOSUS, page 94

**3** Choose one. Serum from patients with drug-induced SLE often demonstrates which of the following autoantibodies?

- ☐ A. Anti-SM
- ☐ B. Anti-histone
- ☐ C. Anti-dsDNA
- ☐ D. Anti-RNA
- ☐ E. Anti-JO-1