

Acute dissection of the aorta: options for diagnostic imaging

MEHDI RAZAVI, MD

SUMMARY When dissection of the aorta is suspected, the physician needs to initiate medical therapy immediately, even before a final diagnosis is made. New imaging technologies are essential in making a diagnosis. In some cases, these new imaging modalities obviate the need for angiography.

KEY POINTS Diagnostic clues include an abrupt, intense, ripping or tearing pain in the chest or back, ischemic signs in various organs due to occlusion of branch vessels, and a new murmur of aortic insufficiency. Patients often have underlying hypertension, atherosclerosis, or connective-tissue disease. ■ Medical therapy should be initiated immediately with intravenous infusions of nitroprusside and concomitant administration of a beta blocker or a calcium antagonist with negative inotropic effects (verapamil or diltiazem). Blood pressure and urine output must be closely monitored to assure adequate tissue perfusion. ■ Aortography remains the gold standard for imaging procedures. Transthoracic or transesophageal echocardiography, computed tomography, and magnetic resonance imaging all have advantages and disadvantages in certain situations, and are safer than aortography. However, they will not reveal coronary artery disease. ■ Proximal dissections must be repaired immediately; patients with coronary artery disease can undergo bypass grafting at the same time.

■ INDEX TERMS: AORTIC ANEURYSM; ANEURYSM, DISSECTING
■ CLEVELAND CLIN J MED 1995; 62:360-365

From the Department of Cardiology, The Cleveland Clinic Foundation.
Address reprint requests to M.R., Department of Cardiology, F25, The Cleveland Clinic Foundation, 9500 Euclid Avenue, Cleveland, OH 44195.

DISSECTION of the aorta is the most common disorder of the aortic root, and the most deadly. Treatment depends on the location and extent of the dissection and whether it is acute or chronic. Rapid action is required in diagnosing and treating this disorder, as the prognosis is poor without intervention. For this reason, physician awareness is critical.

Dissections involving the ascending aorta (type A in the Stanford classification, types I and II in the DeBakey classification) require emergency surgical repair; more distal dissections (Stanford type B or DeBakey type III) may not.

Aortography, magnetic resonance imaging (MRI), computed tomography (CT), transthoracic echocardiography (TTE), and transesophageal echocardiography (TEE) all have advantages and disadvantages in certain situations. The clinician has to quickly choose an imaging technique, after carefully weighing the advantages and risks of each for the individual patient (who often is extremely ill and sometimes has major hemodynamic alterations such as aortic regurgitation or pericardial tam-

ponade). This article puts these new imaging techniques into perspective in diagnosing aortic dissection, and also briefly reviews how to treat it.

CAUSES OF AORTIC DISSECTION

A number of factors can underlie aortic dissection, the most common being hypertension, arteriosclerosis, and degenerative disorders of the smooth muscle and elastic tissue such as cystic medial necrosis. Less common causes are connective-tissue disorders such as Marfan's syndrome, Ehlers-Danlos syndrome, rheumatoid spondylitis, and periarteritis nodosa. Giant-cell arteritis and Takayasu's arteritis are not uncommon, especially in the Orient. Other rare causes are mycotic aneurysms and luetic aortitis.

Poststenotic dilatation or even aneurysm of the ascending aorta is not infrequent in patients with a bicuspid aortic valve, with or without associated aortic coarctation. Such an aneurysm can predispose patients to aortic dissection, particularly if other risk factors are present. Pregnancy very rarely predisposes patients to dissection of the aorta, usually only in patients with Marfan's syndrome. Open heart surgery and coronary bypass surgery involving the aortic root (such as canalization of the aorta, aortic cross-clamping, or fenestration for aortocoronary bypass grafts) also can lead to dissection of the ascending aorta.

Although the most common site for traumatic dissection of the aorta is the isthmus near the ligament arteriosus, blunt trauma can also cause ascending aortic dissection. Aortic aneurysm, whether in the abdominal aorta, the peripheral vascular bed, or even the coronary artery, may be associated with an aortic root abnormality.

CLINICAL CONSIDERATIONS AND DIAGNOSIS

Aortic dissection is often associated with chest pain, which is usually severe, sudden, and maximal at onset; patients frequently describe it as "ripping" or "tearing." The location is variable, either in the front or in the back. A diagnosis of acute myocardial infarction is often entertained; however, the pain rarely radiates to the arms and jaw in dissection. Electrocardiography typically shows either no abnormality or, in hypertensive patients, ventricular hypertrophy. On the other hand, the dissection can cause a stroke, myocardial infarction, or infarction of other organs by occluding the origin of the respective artery.

TABLE 1
AORTIC DISSECTION: DIAGNOSTIC CLUES

Chest pain without electrocardiographic changes
Associated ischemic signs
Stroke (arch involvement)
Unequal blood pressure in brachycephalic vessels
Loss of leg pulses
Paraplegia (vertebral involvement)
Anuria, azotemia (renal artery involvement)
Anemia (hemorrhage)
New murmur of aortic insufficiency
Hoarseness
Pericardial effusion
Pleural effusion
Acute myocardial ischemia or infarction
Abnormal chest roentgenogram

A history of hypertension is often helpful in making a diagnosis of dissection. Atherosclerosis elsewhere in the body or a history of connective tissue disorders are also helpful clues. Blunt trauma or a history of recent cardiac surgery should be kept in mind. Diagnostic clues are listed in *Table 1*.

MEDICAL TREATMENT

If the physician suspects acute dissection of the aorta, medical treatment should be initiated immediately after the initial clinical assessment, even if a final diagnosis has yet to be made. The goals are to reduce the blood pressure and heart rate and to treat congestive heart failure and tachyarrhythmias.

The combination of a vasodilator (nitroprusside in a titrated intravenous infusion) and a beta blocker (propranolol, labetalol, or esmolol) is recommended. If beta blockers are contraindicated, verapamil or diltiazem are the next drugs of choice. The blood pressure should be reduced only to a level where vital organs such as the kidneys, brain, and myocardium remain adequately perfused. A systolic blood pressure of 100 to 110 mm Hg is a reasonable goal, if perfusion remains adequate at this level.

Some authorities warn not to give vasodilators without concomitantly giving a drug that has negative inotropic and negative chronotropic effects; doing so might actually increase the velocity of left ventricular contraction (dP/dT) and make the dissection worse. For the same reason, sublingual use of nifedipine is controversial: it reduces blood pressure in an uncontrolled fashion, potentially causing a

TABLE 2
SENSITIVITY OF IMAGING TESTS
FOR AORTIC DISSECTION*

Type of dissection	Sensitivity (%)			
	TTE [‡]	TEE [‡]	CT [§]	MRI
Type A				
Acute	78.3	95.2	94.1	100
Subacute	87.5	100	80.0	100
Type B				
Acute	40.0 [#]	100	100	100
Subacute	29.4 [#]	100	93.3	94.4

*From Nienaber CA, von Kodolitsch Y, Nicolas V, et al. The diagnosis of thoracic aortic dissection by noninvasive imaging procedures. *N Engl J Med* 1993; 328:1-9

[‡]Transthoracic echocardiography

[‡]Transesophageal echocardiography

[§]Computed tomography

^{||}Magnetic resonance imaging

^{||}[†] $P < .05$ vs TEE, roentgenography, CT, and MRI

[#] $P < .01$ vs TEE, roentgenography, CT, and MRI

reflex increase in heart rate and contractility and increasing dP/dT. A continuous nitroglycerine infusion may be initiated if necessary.

Digitalis may be necessary for tachyarrhythmias such as rapid atrial fibrillation or supraventricular tachycardia; however, calcium channel blockers such as verapamil or diltiazem given intravenously are more appropriate, particularly if renal function is not well established or impaired.

These immediate measures may slow the rate of progression of aortic dissection until more definitive surgical management has been decided upon. For distal dissections, medical treatment is the treatment of choice, unless complications occur.

IMAGING PROCEDURES

The next step is to substantiate the diagnosis and determine the location and extent of the dissection (Figure). The presence or absence of coronary artery disease, whether stabilized or suspected, must also be determined because it is possible to perform adjunctive aortocoronary bypass surgery at the same time that the dissection is repaired. However, because of the higher morbidity involved in cardiac angiography in patients with acute dissection of the ascending aorta, avoiding such a procedure is appropriate when coronary artery disease can reasonably be excluded, ie, if the patient is relatively young, has no history of coronary artery disease, and has no major risk factors for it.

Patients with abdominal aortic aneurysm often have significant coronary artery disease. At our institution, we postpone surgery in such patients until diagnostic coronary arteriography is performed, and appropriate treatment of coronary artery disease is done. It is very likely that an aortic root aneurysm or dissection caused by degenerative processes would be associated with coronary artery disease.

Although newer imaging procedures such as magnetic resonance imaging (MRI), computed tomography (CT), and echocardiography can adequately diagnose aortic root disease or dissection, they will not reveal coronary artery disease. The sensitivity of imaging procedures varies in type A (proximal) vs type B (distal) dissection (Table 2). Whether physicians will rely on CT, MRI, or echocardiography will depend largely on whether these are available. Each has advantages and disadvantages.

Aortography

Aortography has traditionally been the gold standard in diagnosing dissection of the aorta, although MRI and TEE have challenged this role in recent years. Aortography is a procedure with which many institutions have considerable experience, it has high sensitivity and specificity, and it provides surgeons with information regarding entry site, branch vessel involvement, and aortic insufficiency. In addition, coronary arteriography can often be done at the same time. Nevertheless, we do not recommend that aortography be done in all patients suspected of having aortic aneurysm or aortic dissection because it imparts significant added morbidity. It is invasive, it requires contrast media, and on rare occasions, the catheter can worsen the dissection.

Aortographic signs that directly point to the diagnosis of aortic dissection include a double lumen, a dissecting flap, demonstration of the point of entry, and branch involvement in the aortic arch or in the coronary arteries. Indirect signs are compression of the true lumen, a thickened aortic wall, branch abnormalities, and abnormal catheter position.

Computed tomography

CT of the chest is much more informative when contrast media is used than without contrast; however, patients with aortic dissection sometimes have compromised renal function, which is a contraindication to the use of contrast media. The advantages of CT are that it is noninvasive, it is widely available, and it will display intraluminal clot formations.

Pericardial effusions or periaortic hematomas can be observed as well. However, CT often does not reveal the site of entry or branch involvement, and it cannot reveal the degree of aortic regurgitation.

Magnetic resonance imaging

MRI has been used very effectively for diagnosing acute dissection of the ascending aorta. It is noninvasive, does not require contrast media, and, when one can use cine MRI, can reveal the degree of aortic regurgitation. On the other hand, the intensive monitoring and treatment required by patients in unstable condition will preclude MRI, which requires patients to remain in the imaging tube for 30 to 45 minutes. Further, a thrombosed false lumen may be incorrectly diagnosed as an aneurysm by MRI. MRI is hazardous for patients with pacemakers or metallic implants. Because MRI can visualize the entire anatomy of the ascending and descending aorta, it is perhaps the optimal method for following patients who have complex aortic disease, particularly after surgery.

Echocardiography

The development of transesophageal echocardiography (TEE) has revolutionized the emergency diagnosis and management of thoracic aortic dissection. It is a portable procedure that can be performed in critically ill and intubated patients with a high degree of safety. It provides high-resolution images of the ascending and descending thoracic aorta and aortic arch, although a small section

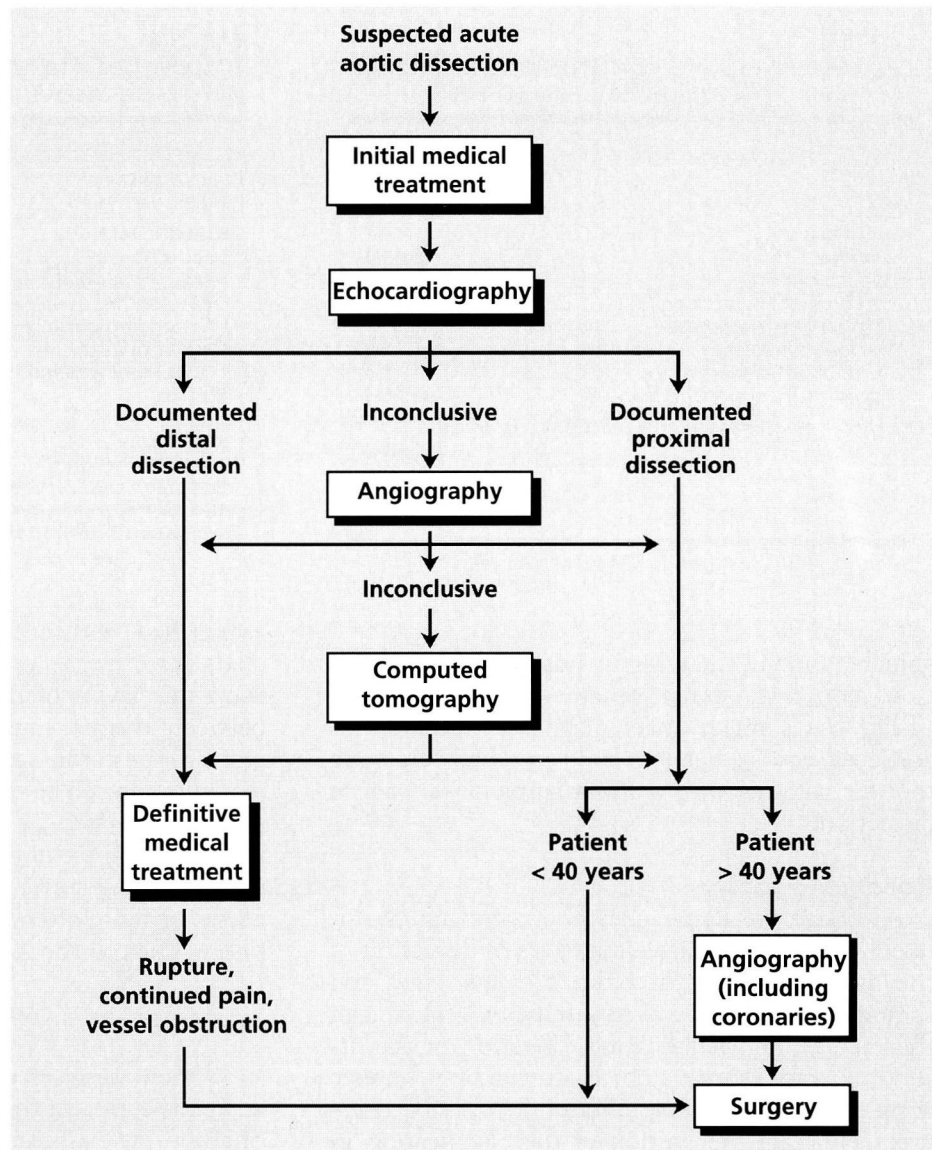


FIGURE. Suggested flow chart for managing acute aortic dissection.

of the vessel in the upper ascending aorta is often obscured by the intervening bronchus between the esophagus and the aorta. TEE also provides important information on the often-multiple entry and exit sites along the dissection, the degree and mechanism of associated aortic regurgitation, and evidence for wall-motion abnormalities suggestive of coronary artery involvement. In patients with a strong suspicion for aortic dissection, TEE is often the only diagnostic test performed in our hospital, and it can be performed in the operating room as the patient is being prepared for surgery, saving

TABLE 3
CHARACTERISTICS OF 37 PATIENTS WITH MEDICALLY
TREATED AORTIC ANEURYSM, 1984 TO 1987*

	No.	(%)
Women	14	(37.8%)
Men	23	(62.2%)
Patient history		
Diabetes	2	(5.4%)
Hypertension	25	(67.6%)
Cerebrovascular accident	5	(13.5%)
Coronary artery disease	25	(67.6%)
Marfan's syndrome	3	(8.1%)
Aortic insufficiency	13	(35.1%)
Aortic insufficiency and stenosis	2	(5.4%)
New York Heart Association functional classification		
I	21	(56.8%)
II	11	(29.7%)
III	2	(5.4%)
IV	0	

*Mean age 64 years (range 50 years to 80 years)

valuable time in these highly unstable patients.

In contrast, transthoracic echocardiography (TTE) has a much lower diagnostic accuracy for aortic dissection, but it remains a useful screening tool for patients with a lower suspicion for aortic dissection.

Roentgenography

Although the simple chest roentgenogram is unlikely to give a definitive diagnosis of dissection of the ascending aorta, it often provides clues and should be used because of its simplicity. Widening of the mediastinum (indicating dilatation of the ascending aorta, aortic arch, or descending thoracic aorta) is the most common finding on a simple chest roentgenogram. Separation of the calcification in the aortic intima from the external aortic root or aortic arch shadow is a highly specific sign. Comparison with previous roentgenograms is often helpful. The size of the cardiac silhouette may indicate pericardial effusion, which can indicate acute dissection. In rare instances, pleural effusion can be seen as the dissected aorta begins to leak into the thoracic cavity.

SURGERY

Surgery and medical treatment together constitute the treatment of choice for proximal dissection of the aorta. Surgery should be performed as soon as a diagnosis of acute proximal aortic dissection is

TABLE 4
FOLLOW-UP DATA FOR 35 PATIENTS*
WITH MEDICALLY TREATED AORTIC ANEURYSM

	No.	(%)
Patients alive	10	(28.6%)
Patients who died	25	(71.4%)
Cause of death		
Sudden death	5	(20.0%)
Acute myocardial infarction	2	(8.0%)
Death during open-heart surgery (ascending aortic aneurysm repair)	1	(4.0%)
Cardiac death (coronary artery disease)	3	(12.0%)
Stroke	1	(4.0%)
Cancer	4	(28.6%)
Respiratory	1	(4.0%)
Aortic dissection	7	(28.0%)
End-stage cardiomyopathy	1	(4.0%)

*Two patients lost to follow-up.

established, within hours. Surgical techniques include resecting a portion of the aorta, reinforcing the three layers of the aorta, and placing a graft between the proximal and distal aorta and vein grafts to the coronary artery if needed. Often, aortic regurgitation can be significantly minimized or completely alleviated by suspending the aortic cusps, which seldom are directly involved in dissection. In rare cases, the aortic valve is replaced with a prosthesis, or more often, a composite aortic graft containing the prosthetic valve.

PROGNOSIS

Without surgical intervention the prognosis in acute dissection of the ascending aorta is very poor. Shah, in his classic review, points out that if acute proximal aortic dissection remains untreated, the mortality rate is 21% in the first 24 hours, 49% at 4 days, 74% after 2 weeks, and 93% after 1 year.

Even without dissection, aneurysm of the ascending aorta carries a very poor prognosis without surgical intervention. We followed up 37 patients who had an aneurysm of the ascending aorta diagnosed between 1984 and 1987 and who did not undergo surgery. Table 3 outlines the associated disorders in these patients. Two patients were lost to follow-up, 10 were still alive, and 25 had died (Table 4). Seven patients underwent open-heart surgery for ascending aortic aneurysm during the follow-up period, mainly because of the development of aortic dissection.

CONCLUSION

Aortic root disorders, particularly dissection of the ascending aorta, impart a very poor prognosis if not treated surgically. Safe and quick means of definitive diagnosis are now available, and clinicians must make every effort to quickly substantiate the diagnosis and the degree to which the aorta is involved.

SUGGESTED READING

- Barbant SD, Eisenberg MJU, Schiller NB. The diagnostic value of imaging techniques for aortic dissection. *Am Heart J* 1992; 124:541-543.
- Cigarroa JE, Isselbacher EM, DeSanctis RW, Eagle KA. Diagnostic imaging in the evaluation of suspected aortic dissection. *N Engl J Med* 1993; 328:35-43.
- Crawford ES, Kirklin JW, Naftel DC, Svensson LG, Coselli JS, Safi JH. Surgery for acute dissection of ascending aorta. *J Thorac Cardiovasc Surg* 1992; 104:46-59.
- DeSanctis RW, Doroghazi RM, Austen WG, Buckley MJ. Aortic dissection. *N Engl J Med* 1987; 317:1060-1067.
- Erbal R, Daniel W, Visser C, Engberding R, Roelandt J, Rennollet H. Echocardiography and diagnosis of aortic dissection. *Lancet* 1989; 1:457-460.
- Ernst CB. Abdominal aortic aneurysm. *N Engl J Med* 1993; 328:1167-1172.
- Katz DA, Littenberg B, Cronenwett JL. Management of small abdominal aortic aneurysms. Early surgery vs. watchful waiting. *JAMA* 1992; 268:2678-2686.
- Lytle BW. Composite aortic valve replacement and graft replacement of ascending aorta plus coronary ostial reimplantation: How I do it. *Semin Thorac Cardiovasc Surg* 1993; 5:84-87.
- Lytle BW. Thoracic aortic dissections and aneurysms. In: Sivak E, Higgins T, Seiver A, editors. *The high risk patient: management of the critically ill*. Malvern, Pa: Lea and Fabiger 1995:700-712.
- Lytle BW, Mahfood SS, Cosgrove DM, Loop FD. Replacement of ascending aorta. *J Thorac Cardiovasc Surg* 1990; 99:651-658.
- Masuda Y, Takamashi K, Takasu J, Morooka N, Inagaki Y. Expansion rate of thoracic aortic aneurysms and influencing factors. *Chest* 1992; 102:461-466.
- Nienaber CA, von Kodolitsch Y, Nicolas V, et al. The diagnosis of thoracic aortic dissection by noninvasive imaging procedures. *N Engl J Med* 1993; 328:1-9.
- Ross Jr JJ, D'Adamo AJ, Karalis DG, Chandrasekaran K. Three-dimensional transesophageal echo imaging of the descending thoracic aorta. *Am J Cardiol* 1993; 71:1000-1002.
- Scully RE, Mark EJ, McNeely WF, McNeely BU. Case records of the Massachusetts General Hospital. *N Engl J Med* 1991; 325:874-882.
- Shah PK. Acute aortic dissection, part 1. Clues that signal impending disaster. *Journal of Critical Illness* 1992; 7:1047-1072.
- Shah PK. Acute aortic dissection, part 2. Choosing among management options. *Journal of Critical Illness* 1992; 7:1075-1078.

