

DAVID L. LONGWORTH, MD, AND JAMES K. STOLLER, MD, EDITORS

An abnormal chest finding in a 45-year-old man

A 45-YEAR-OLD MAN noted the insidious onset of chest discomfort without other associated symptoms. His physical examination and laboratory test results were entirely normal. An echocardiogram revealed an abnormality, and he was referred to a pulmonologist. A roentgenogram and computed tomographic (CT) scan of the chest are shown in *Figure 1*.

Q1 The mass lesion is located in the:

- ☐ Anterior mediastinum
- ☐ Posterior mediastinum
- ☐ Middle mediastinum
- ☐ Lung parenchyma
- ☐ None of the above

Q2 Which of the following entities represents the most likely cause of this mass?

- ☐ Thymoma
- ☐ Neurogenic tumor
- ☐ Teratoma
- ☐ Bronchogenic cyst
- ☐ Lymphadenopathy

Q3 Appropriate treatment strategies for this mass lesion include:

- ☐ Expectant observation
- ☐ Surgical excision
- ☐ Needle aspiration
- ☐ Radiation therapy
- ☐ Chemotherapy

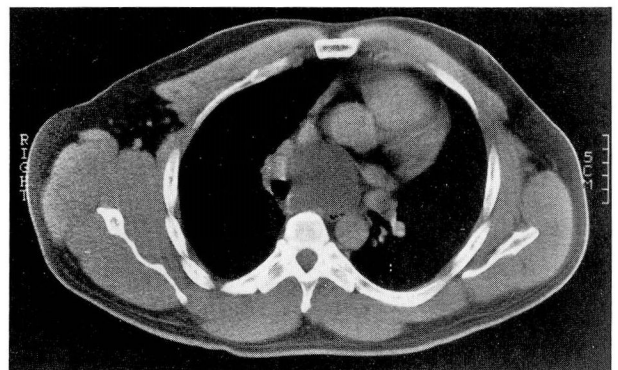
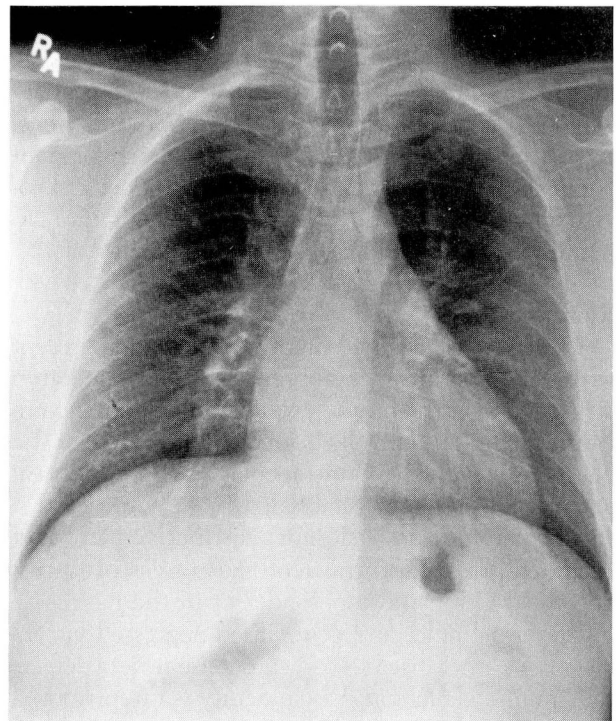


FIGURE 1. Chest roentgenogram and computed tomographic scan of a 45-year-old man with chest discomfort.

DISCUSSION

The mass lesion shown is located in the middle mediastinum. The mediastinum is bounded laterally by the pleural sacs, superiorly by the thoracic inlet, inferiorly by the diaphragm, anteriorly by the sternum, and posteriorly by the spine (Figure 2). The mediastinum is divided into three compartments: anterior, middle, and posterior, with anatomic boundaries as outlined in the Table. Although a number of pathologic entities may exist in more than one compartment, the location of the abnormality does serve to narrow the differential diagnosis. The chest roentgenogram in Figure 1 shows widening of the carina. The CT scan confirms the location of the mass in the middle mediastinum. The lesion is well demarcated and smooth walled and has low attenuation, suggesting its cystic nature.

The radiographic features are most consistent with a bronchogenic cyst. Thymomas and teratomas occur most characteristically in the anterior mediastinum and would be less likely to present as a pure cyst. Neurogenic tumors are of soft-tissue density and characteristically occur in the posterior mediastinum. A lymphoma or hyperplastic lymph node would present as a soft-tissue density and, therefore, can be differentiated on the basis of CT scanning. Finally, the location and nonenhancing nature of the lesion rules out a vascular etiology. Another possibility would be a pericardial cyst; however, these are most

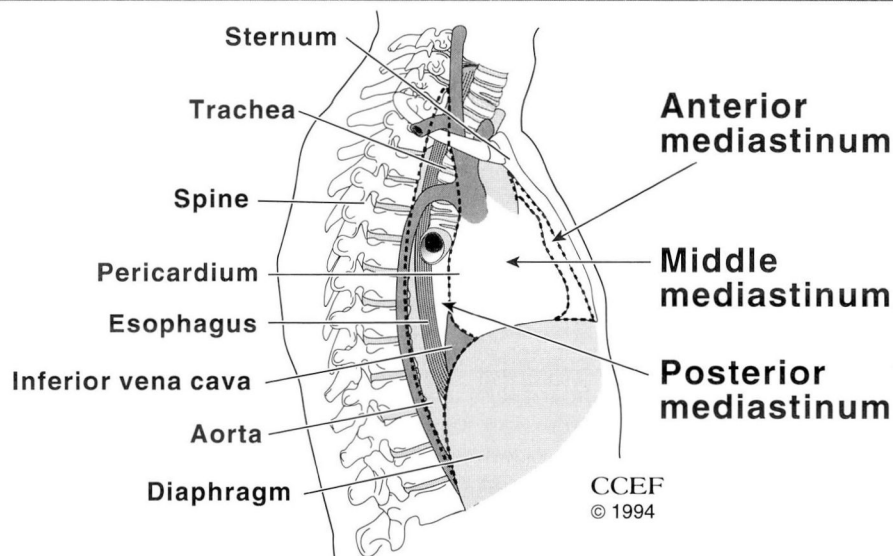


FIGURE 2. The compartments of the mediastinum in relation to other structures in the chest.

TABLE
ANATOMIC BOUNDARIES AND COMMON LESIONS
OF THE THREE MEDIASTINAL COMPARTMENTS

Compartment	Anatomic boundaries	Common lesions
Anterior mediastinum	Anterior: manubrium and sternum Posterior: pericardium, aorta, and brachiocephalic vessels	Thymoma Germ cell tumors (teratomas) Thyroid masses Lymphomas Parathyroid masses
Middle mediastinum	Anterior: anterior mediastinum Posterior: posterior mediastinum	Metastatic or granulomatous lymphadenopathy Lymphomas Masses of vascular origin Bronchogenic cysts Pleuropericardial cysts
Posterior mediastinum	Anterior: pericardium and trachea Posterior: vertebral column	Neurogenic tumors Esophageal lesions Meningomyelocele Extramedullary hematopoiesis

often located in the cardiophrenic angle. Thus, bronchogenic cyst is the most likely diagnosis in this case.

Bronchogenic cysts represent a spectrum of bronchopulmonary malformations that result from an abnormal budding of the tracheobronchial tree. The tracheal bud develops from the primitive foregut as a ventral diverticulum during approximately the fourth week of gestation and then undergoes further branching and differentiation. Ab-

errational development can result in a bronchogenic cyst as part of the tracheobronchial tree, separate from the primary airway. Bronchogenic cysts occur most frequently in the middle mediastinum but may occur in multiple other sites, including the lung parenchyma and outside the thorax.

Most adult patients with bronchogenic cysts experience no symptoms. The most common symptoms, when present, are due to compression of mediastinal structures or infection or hemorrhage within the cyst. While it is generally accepted that cysts causing symptoms should be excised, management of asymptomatic bronchogenic cysts remains controversial. Because children have extremely compliant airways, respiratory compromise may occur easily, and resection of asymptomatic cysts is recommended. The optimal management of asymptomatic cysts in adults is less clear. Some clinicians prefer to follow such patients clinically and operate only if significant symptoms develop. Two recent surgical series, however, support surgical excision of asymptomatic cysts to avoid the morbidity associated with operating on a complicated cyst. Needle aspiration may be useful to completely decompress a cyst that is compressing vital structures, but this does not represent a definitive management strategy. Bronchogenic cysts are

benign, and radiation therapy and chemotherapy are not treatment options.

SUNIT PATEL, MD
Department of Pulmonary and
Critical Care Medicine
The Cleveland Clinic Foundation

DAVID P. MEEKER, MD
Genzyme Corp.
Cambridge, Mass

SUGGESTED READING

O'Rahilly R, Muller F. Respiratory and alimentary relations in staged human embryos. New embryological data and congenital anomalies. *Ann Otol Rhinol Laryngol* 1984; **93**:421-429.

Patel SR, Meeker DP, Biscotti CV, Kirby TJ, Rice TW. Presentation and management of bronchogenic cysts in the adult. *Chest* 1994; **106**:79-85.

Pearson FG, ed. Mediastinal tumors. *Semin Thorac Cardiovasc Surg* 1992; **4**:1-70.

Pierson DJ. Disorders of the mediastinum. General principles and diagnostic approach. In Murray JF, Nadel JA, editors. *Textbook of respiratory medicine*. 2nd ed. Philadelphia: WB Saunders; 1994:2235-2249.

Rice TW. Benign neoplasm and cysts of the mediastinum. *Semin Thorac Cardiovasc Surg* 1992; **4**:25-33.

St Georges R, Deslauriers J, Duranceau A, et al. Clinical spectrum of bronchogenic cysts of the mediastinum and lung in the adult. *Ann Thorac Surg* 1991; **52**:6-13.

