



# Antineutrophil cytoplasmic antibodies in Wegener's granulomatosis and other diseases: clinical issues

CLAUDIO GALPERIN, MD, AND GARY S. HOFFMAN, MD

■ **BACKGROUND** An association between antineutrophil cytoplasmic antibodies (ANCA) and nonimmune complex-mediated glomerulonephritis was first reported over 10 years ago. In Wegener's granulomatosis, the antibody usually binds proteinase 3. Antibodies to a variety of other antigens have been identified in a broad range of diseases.

■ **SUMMARY** The typical coarse, granular cytoplasmic ANCA pattern on indirect immunofluorescence almost always indicates reactivity with proteinase 3, whereas the perinuclear ANCA pattern may reflect reactivity with a host of different antigens. Antibodies to proteinase 3 are overwhelmingly associated with Wegener's granulomatosis (specificity  $\geq 90\%$ ). In a significant number of patients, however, disease activity is not linked to an ANCA titer. ANCA may play a role in the pathogenesis of many types of inflammatory conditions. Antibodies to proteinase 3 may be important in predisposing to Wegener's granulomatosis, but definitive in vivo proof of their role is not yet available.

■ **KEY POINTS** The presence of cytoplasmic ANCA in a patient who is suspected to have Wegener's granulomatosis is strong circumstantial evidence in support of that diagnosis. However, it does not represent absolute proof and should be viewed with skepticism if the clinical presentation is atypical. Conversely, a negative ANCA in the setting of a typical presentation should not rule out Wegener's granulomatosis. Because ANCA titers may not always vary in tandem with disease activity, the decision to modify therapy for Wegener's granulomatosis should continue to be based on clinical judgment.

■ **INDEX TERMS:** AUTOANTIBODIES; WEGENER'S GRANULOMATOSIS; FLUORESCENT ANTIBODY TECHNIQUE; ENZYME-LINKED IMMUNOSORBENT ASSAY; VASCULITIS; RHEUMATIC DISEASES; INFLAMMATORY BOWEL DISEASES  
■ CLEVELAND CLIN J MED 1994; 61:416-427

From the Department of Rheumatic and Immunologic Disease, The Cleveland Clinic Foundation.

Address reprint requests to G.S.H., Department of Rheumatic and Immunologic Disease, A50, The Cleveland Clinic Foundation, 9500 Euclid Avenue, Cleveland, OH 44195.

**A**NTINEUTROPHIL cytoplasmic antibodies (ANCAs) can be detected in the sera of most patients with Wegener's granulomatosis, as well as some patients with different forms of vasculitis, rheumatic diseases, and other inflammatory conditions. Do these antibodies play a role in causing diseases? Are ANCA titers a useful guide to disease activity?

Knowledge of this fascinating topic has expanded tremendously over the past decade, but many questions remain. In this article we will review what we have learned—and what we still do not know.

## WHAT IS ANCA?

Polymorphonuclear granulocytes contain two main kinds of granules: primary (or alpha) and secondary. The primary granules, formed during the promyelocytic differentiation stage, contain mostly myeloperoxidase, numerous serine proteases (including neutrophil elastase, cathepsin G, and proteinase 3), and lysozymes and other microbicidal enzymes such

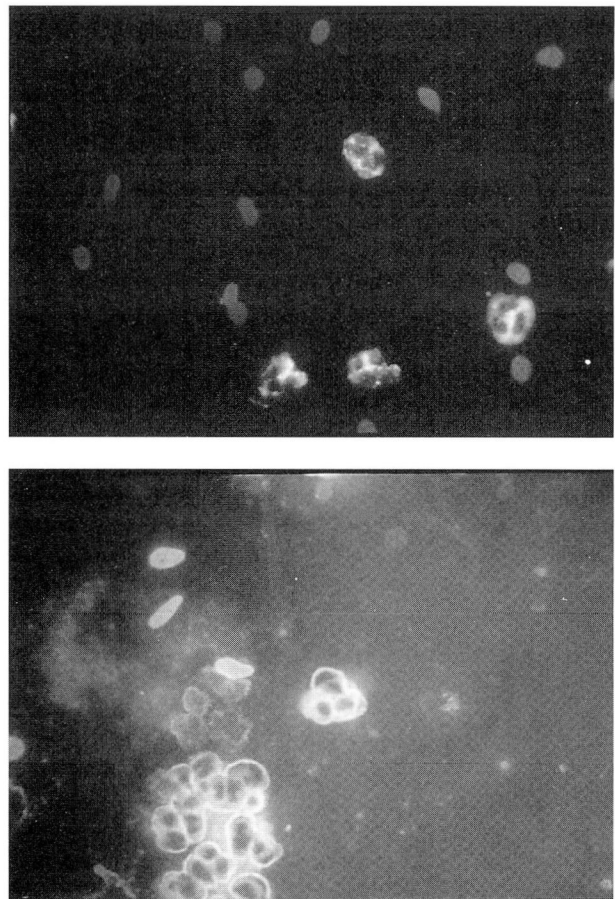
as defensins. The enzymes within these granules play an important role in the digestion of foreign material. Monocytes possess similar granules that contain myeloperoxidase, elastase, and proteinase 3. The secondary granules, formed later during cellular differentiation, contain lactoferrin and vitamin B-12 binding protein.<sup>1</sup>

ANCA reacts to proteins within neutrophil granules and monocyte lysosomes. Although recent studies, including protein purification and amino-acid and DNA sequencing, have defined a variety of ANCA autoantigens, antibodies against neutrophil constituents have been known for some time. As early as 1964 an antinuclear factor specific for leukocytes was reported by Farber et al.<sup>2</sup> In 1972 Wiik et al<sup>3</sup> developed a standardized technique that used ethanol fixation of granulocytes to identify granulocyte-specific antinuclear antibodies. These antibodies were found to occur mostly in patients with rheumatoid arthritis and Felty's syndrome.

Cytoplasmic staining of granulocytes was first recognized by Davies et al<sup>4</sup> in 1982 in patients with segmental necrotizing glomerulonephritis without immune-complex deposition. Five of eight patients also had pulmonary infiltrates. In 1985 van der Woude et al<sup>5</sup> described the same ANCA pattern of staining in 25 of 27 patients with active Wegener's granulomatosis. That association and the suspicion that ANCA was important in the pathogenesis of Wegener's granulomatosis led to intense interest in these antibodies.

In sera from patients with Wegener's granulomatosis, indirect immunofluorescent techniques generally reveal a coarse granular staining pattern of cytoplasmic neutrophil granules (cytoplasmic, or c-ANCA). Subsequently, the antigen responsible for this pattern was found to be a 29-kD serine proteinase, proteinase 3.<sup>6-8</sup> Falk and Jennette<sup>9</sup> described a second indirect immunofluorescent staining pattern in ethanol-fixed neutrophils, perinuclear, or p-ANCA. Patients with p-ANCA often had crescentic glomerulonephritis with or without systemic vasculitis. The antigen most commonly recognized by the sera from these patients was myeloperoxidase.

In addition to the two major recognized ANCA antigens (proteinase 3 and myeloperoxidase), a number of other ANCA-positive primary granule antigens have been described. However, they are less common, and there is yet no convincing evidence to support an association with vasculitis. For example, in one study antielastase antibodies were

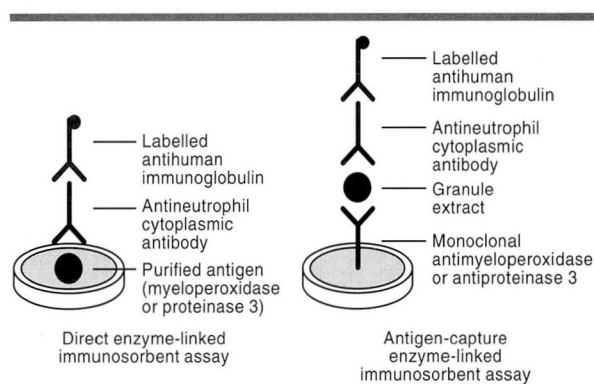


**FIGURE 1.** Indirect immunofluorescent studies demonstrating cytoplasmic ANCA (top) and perinuclear ANCA (bottom). Cytoplasmic ANCA is characterized by diffuse granular staining of the cytoplasm, with accentuation between the lobes of the nucleus and no staining of the nucleus itself. Perinuclear ANCA is characterized by staining of the nucleus, the peripheral part of the nucleus, or the perinuclear area. On some preparations, staining of the cell membrane may also be apparent.

found in only six of 1102 serum samples that produced a perinuclear or atypical cytoplasmic staining pattern.<sup>10</sup> In only two of 315 patients, with different forms of vasculitides and related disorders, were antibodies to elastase present.

The antibody response in ANCA-positive vasculitis may not be restricted to neutrophil granule proteins. Recently, Moodie et al<sup>11</sup> found that of 59 patients with vasculitides and sera containing p-ANCA or c-ANCA, the majority had antibodies that reacted with a cytosolic extract of neutrophils on Western blot analysis. Nearly 40% of these sera





**FIGURE 2.** Solid-phase assay for ANCA to myeloperoxidase and proteinase 3. In the direct enzyme-linked immunosorbent assay (ELISA), purified antigen is bound to the wells. In the antigen-capture ELISA, specific antibody in the well captures the relevant antigen from a crude extract of neutrophil proteins.

had antibodies against alpha enolase, a cytosolic protein weighing 48 kD.

#### HOW IS ANCA DETECTED?

Several methods have been used to detect ANCA, including indirect immunofluorescence, enzyme-linked immunosorbent assay (ELISA), radioimmunoassay, Western blot technique, dot blot technique, and immunoprecipitation. Currently, ANCA is generally detected and defined by the first two methods.

#### Indirect immunofluorescence

Indirect immunofluorescence utilizes isolated normal human neutrophils or cells from the HL-60 promyelocytic leukemic cell line, which are cytocentrifuged onto slides, fixed in ethanol, incubated with dilutions of patients' sera, and then stained with fluoresceinated secondary antihuman immunoglobulin antibodies.<sup>12</sup> Two main patterns are recognized, c-ANCA and p-ANCA (Figure 1). The p-ANCA type is indistinguishable from the granulocyte-specific antinuclear antibody pattern. Lymphocytes, if present on the slide, should not be stained when a true ANCA pattern is seen.

Since the antigens that give rise to the c-ANCA and p-ANCA patterns are both present in the primary granules, how could they give two different immunofluorescent patterns? The p-ANCA pattern is a fixation artifact. During fixation with ethanol,

the granule membranes are disrupted and basic proteins (positively charged), including myeloperoxidase, elastase, and lactoferrin, are redistributed to the negatively charged nucleus. If fixation is done with formaldehyde, which prevents the redistribution of proteins, the artifactual change does not occur and the c-ANCA pattern is seen.

#### Enzyme-linked immunosorbent assay (ELISA)

Problems with interpreting the immunofluorescent patterns prompted development of solid-phase assays, which allow large-scale testing and better quantification and determination of ANCA specificity. Currently, to determine or confirm seropositivity for c-ANCA, either a primary granule extract or purified proteinase 3 is used. Antigen may be bound to the wells either directly, by using purified antigen, or indirectly, by binding a monoclonal antibody to the well, which then captures the relevant antigen from a crude extract of neutrophil proteins (Figure 2). After the sites that have not captured a specific antigen are blocked with bovine serum albumin to avoid nonspecific binding of immunoglobulin to the wells, the samples are incubated with dilutions of sera from patients and control subjects. Bound antibody is then detected with a labeled secondary antibody.<sup>12</sup>

To assess the validity of solid-phase assays, it is important to know the nature of the antigen preparation used as substrate. Denaturation of the tertiary structures of proteinase 3 and myeloperoxidase, which can occur during purification of the antigen, leads to loss of the epitopes recognized by the autoantibodies. This is particularly true for proteinase 3. Although commercial preparations to detect myeloperoxidase antibodies appear reliable, the different proteinase 3 preparations for the detection of antiproteinase 3 provide discrepant results and, so far, have not been as reliable.

#### WHAT IS THE CORRELATION BETWEEN ELISA AND IMMUNOFLUORESCENT ASSAYS?

Some studies using immune affinity-purified proteinase 3 and antigen-capture ELISA showed that almost all c-ANCA-positive sera react with proteinase 3 in ELISA.<sup>13,14</sup> More recently, in other series, only 65% to 80% of the c-ANCA-positive sera were shown to react with proteinase 3.<sup>15,16</sup> These discrepancies could be the result of differences in isolation techniques. However, c-ANCA-positive sera may

contain antibodies directed against antigens other than proteinase 3. Therefore, the correlation between c-ANCA-positive sera and antibodies to proteinase 3 is not absolute, and disparities may not be solely based on technical differences.<sup>1</sup>

The correlation between p-ANCA and antibodies to myeloperoxidase is even less constant, even with careful attention to technique. Antibodies to other cytoplasmic and even nuclear proteins of neutrophils produce staining that cannot be reliably distinguished from that due to antimyeloperoxidase. Indeed, most sera that produce p-ANCA do not contain antimyeloperoxidase antibodies. Ulmer<sup>17</sup> found that of 3000 sera screened for ANCA, 620 had a perinuclear pattern; 86% were positive because of antinuclear antibody reactivity, and only about 10% were positive to myeloperoxidase by ELISA. Indirect immunofluorescence demonstrating p-ANCA is not synonymous with antimyeloperoxidase and should not be interpreted without an antigen-specific immunoassay.

---

#### WHICH DISEASES ARE ASSOCIATED WITH ANCA?

---

##### Wegener's granulomatosis

Several studies performed between 1985 and 1990 evaluated sera from many patients with Wegener's granulomatosis and up to 1657 controls. At present, the sensitivity of c-ANCA for detecting generalized, active, histologically proven Wegener's granulomatosis is at least 80%, and the specificity may be up to 97% (Table). However, in patients with limited disease (no renal involvement), the sensitivity is only approximately 60% to 70%. In fact, many patients with limited disease and negative tests for ANCA who have not been treated have subsequently developed ANCA. On occasion, false-positive c-ANCA tests have also been reported, including cases of tuberculosis and undifferentiated non-Hodgkin's lymphoma that were incorrectly diagnosed as Wegener's granulomatosis.<sup>18</sup>

Nonetheless, indirect immunofluorescence is very useful in evaluating illnesses compatible with Wegener's granulomatosis. Although active Wegener's granulomatosis is almost always associated with the presence of c-ANCA, a negative test should not dissuade one from making this diagnosis in the appropriate clinical setting when histopathologic studies of involved organs reveal typical features and infection has been ruled out.

##### Is the ANCA titer useful in monitoring disease during patient follow-up?

Early reports, based on small numbers of patients, suggested that a rise in the c-ANCA titer predicted disease exacerbation. Although subsequent studies confirmed that ANCA titers tend to vary in parallel with disease activity, a significant number of patients have discordance between disease activity and ANCA titers. In a recent study,<sup>19</sup> serial ANCA titers were prospectively determined in 72 patients and compared with variations in disease activity. Changes in serial titers temporally correlated with a change in disease status in only 64%. Only 24% of patients had a rise in c-ANCA titer that preceded clinical exacerbations. A subset of 16 of 72 patients in this study had at least a fourfold rise in c-ANCA titers. Seven (44%) either continued in sustained remission or were paradoxically improving while c-ANCA titers continued to increase. Thus, a rise in titer alone should not be considered adequate evidence of clinical exacerbation and does not justify initiating or increasing potentially toxic immunosuppressive therapies.

##### Other forms of vasculitis

Microscopic polyarteritis is a small-vessel non-granulomatous vasculitis that may also involve medium-sized vessels. It is often associated with crescentic necrotizing glomerulonephritis.

Uniform criteria for diagnosing microscopic polyarteritis do not exist. Many authors, for example, have applied this term on the basis of renal or skin biopsies and have neither studied the airway nor performed biopsies of lesions in other sites. Some of the confusion regarding ANCA sensitivity and specificity stems from authors not employing a standard classification or not having adequately investigated patients' symptoms. Consequently, the results of studies emphasizing diagnostic measures, treatment, and outcome are quite varied. In some reports, antiproteinase 3 and antimyeloperoxidase were each present in approximately 50% of patients with microscopic polyarteritis,<sup>20</sup> but in other series, p-ANCA was four times more frequent than c-ANCA.<sup>15</sup>

Myeloperoxidase-related p-ANCA has been reported in small series of patients with Churg-Strauss syndrome. ANCA has also been occasionally noted in the serum of children with Kawasaki's disease.<sup>21</sup> In Kawasaki's disease, the binding pattern reported is diffuse with linear accentuations, and the target of

**TABLE**  
DISEASES ASSOCIATED WITH ANTINEUTROPHIL CYTOPLASMIC ANTIBODIES (ANCA)

Disease	ANCA pattern	Target antigen	Remarks
Systemic vasculitis Wegener's granulomatosis	Cytoplasmic, perinuclear	Proteinase 3, myeloperoxidase	Cytoplasmic ANCA and antiproteinase 3 have high sensitivity and specificity; perinuclear ANCA and antimyeloperoxidase rarely occur
Microscopic polyarteritis	Cytoplasmic, perinuclear	Proteinase 3, myeloperoxidase	Sensitivity and specificity studies suffer from the limitation of nonuniform criteria
Churg-Strauss syndrome	Perinuclear	Myeloperoxidase	Sensitivity and specificity are unknown; very small series
Kawasaki's disease	Atypical	Unknown	
Classic polyarteritis nodosa	Perinuclear, cytoplasmic	Proteinase 3, myeloperoxidase	Very low sensitivity
Rheumatoid arthritis	Perinuclear, atypical	Unknown, nuclear proteins, myeloperoxidase, lactoferrin, elastase	
Systemic lupus erythematosus	Perinuclear	Myeloperoxidase, lactoferrin	Antinuclear antibodies can cause perinuclear ANCA pattern in indirect immunofluorescent test for ANCA
Antiglomerular basement membrane disease	Perinuclear	Myeloperoxidase	No cross-reactivity between ANCA and antiglomerular-basement membrane antibodies
Inflammatory bowel diseases Ulcerative colitis	Perinuclear, atypical	Cathepsin G, lactoferrin, unknown	Moderate sensitivity; low specificity
Crohn's disease	Atypical, perinuclear	Cathepsin G, lactoferrin, unknown	Low sensitivity and specificity
Other diseases Chronic liver diseases	Perinuclear, atypical	Cathepsin-G, lactoferrin, unknown	
Primary sclerosing cholangitis	Perinuclear, atypical	Cathepsin G, lactoferrin, unknown	
Sweet's syndrome	Atypical	Unknown	Small series of patients studied; not confirmed
Cystic fibrosis	?	Unknown	Small series of patients studied; not confirmed
Human immunodeficiency virus infection	Perinuclear, cytoplasmic, atypical	Unknown, proteinase 3, myeloperoxidase	Occasionally positive reactions are more often due to nongranule cytosolic antigens
Acute or chronic infection	?	Unknown	Small series of patients studied; not confirmed

the ANCA was not identified. ANCA has rarely been associated with classic polyarteritis nodosa.<sup>22</sup>

### Rheumatic diseases

The specificity of the granulocyte-specific antinuclear antibody in patients with rheumatoid arthritis and Felty's syndrome remains unknown. The reported prevalence of atypical ANCA varies from 0% to 43% in rheumatoid arthritis and from 33% to 50% in Felty's syndrome.<sup>23-25</sup> Antielastase, antimyeloperoxidase, and antilactoferrin antibodies have been described, but many sera do not react with any of these enzymes by ELISA, suggesting other as yet unidentified cytoplasmic antigens are the target molecules.

Although antinuclear antibodies seen in systemic lupus erythematosus (SLE) and other autoimmune diseases can produce an indirect immunofluorescent pattern in human neutrophils that is indistinguishable from p-ANCA, some patients with SLE have been reported to have p-ANCA but no antinuclear antibodies (substrate: Hep-2 cells, which lack primary granule proteins). Occasional SLE sera may react with myeloperoxidase or lactoferrin.

Some patients with ANCA have antiglomerular-basement membrane antibodies with specificity for the NC1 domain of type IV collagen. In a study of 37 patients with antiglomerular-basement membrane disease, 12 had ANCA, which was directed



against myeloperoxidase in 11.<sup>26</sup> Whether an ANCA-related mechanism contributes to injury in some cases of antglomerular-basement membrane disease is not known. However, the coexistence of ANCA and antglomerular-basement membrane antibodies deserves special attention. The two classes of antibodies are not cross-reactive, and they are both so rare that their coexistence is not likely to be coincidental.<sup>12</sup>

# Inflammatory bowel disease

In 1983, antineutrophil antibodies were first recognized to occur in some patients with ulcerative colitis.<sup>27</sup> They were originally described by indirect immunofluorescence as granulocyte-specific antinuclear antibodies. Since then, increasing scientific data have accumulated regarding the presence of these autoantibodies in inflammatory bowel disease. P-ANCA can be found in 40% to 70% of sera from patients with ulcerative colitis and in 5% to 35% of patients with Crohn's disease.

The staining pattern of ethanol-fixed neutrophils differs from the perinuclear pattern of antimyeloperoxidase ANCA. In fact, only rarely do these sera react with myeloperoxidase in ELISA. The most prevalent reactivity of these sera was recently shown to be against cathepsin G.<sup>28</sup> This may occur in as many as 68% of patients with ulcerative colitis.

These antibodies are not restricted to ulcerative colitis or Crohn's disease and have been described in primary sclerosing cholangitis and a variety of chronic hepatic diseases. Occasionally, discordant results occur between indirect immunofluorescence and cathepsin G ELISA. In fact, some patients' sera react against other antigens, such as lactoferrin and other antigens that have not yet been fully characterized.

# Other diseases

In one series of seven patients with a clinical and histologic diagnosis of Sweet's syndrome, six had weak, diffuse cytoplasmic fluorescence.<sup>30</sup> Two of the six ANCA-positive patients had recurrent Sweet's syndrome alone, while the other four had associated Crohn's disease, chronic myeloid leukemia, carcinoma of the stomach, and rheumatoid arthritis. The antigen specificity of these autoantibodies was not identified.

Occasionally, patients with symptomatic human immunodeficiency virus infections have either p-

ANCA or c-ANCA detected by indirect immunofluorescence; these sera infrequently react to proteinase 3 and myeloperoxidase.<sup>31,32</sup> Other conditions such as chronic and acute airway infections and cystic fibrosis have occasionally been associated with ANCA, but this has not been confirmed.

## DOES ANCA CAUSE WEGENER'S GRANULOMATOSIS AND OTHER FORMS OF NECROTIZING VASCULITIS?

Although the association of ANCA with some systemic necrotizing vasculitides and nonimmune-complex-mediated glomerulonephritis is well established, its pathogenic role in these diseases is not clear. Several *in vitro* and *ex vivo* studies support the hypothesis that these antibodies are more than an epiphenomenon. One hypothesis suggests that ANCA antigens are released by neutrophils, bind to vessel walls by ionic interactions, and subsequently bind to circulating ANCA, thus resulting in immune complexes forming *in situ* in vessel walls.

The major problem with this theory is the observation that ANCA-associated vasculitides are characterized by the absence or paucity of immunoglobulin and complement in vessel walls. Alternatively, proteinase 3 released by polymorphonuclear granulocytes and bound to endothelial cells could be presented to T cells in the context of class II major histocompatibility complex and adhesion molecules. Activation of T cells would then stimulate B cells to produce gamma immunoglobulin G (IgG) ANCA. Under basal conditions, arterial smooth muscle cells and endothelial cells express class I (but not class II) antigens on their surfaces. Treatment of endothelial cells with interferon gamma induces expression of class II antigens on endothelial cell membranes.<sup>33</sup>

The pathogenic theory tested most extensively proposes that circulating ANCAs are capable of enhancing activation of neutrophils and monocytes, causing them to adhere to and injure vessel walls. For this to occur: (1) ANCAs must interact with viable leukocytes in the blood, (2) ANCAs must induce neutrophil activation, and (3) ANCA-activated leukocytes must injure vessels.<sup>34</sup>

## Can ANCA react with viable leukocytes in the blood?

The antigens to which ANCAs are directed are located in neutrophil granules and monocyte peroxidase-positive lysosomes, but not on the cell sur-

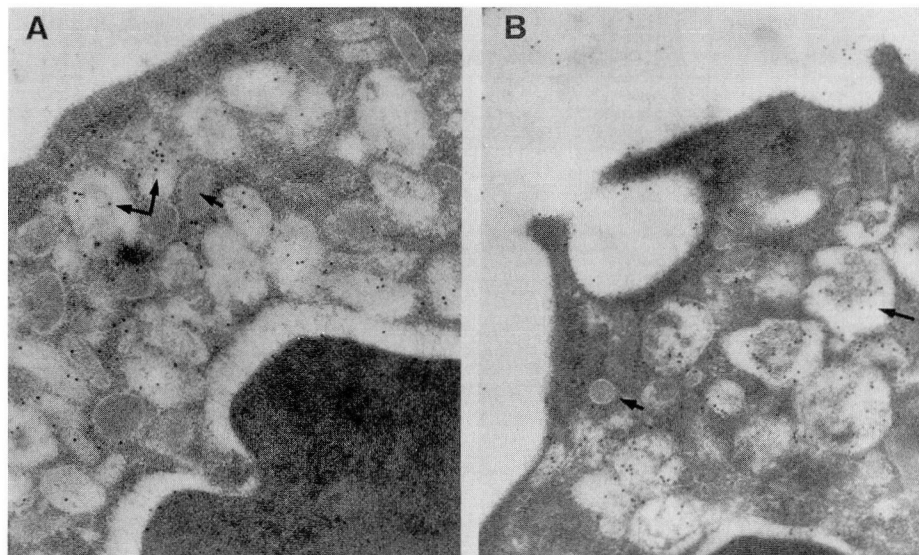


FIGURE 3. Immunogold labeling of an unprimed (A) and a tumor necrosis factor-primed (B) neutrophil with rabbit antihuman myeloperoxidase. In unprimed neutrophils the primary granules (large arrows) are labeled but the secondary granules are not (small arrow), and there is no cell surface labeling. In primed neutrophils, gold particles are present in primary granules (large arrow), in vacuoles opening at the cell surface, and focally along the surface membrane, but not in secondary granules (small arrows). From Charles LA, Falk RJ, Jennette JC. Reactivity of anti-neutrophil cytoplasmic antibodies with mononuclear phagocytes. *J Leukoc Biol* 1992; 51:65–68 with permission.

face of quiescent neutrophils and monocytes. In order to establish that ANCA may be pathogenic, the problem of access of antibody to intracellular, inaccessible antigens needs to be resolved.

Polymorphonuclear granulocytes and monocytes can be “primed” to make their antigens more accessible, an effect that has been investigated using flow cytometry. Neutrophils and monocytes, in response to inflammatory stimuli, pass through stages of up-regulation during which ANCA antigens such as myeloperoxidase and proteinase 3 are released and bound at the cell surface. Interleukin 1 and tumor necrosis factor, for example, which are released into the circulation at sites of inflammation, can prime neutrophils and monocytes, leading to translocation of c-ANCA and p-ANCA antigens to the cell surface.

Immunoelectron microscopy has been used to demonstrate that activation of polymorphonuclear granulocytes is associated with the fusion of the primary granules with the cell membrane (Figure 3).<sup>35</sup> Renal biopsy specimens from patients with ANCA-positive glomerulonephritis have been shown to contain monocytes and resident renal cells that are

activated and produce tumor necrosis factor alpha and interleukin beta.<sup>36</sup> These cytokines may in turn activate neutrophils, which then express myeloperoxidase, proteinase 3, or other protein antigens on their membranes.

### Can ANCA induce leukocyte activation?

Numerous studies have examined the effects of ANCA on the activation of leukocytes and on their adherence to vessel walls. To mediate injury, neutrophils and monocytes must be stimulated to release toxic products, eg, granule and lysosome enzymes and reactive oxygen metabolites.<sup>37</sup>

Generation of reactive oxygen species from neutrophils stimulated with

ANCA was initially demonstrated by Falk et al.<sup>38</sup> C-ANCA- and p-ANCA-positive sera, IgG ANCA, and heterologous antimyeloperoxidase antibodies were able to stimulate a time-dependent release of reactive oxygen species. These effects were augmented if neutrophils were initially primed with tumor necrosis factor. Negative control sera, IgG, and heterologous antibodies stimulated significantly less generation of reactive oxygen species. Antibodies directed against proteinase 3, lactoferrin, and cathepsin G also stimulated primed neutrophils to release superoxide.<sup>37</sup> Similarly, peripheral blood monocytes were found to produce and release superoxide when stimulated by antimyeloperoxidase antibodies.

In addition to inducing a respiratory burst with release of toxic oxygen metabolites, IgG ANCA also causes neutrophils to degranulate. Although priming with tumor necrosis factor is a requirement for ANCA-induced degranulation, it does not induce degranulation by itself or when combined with exposure to control IgG. The release of neutrophil enzymes is the result of active secretion rather than cell death.<sup>38</sup>



### Can ANCA-activated leukocytes injure endothelial cells?

Cultured human endothelial cells from umbilical veins have been used in *in vitro* models to assess the interaction of ANCA-activated neutrophils with vessel walls. Antimyeloperoxidase has been shown to induce tumor necrosis factor-primed neutrophils to adhere to endothelial cells.<sup>39</sup> Release assays using radiolabeled chromium have been used to demonstrate killing of activated endothelial cells by myeloperoxidase-activated polymorphonuclear granulocytes.<sup>39</sup>

### Endothelial cells: just a target?

The normal endothelial surface has anticoagulant properties and, when unperturbed, displays low adhesiveness for platelets and leukocytes. However, inflammatory mediators and cytokines can lead to focal activation, a procoagulant tendency, and increased leukocyte adhesion. Increased neutrophil adhesion to cultured endothelium can be induced by tumor necrosis factor alpha, interleukin 1, or interferon gamma, which up-regulate endothelial cell adhesion molecules such as intracellular adhesion molecule 1 (ICAM-1, CD54). Incubation of endothelial cells with tumor necrosis factor alpha and c-ANCA-positive sera leads to enhanced procoagulant activity and neutrophil adhesion.

Circulating soluble ICAM-1 isoforms are known to be elevated in inflammatory and autoimmune disorders such as SLE, rheumatoid arthritis, and Wegener's granulomatosis.<sup>40</sup> Levels of soluble ICAM-1 were significantly higher in sera from patients with active Wegener's than from patients in remission or from healthy controls. Integrin molecules play an important role in this phenomenon. ANCA-enhanced granulocyte adhesion to cultured endothelium can be inhibited by monoclonal antibodies to lymphocyte function-associated antigen 1 (LFA-1, CD11a/CD18), the leukocyte counter-receptor to ICAM-1.

Mayet et al<sup>41</sup> recently reported the presence of proteinase 3 in the cytoplasm of untreated cultured endothelial cells. They have shown that endothelial-cell stimulation with tumor necrosis factor alpha produces a marked increase of proteinase 3 in the Golgi region and a time-dependent translocation to the cell surface. This potentially important finding indicates that vascular endothelial cells expressing membrane-bound proteinase 3 may be a direct target of ANCA.

---

### WHAT IS THE ROLE OF PROTEINASE 3?

---

Recently, the gene encoding proteinase 3 was cloned and sequenced.<sup>42</sup> The gene spans approximately 6.5 kilobase pairs. Amplification of proteinase 3 from a human-hamster hybrid cell line localizes the gene to human chromosome 19. Proteinase 3 degrades a variety of extracellular matrix proteins, including elastin, fibronectin, laminin, and type IV collagen *in vitro*, and causes emphysema when administered by tracheal insufflation in hamsters.<sup>43</sup> Such broad proteolytic activity may be important in facilitating the migration of polymorphonuclear granulocytes through basement membranes or in destroying microbes. Several authors have shown that proteinase 3 is identical to myeloblastin,<sup>44</sup> a protein that may influence normal myeloid differentiation.<sup>45</sup> Whether this function of proteinase 3 is affected by ANCA is unknown.

---

### WHAT IS THE ROLE OF MONOCYTES, MACROPHAGES, AND T CELLS?

---

Macrophages and T cells are included in lesions of Wegener's granulomatosis. Macrophages process and present antigen to T cells and secrete cytokines (eg, tumor necrosis factor and interleukin 1) that may facilitate lymphocyte, neutrophil, and endothelial-cell activation. Activated endothelial cells have increased expression of adhesion molecules for leukocytes and alter their usual anticoagulant surfaces to become procoagulant. Mononuclear cells from patients with active systemic vasculitis produce increased amounts of tumor necrosis factor alpha.<sup>46</sup> Serum from such patients contains increased concentrations of soluble interleukin-2 receptor, suggesting activation of helper T cells.<sup>47</sup> Partially purified proteinase 3 has also been demonstrated to enhance *in vitro* T-cell proliferation.<sup>48</sup> Autoreactive T cells can induce B-cell differentiation into plasma cells capable of IgG production.

---

### WHAT IS THE ROLE OF ALPHA-1-ANTITRYPSIN?

---

Alpha-1-antitrypsin is the major inhibitor of proteinase 3. In hamsters, instillation of proteinase 3 into the airway causes emphysema; in man, severe alpha-1-antitrypsin deficiency is a risk factor for the development of panlobular emphysema. Alpha-1-antitrypsin is encoded by a polymorphic gene with more than 75 alleles, defining severe, moderate, and



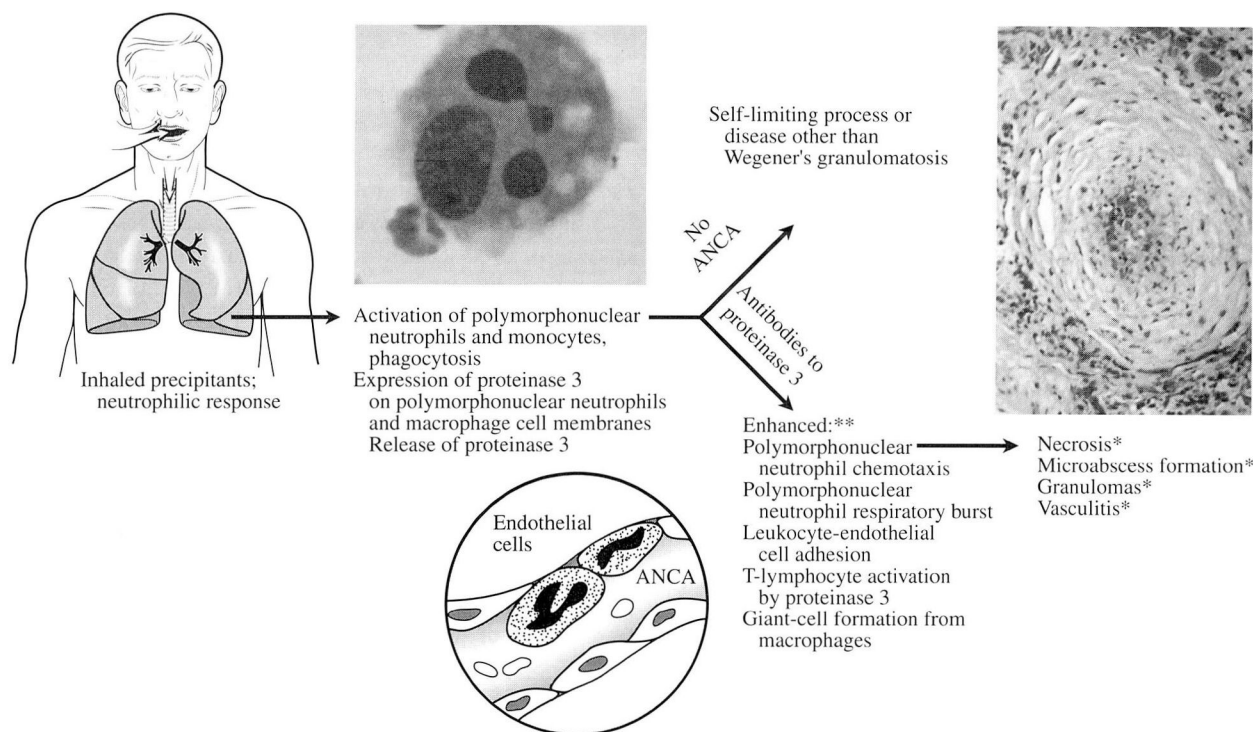


FIGURE 4. Hypothetical scheme of the pathogenesis of Wegener's granulomatosis, combining data observed in vivo (asterisk) in patients, and ex vivo (double asterisk). It is not certain whether the effects of antineutrophil cytoplasmic antibodies that lead to enhanced polymorphonuclear neutrophil chemotaxis, release of oxygen radicals, T-lymphocyte activation, and vascular injury in the laboratory can account for the typical histopathologic abnormalities of Wegener's granulomatosis in vivo. Adapted from Hoffman, reference 17, with permission.

nondeficient protease inhibitor phenotypes. Preliminary data from a recent study indicated a significant association between severe and moderately deficient protease inhibitor phenotypes and antiproteinase 3-positive systemic vasculitis in several patients.<sup>49</sup> Some authors have suggested that antiproteinase 3 antibodies may encourage tissue necrosis by interfering with inactivation of proteinase 3 by alpha-1-antitrypsin. However, the significance of the tripartite interaction of ANCA, proteinase 3, and alpha-1-antitrypsin in vivo remains unclear.

#### DOES INFECTION CAUSE OR TRIGGER RELAPSES IN WEGENER'S GRANULOMATOSIS?

Several unconvincing attempts to link infection to Wegener's granulomatosis have been made. One report noted that in 38% of patients with Wegener's granulomatosis, the onset was in winter (a period of

presumed increased respiratory illness), compared with 11% in whom disease began in the summer.<sup>50</sup> These observations have not been confirmed. In a larger series of 158 patients,<sup>51</sup> neither preceding infections nor seasonal trends appeared to be associated with disease onset.

Of possibly greater importance, analysis of bronchoalveolar lavage fluid in patients with recent-onset disease revealed no bacteria, fungi, mycoplasma, respiratory viruses, or viral-like inclusions.<sup>52</sup> Open-lung biopsy specimens demonstrating typical histologic changes of Wegener's granulomatosis were selected for in situ hybridization studies and showed no nucleic-acid sequences homologous to adenovirus, cytomegalovirus, enterovirus, herpes simplex virus, varicella zoster virus, influenza, parainfluenza, rhinovirus, or respiratory syncytial virus.<sup>52</sup>

If an infectious agent is responsible for Wegener's granulomatosis, its presence is either very transient

or it is an unusual organism, not identified by most currently available routine or research laboratory techniques. Nevertheless, the most striking aspect of bronchoalveolar lavage analysis in Wegener's granulomatosis was the finding of neutrophilic alveolitis and the increased concentration of IgG c-ANCA in bronchoalveolar lavage fluid of patients with active Wegener's granulomatosis, but not during periods of remission. Some patients with neutrophilic alveolitis were asymptomatic and had normal chest radiographs, suggesting that even subclinical airway stimulation could be an obligatory trigger for systemic disease.

#### DOES INHALATION OF PARTICULATES TRIGGER WEGENER'S GRANULOMATOSIS?

Since the original reports by Klinger<sup>53</sup> and Wegener,<sup>54</sup> it has been postulated that airway stimulation is necessary for disease expression. Bronchoalveolar lavage studies indicate that neutrophilic alveolitis is an important consequence of airway stimulation in Wegener's granulomatosis.<sup>52</sup> It has been suggested that such an inflammatory response in patients with the capacity to produce antibodies to proteinase 3 may lead to enhanced pulmonary and systemic inflammation (Figure 4).<sup>55</sup>

This hypothesis does not imply that the stimuli have to be infectious agents. Noninfectious inhalants that cause neutrophilic alveolitis may trigger Wegener's granulomatosis in patients who produce ANCA. For example, inhalation of silica is known to induce neutrophilic infiltrates. Increasing numbers of patients have been recognized in whom silica inhalation has produced pulmonary and renal disease.<sup>56,57</sup> Injected or implanted silica gels may induce a variety of glomerular and tubular lesions in rats and rabbits.<sup>58</sup> The concept that noninfectious agents such as silica may trigger ANCA-associated vasculitis is very credible and deserves further investigation.

#### IS THERE A GENETIC PREDISPOSITION TO WEGENER'S GRANULOMATOSIS?

Data that examine the association between Wegener's granulomatosis and HLA antigens are contradictory, and efforts have suffered from the limitations of small sample sizes in a rare disease. A recent study of HLA alleles in 83 patients failed to identify any unique markers as being unusually com-

mon in Wegener's granulomatosis (Hoffman, unpublished data). From these studies, it appears that if there is a genetic predisposition to developing Wegener's granulomatosis, the genetic element that may cause susceptibility is not apparent from studies of currently known HLA antigens.

#### SUMMARY

During the past 12 years, we have learned that ANCA is part of a large family of antibodies that react with many different cytoplasmic antigens in neutrophils and monocytes. Our knowledge of associations of different antibodies with specific diseases continues to expand. At this point, it is clear that the typical c-ANCA pattern almost always indicates reactivity with proteinase 3, whereas the p-ANCA pattern may reflect reactivity with a host of different antigens.

Antibodies to proteinase 3 are overwhelmingly associated with Wegener's granulomatosis (specificity  $\geq 90\%$ ). The presence of c-ANCA in patients suspected of having Wegener's granulomatosis is strong circumstantial evidence in support of that diagnosis. However, it does not represent definitive proof. Because titers may or may not vary in tandem with disease activity, the decision to modify therapy for Wegener's granulomatosis should continue to be based on clinical judgment rather than on imperfect surrogate markers.

The greatest excitement in the evolving ANCA story relates to the possible role these antibodies may play in the pathogenesis of systemic vasculitis. Although increasing circumstantial evidence suggests that antibodies to proteinase 3 may be important in Wegener's granulomatosis, proof of their role in vivo is not yet available.

#### REFERENCES

1. Hagen EC, Ballieux BEPB, van Es LA, Daha MR, van der Woude FJ. Anti-neutrophil cytoplasmic antibodies: a review of the antigens involved, the assays, and the clinical and possible pathogenic consequences. *Blood* 1993; 81:1996-2002.
2. Faber V, Elling P, Norup G, Mansa B, Nissen NI. An antinuclear factor specific for leukocytes. *Lancet* 1964; 2:344-345.
3. Wiik A, Jensen E, Friis J. Granulocyte-specific antinuclear factors in synovial fluids and sera from patients with rheumatoid arthritis. *Ann Rheum Dis* 1974; 35:515-522.
4. Davies DJ, Moran JE, Niall JF, Ryan GB. Segmental necrotizing glomerulonephritis with antineutrophil antibodies: possible arbovirus aetiology? *Br Med J* 1982; 285:606.
5. van der Woude FJ, Lobatto S, Permin H, et al. Autoantibodies against neutrophils and monocytes: tool for diagnosis and marker




- for disease activity in Wegener's granulomatosis. *Lancet* 1985; 1:425-429.
6. Lüdemann J, Utecht B, Gross WL. Anti-neutrophil cytoplasmic antibodies in Wegener's granulomatosis recognize an elastinolytic enzyme. *J Exp Med* 1990; 171:357-362.
  7. Niles JL, McCluskey RT, Ahmad MF, Arnaout MA. Wegener's granulomatosis autoantigen is a novel serine proteinase. *Blood* 1989; 74:1888-1893.
  8. Goldschmeding R, van der Schoot CE, ten Bokkel Huinink D, et al. Wegener's granulomatosis antibodies identify a novel diisopropylphosphorophosphate-binding protein in the lysosomes of normal human neutrophils. *J Clin Invest* 1989; 84:1577-1587.
  9. Falk RJ, Jennette JC. Antineutrophil cytoplasmic antibodies with specificity for myeloperoxidase in patients with systemic vasculitis and idiopathic necrotizing and crescentic glomerulonephritis. *N Engl J Med* 1988; 318:1651-1657.
  10. Cohen Tervaert JW, Mulder L, Stegeman C, et al. Occurrence of autoantibodies to human leukocyte elastase in Wegener's granulomatosis and other inflammatory disorders. *Ann Rheum Dis* 1993; 52:115-120.
  11. Moodie FDL, Leacker B, Cambridge G, Totty NF, Segal AW. Alpha-enolase: a novel cytosolic autoantigen in ANCA positive vasculitis. *Kidney Int* 1993; 43:675-681.
  12. Niles JL. Value of tests for antineutrophil cytoplasmic antibodies in the diagnosis and treatment of vasculitis. *Curr Opin Rheumatol* 1993; 5:18-24.
  13. Nölle B, Specks U, Lüdemann J, Rohrbach MS, De Remee RA, Gross WL. Anticytoplasmic antibodies: their immunodiagnostic value in Wegener's granulomatosis. *Ann Intern Med* 1989; 111:28-40.
  14. Cohen Tervaert JW, Goldschmeding R, Elema JD, et al. Autoantibodies against myeloid lysosomal enzymes in crescentic glomerulonephritis. *Kidney Int* 1990; 37:799-806.
  15. Hauschild S, Schmitt WH, Csernok E, Flesch B, Rautmann A, Gross WL. ANCA in Wegener's granulomatosis and related vasculitis. In: Gross WL, editor. *Advances in experimental medicine and biology. Abstract book of the Fourth International Workshop on ANCA*. London: Plenum, 1992:8.
  16. Geffriaud C, Nel LH, Chauveau D, Houhou S, Lesavre P, Gruenfeld JP. Clinical association with ANCA of defined antigen specificity in 98 consecutive patients. In: Gross WL, editor. *Advances in experimental medicine and biology. Abstract book of the Fourth International Workshop on ANCA*. London: Plenum, 1992:26.
  17. Ulmer M, Rautmann A, Gross WL. Immunodiagnostic aspects of autoantibodies against myeloperoxidase. *Clin Nephrol* 1992; 37:161-168.
  18. Davenport A. "False positive" perinuclear and cytoplasmic anti-neutrophil cytoplasmic antibody results leading to misdiagnosis of Wegener's granulomatosis and/or microscopic polyarteritis. *Clin Nephrol* 1992; 37:124-130.
  19. Kerr GS, Fleisher TA, Hallahan CW, Leavitt RY, Fauci AS, Hoffman GS. Limited prognostic value of anti-neutrophil cytoplasmic antibody in patients with Wegener's granulomatosis. *Arthritis Rheum* 1993; 36:365-371.
  20. Gaskin G, Turner AN, Ryan JJ, Rees AJ, Pusey CD. Significance of autoantibodies to purified proteinase 3 in systemic vasculitis. In: Gross WL, editor. *Advances in experimental medicine and biology. Abstract book of the Fourth International Workshop on ANCA*. London: Plenum, 1992:44.
  21. Savage COS, Tizard J, Jayne D, Lockwood CM, Dillon MJ. Antineutrophil cytoplasmic antibodies in Kawasaki's disease. *Arch Dis Child* 1989; 64:360-363.
  22. O'Donoghue DJ, Nusbaum P, Halbwachs-Mecarelli L, Lesavre P, Noel LM, Guillevain L. Anti-neutrophil cytoplasmic antibodies associated with polyarteritis nodosa, Guburg-Strauss syndrome and HIV related systemic vasculitis. *Am J Kidney Dis* 1991; 18:208.
  23. Juby A, Johnston C, Davis P, Russel AS. Antinuclear and antineutrophil cytoplasmic antibodies (ANCA) in the sera of patients with Felt's syndrome. *Br J Rheumatol* 1992; 31:185-188.
  24. Savage JA, Gallicchio MC, Stockman A, Cunningham TJ, Rowley MJ. Anti-neutrophil cytoplasmic antibodies in rheumatoid arthritis. *Clin Exp Immunol* 1991; 86:92-98.
  25. Mulder AL, Horst G, van Leeuwen MA, Limburg PC, Kallenberg CG. Antineutrophil cytoplasmic antibodies in rheumatoid arthritis. Characterization and clinical correlations. *Arthritis Rheum* 1993; 36:1054-1060.
  26. Bosch X, Mirapeix E, Font J, et al. Prognostic implication of anti-neutrophil cytoplasmic autoantibodies with myeloperoxidase specificity in anti-glomerular basement membrane disease. *Clin Nephrol* 1991; 36:107-113.
  27. Nielsen H, Wiik A, Elmgreen J. Granulocyte specific antinuclear antibodies in ulcerative colitis. *Acta Pathol Microbiol Immunol Scand [C]* 1983; 91:23-26.
  28. Halbwachs-Mecarelli L, Nusbaum P, Noël LH. Antineutrophil cytoplasmic antibodies (ANCA) directed against cathepsin G in ulcerative colitis, Crohn's disease and primary sclerosing cholangitis. *Clin Exp Immunol* 1992; 90:79-84.
  29. Mulder AHL, Horst G, Broekroelofs G, Nelis GF, Kallenberg CGM. ANCA in inflammatory bowel disease recognize several antigens. In: Gross WL, editor. *Advances in experimental medicine and biology. Abstract book of the Fourth International Workshop on ANCA*. London: Plenum, 1992:8.
  30. Kemmett D, Harrison DJ, Hunter JAA. Antibodies to neutrophil cytoplasmic antigens: a serologic marker for Sweet's syndrome. *J Am Acad Dermatol* 1991; 24:967-969.
  31. Klaassen RJL, Goldschmeding R, Dolman KM, et al. Antineutrophil cytoplasmic antibodies in patients with symptomatic HIV infection. *Clin Exp Immunol* 1992; 87:24-30.
  32. Savage J, Chang L, Crowe S. Anti-neutrophil cytoplasmic antibodies in HIV infections. In: Gross WL, editor. *Advances in experimental medicine and biology. Abstract book of the Fourth International Workshop on ANCA*. London: Plenum, 1992:42.
  33. Stemme S, Fager G, Hansson GK. MHC class II antigen expression in human vascular smooth muscle cells is induced by interferon-gamma and modulated by tumor necrosis factor and lymphotoxin. *Immunology* 1990; 69:243-249.
  34. Jennette JC, Ewert BH, Falk RJ. Do antineutrophil cytoplasmic autoantibodies cause Wegener's granulomatosis and other forms of necrotizing vasculitis? *Rheum Dis Clin North Am* 1993; 19:1-14.
  35. Charles LA, Caldas MRR, Falk RJ, Terrell RS, Jennette JC. Antibodies against granule proteins activate neutrophils in vitro. *J Leukoc Biol* 1991; 50:539-546.
  36. Noronha IL, Krüger K, Andrassy K, Ritz E, Waldherr R. In situ production of TNF- $\alpha$ , IL-1 $\beta$  and IL-2R in ANCA-positive glomerulonephritis. *Kidney Int* 1993; 43:682-692.
  37. Ewert BH, Jennette JC, Falk RJ. The pathogenic role of anti-neutrophil cytoplasmic antibodies. *Am J Kidney Dis* 1991; 18:188-195.
  38. Falk RJ, Terrell RS, Charles LA, Jennette C. Anti-neutrophil cytoplasmic antibodies induce neutrophils to degranulate and produce oxygen radicals in vitro. *Proc Natl Acad Sci USA* 1990; 87:4115-4119.
  39. Ewert BH, Jennette JC, Falk RJ. Anti-myeloperoxidase antibodies stimulate neutrophils to damage human endothelial cells. *Kidney Int* 1992; 41:375-383.
  40. Hauschild S, Schmitt WH, Kekow J, Szymkowiak C, Gross WL. Elevated serum levels of ICAM-1 in Wegener's granulomatosis. *Immun Infekt* 1992; 20:84-85.
  41. Mayet WJ, Csernok E, Szymkowiak KC, Gross WL, Meyer zum Buschenfelde KM. Human endothelial cells express proteinase 3, the target antigen of anticytoplasmic antibodies in Wegener's granulomatosis. *Blood* 1993; 82:1221-1229.
  42. Sturrock AB, Franklin KF, Rao G, et al. Structure, chromosomal assignment, and expression of the gene for proteinase-3. *J Biol Chem* 1992; 267:21193-21199.
  43. Kao RC, Wehner NG, Skubitz KM, Gray BH, Hoidal JR.



Proteinase 3. A distinct human polymorphonuclear leukocyte proteinase that produces emphysema in hamsters. *J Clin Invest* 1988; **82**:1963-1973.

44. Labbaye C, Musette P, Cayre YE. Wegener autoantigen and myeloblastin are encoded by a single mRNA. *Proc Natl Acad Sci USA* 1991; **88**:9253.
45. Bories D, Raynal MC, Solomon DH, Darzynkiewicz Z, Cayre YE. Down-regulation of a serine proteinase, myeloblastin, causes growth arrest and differentiation of promyelocytic leukemia cells. *Cell* 1989; **59**:959-968.
46. Deguchi Y, Shibata N, Kishimoto S. Enhanced expression of the tumor necrosis factor/cachectin gene in peripheral blood mononuclear cells from patients with systemic vasculitis. *Clin Exp Immunol* 1990; **81**:311-314.
47. Schmitt WH, Heesen C, Csernok E, Rautmann A, Gross WL. Elevated serum levels of soluble interleukin-2 receptor in patients with Wegener's granulomatosis. *Arthritis Rheum* 1992; **35**:1088-1096.
48. Petersen J, Rasmussen N, Szpirt W, Hermann E, Mayet W. T-lymphocyte proliferation to neutrophil cytoplasmic antigens in Wegener's granulomatosis. *Am J Kidney Dis* 1991; **18**:205.
49. Esnault VLM, Testa A, Audrain M, et al. Alpha 1-antitrypsin genetic polymorphism in ANCA-positive systemic vasculitis. *Kidney Int* 1993; **43**:1329-1332.
50. Falk RJ, Hogan S, Carey TS, Jennette JC. The clinical course of patients with antineutrophil cytoplasmic autoantibody associated glomerulonephritis and systemic vasculitis. *Ann Intern Med* 1990; **113**:656-663.
51. Hoffman GS, Kerr GS, Leavitt RY, et al. Wegener's granulomatosis: an analysis of 158 patients. *Ann Intern Med* 1992; **116**:488-498.
52. Hoffman GS, Sechler JMG, Gallin JI, et al. Bronchoalveolar lavage analysis in Wegener's granulomatosis. *Am Rev Respir Dis* 1991; **143**:401-407.
53. Klinger H. Grenzformen der periarteritis nodosa. *Frankf Z Pathol* 1931; **42**:455-480.
54. Wegener F. Über generalisierte, septische efüberkrankungen. *Verh Dtsch Ges Pathol* 1936; **29**:202-210.
55. Hoffman GH. Wegener's granulomatosis. *Curr Opin Rheumatol* 1993; **5**:11-17.
56. Osorio AM, Thun MJ, Novak RF, Van Cura EJ, Avner ED. Silica and glomerulonephritis: case report and review of the literature. *Am J Kidney Dis* 1987; **3**:224-230.
57. Bolton WK, Suratt PM, Sturgill BC. Rapidly progressive silico-n nephropathy. *Am J Med* 1981; **71**:823-828.
58. Policard A, Collet A, Daniel-Moussard H, Pregermain S. Sur les premiers stades des altérations expérimentales du rein par l'acide silicique. Étude au microscope électronique. *J Urol Med Chir* 1960; **66**:585-600.



# CLEVELAND CLINIC JOURNAL OF MEDICINE



## INTERNAL MEDICINE BOARD REVIEW

**IM BOARD REVIEW**  
*presents clinical vignettes  
along with questions on  
the differential diagnosis  
and treatment of medical  
conditions likely to be  
encountered on the  
Qualifying Examination  
in Medicine –  
as well as in practice.  
Take the challenge.*

**IN THIS ISSUE**  
*Page 409*