

WILLIAM S. WILKE, MD, EDITOR

FINE-NEEDLE ASPIRATION BIOPSY TO EVALUATE THYROID NODULES

Fine-needle aspiration biopsy provides a rapid, highly accurate, and inexpensive means of determining if a thyroid nodule is malignant. This method has decreased the number of surgeries for benign thyroid nodules by approximately two thirds and has doubled the diagnostic yield in identifying thyroid cancer.

Thyroid nodules are common, but thyroid cancer is relatively rare. As many as 20 million people in the United States alone may have palpable thyroid nodules, and autopsy studies indicate that half the population may have nodules too small to palpate. Fortunately, only about 5% of palpable thyroid nodules are cancerous. Physicians face the challenge of identifying patients at risk for thyroid cancer and evaluating thyroid nodules with a cost-effective, sensitive approach that avoids unnecessary surgery without missing a potentially fatal cancer.

BENIGN OR MALIGNANT?

Women develop thyroid nodules four times more often than men, but a nodule in a man carries a greater risk of cancer. Nodules increase in frequency with age, but a nodule in a person younger than 30 or older than 60 raises the suspicion of cancer, as does a family history of thyroid

cancer (especially medullary carcinoma) or a history of exposure to radiation. Nodules larger than 4 cm or those with associated adenopathy, fixation, or dysphonia also raise the suspicion of cancer.

Laboratory tests can help determine the patient's level of thyroid function but are not sensitive in

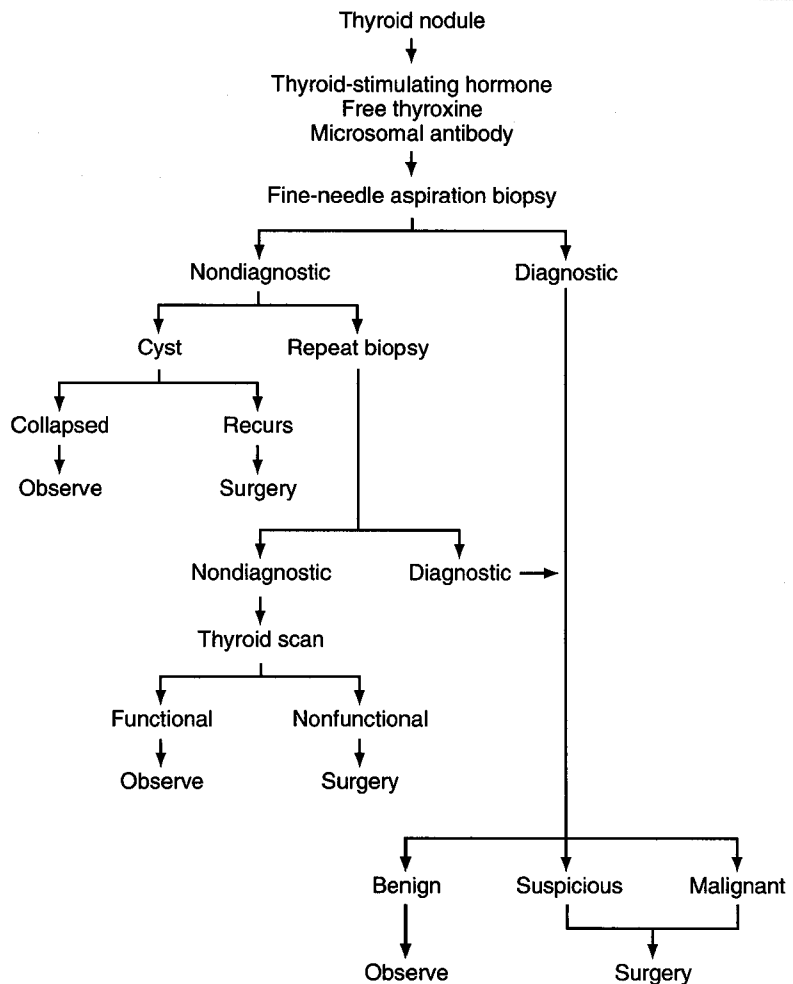


FIGURE. Diagnostic evaluation of thyroid nodules.

distinguishing malignant from benign lesions. Likewise, imaging studies by themselves are of limited use. Radionuclide scanning with iodine or technetium cannot reliably distinguish benign from malignant nodules: only 20% of "cold" nodules are malignant, "warm" nodules are not usually malignant (but 9% can be), and even "hot" nodules can be malignant in 1% of patients. Ultrasonography is 90% sensitive for distinguishing solid from cystic or mixed nodules. However, 15% of cystic nodules may harbor cancers.

Fine-needle aspiration biopsy has become the diagnostic test of choice. The test is safe and has a false-negative and false-positive rate of 2%. The accuracy depends on the aspiration technique and on the experience of the cytopathologist. Over 70% of nodules evaluated by fine-needle aspiration biopsy are benign, including colloid nodules, cysts, and thyroiditis. Suspicious and malignant lesions account for 5% to 15% of studies, and 2% to 21% are nondiagnostic. The *Figure* shows a diagnostic algorithm for evaluating thyroid nodules.

THYROID CANCER: AGGRESSIVE FORMS

Thyroid cancer accounts for approximately 1% of all cancers, and only 9% of patients with thyroid cancer die from it. Yet some forms are very aggressive and require early recognition and early aggressive intervention for prolonged survival.

Papillary adenocarcinoma accounts for 70% of all thyroid cancers in adults and 90% in children. The peak incidence occurs in the third and fourth decades, and it is the most common thyroid cancer associated with previous ionizing radiation exposure. Most patients have an excellent chance for long-term survival; risk factors for more aggressive disease include age younger than 20 or older than 50, male sex, tumor size larger than 4 cm, unfavorable histology, distant metastasis, and the absence of coexisting Hashimoto's thyroiditis. Treatment includes surgical resection with or without radioactive iodine ablation and thyroid hormone suppression.

Follicular cancer accounts for 15% of thyroid cancers and generally carries a worse prognosis than papillary adenocarcinoma. Distant metastasis is not uncommon because it spreads hematogenously. Risk factors for poor outcome include age older than 40, tumor size larger than 4 cm, invasion through the capsule or vascular invasion, and local or distant spread. Treatment includes subtotal or total thy-

roidectomy, radioiodine ablation, and thyroid hormone suppression. Occasionally, focused-beam irradiation is used as a palliative treatment, especially for bony metastasis. The undifferentiated thyroid cancers include Hurthle cell carcinoma, medullary carcinoma, lymphoma, metastatic carcinoma (from the breast, kidney, or lung), and anaplastic carcinoma. These aggressive forms of thyroid carcinoma carry a poor prognosis unless detected early and treated aggressively. These tumors almost never respond to radioiodine ablation, and treatment usually includes surgery, focused-beam irradiation, and possibly chemotherapy. Fortunately, they account for only approximately 15% of all thyroid cancers.

RICHARD BEHAM, MD
Department of Endocrinology
The Cleveland Clinic Foundation

SUGGESTED READING

Gharib H, Goellner J. Fine-needle aspiration biopsy of the thyroid: an appraisal. *Ann Intern Med* 1993; 118:282-289.

Robbins J, Merino MJ, Boice JD Jr, et al. Thyroid cancer: a lethal endocrine neoplasm. *Ann Intern Med* 1991; 115:133-147.

de los Santos ET, Keyhani-Rofagha S, Cunningham JJ, Mazzaferri EL. Cystic thyroid nodules. *Arch Intern Med* 1990; 150:1422-1427.

Sessions R. Thyroid cancer. *Med Clin North Am* 1993; 77:517-538.

CHRONIC DIZZINESS: VESTIBULAR EVALUATION AND REHABILITATION

Dizziness, one of the top four symptoms for which patients seek medical attention, is one of the most complex and frustrating symptoms to evaluate. A systematic approach can speed the evaluation, improve management, and decrease the frustration of the physician and patient. The key is to establish through careful questioning precisely what the patient means by "dizziness." The physician's task is to distinguish true vertigo (an erroneous sensation of movement) from other sensations such as faintness, and, if vertigo is present, to determine if it is caused by a vestibular (peripheral) or a central disorder.

THE BALANCE MECHANISM

Three systems contribute to balance: the vestibular, visual, and proprioceptive systems. Because the vestibular system is the least redundant, when it is compromised, the symptoms are more pronounced than if the visual or proprioceptive systems are af-