



Echocardiographically guided removal of an intracardiac foreign body

VICENTE E. FONT, MD; CARL C. GILL, MD; DAVID E. LAMMERMEIER, MD

- **BACKGROUND** Foreign bodies lodged in the heart can easily be missed during surgical repair of penetrating cardiac wounds.
- **SUMMARY** We report the use of intraoperative echocardiography to identify and accurately locate a small cardiac foreign body. Our patient had a fragment of a drill bit lodged in his left atrium as the result of an industrial accident. He initially underwent emergency median sternotomy because of acute tamponade, but the foreign body was not found, and he subsequently required a second procedure to remove it. Intraoperative transesophageal and epicardial echocardiography during the second procedure confirmed the position of the metallic fragment, excluded the possibility of other lodged foreign particles, and ruled out other types of penetrating injury to the heart.
- **CONCLUSIONS** Intraoperative echocardiography should be standard procedure in the removal of intracardiac foreign bodies.

■ **INDEX TERMS:** HEART INJURIES; FOREIGN BODIES; ECHOCARDIOGRAPHY; INTRAOPERATIVE PERIOD ■ CLEVE CLIN J MED 1994; 61:228-231

From the Departments of Cardiology (V.E.F.) and Cardiothoracic Surgery (C.C.G., D.E.L.), Cleveland Clinic Florida, Fort Lauderdale.

Address reprint requests to V.E.F., Cleveland Clinic Florida, Department of Cardiology, 3000 W. Cypress Creek Road, Fort Lauderdale, FL 33309.

PENETRATING CARDIAC injuries can leave foreign bodies within the heart, most commonly bullets, but also knives, needles, ice picks, and displaced bone fragments. Venous embolization of bullets and gunshot pellets has also been reported. In addition, intracardiac foreign bodies can result from iatrogenic causes such as embolization of fragments of intravenous or intracardiac catheters and needles, migration of Greenfield filters, and malpositioned transvenous pacemaker leads. When a penetrating missile wound occurs, the degree of injury usually depends on the size and shape of the foreign body, its location within the heart, the depth of penetration, and the damage to contiguous structures.

Due to its anterior position, the right ventricle is the chamber most frequently involved, followed by the left ventricle, the right atrium, and the left atrium.¹ Although a low-velocity projectile may stop within the pericardium or even the myocardium, life-threatening hemorrhage with clinical evidence of tamponade and shock is the rule. Unfortunately, emergency surgery frequently does not allow time to

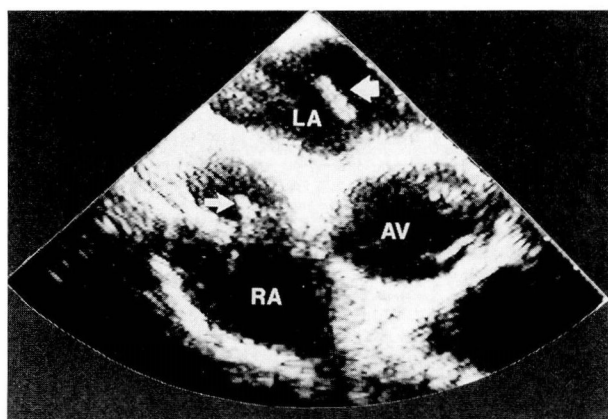


FIGURE 1. Two-dimensional transesophageal echocardiogram in a short-axis view (partially oblique) at the level of the aortic valve shows a metallic foreign body in the left atrium (large arrow). The small arrow points to a central venous catheter. AV, aortic valve; LA, left atrium; RA, right atrium.

precisely locate the foreign body preoperatively with noninvasive imaging modalities.

We describe our recent experience with a young man who sustained a penetrating cardiac injury. The purpose of this report is to stress the utility of intraoperative echocardiography as a standard part of the evaluation and management of this life-threatening problem.

CASE HISTORY

A healthy 32-year-old male machinist was heating a metal rod from which a drilling bit was to be made. The rod was anchored on a utility table and was pointing up. As the patient leaned over the table the intense heat caused the rod to crack and break, propelling a distal fragment into the patient's chest. The patient was able to walk to his supervisor's office and call the rescue squad. By the time the paramedics arrived the patient had lost consciousness. They immediately started an intravenous infusion and applied medical antishock trousers. The moribund patient was then transported to the nearest hospital.

An initial roentgenogram of the chest showed massive enlargement of the cardiac silhouette. The patient was taken to the operating room, where he was found to have cardiac tamponade and a small laceration in the right ventricular free wall. He responded well to evacuation of the pericardial blood




FIGURE 2. The extracted foreign body.

and closure of the ventricular laceration. There was no exit wound from the heart, but no foreign body was found during surgery.

A computed tomographic scan obtained after extubation failed to reveal the projectile; however, a fluoroscopic study identified the metal object within the heart. A surface (transthoracic) echocardiographic study failed to confirm this finding due to limited windows and poor-quality images. The patient then underwent transesophageal echocardiography, which clearly detected a linear metallic object lodged in the left atrium and partially covered by thrombotic material (*Figure 1*). The patient was then transferred to Cleveland Clinic Florida for removal of the left atrial foreign body.

After the patient had been intubated in the operating room, a 5.0-MHz single-plane transesophageal probe was introduced into his esophagus, and a complete echocardiographic study was performed before a median sternotomy was begun. This study confirmed that a metallic object was lodged in the left atrium and demonstrated no other smaller fragments in the heart. In addition, it showed no traumatic atrial or ventricular septal defects or perforated valve leaflets. The foreign body could not be palpated from outside the heart.

The patient was connected to a cardiopulmonary bypass machine. Before cardiotomy, a 3.5-MHz phased-array ultrasonic transducer covered by a sterile double plastic sheath was positioned over the surface of the heart, and epicardial imaging was performed to monitor the location of the foreign body. The object was then successfully retrieved through a left atriotomy, the cardiopulmonary bypass was discontinued, and the incision was closed (*Figure 2*).

TABLE
REPORTED CASES USING INTRAOPERATIVE ECHOCARDIOGRAPHY
IN PATIENTS WITH INTRACARDIAC FOREIGN BODIES

Author	Number of patients	Technique	Foreign body	Location
Harrison, 1981 ²⁰	1	Epicardial	Bullet	Left ventricle
Hassett, 1986 ²¹	3	Epicardial	Bullet	Left ventricle, epicardium
Mazzei, 1989 ²²	1	Transesophageal	Bullet	Right ventricle
Shaikh, 1989 ²³	1	Epicardial	Shotgun pellet	Left ventricle
Reeves, 1989 ⁶	12*	Epicardial, transesophageal	Bullet	Left ventricle, right ventricle, pericardium
Takana, 1991 ²⁴	1	Epicardial	Dislodged Björk-Shiley mitral valve replacement	Left ventricle
Font, 1994 (present case)	1	Epicardial, transesophageal	Drill bit	Left atrium

*4 humans, 8 experimental dogs

The patient had an uneventful recovery and was discharged on the sixth postoperative day; his discharge regimen included oral antibiotics.

DISCUSSION

Attempts in the early 1930s to surgically repair penetrating cardiac injuries were controversial because the mortality rate was as high as 20%, which was similar to the mortality rate of patients who did not undergo surgery.² Ten years later, Harken³ reported that no patients died during the surgical removal of 56 intracardiac foreign bodies, and surgery became the treatment of choice.

Parmley⁴ and Symbas⁵ reported that as many as 30% of foreign bodies were missed at surgery. Reeves et al⁶ demonstrated that two-dimensional echocardiography can miss even large metallic fragments when they are close to the pericardium because the pericardial membrane is highly reflective. These objects can also be missed if they are located near other brightly echogenic structures such as calcified valves. Furthermore, retained missile fragments may be difficult to find if lodged within posterior structures of the heart.

Echocardiography's rapid evolution in the last three decades has made it the leading imaging tool for diagnosing many cardiac conditions. Echocardiography can provide an immediate diagnosis and improve the understanding of the underlying pathophysiology. It is accessible, practical for long-term follow-up, cost-effective, and safe.

Transesophageal echocardiography was intro-

duced in the early 1970s and has revolutionized the practice of cardiology because of the additional information it provides.^{7,8} Since then, its development has continued with the addition of color-flow mapping, pulsed- and continuous-wave Doppler, and more imaging planes. Transesophageal echocardiography has proven superior to transthoracic echocardiography in evaluating valvular disease (especially prosthetic mitral valve dysfunction), diagnosing endocarditis and other intracardiac masses (including foreign objects), repairing thoracic aortic dissections and certain congenital heart defects, and in the critical care setting.⁹⁻¹⁵

Intraoperative echocardiography was initially used for monitoring cardiac function.^{16,17} As the number of complex surgical repairs increased, surgeons soon demanded immediate and accurate information and feedback regarding the adequacy and success of many cardiac procedures.^{18,19}

The use of intraoperative echocardiography during the removal of intracardiac foreign bodies has been previously reported (*Table*). Our report stresses the utility of echocardiography in providing intraoperative "on-line" information for directing the removal of an intracardiac foreign object. Ours is the first report of the combined use of intraoperative transesophageal and epicardial echocardiography to confirm the precise location of a left atrial foreign body.

Although an extremely useful tool, echocardiography may have some limitations. Retained fragments or foreign bodies can still be missed because of reverberation artifact and ultrasonic shadowing

caused by nearby highly reflective structures such as the pericardium, dense calcifications, and intracardiac prosthetic material.

CONCLUSION

Perioperative echocardiographic evaluation is extremely useful in patients with intracardiac foreign bodies. Planning the surgery for a penetrating cardiac injury can clearly be improved with intraopera-

tive echocardiography to define the presence and location of a cardiac foreign body and to assess the extent of the damage or secondary complications. This technology will help the cardiac surgeon plan the surgical approach and determine the need for additional corrective intervention. Intraoperative echocardiography, if done routinely in all patients with penetrating cardiac injuries, will help reduce cardiopulmonary bypass time and may obviate a second operation to extract a foreign body.

REFERENCES

1. Fallahnejad M, Kutty ACK, Wallace HW. Secondary lesions of penetrating cardiac injuries. *Ann Surg* 1980; **191**:228-233.
2. Decker HR. Foreign bodies in the heart and pericardium—should they be removed? *J Thorac Surg* 1939; **9**:62-79.
3. Harken DE. Foreign bodies in, and in relation to, the thoracic blood vessels and heart. *Surg Gynecol Obstet* 1946; **83**:117-125.
4. Parmley LF, Mattingly TW, Manion WC. Penetrating wounds of the heart and the aorta. *Circulation* 1958; **17**:953-973.
5. Symbas PN, DiOrio DA, Tyras DH, et al. Penetrating cardiac wounds. Significant residual and delayed sequelae. *J Thorac Cardiovasc Surg* 1973; **66**:526-532.
6. Reeves WC, Movahed A, Chitwood R, et al. Utility of precordial, epicardial and transesophageal two-dimensional echocardiography in the detection of intracardiac foreign bodies. *Am J Cardiol* 1989; **64**:406-409.
7. Frazin L, Talano JV, Stephanides L, et al. Esophageal echocardiography. *Circulation* 1976; **54**:102-108.
8. Hisanaga K, Hisanaga A, Nagata K, et al. A new transesophageal real-time two-dimensional echocardiographic system using a flexible tube and its application. *Proc Jpn Soc Ultrason Med* 1977; **32**:43-44.
9. Pavlides GS, Hauser AM, Stewart JR, et al. Contribution of transesophageal echocardiography to patient diagnosis and treatment: a prospective analysis. *Am Heart J* 1990; **120**:910-914.
10. Erbel R, Rohmann S, Drexler M, et al. Improved diagnostic value of echocardiography in patients with infective endocarditis by transesophageal approach: a prospective study. *Eur Heart J* 1988; **9**:43-53.
11. Obeid AI, Marvasti M, Parker F, et al. Comparison of transthoracic and transesophageal echocardiography in diagnosis of left atrial myxoma. *Am J Cardiol* 1989; **63**:1006-1008.
12. Mügge A, Werner DG, Haverich A, et al. Diagnosis of noninfective cardiac mass lesions by two-dimensional echocardiography. Comparison of the transthoracic and transesophageal approaches. *Circulation* 1991; **83**:70-78.
13. Erbel R, Engberding R, Daniel W, et al. European Cooperative Study Group for Echocardiography: echocardiography in diagnosis of aortic dissection. *Lancet* 1989; **1**:457-460.
14. Stümper OFW, Elzenga NJ, Hess J, et al. Transesophageal echocardiography in children with congenital heart disease: an initial experience. *J Am Coll Cardiol* 1990; **16**:433-441.
15. Font VE, Obarski TP, Klein AL, et al. Transesophageal echocardiography in the critical care unit. *Cleve Clin J Med* 1991; **58**:315-322.
16. Ren JE, Panidis IP, Kotler MN, et al. Effects of coronary bypass surgery and valve replacement on left ventricular function: assessment by intraoperative two-dimensional echocardiography. *Am Heart J* 1985; **109**:281.
17. Schiller NB, Cahalan MK, Lee E. Intraoperative monitoring of left ventricular function by transesophageal echocardiography. In: Maurer G, Mohl W, editors. *Echocardiography and Doppler in cardiac surgery*. New York: Igaku-Shoin Medical Publishers, 1989:203-209.
18. Maurer G, Czer LSC, Chaux A, et al. Intraoperative color flow Doppler in evaluating valvuloplasty and correction of congenital heart disease. *Learning Center Highlights*. Bethesda, MD: American College of Cardiology, 1989; **5**:1-7.
19. Stewart WJ, Currie PJ, Salcedo EE. Intraoperative Doppler color flow mapping for decision making in valve repair for mitral regurgitation. *Circulation* 1990; **81**:556.
20. Harrison LH, Kisslo JA, Sabiston DC. Extraction of intramyocardial foreign body utilizing operative ultrasonography. *J Thorac Cardiovasc Surg* 1981; **82**:345-349.
21. Hassett A, Moran J, Sabiston DC, et al. Utility of echocardiography in the management of patients with penetrating missile wounds of the heart. *J Am Coll Cardiol* 1986; **7**:1151-1156.
22. Mazzei WJ, Burzynski M. Transesophageal echocardiographic monitoring of an intraventricular foreign body. *J Cardiothorac Anesth* 1989; **3**:84-86.
23. Shaikh K, Cilley J, O'Connor W, et al. Intraoperative echocardiography: a useful tool in the localization of small intracardiac foreign bodies. *J Cardiovasc Surg* 1989; **30**:42-43.
24. Takana M, Abe T, Takeuchi E, et al. Intraoperative echocardiography of a dislodged Björk-Shiley mitral valve disc. *Ann Thorac Surg* 1991; **51**:315-316.