



DAVID L. LONGWORTH, MD AND JAMES K. STOLLER, MD, EDITORS

Dyspnea on exertion with cardiomegaly

THE PATIENT IS A 48-YEAR-OLD WHITE MAN WHO presents with a chief complaint of epigastric “pressure” radiating up to the chest. He also complains of increasing shortness of breath with exertion. The symptoms began about 2 to 3 weeks ago. Bending over to pick something up or tie his shoes increased the discomfort and caused facial flushing. He went to his family physician and was found to have cardiomegaly on chest roentgenography. He was referred to a cardiologist for further evaluation.

His past medical history includes hay fever, eczema, and diverticulitis. He has had no viral syndrome and denies any history of tuberculosis, cough, or fever. His family history includes liver failure and diabetes in his father and breast cancer in his mother. He has smoked three packs per day for more than 31 years and he consumes six beers a week. The only medication he takes is terfenadine (Seldane), and he has an allergy to penicillin, which gives him a generalized rash.

Q1 Given the above information, the *best* test to order at this time would be:

- ☐ Exercise treadmill test
- ☐ Cardiac catheterization
- ☐ Echocardiography with Doppler
- ☐ Nuclear multigated angiography

A1 In a 48-year-old male without a significant cardiac history, it would be very unusual to see cardiomegaly on chest roentgenography. Echocardiography can give you a great deal of information regarding chamber enlargement, valvular defects, intracardiac shunts, and overall cardiac function. While the other tests may be useful at a

later date, the best test is echocardiography.

On physical examination, the patient is alert and oriented and is in no significant distress. Blood pressure is 130/80 mm Hg with a pulsus paradoxus of 22 mm Hg. The respiratory rate is 22 per minute, and the heart rate is 110 beats per minute. He is afebrile. Pertinent findings include jugular venous distension at 30 degrees. His heart tones are distant with a normal S₁ and S₂; no S₃ or S₄ is auscultated, and the point of maximal impulse is nonpalpable. His lungs have decreased breath sounds in the bases, and the abdomen is benign.

His electrocardiogram is shown in *Figure 1*. The chest roentgenogram is shown in *Figure 2*. *Figure 3* shows his roentgenogram from several years earlier. His laboratory values are unremarkable.

Q2 Given the physical exam, chest roentgenogram, and electrocardiogram, what is your preliminary diagnosis?

- ☐ Severe left ventricular failure
- ☐ Coronary artery disease, rule out myocardial infarction
- ☐ Exacerbation of chronic obstructive pulmonary disease
- ☐ Cardiac tamponade
- ☐ Pulmonary embolism

A2 Given the physical findings of pulsus paradoxus of 22 mm Hg, tachycardia and distant heart tones, the diagnosis of tamponade is suggested. His electrocardiogram shows subtle signs of electrical alternans, especially in lead V₁, which is consistent with a large pericardial effusion. His chest

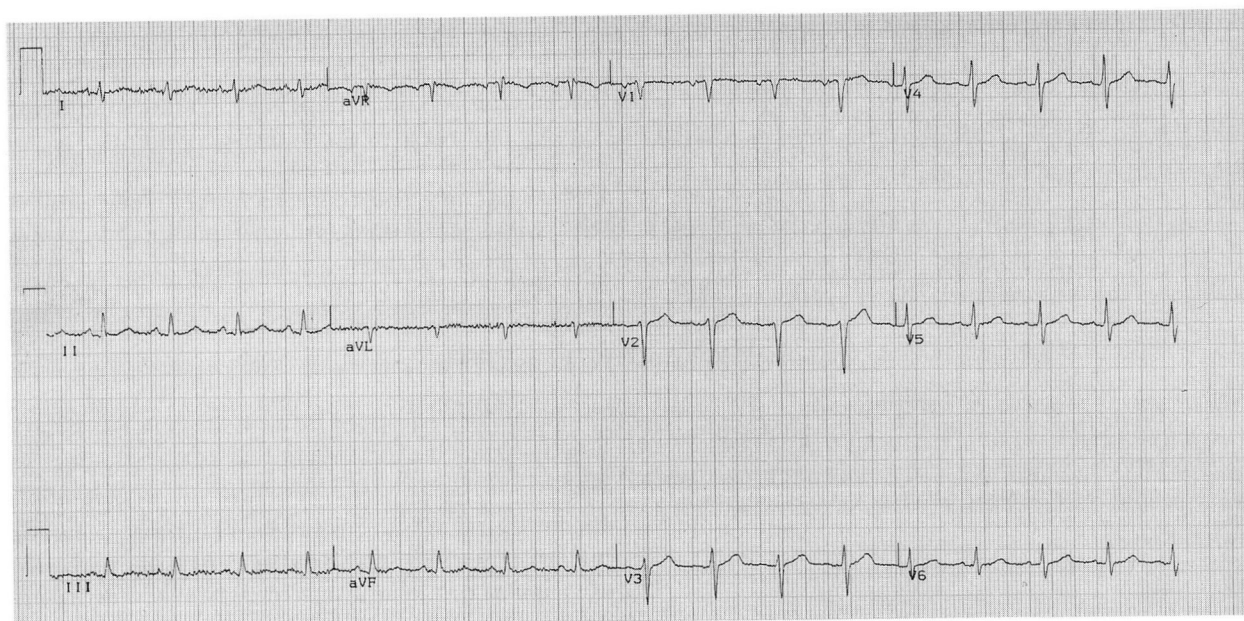


FIGURE 1

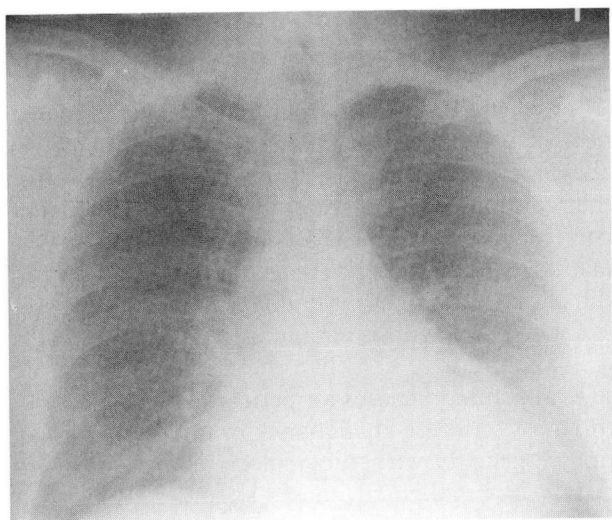


FIGURE 2

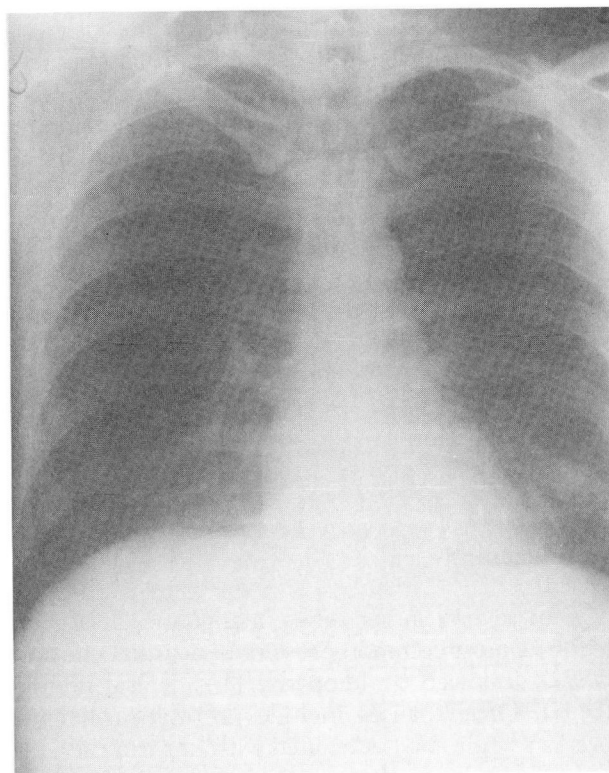


FIGURE 3

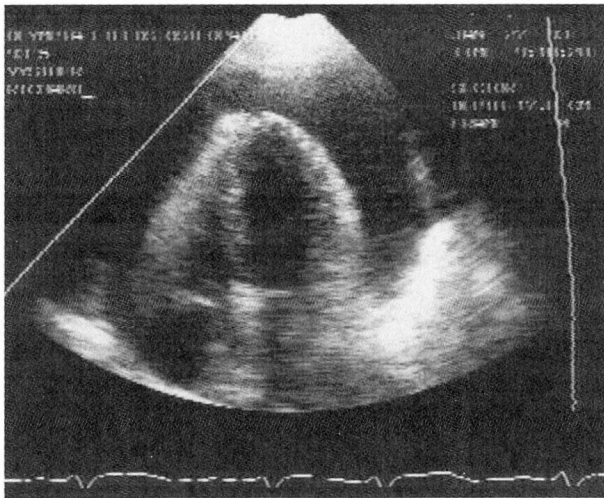


FIGURE 4

roentgenogram clearly shows cardiomegaly and suggests a “waterbottle heart” consistent with pericardial effusion.

The patient underwent echocardiography and was found to have a large pericardial effusion with evidence of right atrial collapse and normal chamber sizes, as well as normal left ventricular function (Figure 4). Because of the patient’s impending hemodynamic compromise, he was taken directly to the catheterization laboratory where he underwent pericardial drainage as well as right heart catheterization for hemodynamic data.

Q3 What is the most likely cause of this patient’s effusion?

- ☐ Idiopathy
- ☐ Viral infection
- ☐ Collagen vascular disease
- ☐ Malignancy
- ☐ Tuberculosis

A3 In several larger series, malignancy has been the most common cause of pericardial effusion (58%), followed by idiopathy (14%), and uremia (14%). Other causes include postmyocardial infarction syndrome (associated with heparin use), diagnostic cardiac catheterization, tuberculosis, radiation, myxedema, dissecting aortic aneurysm, and collagen vascular diseases, in particular, lupus and rheumatoid arthritis. Many centers are now report-

ing that acquired immunodeficiency syndrome (AIDS) is one of the more common causes of pericardial effusions, and there is a high rate of underlying tuberculosis infections in these patients.

Q4 What are the most common malignancies known to spread to the pericardium?

- ☐ Gastrointestinal tumors
- ☐ Head and neck tumors
- ☐ Lung cancer
- ☐ Osteosarcomas

A4 Most commonly, lung and breast cancers account for more than 50% of the malignancies causing pericardial effusions. The most common malignancies that spread to the pericardium in order are cancers of the lung and breast, leukemia or lymphomas, sarcomas, and melanomas.

Discussion

This patient presented with symptoms of shortness of breath and a markedly enlarged heart on chest roentgenography. It is important to remember that cardiomegaly does not always represent chamber enlargement, and that pericardial effusion remains in the differential diagnosis, especially when the patient has no other underlying cardiac disease.

Once the diagnosis of tamponade has been made, it is important to establish the etiology. There are several common causes for pericardial effusions, but the most serious is malignancy or underlying infection, especially with tuberculosis in patients with AIDS. Nonmalignant causes should be sought as well, including hypothyroidism, collagen vascular diseases, or an association with a viral syndrome of myopericarditis. It should also be kept in mind that even patients with underlying malignancy may present with tamponade, particularly if they have had prior mediastinal irradiation.

Patients with malignant pericardial effusions usually have either lung or breast cancer, lymphoma, leukemia, or melanoma. The therapeutic options depend on the underlying condition of the patient. Patients who manifest evidence of tamponade associated with effusion should undergo both diagnostic

and therapeutic pericardiocentesis, and the fluid should be sent for bacteriologic and cytologic examination.

The management of malignant pericardial effusions is limited. After pericardial drainage, a catheter should be left in place to prevent the reaccumulation of fluid. Most likely, the patient will need a pericardial "window" (surgical procedure to remove a segment of pericardium) or a sclerosing procedure. Beyond that, the treatment approach depends on the patient's life expectancy and whether or not the tumor is sensitive to chemotherapy or radiotherapy. The overall prognosis is dictated by the histologic diagnosis of the tumor; however, except for lymphomas or leukemias, involvement of the pericardium virtually always indicates incurability and a very limited prognosis, on the order of several months.

ANITA ARNOLD, DO
Milwaukee, Wis

SUGGESTED READING

Buzaid AC, Garewal HS, Greenberg BR. Managing malignant pericardial effusion. *West J Med* 1989; 150:174-179.

Guberman BA, Fowler NO, Engel PJ, Gueron M, Allen JM. Cardiac tamponade in medical patients. *Circulation* 1981; 64:633-640.

Huntsman WT, Brown ML, Albala DM. Cardiac tamponade as an unusual presentation of lung cancer: case report and review of the literature. *Clin Cardiol* 1991; 14(6):529-532.

Levine MJ, Lorell BH, Diver DJ, Come PC. Implications of echocardiographically assisted diagnosis of pericardial tamponade in contemporary medical patients: detection before hemodynamic embarrassment. *J Am Coll Cardiol* 1991; 17:59-65.

Reynolds MM, Hecht SR, Berger M, Kolokathis A, Horowitz SF. Large pericardial effusions in the acquired immunodeficiency syndrome. *Chest* 1992; 102:1746-1747.

THE CLEVELAND CLINIC FOUNDATION



25 YEARS OF MYOCARDIAL REVASCULARIZATION

CURRENT TECHNOLOGIES AND
CLINICAL CONTROVERSIES

ON VIDEO

FOR YOUR
CONTINUING EDUCATION

- Provocative debates
- State-of-the-art reviews
- Live demonstrations

PRICE INCLUDES:

- 8 videotapes
- Original symposium syllabus
- Book: *The Challenging Dream of Heart Surgery* by Rene G. Favaloro, MD
- Category I credit (14 hours)

VIDEO

Price:

U.S. \$425

INTERNATIONAL \$525

Specify: ☐ PAL ☐ SECAM ☐ OTHER

price includes shipping and handling

- Please charge the following account:
☐ VISA ☐ MASTERCARD Exp date: _____

Card number _____

Signature: _____

(Not valid without signature)

Total amount to be charged: \$ _____

To expedite credit card orders, fax this form to: (216)445-9406

- Check enclosed: \$ _____ All checks must be issued in US dollars drawn on a US bank

Please make checks payable to:

The Cleveland Clinic Educational Foundation

Please print

Name _____

Address _____

City _____ State _____ Zip _____

Country _____

Fax () _____ Home phone () _____

Business phone () _____

Mail order form to:

The Cleveland Clinic Educational Foundation
Department of Continuing Education TT-31
9500 Euclid Avenue
Cleveland, OH 44195
1-800-762-8173