



Bullectomies for bullous sarcoidosis

CESAR M. PENA, MD; DELOS M. COSGROVE, MD; PHILIP ENG, MD; THOMAS KIRBY, MD;
THOMAS RICE, MD; ATUL C. MEHTA, MD

■ A 36-year-old woman presented with respiratory insufficiency due to cystic sarcoidosis. She had been previously treated with multiple courses of prednisone without improvement. Enlarging blebs involving both lower lobes impaired the function of the relatively spared upper lobes. Bilateral lower lobectomies were performed in one step via median sternotomy without complications, with prompt subjective and objective improvement of her respiratory status. One-stage bilateral upper-lobe bullectomy for bullous emphysema has been previously reported, but to our knowledge this is the first performance of one-stage bilateral lower-lobe bullectomies for cystic sarcoidosis. The immediate benefits were evident; long-term results will depend on the course of the underlying disease.

□ INDEX TERMS: SARCOIDOSIS; RESPIRATORY INSUFFICIENCY; PNEUMONECTOMY □ CLEVE CLIN J MED 1993; 60:157-160

SARCOIDOSIS, A MULTISYSTEMIC granulomatous disease of uncertain etiology, typically presents with abnormalities on chest radiography.¹ In 90% of cases, hilar and paratracheal adenopathy, parenchymal disease, or both are present. Chest radiography is the basis for staging the disease in an attempt to establish its progression from a normal radiographic appearance to the fibrotic end stage.² The development of large bullae is a serious complication of sarcoidosis that invariably occurs in association with the fibrotic stage of the disease.³⁻⁵ At the time of initial diagnosis, about one of every seven patients exhibits the features of end-stage disease.² In such patients, the bullae can remain stable or increase in size, producing compression of the spared lung tis-

sue. At this advanced stage of the disease, steroids are of no benefit, and the patient eventually develops respiratory failure and cor pulmonale, leading to death.

Removal of giant bullae allows the compressed lung to re-expand and may lead to improved lung function. Such a modality has been applied previously, mainly in bullous disease associated with emphysema,⁶ and has been reported only rarely in sarcoidosis.^{7,8}

We report a case of sarcoidosis with severe respiratory insufficiency due to advanced bullous disease that successfully underwent one-stage bilateral lower-lobe bullectomies.

CASE HISTORY

A 36-year-old white female nonsmoker with insulin-dependent diabetes mellitus was being followed by a local physician for sarcoidosis; she had received prolonged courses of prednisone on several occasions. Eventually, prednisone therapy had been stopped because of multiple pathological bone fractures and poor control of diabetes. The patient was seen for the first

From the Department of Pulmonary Disease (C.M.P., P.E., A.C.M.) and the Department of Cardiothoracic Surgery (D.M.C., T.K., T.R.), The Cleveland Clinic Foundation.

Address reprint requests to A.C.M., Department of Pulmonary Disease, A90, The Cleveland Clinic Foundation, 9500 Euclid Avenue, Cleveland, OH 44195.

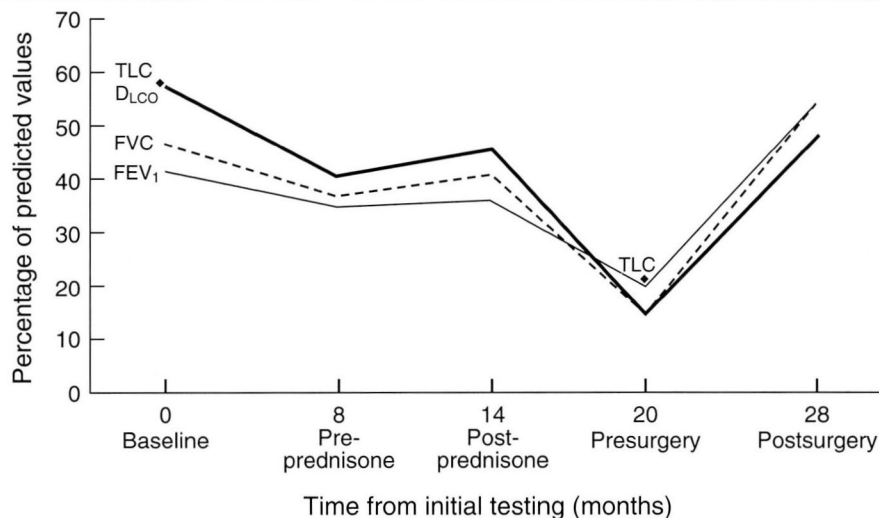


FIGURE 1. Pulmonary function in a patient with sarcoidosis. Tests for total lung capacity (TLC), diffusing capacity for carbon monoxide (D_{LCO}), forced vital capacity (FVC), and forced expiratory volume in 1 second (FEV_1) show dramatic improvement after bilateral bullectomy.

time in our division for preoperative clearance. She had developed a post-hysterectomy vesicovaginal fistula that required repair. She was asymptomatic, and her physical exam was unremarkable except for the presence of inspiratory crackles in both lung bases. Baseline pulmonary function tests revealed moderate restrictive ventilatory impairment (Figure 1). Angiotensin-converting enzyme was 166 U/L (normal 3 to 48 U/L). Chest radiography showed bilateral interstitial infiltrates, a giant bulla occupying the inferior half of the right lung, and multiple small bullae in the left lung base. The alpha-1 antitrypsin level was within normal limits. Because the patient was clinically stable, no treatment was prescribed.

Eight months later, the patient developed severe dyspnea on exertion. Her pulmonary function had worsened significantly (Figure 1), and her chest radiography revealed an increase in the size of the right-sided bulla and a new giant bulla in the left base. Prednisone therapy was restarted. Her pulmonary function improved significantly, and over the next 6 months the medication was tapered off (Figure 1). One month after prednisone was discontinued, her symptoms recurred. Despite a new 2-month course of prednisone, her pulmonary function continued to deteriorate (Figure 1).

She developed spontaneous right-sided pneumothorax twice, requiring chest tube drainage: the first

episode was treated in an outside hospital; the second episode, 4 months later, was treated in our institution. During that admission, because of her rapid deterioration and profound incapacitation, she underwent evaluation for bilateral bullectomies after the resolution of the pneumothorax. Arterial blood gases on 3 L of oxygen per minute via nasal cannula were as follows: pH 7.36, partial pressure of carbon dioxide (PCO_2) 58 torr, and partial pressure of oxygen (PO_2) 51 torr. Chest radiography showed further enlargement of the bibasilar bullae compressing the upper portions of

both lungs (Figure 2). A quantitative perfusion lung scan demonstrated 12% perfusion to the right lung and 88% perfusion to the left lung. Preoperative digital subtraction angiography of the pulmonary arteries revealed bilateral upward displacement of the pulmonary vasculature due to the lower lobe bullae. Based on these findings and the patient's clinical course, age, and general status, one-stage bilateral bullectomies via median sternotomy were planned.

Resection of the bullae was uneventful, and the compressed upper lobes were satisfactorily re-expanded. Pathological examination of the resected tissue revealed non-necrotizing granulomata consistent with sarcoidosis in addition to the giant bullae. The patient was extubated approximately 1 hour after surgery, and she reported immediate improvement in her respiratory symptoms. Bilateral chest tubes were inserted due to air leakage; these were removed on postoperative day 7 (right side) and day 9 (left side). The patient was discharged on postoperative day 13, while receiving oxygen via nasal cannula at a rate of 2 L/minute with a good oxygen saturation level (95%).

In subsequent follow-up visits, the patient reported improvement in her respiratory status; the supplemental oxygen was slowly tapered down. Eight months after surgery, she had gained 3 lb, her exercise tolerance had improved significantly, and she was using oxygen only intermittently. Evaluation of pulmonary function cor-

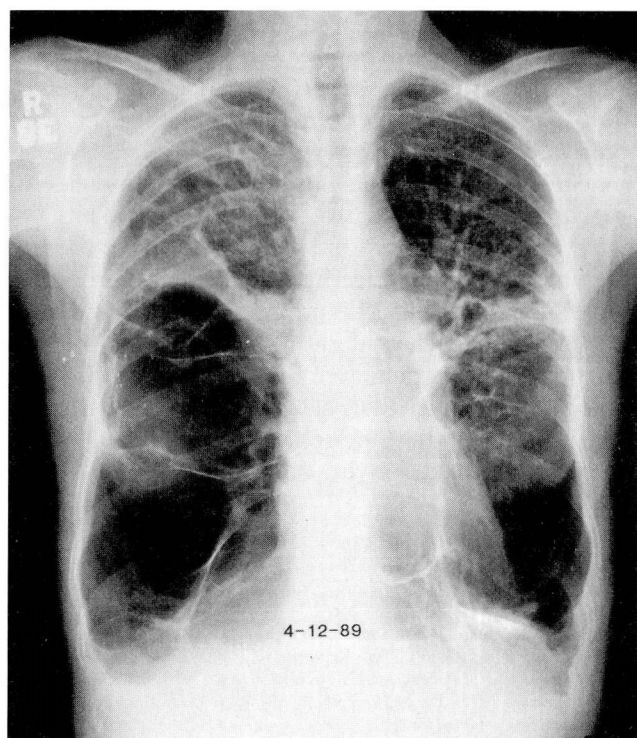


FIGURE 2. Large bilateral bullae in both lower lobes in a patient with sarcoidosis. The bullae produce compressive changes in the remaining lungs.

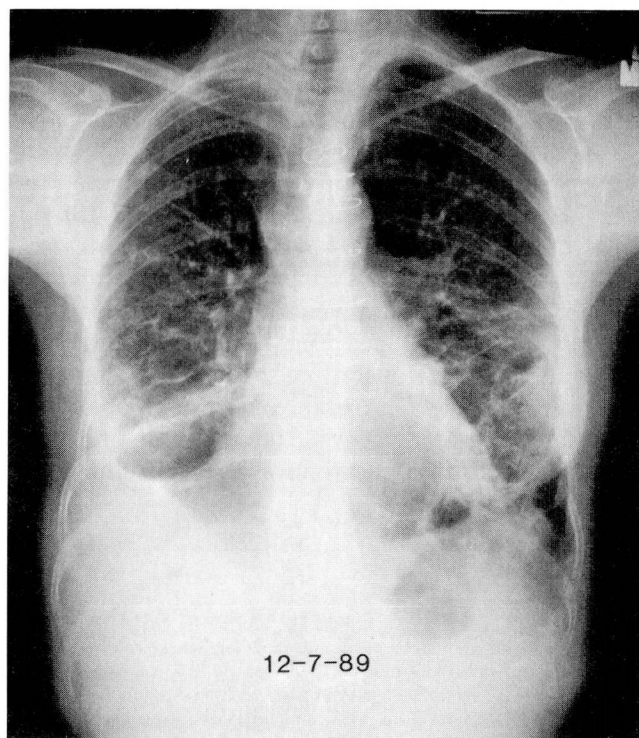


FIGURE 3. Chest radiograph 8 months after single-stage bilateral lower-lobe bullectomy via sternotomy revealing expansion of the upper lobes and interstitial infiltrates of sarcoidosis.

roborated her clinical status (Figure 1). Chest radiography showed well-expanded lungs with bilateral pleural parenchymal scarring, prominence of interstitial markings, and residual bullous changes in the left lung base (Figure 3). Arterial blood gases obtained while the patient was breathing room air showed a pH of 7.43, PCO_2 39 torr, PO_2 65 torr, and O_2 saturation 92%.

At that point, based on her general status, no further interventions were considered and periodic follow-up visits were scheduled.

DISCUSSION

Most patients with pulmonary sarcoidosis do well without treatment, clearing their disease totally in 1 or 2 years. However, some patients develop progressive disease leading to pulmonary fibrosis and, eventually, death due to respiratory insufficiency and cor pulmonale.⁷ Bullous and multicystic radiologic changes are often manifestations of irreversible end-stage disease. These bullae are similar to the bullous emphysema seen in some patients with severe chronic obstructive pulmonary disease and can be a cause of the “vanishing

lung” syndrome.⁸ On occasion, enlarging bullae can compress the functional portions of the lung, resulting in worsening of the restrictive defect. The presence of this complication can also be suspected from the radiographic appearance and confirmed by quantitative ventilation/perfusion scan and angiography.⁹ In addition, the bullae can rupture and produce spontaneous pneumothoraces, which can be fatal in the setting of a fibrotic lung. Once the disease has reached this stage, surgery can be an effective palliative treatment.⁹ Resection of the bullae, as in patients with bullous emphysema, may be considered in order to allow the relatively spared normal portions of the lungs to re-expand. In patients who underwent surgery for bullous emphysema, best results were obtained in those with giant bullae evidenced by a large difference in residual volume measured by body plethysmography and helium dilution, and in those with a normal diffusion capacity for carbon monoxide before surgery (indicating the absence of generalized lung emphysema).^{10,11} Arterial blood gases showing preoperative hypercapnia at rest often portend a difficult postoperative course,⁹ but this was not the case in our patient.

The procedure is technically easier when the bullae are in the upper lobes than in the lower lobes.¹² Depending on the extent of the disease, unilateral bullectomy via lateral thoracotomy or bilateral resections via median sternotomy can be performed. The traditional approach to patients with bilateral bullae has been staged bilateral thoracotomies. However, this approach has two major disadvantages: it requires two operations, and it entails increased risk of pulmonary complications—especially ventilatory impairment.^{6,13–15} Median sternotomy has been used for simultaneous bilateral pulmonary operations¹²; this procedure yields less postoperative pain and ventilatory impairment than lateral thoracotomy.¹⁵ In our case, one-stage bilateral lower-lobe bullectomies were successfully per-

formed via median sternotomy, resulting in subjective and objective improvement.

In summary, bullous changes associated with sarcoidosis result from extensive diffuse pulmonary fibrosis. Medical treatment with corticosteroids is usually ineffective. The bullae can progressively increase in size, compressing the relatively spared lung and producing severe respiratory insufficiency. As with one-stage bilateral upper-lobe bullectomy via median sternotomy in bullous emphysema, this procedure can be performed in cases of bullous sarcoidosis involving the lower lobes. However, this is a palliative form of therapy aimed at rehabilitation rather than cure⁶; its immediate benefits are evident, but the long-term results will depend on the course of the underlying disease.⁶

REFERENCES

1. Fanburg B, Pitt E. Sarcoidosis. In: Murray JF, Nadel JA, editors. Textbook of respiratory medicine. Philadelphia, PA: WB Saunders Company, 1988:1486–1500.
2. Johnson C. Sarcoidosis. In: Fishman A, 2nd ed. Pulmonary disease and disorders. New York: McGraw-Hill Book Company, 1988:619–644.
3. Kirks DR, McCormick VD, Greenspan RH. Pulmonary sarcoidosis, roentgenographic analysis of 150 patients. *AJR* 1973; **117**:777–786.
4. Felson B. Uncommon roentgen patterns of pulmonary sarcoidosis. *Dis Chest* 1958; **34**:357–367.
5. Harden KA, Barthakur A. “Cavitary” lesions in sarcoidosis. *Chest* 1959; **35**:607–614.
6. Lee M, Prosko D, Berger H, Lajam F. One-stage surgery for bilateral bullous emphysema via median sternotomy: report of three cases. *Mt Sinai J Med* 1983; **50**:522–526.
7. Thrasher DR, Briggs Jr DD. Pulmonary sarcoidosis. *Clin Chest Med* 1982; **3**:537–563.
8. Miller A. The vanishing lung syndrome associated with pulmonary sarcoidosis. *Br J Dis Chest* 1981; **75**:209–214.
9. Gaensler EA, Gaensler EHL. Surgical treatment of bullous emphysema. In: Bave AE, editor. Glenn's thoracic and cardiovascular surgery. Norwalk, Connecticut: Appleton & Lange, 1991:193–217.
10. Gaensler EA, Cugell DW, Knudson RJ, FitzGerald MX. Surgical management of emphysema. *Clin Chest Med* 1983; **4**:443–463.
11. Nickoladze GD. Functional results of surgery for bullous emphysema. *Chest* 1992; **101**:119–122.
12. Meng RL, Jensik RJ, Kittle CF, Faker LP. Median sternotomy for synchronous bilateral pulmonary operations. *J Thorac Cardiovasc Surg* 1980; **80**:1–7.
13. Takita H, Merrin C, Didolkar MS, Douglass HO, Edgerton F. The surgical management of multiple lung metastases. *Ann Thorac Surg* 1977; **24**:359–364.
14. Julian OC, Lopez-Belio M, Dye WS, Javid H, Grove WJ. The median sternal incision in intracardiac surgery with extracorporeal circulation. *Surgery* 1957; **42**:753–761.
15. Cooper JD, Nelems JM, Pearson FG. Extended indications for median sternotomy in patients requiring pulmonary resection. *Ann Thorac Surg* 1978; **26**:413–420.