

Mechanical lithotripsy of large common bile duct stones

JACQUES VAN DAM, MD, PhD, AND MICHAEL V. SIVAK, Jr, MD

■ Endoscopic removal of biliary calculi is a safe and effective alternative to surgical exploration of the common bile duct. However, as stones increase in diameter, endoscopic retrieval becomes more difficult and hazardous. Mechanical lithotripsy is an endoscopic technique used to crush common bile duct stones that are too large to be removed by conventional methods. In the 3 years following the introduction of this technique at our institution, 145 patients underwent endoscopic retrograde cholangiopancreatography for symptomatic choledocholithiasis. Endoscopic mechanical lithotripsy improved the overall success rate of common bile duct clearance from 86.2% to 94.5%. No morbidity or mortality was associated with the procedure. Therefore, we recommend mechanical lithotripsy when bile duct stones cannot be removed with conventional techniques.

□ INDEX TERMS: COMMON BILE DUCT CALCULI; LITHOTRIPSY; CHOLANGIOPANCREATOGRAPHY, ENDOSCOPIC RETROGRADE
□ CLEVE CLIN J MED 1993; 60:38-42

MECHANICAL LITHOTRIPSY is an endoscopic technique used to crush common bile duct stones too large to be removed with conventional methods. To determine the efficacy and limitations of endoscopic mechanical lithotripsy, we reviewed the medical records of all patients who underwent endoscopic retrograde cholangiopancreatography for choledocholithiasis in the first 3 years after endoscopic mechanical lithotripsy was introduced at our institution.

BACKGROUND

Cholecystectomy is one of the most common operations performed by general surgeons: 500,000 to

700,000 cholecystectomies are performed yearly in the United States.¹ Simple cholecystectomy is relatively safe, with an overall mortality of less than 1%.² However, for the 15% to 22% of patients who undergo common bile duct exploration at the time of cholecystectomy, operative mortality may be three to four times higher.¹⁻⁵

After remote cholecystectomy, patients frequently present with symptomatic retained common bile duct stones. In these patients, endoscopic stone removal following sphincterotomy is a safe and effective alternative to surgical exploration of the common bile duct. Sphincterotomy is successful in up to 96% of patients, and the overall ability to clear the common bile duct of stones approaches 90%.^{6,7} Although stones larger than 2.0 cm in diameter may occasionally be removed using standard techniques, endoscopic stone extraction becomes increasingly difficult as common bile duct stones exceed 15 mm in diameter.⁷ When conventional techniques fail, mechanical lithotripsy may be an effective alternative.

From the Department of Gastroenterology, The Cleveland Clinic Foundation.

Address reprint requests to J.V.D., Division of Gastroenterology, Brigham and Women's Hospital, 75 Francis Street, Boston, MA 02115.

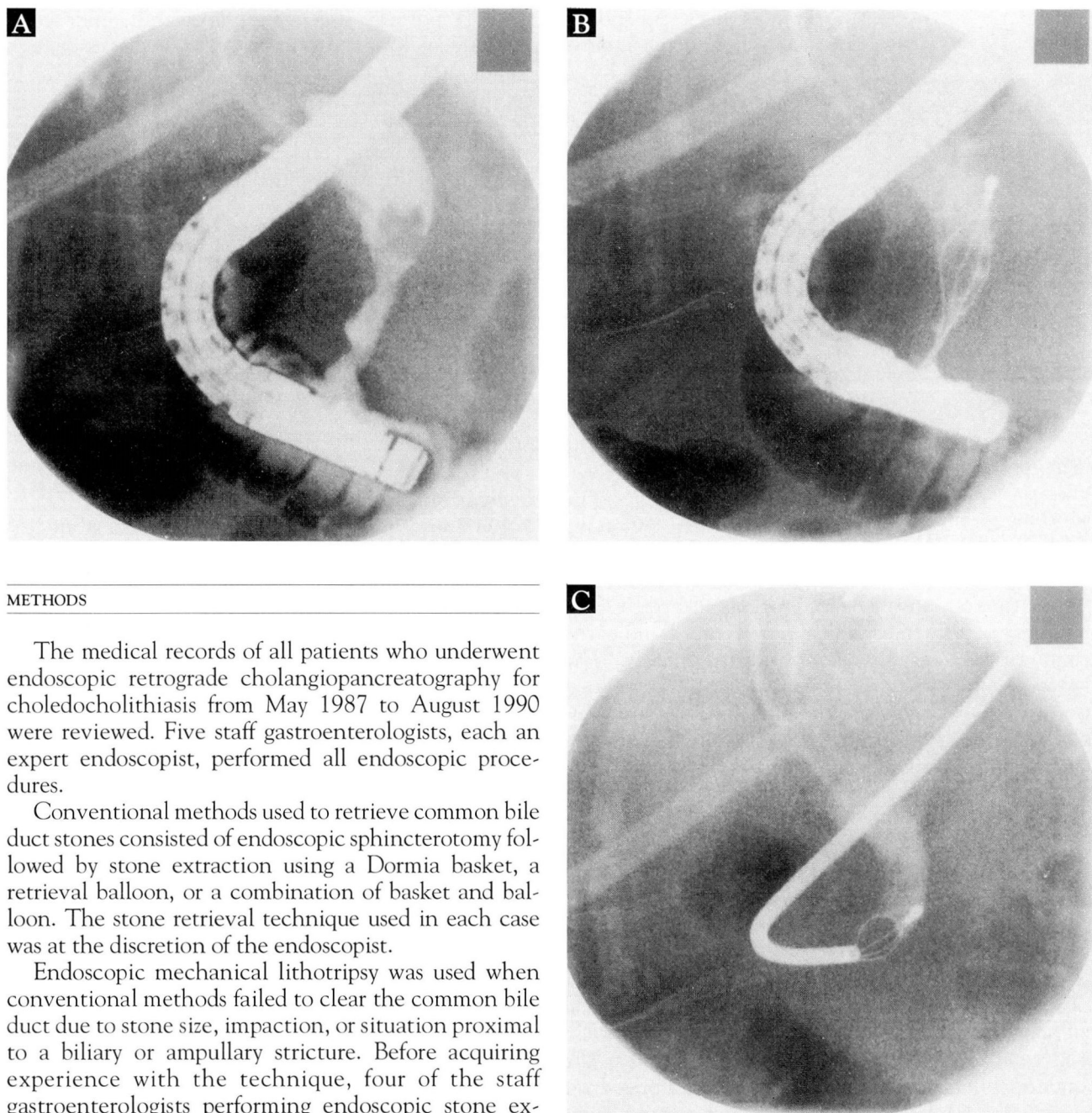


FIGURE 1. Radiographs showing stages of mechanical lithotripsy. With the side-viewing duodenoscope in position (A), a large common bile duct stone is entrapped within a special reinforced mechanical lithotripsy basket. The stone remains within the basket as the duodenoscope is removed (B). A steel spiral sheath is advanced along the basket wire to the stone (C). Mechanical force is then applied to the mechanical lithotripsy handle and delivered to the stone, fragmenting it (stone fragmentation is observed fluoroscopically).

METHODS

The medical records of all patients who underwent endoscopic retrograde cholangiopancreatography for choledocholithiasis from May 1987 to August 1990 were reviewed. Five staff gastroenterologists, each an expert endoscopist, performed all endoscopic procedures.

Conventional methods used to retrieve common bile duct stones consisted of endoscopic sphincterotomy followed by stone extraction using a Dormia basket, a retrieval balloon, or a combination of basket and balloon. The stone retrieval technique used in each case was at the discretion of the endoscopist.

Endoscopic mechanical lithotripsy was used when conventional methods failed to clear the common bile duct due to stone size, impaction, or situation proximal to a biliary or ampullary stricture. Before acquiring experience with the technique, four of the staff gastroenterologists performing endoscopic stone extraction had immediate access to the endoscopist who was expert in endoscopic mechanical lithotripsy. Therefore, all patients with indications for mechanical lithotripsy had similar access to the procedure.

The technique

In brief, endoscopic mechanical lithotripsy (Figure 1) is performed after a standard retrograde cholangiogram and endoscopic sphincterotomy. The common

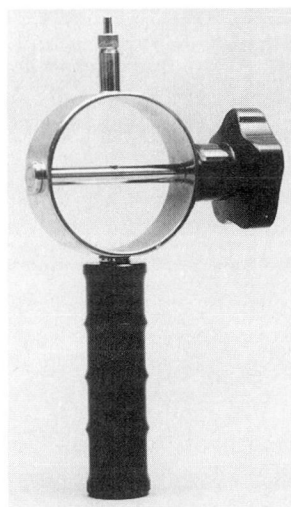


FIGURE 2. Mechanical lithotripter handle (Endotripter, G.P. McGown, Pembroke Pines, Fla).

bile duct stone is captured under fluoroscopic control in a four- or six-wire lithotripsy basket. The basket handle is then removed from the basket wire with wire cutters.

The endoscope is removed, and a steel spiral sheath (3.3 mm × 80 cm) is advanced under fluoroscopic guidance along the basket wire until it reaches the basketed stone. The basket wire and the proximal end of the spiral sheath are attached to the mechanical lithotripter handle (Figure 2). The stone is crushed by forcing the basket with its captured stone against the leading

edge of the steel sheath. This is accomplished by turning a lever on the mechanical lithotripter handle; the fragmentation is observed fluoroscopically. The duodenoscope is then repositioned, and the stone fragments are removed using standard techniques. Clearance of stones from the common bile duct is confirmed by retrograde cholangiography.

RESULTS

Of the 145 patients reviewed, 137 (94.5%) were endoscopically cleared of symptomatic biliary calculi. The conventional techniques used to clear the common bile duct were as follows: Dormia basket (18 patients, or 12.4%), retrieval balloon (29 patients, or 20.0%), and both the Dormia basket and retrieval balloon (89 patients, or 61.4%). Both methods were used when the endoscopist was unable to clear the common bile duct using either method alone. In 1 patient (0.7%), the common bile duct cleared spontaneously.

Mechanical lithotripsy was attempted in 14 patients when both conventional methods failed to clear the common bile duct. The general state of health and indications for stone extraction in these patients did not differ from those of patients in whom stones were removed using conventional methods. Stone fragmentation was achieved in 12 of these 14 patients (85.7%), and 1 required a second procedure on the day after an

initially unsuccessful attempt. Overall, endoscopic mechanical lithotripsy improved the success rate of common bile duct clearance in these 145 patients by approximately 8% (from 86.2% to 94.5%).

Eight patients were referred for operative treatment after unsuccessful endoscopic procedures (Table). Mechanical lithotripsy failed in two patients in spite of repeated endoscopic retrograde cholangiopancreatography with attempted mechanical lithotripsy on successive days. Failure of both mechanical lithotripsy and conventional methods in these two patients was attributed to the inability to entrap the stone within the mechanical lithotripsy basket. No morbidity or mortality was associated with mechanical lithotripsy regardless of whether stone removal was achieved.

DISCUSSION

Indications and risks

Retained symptomatic common bile duct stones following cholecystectomy are the primary indication for endoscopic sphincterotomy and stone extraction. Surgical cholecystectomy carries a less than 1% risk of mortality, which may increase threefold to fourfold for patients also undergoing a common bile duct exploration.^{1-5,8} Surgical exploration of the common bile duct carries a significantly increased risk in elderly or debilitated patients and requires a prolonged postoperative hospital recovery when compared with younger patients.⁹

Although sphincterotomy is associated with an increased risk of bleeding and perforation when compared with diagnostic endoscopic retrograde cholangiopancreatography,^{10,11} the mortality rate for endoscopic sphincterotomy and stone extraction is approximately 1.5%, and the procedure entails a shorter hospitalization than does surgical common bile duct exploration.^{12,13} Stones smaller than 1 cm in diameter may pass spontaneously through a sphincterotomy; however, stones larger than 1.5 cm pose a problem for endoscopic retrieval.^{10,14} From 5% to 10% of common bile duct stones must be fragmented before endoscopic extraction.^{11,15,16}

Indications for mechanical lithotripsy include large-diameter stones (including those disproportionately large in relation to the caliber of the distal common bile duct), impacted stones, or stones situated proximal to a biliary or ampullary stricture.¹⁷ Sphincterotomy is usually required prior to mechanical lithotripsy and stone extraction; however, mechanical lithotripsy through the intact papilla has been reported.^{18,19}

Devices

Mechanical lithotriptors are available in a number of models, all of which operate in essentially the same manner. Specially reinforced, "double strength" baskets have been designed with sufficient tensile strength to render them capable of crushing even extremely hard stones.²⁰ The reusable steel-reinforced sheath used in the present study is too large to pass through the working channel of the therapeutic duodenoscope (4.2-mm diameter), and therefore requires sacrifice of the basket handle and removal of the endoscope prior to stone fragmentation. Removing the basket handle renders the device unsuitable for reuse; at our institution, the patient is charged an additional \$85 for each wire basket sacrificed during mechanical lithotripsy. Alternative models of mechanical lithotriptors are designed to pass through the working channel of the duodenoscope, permitting the scope to remain positioned for fragment retrieval and confirmatory cholangiogram.²¹ Some permit contrast to be administered and endoscopic sphincterotomy to be performed with the lithotripter in place,¹⁸ thus avoiding the need for repeated intubation of the papilla of Vater.

Inability to capture stones

Failure of mechanical lithotripsy usually results from inability to capture the stone in the lithotripsy basket.^{14,17,22,23} In their study of 24 patients with large common bile duct stones (diameter >20 mm), Matsumoto et al attributed a 20% failure rate (5 of 24 patients) to the fact that large stones and multiple impacted stones left little space for basket manipulation to ensnare the stones within the bile duct.²² Others have also reported a 20% failure rate with mechanical lithotripsy^{11,24,25} and recommend using ultrasound to reduce the size of the stone before attempting mechanical stone fragmentation.²⁴

It may not be necessary for the entire stone to be captured within the basket: lithotripsy following repeated partial stone capture and fragmentation has been reported.^{11,17} Also, achieving fragmentation may require a second or third attempt.²³ In the present study, mechanical lithotripsy in one patient was achieved in a second procedure on the day after an initial unsuccessful attempt.

Alternative methods

Alternative methods for fragmenting common bile duct stones to facilitate endoscopic removal have been employed with varying degrees of success. Extracorporeal shock-wave lithotripsy, once limited to gallblad-

TABLE
PATIENTS REFERRED FOR OPERATIVE STONE REMOVAL

Number of patients	Reason for referral
2	Inability to entrap the stone within the basket
2	Unsuccessful sphincterotomy
1	Total common bile duct obstruction; impacted 3.0-cm × 2.5-cm stone found at laparotomy
1	Multiple common bile duct and intrahepatic duct stones
1	Patient unable to tolerate endoscopic procedure
1	Unsuccessful endoscopic retrograde cholangiopancreatography; reason not documented

der stones, is now being successfully applied to complicated bile duct stones.^{26,27} Electrohydraulic lithotripsy (using high-pressure shock waves generated by a high-voltage discharge), has been used in conjunction with endoscopic techniques to fragment biliary calculi.²⁸

Pulsed-dye laser lithotripsy is a promising new adjunct for the endoscopic removal of biliary calculi too large for conventional lithotripsy techniques. It is extremely effective in patients in whom standard basket extraction and mechanical lithotripsy have been unsuccessful.²⁹ The laser's energy is absorbed by the stone's surface, ionizing a small portion of the stone material. The resulting microscopic cloud of rapidly expanding electrons (called a "plasma") produces mechanical stress waves that fragment the stone.

CONCLUSION

Endoscopic mechanical lithotripsy is considered a reliable and safe technique for the intraductal fragmentation of large or impacted biliary calculi.^{11,17,18,23} In this series of 145 patients, endoscopic mechanical lithotripsy improved the success rate for clearing the common bile duct of symptomatic stones by approximately 8%. No mortality or morbidity was associated with the procedure. Based on our experience and a review of the literature, we recommend mechanical lithotripsy for patients in whom common bile duct stones cannot be removed with conventional techniques.

REFERENCES

1. Gliedman M, Wilk P. The present status of biliary tract surgery. *Surg Ann* 1985; 17:69-124.
2. Rogers A, Farha G, Beamer R, Chang F. Incidence and associated mortality of retained common bile duct stones. *Am J Surg* 1985; 150:690-693.

3. Martin J, van Heerden J. Surgery of the liver, biliary tract, and pancreas. *Mayo Clin Proc* 1980; **55**:333-337.
4. McSherry CK, Glenn F. The incidences and causes of death following surgery for nonmalignant biliary tract disease. *Ann Surg* 1980; **191**:271-275.
5. McSherry CK. Cholecystectomy: the gold standard. *Am J Surg* 1989; **158**:174-178.
6. Rothschild J, Kaplan M, Millan V, Reinhold R. Management of biliary obstruction. *Arch Surg* 1989; **124**:556-560.
7. Cotton PB. Non-operative removal of bile duct stones by duodenoscopic sphincterotomy. *Br J Surg* 1980; **67**:1-5.
8. Crumplin MKH, Jenkinson LR, Kassab JY, Whitaker CM, Al-Boutiahi FH. Management of gallstones in a district general hospital. *Br J Surg* 1985; **72**:428-432.
9. Hacker KA, Schultz CC, Helling TS. Choledochotomy for calculous disease in the elderly. *Am J Surg* 1990; **160**:610-613.
10. Taylor BR, Ho CS. Nonsurgical treatment of common bile-duct-stones. *Can J Surg* 1984; **27**:28-32.
11. Riemann JF, Seuberth K, Demling L. Mechanical lithotripsy of common bile duct stones. *Gastrointest Endosc* 1985; **31**:207-210.
12. Reiter JJ, Bayer HP, Mennicken C, Manegold BC. Results of endoscopic papillotomy: a collective experience from 9 endoscopic centers in West Germany. *World J Surg* 1978; **2**:505-507.
13. Miller BM, Kozarek RA, Ryan JA, Ball TJ, Traverso LW. Surgical versus endoscopic management of common bile duct stones. *Ann Surg* 1988; **207**:135-141.
14. Leung JWC, Chung SCS, Mok SD, Li AKC. Endoscopic removal of large common bile duct stones in recurrent pyogenic cholangitis. *Gastrointest Endosc* 1988; **34**:238-241.
15. Cotton PB. Endoscopic management of bile duct stones: (apples and oranges). *Gut* 1984; **25**:587-597.
16. Siegel JH. Endoscopic papillotomy: sphincterotomy or sphincteroplasty. *Am J Gastroenterol* 1979; **72**:511-516.
17. Riemann JF, Seuberth K, Demling L. Clinical application of a new mechanical lithotriptor for smashing common bile duct stones. *Endoscopy* 1982; **14**:226-230.
18. Staritz M, Ewe K, Meyer zum Buschenfelde KH. Mechanical gallstone lithotripsy in the common bile duct: in vitro and in vivo experience. *Endoscopy* 1983; **15**:316-318.
19. Riemann JF, Seuberth K, Demling L. Mechanical lithotripsy through the intact papilla of Vater. *Endoscopy* 1983; **15**:111-113.
20. Higuchi T, Kon Y. Endoscopic mechanical lithotripsy for the treatment of common bile duct stone: experience with the improved double sheath basket catheter. *Endoscopy* 1987; **19**:216-217.
21. Chung SCS, Leung JWC, Leong HT, Banez VP, Li AKC. Endoscopic extraction of large common duct stones using a mechanical lithotripsy basket [abstract]. *Gastrointest Endosc* 1991; **37**:252.
22. Matsumoto S, Ikeda S, Tanaka M, Yoshimoto H, Nakayama F. Non-operative removal of giant common bile duct calculi. *Am J Surg* 1988; **155**:780-782.
23. Siegel JH, Ben-Zvi JS, Pullano WE. Mechanical lithotripsy of common duct stones. *Gastrointest Endosc* 1990; **36**:351-356.
24. Demling L, Ermert H, Riemann JF, Schmolke G, Heyder N. Lithotripsy in the common bile duct using ultrasound: primary in vitro experience. *Endoscopy* 1984; **16**:226-228.
25. Shaw MJ, Dorsher PJ, Vennes JA. A new mechanical lithotriptor for the treatment of large common bile duct stones. *Am J Gastroenterol* 1990; **85**:796-798.
26. Weber J, Adamek HE, Riemann JF. Extracorporeal piezoelectric lithotripsy for complicated bile duct stones. *Am J Gastroenterol* 1991; **86**:196-200.
27. Moody FG, Amerson JR, Berci G, et al. Lithotripsy for bile duct stones. *Am J Surg* 1989; **158**:241-247.
28. Leung JWC, Chung SCS. Electrohydraulic lithotripsy with peroral choledochoscopy. *Br Med J* 1989; **299**:595-598.
29. Ponchon T, Gagnon P, Valette P, Henry L, Chavaillon A, Thieulin F.