

MULTIPLE HEMORRHAGIC TELANGIECTASIS WITH SPECIAL REFERENCE TO GASTRO- SCOPIC APPEARANCE

JOHN F. RENSHAW, M. D.

The gastroscopic appearance of gastric telangiectasis has not been described, and a review of the literature revealed apparently only one description of the post-mortem appearance¹.

The following case is reported because telangiectases of the gastric mucosa were observed gastroscopically and because the patient presented an occult anemia in which the gastroscopic examination was an important diagnostic procedure.

A white man, a sheetmetal worker 44 years of age, was first seen at the Clinic on January 9, 1939, complaining of weakness and lack of strength. The present illness had its onset in the autumn of 1927 when, over a period of a few weeks, he noticed progressive weakness, lack of strength, and increased sensitivity to cold. This episode lasted three or four months but after he consulted his family doctor, it was relieved by the use of iron for a short time. No examinations of the blood or stools were made. Following this he apparently felt well until 1932 when he had a recurrence of similar symptoms which again were relieved by the use of iron for a short period. About October, 1936, the patient had six teeth extracted without any unusual bleeding but following the extraction he felt tired, run down, and cold all the time. He consulted another doctor in November, 1936, at which time his erythrocyte count was reported to be 4,240,000 and the hemoglobin was 27 per cent. Repeated examinations of stools showed occult blood by the benzidine test. After the patient used liver extract and iron, the hemoglobin was reported to be 90 per cent two months later, but from November, 1936, to March, 1937, the stools were consistently found to contain varying degrees of occult blood. The patient could not remember that any of his stools had been black except while iron therapy was used. There had, however, been some bright red blood in the stools without rectal pain on at least one occasion in 1935 and again in January, 1937. In March, 1937, he was referred by his family doctor to a consultant at which time the significant physical findings were pale skin and mucous membranes, except the nasal mucous membrane which was red, and red spots on the tongue, lips, and buccal mucosa. The spots were not raised or tender. A sigmoidoscopic examination revealed a pale mucous membrane and internal hemorrhoids. Otherwise the physical examination gave normal findings. Roentgen examination of the gastrointestinal tract was reported to reveal: "A very small defect in the pylorus" more suggestive of spasm than organic change. The duodenum

MULTIPLE HEMORRHAGIC TELANGIECTASIS

was normal and the colon was negative except for "moderate dilatation of the lower sigmoid and rectum." A gastroscopic examination was also done at that time. The fundus and cardia were reported to be normal. There was "some gastritis" of the antrum but in general the visualization was not satisfactory and the examiner asked for a recheck examination.

Other laboratory procedures were reported by the consultant as follows: The level of the hemoglobin was 72 per cent, the erythrocyte count was 4,530,000, the white blood count was 8,350 with a normal differential count. The urine showed no abnormalities. The stools were black and were 4 plus positive for occult blood and bile. A gastric analysis revealed 92 units of free hydrochloric acid and 110 of total acid. The indirect van den Bergh reaction was positive but the direct reaction was negative. The icterus index was 10 units. The Wassermann reaction of the blood was negative.

The patient was advised as to diet and medication, which was chiefly extract of belladonna before meals and alkaline powders frequently between meals. He did not follow the management carefully and because his symptoms of fatigue and weakness persisted, he was referred to the Clinic.

The family history was negative for any bleeding or anemia. The general questionnaire and review of the systems was negative except for the following features: As a child he had many nosebleeds and at the time of our examination his nose would bleed easily. He had not noticed the red spots on the tongue and lips until 1936 although his tongue had been sore intermittently since 1927. He had been singularly free from gastro-intestinal or abdominal distress. The bowel habits were normal and laxatives were not used.

Physical examination at the Clinic revealed the patient to be well developed and nourished. The skin was pale. There were multiple, small red spots around the mouth and on the lips, being more abundant on the lower lip with several on the cheek and nose. The lesions were oval or irregularly circular; very few were linear or web-like. They were not tender but blanched on pressure. They were a brilliant, blood-red color. The eyes, including examination of the fundus, were normal, as were the ears. There was a marked deviation of the nasal septum to the right and the turbinates were pale. A few telangiectatic lesions were seen scattered over the septum, turbinates, and in the nasopharynx. The tonsils had been removed. The vocal cords were smooth and freely movable but diffusely reddened because of telangiectasia. There was no lymphadenopathy. The thyroid was the usual size and consistency. The chest was clear to percussion and auscultation, the heart borders were within normal limits, and the tones were of good quality. No murmurs were heard. The rhythm was regular at 60 beats per minute. The systolic

blood pressure was 140 mm. of mercury and the diastolic pressure was 90 mm. of mercury. There was no abdominal tenderness and no masses or organs were palpated. The genitalia were normal except for a non-tender small swelling in the left testicle or spermatic cord. Several years previously the patient had been hit in this region with a baseball. Digital examination of the rectum was negative and an anoscopic examination for six inches showed no telangiectasia or hemorrhoids. The neurological examination gave normal findings.

A blood study by the special blood laboratory revealed an erythrocyte count of 6,260,000 cells with severe anisocytosis, poikilocytosis, and pallor. The hemoglobin was 11 grams per 100 cc. or 71 per cent. The volume of packed cells was 40 cc. per 100 cc. of blood, or 89 per cent. The volume index was 0.71, the color index 0.57, and the saturation index 0.80. The white blood cells numbered 4,250 and the differential count showed 55 per cent neutrophils, 31 per cent lymphocytes, 3 per cent eosinophils, 7 per cent monocytes, and 4 per cent basophils. There were no abnormal forms. The icterus index was 4 units and the platelets were normal. The mean cell diameter was 8.1 microns.

Other laboratory tests included examination of the urine which was normal. The blood Wassermann and Kahn tests gave negative reactions. The level of the fasting blood sugar was 104 mg. per 100 cc. Four liquid stools obtained following the administration of magnesium sulfate were examined while fresh on a warm microscopic stage and were found to be negative for ova or parasites but gave 2 and 3 plus reactions to benzidine. The fractional gastric analysis, using 35 grams of bread and 350 cc. of water, revealed the following acid figures at 15 minute intervals. No fasting secretion was obtained. Free hydrochloric acid was 20, 50, 60, 70, 60, 50, 30, and 40 units. The total acidity was 50, 90, 100, 90, 80, 80, 50, 60. There was no occult blood, mucus, or bile, and no food residue after 90 minutes. A duodenal drainage was normal.

The gastroscopic examination was easy and all parts of the stomach were well visualized, including the lesser curvature of the antrum. Cooperation was excellent. Peristalsis was unusually vigorous and deep, rolling out the entire antrum before reaching the pylorus. The pylorus in the patent phase was round and smooth; when completely closed there was considerable redundancy and puckering of the mucosa with regurgitation of the duodenal contents. The mucosa of the antrum was smooth, glistening, and orange-red. It appeared to be the usual color and texture. There were eight millet seed to pinhead sized, bright red spots in the mucosa (this is the actual size seen through the gastroscope and not the estimated size of the lesion in the stomach). These spots were circular and seemed to catch the highlight as if slightly raised.

MULTIPLE HEMORRHAGIC TELANGIECTASIS

They were all of uniform color, being a brilliant blood-red or carmine. The angulus was smooth and two more similar red lesions were seen on it. The musculus sphincter antri was high and smooth and there was one red spot on the crest of the fold (Fig. 1). In the lesser curvature of the body four additional such red spots were seen. The mucosa of the lesser curvature was smooth, glistening, and the usual pink to orange-red color. Just proximal to the level of the angulus, the mucosa of both the

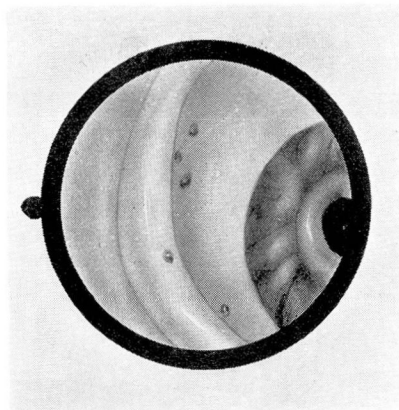


FIGURE 1: Telangiectatic lesions on musculus sphincter antri of anterior wall.

anterior and posterior walls became lusterless and granular. The changes were progressively more severe in the upper parts of the stomach and in the upper half the mucosa was definitely granular and nodular. In some places, particularly on the posterior wall, it caused the mucosa to have a cobblestone or mosaic pattern. The folds, however, seemed to be of the usual caliber and distribution. Six more red spots were observed in the upper parts of the stomach but they were more widely scattered than in the lower part.

- Diagnosis:
1. Hypertrophic gastritis of the body and fundus.
 2. Multiple telangiectasia of the stomach.

COMMENT

The question of interpretation of these red lesions is important. How can we say that these are telangiectases rather than pigment spots or chronic localized gastric purpura? The lesions were considered to be telangiectatic because:

1. They were more widespread than pigment spots usually are.
2. The lesser curvature, where pigment spots usually occur more

abundantly than in any other region, was not involved any more than other areas of the stomach.

3. The lesions were all of a uniform, bright red color and showed no evidence of dark red or brown coloration commonly seen with older pigment spots. It is unlikely that so many lesions so widely separated should occur simultaneously.

4. The demonstration of telangiectatic lesions on the lips, tongue, buccal mucosa, nasal mucosa, nasopharynx, and vocal cords makes it seem reasonable that they could occur on the mucous membrane of the stomach.

REFERENCE

- Osler, William: On a family form of recurring epistaxis associated with multiple telangiectasis of the skin and mucous membranes, Johns Hopkins Hosp. Bull., 12:333-337, (November) 1901.