

MOULAY A. MEZIANE, MD, EDITOR

# Expansile tibial lesion in a 23-year-old man

DAVID PIRAINO, MD, AND THOMAS W. BAUER, MD, PhD

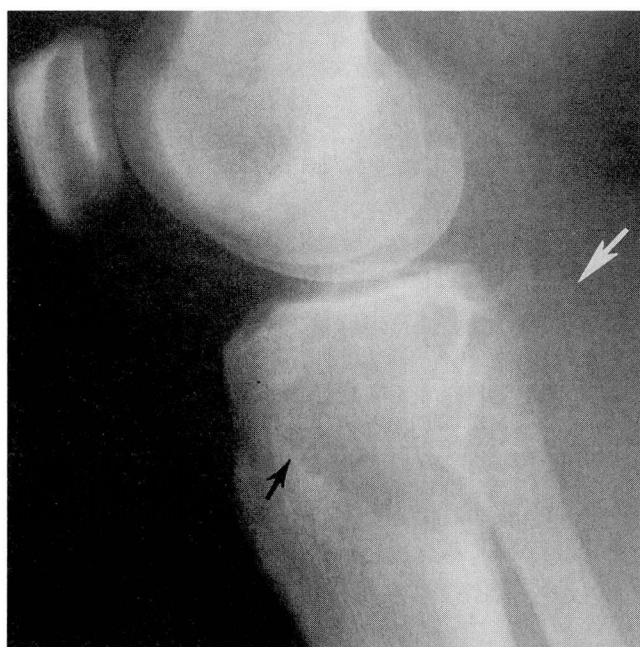

FIGURE 1. Lateral film of the knee demonstrates a well-defined lytic lesion (black arrow) in the proximal tibia. Posterior cortex of the tibia is not well defined, and there is a suggestion of a thin rim of bone in the soft tissue (white arrow).

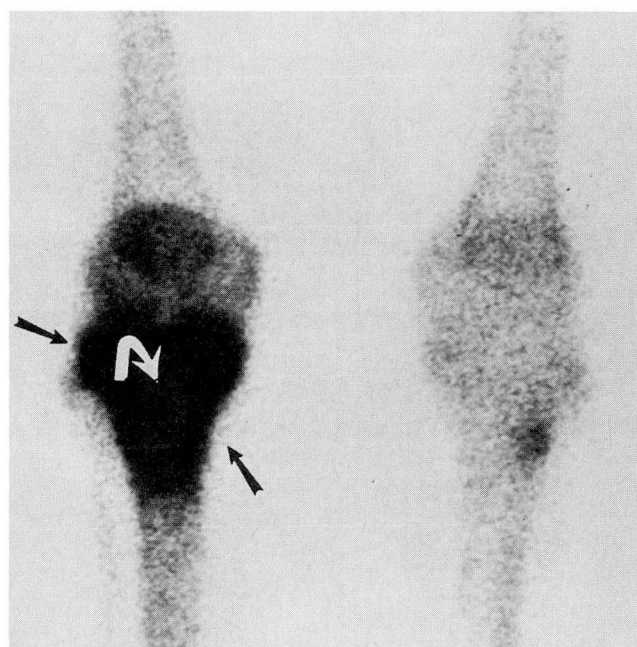


FIGURE 2. Delayed image from a technetium Tc 99m radio-nucleotide bone scan demonstrates a focal area of increased activity involving the proximal right tibia (black arrows). There is a suggestion of a central area of slightly less intense activity (curved arrow) in the center of the region of increased activity.

**A** 23-YEAR-OLD MAN presented with a 3-week history of right knee pain. Physical exam revealed a mass posterior to the right knee. The rest of the physical examination was unremarkable.

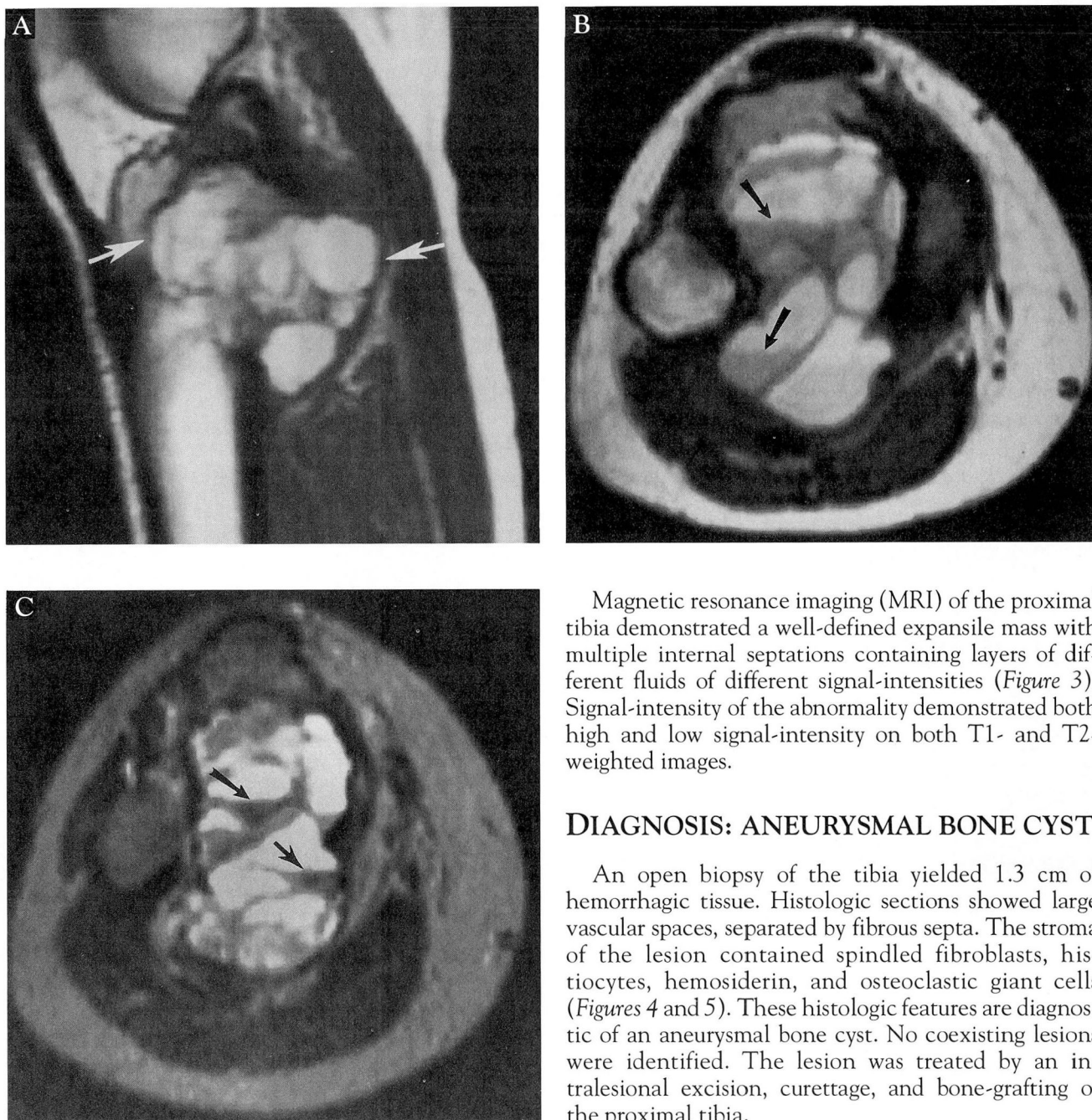
Plain radiographs of the knee demonstrated a lytic

lesion measuring approximately 8 cm in greatest dimension involving the proximal epiphysis and metaphysis of the tibia. Expansion of the posterior cortex of the proximal tibia was noted, with a thin rim of calcification identified posteriorly (*Figure 1*). The lesion demonstrated well-defined margins and abutted the subchondral bony plate at the knee. A three-phase bone scan demonstrated increased perfusion and increased activity on the blood pool images inferior to the right knee. Delayed images also showed increased activity in the proximal tibia (*Figure 2*). No other focal abnormalities were identified.

From the Departments of Radiology (D.P.) and Pathology (T.W.B.), The Cleveland Clinic Foundation.

Address reprint requests to Moulay A. Meziane, MD, Department of Diagnostic Radiology, The Cleveland Clinic Foundation, 9500 Euclid Avenue, Cleveland, OH 44195.





**FIGURE 3.** MRI of the proximal right tibia. A T1-weighted sagittal image of the proximal tibia (A) demonstrates a multiloculated lesion involving the proximal tibia and extending into the soft tissues (arrows). An axial T1-weighted image through the proximal tibia and fibula (B) identifies the multiloculated lesion of the proximal tibia extending into the soft tissue. Arrows demonstrate layers of different fluids of different signal intensities on the T1-weighted image. A T2-weighted axial image through this same area (C) demonstrates fluid-fluid levels (arrows) involving the multiloculated lesion.

Magnetic resonance imaging (MRI) of the proximal tibia demonstrated a well-defined expansile mass with multiple internal septations containing layers of different fluids of different signal-intensities (*Figure 3*). Signal-intensity of the abnormality demonstrated both high and low signal-intensity on both T1- and T2-weighted images.

### DIAGNOSIS: ANEURYSMAL BONE CYST

An open biopsy of the tibia yielded 1.3 cm of hemorrhagic tissue. Histologic sections showed large vascular spaces, separated by fibrous septa. The stroma of the lesion contained spindle fibroblasts, histiocytes, hemosiderin, and osteoclastic giant cells (*Figures 4 and 5*). These histologic features are diagnostic of an aneurysmal bone cyst. No coexisting lesions were identified. The lesion was treated by an intralesional excision, curettage, and bone-grafting of the proximal tibia.

### DISCUSSION

Aneurysmal bone cyst consists of thin-walled, blood-filled cystic cavities. This abnormality is generally considered nonneoplastic and can be associated with a variety of benign skeletal processes including chondroblastoma, chondromyxoid fibroma, osteoblastoma, giant cell tumor, and fibrous dysplasia.



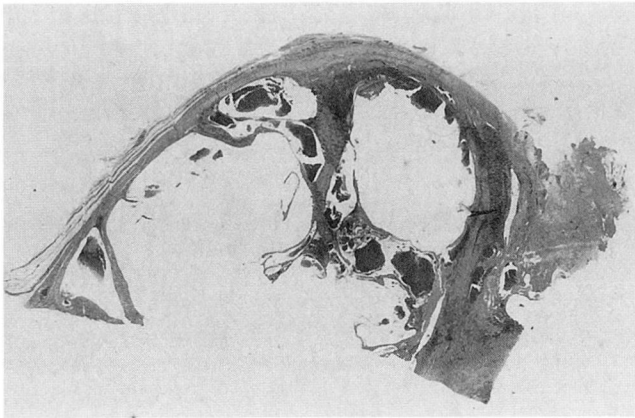


FIGURE 4. Low-magnification photomicrograph illustrating cystically dilated vascular spaces separated by fibrous septa.

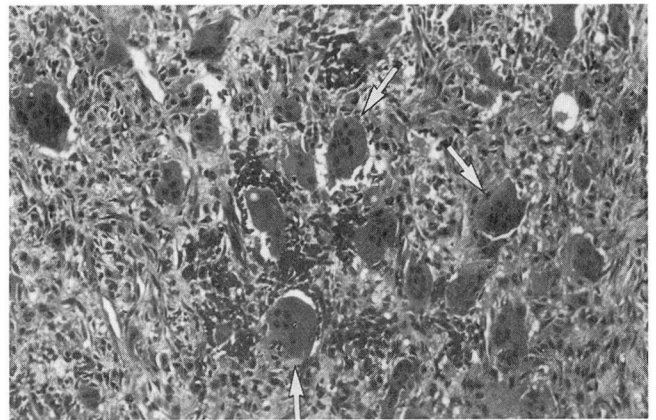


FIGURE 5. Osteoclastic giant cells (arrows) are common in aneurysmal bone cysts but are focally distributed and are often surrounded by a stroma of spindled cells.

Aneurysmal bone cysts have also been associated with previous fractures.<sup>1</sup>

Any bone of the skeleton may be affected by aneurysmal bone cyst, but the long tubular bones are most frequently affected. Eighty percent of the patients with aneurysmal bone cysts are under age 20, although lesions have been reported in patients as young as age 3 and as old as age 70.<sup>2</sup> In the tubular bones, aneurysmal bone cysts are most common in the metaphysis.

Clinical findings include local pain, swelling, and increased skin temperature. If the aneurysmal bone cyst is adjacent to a joint, restriction of motion may occur. In the spine, these lesions can cause neurologic abnormalities.

Radiographically, aneurysmal bone cysts present as eccentric osteolytic lesions within the metaphysis of long tubular bones. These lesions are usually well defined, but they may be expansile. There is loss of cortical definition with only a thin osseous shell around the expanded lesion. The radiographic differential diagnosis includes giant cell tumor, enchondroma, giant cell reparative granuloma, brown tumor of hyperparathyroidism, chondroblastoma, telangiectatic osteosarcoma, and osteoblastoma.<sup>2</sup>

Bone scans typically demonstrate increased uptake of radioactive material at the periphery of the lesion, with less activity towards the center. This pattern is nonspecific and also can be seen with giant cell tumors and chondrosarcomas.

MRI characteristics include areas of increased and decreased signal-intensity on both T1- and T2-weighted images.<sup>3</sup> Commonly, a rim of low signal-in-

tensity is identified surrounding the lesion indicating a nonaggressive process. Layers of different fluid- intensities within numerous well-defined cystic cavities are commonly identified on MRI.<sup>4</sup> Diverticulum-like projections are also seen arising from the walls of larger cysts.<sup>5</sup> MRI evaluation of these lesions is helpful in determining their extent and suggesting their diagnosis.

Biopsy specimens of aneurysmal bone cysts are frequently brown or frankly hemorrhagic in appearance. Cavernous vascular spaces are present, and these may or may not be lined by endothelial cells. Osteoclastic giant cells are common but tend to be focally distributed throughout the lesion, often clustering around recent and organizing hemorrhage. The focal distribution of giant cells in an aneurysmal bone cyst helps distinguish it from a giant cell tumor of bone, in which giant cells are more uniformly distributed. The mononuclear cells of an aneurysmal bone cyst tend to be spindled, an observation helpful in distinguishing an aneurysmal bone cyst from a chondroblastoma or giant cell tumor. Reactive bone formation may occur within the fibrous septa, but it should not be misinterpreted as a bone-forming tumor. Mitotic figures may be present, but nuclear pleomorphism is not. If bizarre giant cells are present, the possibility of a telangiectatic osteosarcoma must be considered. The biopsy must be carefully studied to exclude other lesions that frequently coexist with aneurysmal bone cysts.

While large vascular spaces separated by fibrous septa are characteristic of aneurysmal bone cysts, in

some lesions solid areas predominate.<sup>6</sup> The appearance of a solid area of an aneurysmal bone cyst is essentially identical to the appearance of a giant cell reparative granuloma or a brown tumor of hyperparathyroidism.<sup>7</sup> As with many bone lesions, careful correlation be-

tween clinical findings and radiologic and histologic appearance is necessary to establish the correct diagnosis. Characteristic radiologic findings (plain radiograph, MRI, bone scan) should help in suggesting the diagnosis of this surgically treatable lesion.

#### REFERENCES

1. Hudson TM. Radiologic-pathologic correlation of musculoskeletal lesions. Baltimore: Williams & Wilkins, 1987:261–287.
2. Resnick D, Kyriackas M, Greenway GD. Tumor and tumor-like lesions of bone: imaging and pathology of specific lesions. In: Resnick D, Niwayama G, editors. Diagnosis of bone and joint disorders. Philadelphia: WB Saunders, 1988:3831–3842.
3. Zimmer WD, Berquist TH, Sim FH, et al. Magnetic resonance imaging of aneurysmal bone cyst. Mayo Clin Proc 1984; **59**:633–636.
4. Hudson TM, Hamlin DJ, Fitzsimmons Jr. Magnetic resonance imaging of fluid levels in an aneurysmal bone cyst and in anticoagulated human blood. Skeletal Radiol 1985; **13**:267–270.
5. Beltran J, Simon DC, Levy M, Herman L, Weis L, Mueller CF. Aneurysmal bone cysts: MR imaging at 1.5T. Radiology 1986; **158**:689–690.
6. Sanerkin NG, Mott MG, Roylance J. An unusual intraosseous lesion with fibroblastic, osteoclastic, osteoblastic, aneurysmal, and fibromyxoid elements. "Solid" variant of aneurysmal bone cyst. Cancer 1983; **51**:2278–2286.
7. Dahlin DC, McLeod RA. Aneurysmal bone cyst and other non-neoplastic conditions. Skeletal Radiol 1982; **8**:243–250.

