



Primary angiitis of the central nervous system: diagnostic criteria and clinical approach

LEONARD H. CALABRESE, DO; ANTHONY J. FURLAN, MD; LISA A. GRAGG, MS; TRUMAN J. ROPOS, DO

■ Primary angiitis of the central nervous system has until recently been considered rare, usually progressive, and untreatable. In 1987, preliminary diagnostic criteria for the disorder were proposed in the hope of gaining a more accurate description of the disease. We used these criteria in reviewing all cases reported in the English language (99 cases) and those seen at The Cleveland Clinic Foundation (9 cases). We believe that the disorder is heterogeneous, and has a better prognosis than previously thought. Furthermore, a relatively benign subset of this disorder, termed "benign angiopathy of the central nervous system," can be defined on clinical grounds. We propose a revised set of diagnostic criteria and a practical approach to treatment.

□ INDEX TERMS: VASCULITIS; CENTRAL NERVOUS SYSTEM DISEASES □ CLEVE CLIN J MED 1992; 59:293-306

PPrimary angiitis of the central nervous system (PACNS), also known as isolated angiitis of the CNS or granulomatous angiitis of the CNS, is a poorly understood disorder in which vasculitis confined to the CNS occurs in the absence of any systemic disease that may contribute to such a process. First described in the mid-1950s, the condition is considered rare: only 46 cases were reported in the English language by 1986.¹ Prior to 1980, the disorder was described as homogeneous and

highly resistant to corticosteroid therapy, with a chronic progressive course and a high mortality rate. The pathology consisted of granulomatous angiitis affecting the small leptomeningeal and parenchymal blood vessels.

Recent trends have prompted a reappraisal of PACNS. The early experience was based on untreated cases which were identified at postmortem examination, but since 1975 an increasing number of cases have been diagnosed on the basis of arteriographic abnormalities alone, without pathologic documentation. As a result, the disease has become much more frequently reported: 62 of the 108 cases included in this review were described since 1986.

In 1983, Cupps et al² reported successful treatment of PACNS by combined corticosteroid and cytotoxic therapy. This report increased enthusiasm for early and aggressive treatment. Today, it is common for PACNS to be diagnosed on angiographic grounds alone and for

From the Departments of Rheumatic and Immunologic Disease (L.H.C.), Neurology (A.J.F.), and Biostatistics (L.A.G.), The Cleveland Clinic Foundation, and the Department of Rheumatic and Immunologic Disease (T.J.R.), Cleveland Clinic Florida.

Address reprint requests to L.H.C., Head, Section of Clinical Immunology, Department of Rheumatic and Immunologic Disease, The Cleveland Clinic Foundation, 9500 Euclid Avenue, Cleveland, Ohio 44195-5028.

TABLE 1
CONDITIONS RESEMBLING PACNS EXCLUDED
BY THE PRELIMINARY DIAGNOSTIC CRITERIA

Systemic vasculitides
Polyarteritis nodosa
Allergic granulomatosis
Hypersensitivity vasculitis
Vasculitis with connective tissue disease
Henoch-Schönlein purpura
Wegener's granulomatosis
Temporal arteritis
Takayasu's arteritis
Behçet's syndrome
Lymphomatoid granulomatosis
Infection
Viral
Bacterial
Fungal
Rickettsial
Neoplasm
Hodgkin's and non-Hodgkin's lymphoma
Leukemia
Small-cell lung cancer
Atrial myxoma
Malignant angioendotheliomatosis
Drug use
Amphetamines
Heroin
Ephedrine
Allopurinol
Other vasculopathies
Fibromuscular dysplasia
Moyamoya disease
Thrombotic thrombocytopenic purpura
Sickle cell anemia
Cerebrovascular atherosclerosis
Sarcoidosis

the patient then to be treated with corticosteroids and cytotoxic drugs, often for prolonged periods of time. This approach is justified, based on the assumption that angiographically and pathologically documented cases of PACNS are clinically equivalent.

Over the past decade there have been numerous case reports of a benign or more self-limited form of PACNS, often described as isolated benign cerebral vasculitis.^{3,4} These cases had nonprogressive courses and a high rate of survival; many of the patients were treated with minimal therapy. Nearly all of these cases were diagnosed on angiographic grounds alone.

These reports led us to question whether PACNS is more heterogeneous than previously recognized, and whether more benign subsets of PACNS can be clinically identified and treated less aggressively. Unfortunately, without prospective clinical experience or a large clinical series, rigorous conclusions regarding the illness, its treatment, and outcome must be made with caution. In 1987, we proposed preliminary diagnostic

TABLE 2
CLINICAL FEATURES OF PACNS IN 108 PATIENTS

Symptoms	n (%)
Headache	67 (62.0)
Paresis	60 (55.6)
Decreased cognition	55 (50.9)
Decreased consciousness	31 (28.7)
Seizure	23 (21.3)
Spinal cord problems	19 (17.6)
Cerebral hemorrhage	4 (3.7)
Fever	21 (19.4)
Weight loss	13 (12.0)
Duration of symptoms	
<4 weeks	43 (40.2)
4-12 weeks	22 (20.6)
>12 weeks	42 (39.3)
Nature of findings	
Focal only	35 (32.4)
Diffuse only	12 (11.1)
Focal and diffuse	57 (52.8)

criteria for PACNS that were designed to provide a more uniform assessment of its clinical manifestations, diagnostic studies, and therapy.¹ Using these criteria, we examined the reported cases of PACNS, and propose a revision of the diagnostic criteria and a practical approach to diagnosis and management.

REPORTED CASES OF PACNS

We analyzed all cases of PACNS reported through January 1990 from case records of The Cleveland Clinic Foundation (n=9)¹ and cases reported in the English language medical literature (n=99).²⁻⁷⁵ The diagnostic criteria were those proposed in 1987¹: each case had a history or clinical finding of an acquired neurologic deficit affecting the CNS and unexplained by another process, classic angiographic or histopathologic features of angiitis within the CNS, and no evidence of systemic vasculitis or any other condition to which the angiographic or pathologic features could be secondary. These exclusionary conditions are presented in *Table 1*.

Sixty-five variables were analyzed, including clinical symptoms and signs, time course, diagnostic studies (including biopsy, angiography, computed tomography (CT) scans, magnetic resonance imaging (MRI), electroencephalography (EEG), cerebrospinal fluid (CSF) analysis, and laboratory studies), associated conditions, treatment, and outcome.

In comparing subgroups, the exact chi-square was used for categorical variables and a Wilcoxon test was used for the numeric variables.

TRENDS IN PACNS

Figure 1 displays diagnostic, therapeutic, and mortality trends in PACNS. Most of the early cases were diagnosed only at postmortem examination. Postmortem diagnoses have progressively diminished in recent times: nearly one third of the cases reported since 1984 were diagnosed antemortem on angiographic grounds, without biopsy confirmation.

Before 1975, the majority of cases went untreated. These patients suffered from poorly understood progressive neurologic diseases that were discovered to have been PACNS only at postmortem examination. Over the past decade, earlier diagnosis has permitted treatment with a variety of therapeutic regimens. Since the 1983 report of successful therapy with corticosteroids and cytotoxic drugs, the trend has been for the majority of patients to be treated with combination regimens.

The trend in mortality since 1975 has been toward improved survival. Some investigators have concluded that this is solely due to the use of combination cytotoxic and corticosteroid therapy,^{1,76} but historical biases must be accounted for which result from including histologically unconfirmed cases and from the trend for more prompt diagnosis and early therapy.

CLINICAL FEATURES OF PACNS

The clinical features of the reported cases of PACNS are displayed in Table 2. The mean age for all patients was 45.1 years; 58% were male and 42% were female. The onset of the disease was variable: 40% of patients presented with fewer than 4 weeks of symptoms, and 40% presented with symptoms for more than 3 months.

As noted in previous reviews,^{1,77} headache is the most common symptom, found in 62% of cases. The headache may be mild or severe, and it is often accom-

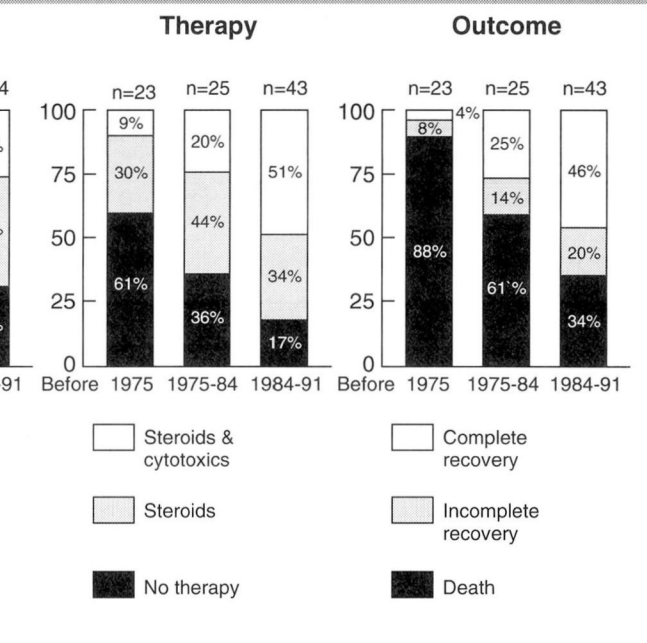


FIGURE 1. Trends in diagnosis, therapy, and outcome for 108 cases of PACNS.

panied by nausea or vomiting. The onset of the headache may be either acute or insidious. The course may be surprisingly fluctuating, with prolonged periods of apparent remission.

The presenting manifestation may be the insidious development of impaired higher cortical function, including intermittent confusion or dementia. Decreased levels of consciousness, ranging from mild drowsiness to coma, may punctuate the course. Acute stroke-like presentations have been increasingly described,^{3,4,12,17} particularly in young, previously healthy women; as discussed later, these may represent a distinctive subset of PACNS. Rarely, cerebral hemorrhage may mark the onset.

A variety of other neurologic defects have been reported in PACNS, including cranial neuropathies, cerebellar dysfunction, and cauda equina syndrome. On rare occasions vasculitis has been identified in non-CNS tissues, but these findings have been incidental and clinically insignificant.

A previous review emphasized the diagnostic significance of the presence of both focal and nonfocal (as opposed to purely focal or non-focal) neurologic dysfunction.¹ While this is still the most common presentation, it is found in only 52.8% of the patients.

Systemic symptoms such as fever, weight loss, arthralgia, and myalgia, which are characteristic of sys-

TABLE 3
DIAGNOSTIC PROCEDURES

	Cases diagnosed pathologically (N =83)	Cases diagnosed angiographically (N =25)
Biopsy performed	43	2
Diagnostic biopsy	32 (74.4%)	0
Nondiagnostic biopsy	11 (25.6%)	2
Cortex biopsy	38	2
Vasculitis	22/38 (57.9%)	0
Leptomeningeal biopsy	23	2
Vasculitis	20/23 (87.0%)	0
Angiography performed	44	25
Vasculitis	11 (25.0%)	25
Normal	17 (38.6%)	0
Mass	10 (22.7%)	0
Other	6 (13.6%)	0
CSF analysis performed	70	20
Positive findings	64 (90.3%)	12 (60%)
Normal	6 (9.7%)	8 (40%)
Mean cells/ μ L (95% CI)	73 (55-92)	30 (0-63)
Mean protein mg% (95% CI)	174 (116-232)	99 (19-178)

temic necrotizing vasculitis, are usually absent in PACNS.

DIAGNOSTIC STUDIES IN PACNS

The diagnosis of PACNS is hampered by the lack of reliable noninvasive tests. The mainstays of diagnosis are cerebral angiography and biopsy of CNS tissues, but the sensitivity, specificity, and predictive value of these diagnostic tests have not been thoroughly analyzed. A clear understanding of the usefulness of these tests is hampered by several factors. For example, the classic angiographic picture of arteritis, including vascular beading and alternating areas of stenosis and ectasia, is not specific for vasculitis: it can be seen in a variety of neoplastic, infectious, degenerative, and spastic vascular disorders.⁷⁸ Another obstacle to evaluating the usefulness of cerebral angiography has been the increasing use of the technique as a gold standard for diagnosis. Many recent cases have been reported without pathologic confirmation, making evaluation of diagnostic sensitivity difficult.

The pitfalls of relying solely on angiography for the diagnosis of PACNS can be appreciated from *Table 3*. In 38.6% of histologically confirmed cases of PACNS, cerebral angiography was entirely normal, and the classic picture of arteritis was seen in only 25% of cases. In addition, the classic picture of arteritis on cerebral arteriography is not highly specific for PACNS.⁷⁸ Thus, the value of using cerebral angiography alone in diag-

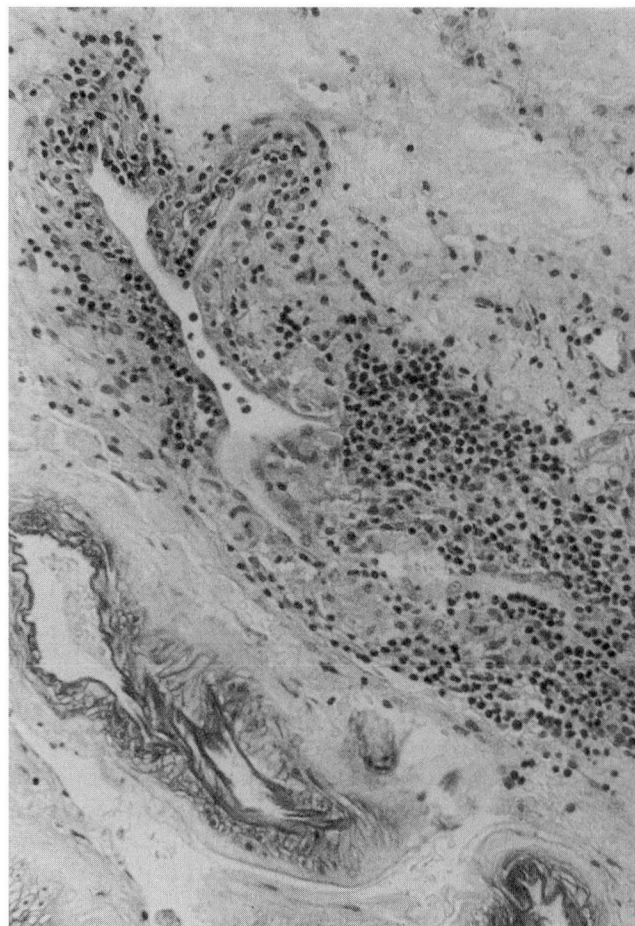


FIGURE 2. Section of leptomeninges showing focal, often eccentric, granulomatous vasculitis predominantly around veins (From Calabrese and Mallek⁷⁹).

nosing PACNS must be carefully examined.

Diagnostic biopsy of the CNS requires identification of characteristic histopathology in the sampled tissues. The pathology of PACNS is an inflammatory process centered around small veins and arterioles that is more prominent in the leptomeninges than in the underlying cortex (*Figure 2*).^{1,77,79} The infiltrate is usually granulomatous and may contain multinucleated giant cells, but, for unknown reasons, 15% of the cases showed nongranulomatous pathology. Since the damage may be focal, there is a significant risk of sampling error.

Biopsy of the CNS has been considered the gold standard for the diagnosis of cerebral arteritis, though its diagnostic sensitivity, specificity, or predictive value have not been analyzed. Its specificity is assumed to approach 100% (no false-positives), but even this as-

sumption must be made with caution since the histology is not specific, other vasculitic conditions may occasionally be encountered, and the technique is subject to significant sampling error. For these reasons, a biopsy demonstrating vasculitis must be interpreted cautiously and in the appropriate clinical context.

However, the diagnostic sensitivity of CNS biopsy can be assessed. Of the 43 premortem biopsies which were pathologically confirmed, 11 were false-negatives (PACNS was later confirmed at autopsy), thus yielding a diagnostic sensitivity of 74.4%. Technical factors can affect the sensitivity, since the diagnostic yield of leptomeningeal samples was 87% vs 57.9% for cerebral cortex samples. Recent recommendations^{1,44,75,79} stress that diagnostic biopsies for cerebral angiitis should always include both leptomeninges and underlying cortex, since examples have been encountered in which one revealed vasculitis and the other was normal.^{1,36,38,72}

Of the 11 nondiagnostic biopsies, 5 had abnormal findings, including pathologic impressions of lymphocytic meningitis, granulomatous meningitis, necrosis, and infarct. Four of the 11 patients with false-negative biopsies underwent cerebral arteriography; arteritis was found in only 1.

Given that (1) biopsy of the CNS yields false-negative results in one of four patients, (2) cerebral arteriography is entirely normal in nearly 40% of pathologically documented cases, and (3) both biopsy and cerebral arteriography may be nondiagnostic in the same patients, therefore reliance upon these tests either separately or combined must be critically assessed before a clinical approach can be recommended.

As described in previous reviews, examination of the CSF is highly sensitive for PACNS (90.3%) in pathologically documented cases (Table 3). In our experience, patients with a chronic progressive course are more likely to have CSF analysis resembling chronic meningitis than are those with abrupt, stroke-like presentations.

Ancillary tests that are traditionally used to diagnose vasculitis, (autoantibodies, rheumatoid factor, circulating immune complexes, acute phase reactants such as the C-reactive protein, and erythrocyte

TABLE 4
TREATMENT AND OUTCOME

	Complete recovery	Incomplete recovery	Death
All patients (N=97)			
No treatment (n=31)	2 (6.3%)	1 (3.1%)	28 (90.6%)
Steroids (n=35)	12 (34.3%)	4 (11.4%)	19 (54.3%)
Steroids and cytotoxics (n=31)	16 (51.6%)	11 (35.5%)	4 (12.9%)
Patients diagnosed before death (N=53)			
No treatment (n=3)	2 (66.7%)	1 (33.3%)	0
Steroids (n=20)	12 (60%)	4 (20%)	4 (20%)
Steroids and cytotoxics (n=30)	15 (50%)	11 (36.7%)	4 (13.3%)
Diagnosed pathologically (n=28)	15 (53.6%)	10 (35.7%)	3 (10.7%)
Diagnosed angiographically (n= 25)	14 (56%)	6 (24%)	5 (20%)

sedimentation rate) are not useful in the diagnosis of PACNS. Pathological or angiographical diagnosis of PACNS can be made without abnormalities showing in any of these studies.

While CT and MRI examinations are generally performed early in the evaluation of suspected PACNS, they rarely provide sufficient information to diagnose vasculitis. CT examinations were described in 65 patients and were found to be abnormal in 44 (67.7%), but the reported findings are highly disparate.¹ MRI examinations have been reported in only six patients and were found to be abnormal in five. In an abstract⁸⁰ reporting the results of MRI in nine patients with PACNS, the sensitivity was found to be 100%. Unfortunately, MRI did not appear to be valuable for following disease activity, since the abnormalities persisted for months after clinical remission of the disease. An additional study found no patterns specific for PACNS when MRI was analyzed as a tool to differentiate vasculitis from multiple sclerosis.⁸¹

THERAPY AND OUTCOME IN PACNS

PACNS has been traditionally viewed as a disease with a relentless, chronic, and fluctuating course. The use of corticosteroids and cytotoxic therapy seems to have radically altered the outcome of this otherwise fatal condition,^{1,44,76} but without controlled therapeutic trials, such conclusions must be made with caution. Previous analyses have failed to account for historical biases in diagnostic and therapeutic choices, and have included histologically unconfirmed cases in survival analysis.

Table 4 displays treatment and outcome of PACNS. When the cases are considered overall, survival appears to be enhanced in the subgroup which is treated most aggressively.^{1,76} However, this view does not ac-

count for the biases of changing diagnostic and therapeutic trends, since it includes a sizeable number of patients who were not diagnosed antemortem and who therefore experienced extremely protracted courses under a variety of empiric therapies.

When the patients who were diagnosed after death are excluded, the outcomes for the remaining 53 patients present a totally different picture. Among these patients, there were only 8 deaths; moreover, there is no difference in outcome in patients treated with corticosteroids alone vs those treated with a combination of corticosteroids and cytotoxic agents, nor in patients diagnosed angiographically vs those documented pathologically.

Since corticosteroid and combination therapies show no difference in outcome, it appears that there are clinical subsets of PACNS that may respond to less aggressive forms of therapy. However, without prospective trials of therapeutic modalities, therapeutic bias, whereby patients with benign disease are treated with unnecessarily aggressive therapy, cannot be assessed. We agree with Moore⁴⁴ that the outcome for patients with pathologically documented, chronic progressive disease is dramatically improved by combination therapy.

CLINICAL SUBSETS OF PACNS

Data in this review reflect the growing evidence that several clinical subsets of PACNS exist. Some subsets now have definite prognostic and therapeutic implications, while others (postpartum-, amyloid-, and HIV-associated) are so rare that it is difficult to draw valid conclusions about them; however, their uniqueness warrants nosologic distinction.

True PACNS

The diagnosis of true PACNS should be reserved for cases of angiitis confined to the CNS that closely resemble the original descriptions of granulomatous angiitis of the CNS.¹⁸ The diagnosis should be based on the presence of chronic (longer than 3 months) focal and diffuse neurologic dysfunction, and, where possible, on a positive biopsy of the CNS.

The pathology of this disorder is usually most prominent in the small unnamed arteries and veins of the leptomeninges and underlying cortex. In the vast majority of cases, CSF analysis resembles chronic meningitis, but there are no associated clinical conditions (Table 1) to account for the disorder.

Relying on a granulomatous pathology for the diag-

nosis is problematic, since biopsies are subject to sampling error and as many as 25% of biopsies are nondiagnostic. Even antemortem biopsy-proven cases of PACNS show marked heterogeneity in pathology. Of particular importance is nongranulomatous angiitis (12 of 82 cases in this series): within this subset are occasional cases of PACNS presenting with a mass lesion^{2,40} that were treated and cured by resection with minimal or no drug therapy. We have managed a similar case, and are unable to place this clinical picture within the established spectrum of PACNS.

The outcome of true PACNS is poor if it is untreated or treated with steroids alone. We believe the condition warrants a combination of corticosteroid and cytotoxic drug therapy.

Benign angiopathy of the CNS

Some of the cases that conform to the preliminary diagnostic criteria appear to represent a more benign form of disease than true PACNS.^{3,4,12,17,41,67} These cases have acute onset, normal CSF analyses, primary diagnosis by angiography, and benign clinical courses. The patients usually respond to corticosteroid therapy alone; at times resolution comes with no therapy at all. In addition, some angiographically documented cases of PACNS are not clinically equivalent to pathologically confirmed cases,⁸² and they share many features with these benign cases.

Bettoni et al³ reported a case that they referred to as "isolated benign cerebral vasculitis;" they felt that this syndrome is characterized by benign evolution, sensitivity to cortisone, normal CSF, and consistent angiographic pattern of arteritis. We agree with these impressions, but, unfortunately for diagnostic efforts, benign evolution and sensitivity to cortisone can only be appreciated in retrospect. The majority of these cases involve young women who present with acute onset headache or a focal neurologic defect associated with a benign CSF analysis and the angiographic picture of classical vasculitis. We believe these patients have a good prognosis and should be treated with brief courses of corticosteroids with possibly the additional use of calcium-channel blockers.

For this condition, we prefer the term "benign angiopathy" of the CNS, since it is unclear whether these cases represent true arteritis or vasospasm (as others have suggested⁸³).

Reversible vasoconstriction can be observed following subarachnoid hemorrhage,⁸⁴ sympathomimetic drug intoxication⁸⁵ (including over-the-counter drugs such as phenylpropanolamine⁸⁶), surgical manipulation,⁸⁷

and other head injury,⁸⁸ but since the arteritic changes seen on cerebral angiography in other forms of vasculitis also may be associated with true PACNS, this finding alone does not ensure benignity. True PACNS may be distinguished clinically from BACNS by other features, including a chronic progressive course and abnormal CSF analysis (both increased cell count and protein). The following case report from our previous review of PACNS¹ is illustrative of BACNS.

BACNS, Case 1. In August 1984, a healthy 10-year-old girl stumbled and tripped when getting out of the car. When spoken to, she was suddenly unable to answer. On arrival at a local emergency room, she was found to have right-sided hemiplegia as well as some mental confusion and aphasia. Over the next 24 hours she experienced recurrent episodes of hemiplegia and aphasia lasting between 5 and 30 minutes. By the next morning she had improved but had residual right-sided weakness and was felt to be about 50% recovered. By the third morning she had gained 95% of her original strength. An evaluation at her local hospital revealed no other evidence of systemic disease and, because of the continued resolution of her symptoms, it was elected to observe her on an outpatient basis.

Three weeks later she was evaluated at the Cleveland Clinic. A CT scan revealed hypodensity in the area of the left internal capsule that was interpreted as edema. A lumbar puncture was essentially normal. Extensive laboratory testing included assays for C-reactive protein, rheumatoid factor, antinuclear antibody and complement; all were negative. A temporal artery biopsy revealed no pathologic change. Cerebral arteriography showed multiple discrete areas of vessel beading involving the small branches of both middle cerebral arteries. When discharged, she had completely recovered; because of her health and youth she was not subjected to confirmatory leptomeningeal biopsy. She was given no treatment and was followed for the next several years without recurrence of her illness.

Comment. This case meets the 1987 preliminary criteria for the diagnosis of PACNS on angiographic grounds.¹ However, the case is characteristic of BACNS: the patient was a young, healthy female who had no prior neurologic symptoms; she had acute-onset focal neurologic defects, normal CSF, and a characteristic vasculitic-appearing angiogram. She completely recovered from her illness without therapy: this testifies to the benign nature of the disease.

We have seen numerous other cases fitting the picture of BACNS and have elected to treat them with

successively less intense regimens of therapy. The following case illustrates several other features of BACNS:

BACNS, Case 2. The patient was a 52-year-old woman who began to experience severe headaches associated with sexual intercourse. The headaches were described as "worse than anything she had experienced in her life." They were generalized, maximal in the vertex and occipital regions, and described as building slowly and then intensifying with climax. She also noted headaches associated with straining at bowel movements. She had no associated visceral or neurologic signs or symptoms. The headaches persisted and intensified over several months, and she ultimately sought neurologic consultation in June 1990. She was admitted to a hospital and given a detailed medical and neurologic evaluation. A lumbar puncture revealed six lymphocytes and seven red cells. Protein and glucose were normal. Extensive laboratory testing—including CSF cytology; bacterial, fungal, and acid fast cultures; and CSF cryptococcal and VDRL antigen—produced negative findings. The patient underwent four-vessel cerebral arteriography which revealed areas of segmental narrowing and sausageing in multiple proximal intracranial vessels in several vascular territories. The angiograms were reviewed by the attending neurologist and three neuroradiologists; all suspected a vasculitic process. The patient was put on verapamil 80 mg three times a day and claimed complete resolution of her symptoms.

Because of the profound abnormalities on her cerebral arteriogram, she was referred to the Cleveland Clinic in July 1990. Physical and neurologic examinations were totally normal. She claimed to have no more symptoms with intercourse or bowel movements and was feeling quite well. Additional laboratory tests included a lipid profile, anticardiolipin antibodies, acute phase reactants and a hypercoagulability screen, all of which revealed no significant abnormalities. Because she had experienced severe headache during her previous cerebral arteriogram, it was elected to maintain her on verapamil and continue to observe her. She has had no more headaches.

Comment. The patient's symptoms resembled exertional headaches; factors in her history, including motion sickness and having a daughter with migraine headaches, suggested a migraine-like syndrome. However, while focal areas of vascular spasm have been reported in the presence of headache,⁸⁹ the diffuse and profound nature of her arteriographic abnormalities were disturbing. This case would be classified as

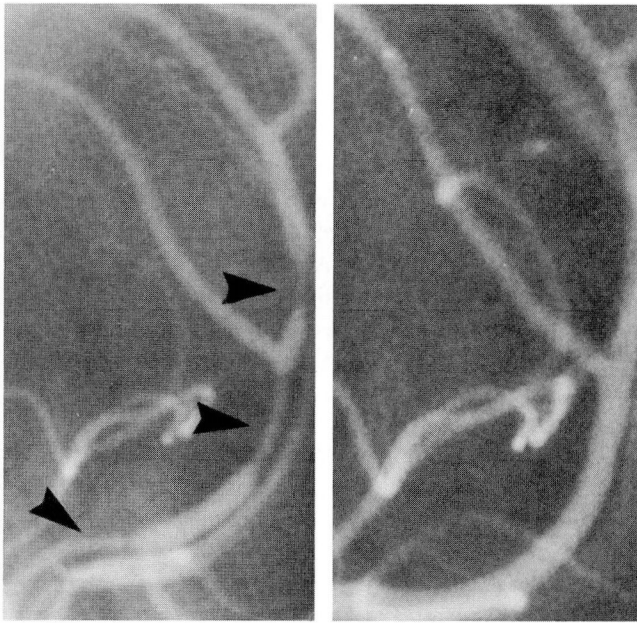


FIGURE 3. Cerebral angiograms from a patient with postpartum angiopathy. A. Before treatment, showing segmental narrowing and sausaging (arrowheads). B. Six months later, following corticosteroid and cyclophosphamide therapy.

PACNS under the 1987 proposed diagnostic criteria, but at present it appears to fit into the subgroup of BACNS. The patient's response to calcium-channel blockers has increased our enthusiasm for the use of this class of drugs in other cases of BACNS.

BACNS has recently been described as "reversible cerebral segmental vasoconstriction" by Call et al,⁹⁰ who argue that the etiology of BACNS is reversible vasospasm. They based this conclusion on the serial angiographic study of four patients with clinical features identical to those outlined for BACNS, and emphasize the salient features of the syndrome, including the sudden onset of a high intensity headache associated with nausea, vomiting and occasionally photophobia. Most cases displayed an associated motor or sensory deficit. Call et al further describe 19 similar cases in the literature, including several in this series of BACNS. Most of these patients recovered completely within 30 days. However, even in their index cases, each patient was subjected to several therapeutic regimens including high-dose corticosteroids, and one case was treated with corticosteroids and cyclophosphamide as well. As the syndrome of BACNS becomes more clearly defined, more standard forms of therapy can be designed.

Postpartum cerebral angiopathy

An unusual and distinctive syndrome occurring immediately after childbirth has been described under various headings including postpartum cerebral angiopathy,⁸ isolated angiitis of the brain in pregnancy and puerperium,²² and PACNS.¹ This series includes four cases (two from the Cleveland Clinic).¹ Eight more cases have been reported in the French literature.⁹¹⁻⁹⁴ Four of these were associated with subarachnoid hemorrhage or vasoconstrictive drugs, both of which can induce vasospastic changes on angiography, and will not be considered here. The remaining cases were all clinically similar, and were unassociated with significant hypertension or toxemia. They have common clinical features: normal pregnancy followed by a neurologic illness characterized by severe headaches, nausea, or vomiting, and various other neurologic defects including hemiparesis or seizures. Cerebral angiography showed alternating areas of stenosis and ectasia or frank "sausaging" of multiple vessels (Figure 3). In some cases the CSF showed a modest pleocytosis or significantly elevated protein, as opposed to the normal findings seen in BACNS.

The basic vascular pathology of this disease is unknown, but several researchers considered it a form of isolated arteritis.^{1,22} Others argued that it is a reversible form of vasospasm.⁸ We believe that initially the lesion is vasospastic in nature. Bogousslavsky et al⁸ described a 22-year-old woman with postpartum angiopathy which was associated with multiple segmental narrowing of the cerebral arteries. She was not treated but was followed by sequential transcranial Doppler ultrasound examinations which demonstrated gradual, sustained improvement 4 days after onset and normalization by 4 weeks. This case strongly supports a vasospastic etiology for the condition.

As in other intracranial arteriopathies that have strong evidence for both vasospasm and arteritis, there may be a continuum of vascular pathology starting with a spastic lesion and ending with arteritis. Angiopathy characterized by reversible vasospasm has been associated with pheochromocytoma with intermittent severe hypertension,⁹⁵ experimental hypertension,⁹⁶ and with a variety of drugs, including ergots and phenylpropanolamine.^{86,97}

By contrast, it is well documented that if vascular lesions persist, particularly those induced by increased hemodynamic forces, a frank vasculitic lesion can develop. Examples can be seen in the kidneys of patients with malignant hypertension,⁹⁸ in the mesenteric vessels of patients who develop mesenteric

ischemia following correction of coarctation of the aorta,⁹⁹ and in the cerebral circulation following embolectomy.⁸⁷ Vascular structures may be able to respond to noxious stimuli, including hypertension, to only a limited extent. In patients who have developed CNS vasculitis from a variety of sympathomimetic drugs, only rarely do biopsies of the CNS reveal vasculitic lesions.¹⁰⁰ In animal models of arteriopathy caused by exposure to sympathomimetic drugs, the induction of hypertension results in only the arteriographic picture of cerebral arteritis, not in necrotizing vasculitis.^{101,102}

Several cases of postpartum CNS angiopathy responded to prednisone with or without cytotoxic drugs, but this does not support either spasm or arteritis in the etiology of this syndrome, since corticosteroids are effective for benign vascular headaches.

We currently advocate a short course of high-dose corticosteroids together with a calcium-channel blocker for patients with postpartum CNS angiopathy without hypertension or toxemia.

Cerebral amyloid angiopathy with granulomatous angiitis of the CNS

Among the 108 cases reviewed are 5 cases of vasculitis confined to the CNS with granulomatous features associated with amyloid angiopathy.^{25,45,51,54} Amyloid angiopathy is characterized by amyloid deposition in brain vessels. It is frequently associated with Alzheimer's disease and subacute dementia of the Alzheimer's type, and is sometimes found in normal aged individuals.¹⁰³ Usually, the lesion is noninflammatory and leads to vascular obliteration, but occasionally vascular inflammation can be seen.¹⁰³

These five cases were remarkably similar. Most involved an elderly individual with rapidly progressive neurologic disease which ultimately culminated in death. In one case, the diagnosis was made antemortem, and corticosteroid therapy led to striking clinical improvement.²⁵ The CT examination revealed more diffuse defects than in PACNS, and was described as a generalized hypodensity and edema of the white matter. Pathological study showed that the meningeal and superficial cortical vessels were mostly affected with a granulomatous angiitis, replete with multinucleated giant cells which were observed in and around vessels that were infiltrated by amyloid.

The pathogenesis of this disease is unknown. Since both cerebral amyloid angiopathy and granulomatous angiitis of the CNS have a predilection for the leptomeningeal and superficial cortical vessels, this

strongly suggests that the changes are related. The chronic inflammation of vasculitis may have led to the deposition of amyloid. On the other hand, amyloid-containing vessels may develop vasculitis, since primary amyloidosis in other parts of the body may be accompanied by a granulomatous process.

PACNS ASSOCIATED WITH IMMUNOSUPPRESSIVE ILLNESS

In 13 of the 108 cases, PACNS was associated with disorders which involve immunosuppression.^{1,9,19,26,28,37,55,57-59,73-75} These conditions included leukemias, lymphomas, myeloproliferative disorders, immunosuppressive therapy associated with inflammatory bowel disease and the post renal transplant state, and human immunodeficiency virus (HIV) infection. PACNS associated with lymphoproliferative diseases has been noted previously.¹

These cases have each been considered separate entities because the pathogenic significance of the concurrent condition is unknown. The patients did not have evidence of direct vascular invasion by tumor, nor did the lymphomas necessarily involve the CNS. The immunosuppressed state may lead to activation of some vasculocentric infection, such as a virus, leading to an inflammatory response. The entity of CNS vasculitis associated with herpes zoster ophthalmicus is believed to be caused by the retrograde spread of varicella zoster infection from cranial nerves to the intracranial vascular structures via the Gasserian ganglion.⁷⁷ PACNS has also been reported in association with herpes zoster infection not involving the trigeminal nerve, further supporting the association of PACNS with a decreased state of immunosurveillance.⁵⁷ There are no detailed pathophysiologic studies of PACNS associated with immunosuppressive illness at this time.

The two cases of HIV infection associated with PACNS deserve particular mention. Yanker et al⁷⁴ described a classical case of granulomatous angiitis of the CNS proven by biopsy. The patient was serologically nonreactive to HIV by enzyme-linked immunosorbent assay (ELISA) and Western blot techniques, but HIV was cultured from the CSF. Vinters et al⁷³ reported a case of nongranulomatous angiitis limited to the CNS. HIV infection has also been reported in association with angiocentric immunoproliferative lesions, which are intracranial vasculitic processes that are clinically and pathologically distinct from PACNS.¹⁰⁴ These conditions are among the few forms of vasculitis that are anatomically confined to the CNS and yet differ radically from PACNS. They appear to represent

TABLE 5
ADDITIONAL CONDITIONS RESEMBLING PACNS

Drug-associated vasculopathy (especially phenylpropylamine and cocaine) ^{85,86,106}
Demyelinating disease ⁸²
Neurofibromatosis ¹⁰⁷
HIV infection ¹⁰⁸
Lyme disease ¹⁰⁹
Syphilis ¹¹⁰
Angiocentric immunoproliferative lesions ¹⁰⁵
Eale's disease ¹¹¹
Cogan's syndrome ¹¹²
Carcinomatous meningitis ¹¹³
Acute febrile cerebrovasculitis ¹¹⁴
Acute posterior multifocal placoid pigment epitheliopathy and cerebral vasculitis ¹¹⁵
Antiphospholipid antibody syndrome ¹¹⁶

a spectrum of lymphocytic vasculitic conditions ranging from benign inflammatory disease to frank angiocentric lymphomas.¹⁰⁵

PACNS associated with immunosuppressive illness is pathophysiologically, diagnostically, and therapeutically distinctive. In addition to our published experience with this disease, we have seen a patient, who, following renal transplantation, was diagnosed angiographically with isolated CNS angiitis. This patient improved clinically after withdrawal of antirejection immunosuppressive therapy; suggesting that immunosuppression may be a causal factor in at least some of these cases.

CONDITIONS THAT MIMIC PACNS

Many patients have been referred to us specifically for the diagnosis or management of PACNS. Most of these patients appear to have one of a variety of conditions that may closely resemble PACNS. These include the conditions listed under the preliminary diagnostic criteria and a number of additional conditions (Table 5). These additional conditions range in incidence from extremely common to rare, and all of them should be considered in the diagnosis and treatment of PACNS.

The patient's presentation will suggest different avenues of investigation. Acute focal presentations warrant a search for hypercoagulable states, including anticardiolipin antibodies, and they call for a meticulous social history for drug use, including over-the-counter agents containing phenylpropanolamine and caffeine. Chronic progressive disease, resembling chronic meningitis, warrants a search for a variety of infectious diseases including mycobacterial, fungal,

and HIV illness. An appropriate epidemiologic history may increase suspicion for Lyme infection. Dementia as a presenting sign may warrant a search for Creutzfeldt-Jakob disease, while ocular signs or symptoms may raise the possibility of Cogan's or Eales's disease. Changing focal neurologic signs or symptoms without impaired cortical function suggests the possibility of demyelinating disease.

REVISED CRITERIA

In view of the heterogeneity of the cases which meet the preliminary diagnostic criteria for PACNS and the important clinical differences among them, we propose a revised system of classification (Table 6). The new criteria recognize the differences between true PACNS and BACNS and attempt to take into account the limitations of performing multiple invasive diagnostic tests (ie, angiography and brain biopsy) on a single patient.

True PACNS and BACNS constitute the majority of cases (87 of 108) which conformed to the preliminary criteria, and they have the greatest clinical significance for prognosis, diagnostic strategy, and therapy. For these reasons, criteria requiring either angiography or biopsy are proposed for these conditions. A provision for a probable diagnosis for true PACNS is included, since in the absence of pathologic confirmation the diagnosis cannot be totally secure. Some cases may fall between the criteria: for example, a patient with an acute focal neurologic event who has an abnormal angiogram may also have a highly abnormal CSF. In our experience, these cases are relatively rare, and most cases fall clearly into one category or another.

Cases of isolated CNS angiitis associated with the postpartum state, amyloid angiopathy, or immunosuppression (especially HIV) are too rare to draw strong conclusions, but we believe that these cases deserve nosologic distinction until more clinical experience is gathered.

DIAGNOSTIC APPROACH

Since no clinical picture is specific for PACNS, a high degree of clinical suspicion is needed to make the diagnosis. PACNS has been diagnosed more frequently in recent years; we believe this is due both to increased awareness and a more vigorous diagnostic approach.

The diagnosis should be suspected when headache, focal or multifocal neurologic deficits, decreased higher cortical function (including dementia, altered

sensorium, or a decreased level of consciousness), myelopathy, cranial neuropathy, or chronic meningitis remain unexplained after a thorough basic workup.

In cases of true PACNS, the clinical course may be progressive, although it is sometimes punctuated by periods of seeming spontaneous improvement,⁴⁴ whereas in BACNS, a history of good health usually precedes an acute neurologic event. The presence of both multifocal and diffuse neurologic dysfunction greatly raises the diagnostic probability of PACNS. Usually, significant constitutional symptoms are absent in both PACNS and BACNS.

The diagnostic process should be tailored to the presentation but should always include a thorough history and physical examination. Family members should be interviewed for independent assessment of social and drug histories and prepresentation behavior because of the possibility of altered cognitive function in the patient. Basic radiologic and laboratory evaluations are essential; these include serologic tests for autoimmune and connective tissue disease, hypercoagulability profile including anticardiolipin antibody, and lipid profile. An echocardiogram may be useful to rule out occult valvular disease and cardiac myxoma. Microbiologic tests, including serologic assays for HIV, Lyme disease, syphilis, and fungal infections, as well as blood cultures for bacteria, fungi, and mycobacteria, are particularly important when the clinical picture resembles chronic meningitis.

An MRI or CT examination is essential to search for mass lesions and findings suggestive of demyelinating disease or other conditions. A totally normal MRI has a strong negative predictive value, but has nevertheless been reported in the presence of biopsy-proven PACNS.⁷² The EEG is rarely helpful for diagnosing PACNS but may be useful for diagnosing other conditions such as Creutzfeldt-Jakob disease.

Examination of the CSF should include cytology; analysis of protein; cell count; cultures for bacteria, fungi and mycobacteria; and serologic tests for cryptococcal antigen and VDRL. Tests for immunoglobulin G synthesis or oligoclonal bands are useful for evaluating demyelinating disease, but these abnormalities are not specific; they have occasionally been reported in PACNS and should be expected in cases of PACNS associated with HIV infection. CSF analysis is valuable for diagnosing other mimicking conditions and for separating true PACNS from BACNS.

After the evaluation, a critical decision must be made to proceed with either biopsy or angiography. We favor cerebral angiography with film magnification

TABLE 6
DIAGNOSTIC CRITERIA FOR PACNS

True PACNS

Definite disease: leptomeningeal, cerebral cortex, or spinal cord biopsy demonstrating primary angiitis (with or without granulomatous features)

and

exclusion of the conditions listed in *Tables 1* and *5*.

Possible disease: cerebral angiogram demonstrating the classical findings of arteritis, including segmental narrowing, ectasia, or beading

and

headaches or multifocal neurologic dysfunction present for more than 3 months

and

CSF analysis demonstrating elevated cell and protein levels

and

exclusion of the conditions listed in *Tables 1* and *5*.

BACNS

Cerebral angiogram demonstrating the classical findings of arteritis, including segmental narrowing, ectasia, or beading

and

acute presentation of a focal or multifocal neurologic deficit

and

relatively normal CSF cell and protein levels

and

exclusion of the conditions in *Tables 1* and *5*.

Varieties of uncertain pathogenesis

Postpartum cerebral angiopathy

Cerebral amyloid angiopathy

Granulomatous angiitis of the CNS

CNS angiitis associated with immunosuppressive illness

when true PACNS or BACNS is suspected on clinical grounds. In the former case, a classic angiogram warrants a diagnosis of probable PACNS and is an adequate basis for therapy if all mimicking conditions have been ruled out. In the latter case, a classic angiogram is ample evidence for definitive diagnosis of BACNS (with the appropriate exclusions) and therapy can then be started.

Biopsy of the CNS is required in most cases of suspected true PACNS, since angiography confirms the diagnosis in fewer than one third of cases. Biopsy is also required in any case with evidence of a mass lesion. Biopsy of suspected BACNS is only necessary if the patient fails to respond to initial therapy (see below). The site and type of biopsy is important, and in the presence of a mass documented by CT or MRI, we favor a stereotactic biopsy of the lesion together with biopsy of the leptomeninges. More frequently, in the absence of a mass lesion, we favor sampling the tip of the temporal lobe in the nondominant hemisphere, including leptomeninges and underlying cortex.⁴⁴ Biopsy tissue should be stained for infectious agents as well as for routine histologic examination and sent for

appropriate cultures. When appropriately done, brain biopsy has less than 2% morbidity.¹¹⁷

THERAPEUTIC APPROACH

No controlled studies of therapy for either true PACNS or BACNS have been reported to date. For BACNS, we favor initiating high-dose corticosteroid therapy (60 to 80 mg/day), combined with a calcium-channel blocker. We believe that this therapy can be rapidly tapered over several weeks, based on clinical symptomatology. If the patient makes a good clinical response, all therapy may be discontinued after several weeks or a few months. If the patient does not respond and headaches persist or increase, or more focal events are noted, then we favor biopsy to confirm true vasculitis or to rule out other mimicking conditions. This should be followed by initiation of combined therapy with high-dose corticosteroids and oral cyclophosphamide (1 to 2 mg/kg/d). The treatment should be continued for 6 to 12 months after all signs of disease

have disappeared. Follow-up angiography may be useful in these patients.¹

In pathologically diagnosed true PACNS in the presence of chronic and progressive disease, we favor initiation of therapy with corticosteroids and cyclophosphamide from the outset. As with BACNS, therapy may need to be continued for 6 to 12 months or longer following complete clinical remission. The exact length of therapy required to suppress this disease, or whether the disease can be cured on a long-term basis, is unknown. It may be useful to monitor CSF abnormalities, but serial angiography may be less useful in this condition since clinical relapses have occurred in the face of normal cerebral arteriograms.⁴⁴ The toxicities of long-term cyclophosphamide use have been discussed in detail elsewhere.¹¹⁸

ACKNOWLEDGMENT

We are grateful for the careful review and comments on this manuscript by Constance S. White, MD.

REFERENCES

- Calabrese LH, Mallek JA. Primary angiitis of the central nervous system: report of eight new cases, review of the literature and proposal for diagnostic criteria. *Medicine* 1988; 67:20-39.
- Cupps TR, Moore PM, Fauci AS. Isolated angiitis of the central nervous system. *Am J Med* 1983; 74:97-106.
- Bettoni L, Bortjuvarra G, Lechi A. Isolated benign cerebral vasculitis. *Acta Neurol Belg* 1984; 84:161-173.
- Snyder BD, McClelland RR. Isolated benign cerebral vasculitis. *Arch Neurol* 1978; 35:612-614.
- Arthur G, Margolis G. Mycoplasma-like structures in granulomatous angiitis of the central nervous system. *Arch Pathol Lab Med* 1977; 101:382-387.
- Beresford HR, Hyman RA, Sharer L. Self-limited granulomatous angiitis of the cerebellum. *Ann Neurol* 1979; 5:490-492.
- Beller J, Loftus CM, Moore SA, et al. Isolated central nervous angiitis first presenting as spontaneous intracranial hemorrhage. *Neurology* 1987; 20:310-315.
- Bogousslavsky J, Despland PA, Regli F, Dubuis PY. Postpartum cerebral angiopathy: reversible vasoconstriction assessed by transcranial doppler ultrasounds. *Eur Neurol* 1989; 29:102-105.
- Borenstein D, Costa M, Jannotta F, Rizzoli F. Localized isolated angiitis of the central nervous system associated with primary intracerebral lymphoma. *Cancer* 1988; 62:375-380.
- Budzilovich GN, Deigin I, Siegel H. Granulomatous angiitis of the nervous system. *Arch Pathol Lab Med* 1963; 76:250-256.
- Burger PC, Burch JG, Vogel FS. Granulomatous angiitis: an unusual etiology of stroke. *Stroke* 1977; 8:29-35.
- Calenbergh FV, Van Den Berg V, Wilms G. Benign isolated arteritis of the central nervous system. *Clin Neurol Neurosurg* 1986; 88:267-273.
- Castleman B, McNeely BV. Case records of the Massachusetts General Hospital. Case 41152. *N Engl J Med* 1955; 252:634-641.
- Castleman B, McNeely BV. Case records of the Massachusetts General Hospital. Case 14-1967. *N Engl J Med* 1967; 276:744-750.
- Clifford-Jones RE, Love S, Gurusinghe N. Granulomatous angiitis of the central nervous system: a case with recurrent cerebral hemorrhage. *J Neurol Neurosurg Psychiatry* 1985; 48:1054-1056.
- Clinical Pathologic Conference. Chronic meningitis in a 68 year old man. *Am J Med* 1985; 85:407-413.
- Craven RS, French JK. Isolated angiitis of the central nervous system. *Ann Neurol* 1985; 18:263-265.
- Cravioto M, Feigin I. Noninfectious granulomatous angiitis with a predilection for the nervous system. *Neurology* 1959; 9:599-609.
- De Reuck J, Crevitus L, Sieben G, DeCoster W, VanderEeken H. Granulomatous angiitis of the nervous system: a CPC of one case. *J Neurol* 1982; 277:49-53.
- Enzmann D, Scott WR. Intracranial involvement of giant-cell arteritis. *Neurology* 1977; 27:794-797.
- Faer MJ, Mead JH, Lynch RD. Cerebral granulomatous angiitis: case report and literature review. *Am J Roentgenol* 1977; 125:463-467.
- Farine D, Andreyko J, Lysikiewicz A, Simha S, Addison A. Isolated angiitis of brain in pregnancy and puerperium. *Obstet Gynecol* 1979; 63:586-588.
- Feasby TE, Ferguson GG, Kaufman JCE. Isolated spinal cord arteritis. *Can J Neurol Sci* 1975; 2:143-146.
- Frayne JH, Gilligan BS, Esser WB. Granulomatous angiitis of the central nervous system. *Med J Aust* 1985; 145:410-412.
- Ginsberg L, Geddes J, Valentine A. Amyloid angiography and granulomatous angiitis of the central nervous system: a case responding to corticosteroid therapy. *J Neurol* 1988; 235:438-440.
- Greco FA, Kolins J, Rajjoub RK, Brereton HD. Hodgkins disease and granulomatous angiitis of the central nervous system. *Cancer* 1976; 38:2027-2032.
- Griffin J, Price DL, David L, McKhann GM. Granulomatous angiitis of the central nervous system with aneurysms on multiple cerebral arteries. *Trans Am Neurol Assoc* 1973; 98:145-148.
- Groothuis DR, Mikhael MA. Focal cerebral vasculitis associated with circulating immune complexes and brain irradiation. *Ann Neurol* 1986; 19:590-592.
- Harrison PE Jr. Granulomatous angiitis of the central nervous system: case report and review. *J Neurol Sci* 1976; 29:335-341.
- Hinck VC, Carter CC, Rippey JG. Giant cell (cranial) arteritis. A case with angiographic abnormalities. *Am J Roentgenol Radium Ther Nucl Med* 1964; 92:769-775.
- Hirsch M, Mayersdorf A, Lehmann E. Cranial giant cell arteritis. *Br J Radiol* 1974; 47:503-506.

32. Hughes JT, Brownell B. Granulomatous giant-celled angitis of the central nervous system. *Neurology* 1966; **16**:293-298.
33. Ibrahim WN, Paroski MW. Communicating hydrocephalus as a complication of isolated CNS angitis: a case report. *Angiology* 1987; **38**:635-641.
34. Jellinger K. Giant cell granulomatous angitis of the central nervous system. *J Neurol* 1977; **215**:175-190.
35. Judice DJ, LeBlanc HJ, McGarry PA. Spinal cord vasculitis presenting as a spinal cord tumor in a heroin addict. *J Neurosurg* 1978; **48**:131-134.
36. Kattach J, Cupp TR, DiChiro G, Manz HJ. An unusual case of central nervous system vasculitis. *J Neurol* 1987; **234**:344-347.
37. Kolodny EH, Rebeiz JJ, Caviness VS Jr, Richardson EP. Granulomatous angitis of the central nervous system. *Arch Neurol* 1968; **19**:510-524.
38. Koo EH, Massey EW. Granulomatous angitis of the central nervous system: protean manifestations and response to treatment. *J Neurol Neurosurg Psychiatry* 1988; **51**:1126-1133.
39. Koo EH, Massey EW. Therapy for granulomatous angitis. *Clin Neuropharmacol* 1986; **9**:132-137.
40. Kristoferitsch W, Jellinger K, Bock F. Cerebral granulomatous angitis with atypical features. *Neurology* 1984; **231**:38-40.
41. Launes J, Livanainen M, Erkinjuntti, Vuoriaho M. Isolated angitis of the central nervous system. *Acta Neurol Scand* 1986; **74**:108-114.
42. Marsden HB. Basilar artery thrombosis and giant cell arteritis. *Arch Dis Child* 1974; **49**:75.
43. McCormick HM, Neuburger KT. Giant cell arteritis involving small meningeal and intracerebral vessels. *J Neuropathol Exp Neurol* 1958; **17**:471-478.
44. Moore P. Diagnosis and management of isolated angitis of the central nervous system. *Neurology* 1989; **39**:167-173.
45. Murphy MN, Sima AF. Cerebral amyloid angiography associated with giant cell arteritis. *Stroke* 1985; **16**:514-517.
46. Nagaratnam N, James WE. Isolated angitis of the brain in a young female on the contraceptive pill. *Postgrad Med J* 1987; **63**:1085-1086.
47. Nelson J, Barron N, Riggs J, Gutmann L, Schochet SS. Cerebral vasculitis and ulcerative colitis. *Neurology* 1986; **36**:719-721.
48. Newman W, Wolf A. Noninfectious angitis involving the central nervous system. *Trans Am Neurol Assoc* 1952; **77**:114-117.
49. Nurick S, Blackwood W, Mair WGP. Giant cell granulomatous angitis of the central nervous system. *Brain* 1972; **95**:133-142.
50. Pezeshkpour G. Crystalline encephalopathy: cerebral immunoprotein deposits and isolated angitis. *Ann Neurol* 1985; **17**:96-99.
51. Probst A, Ulrich J. Amyloid angiopathy combined with granulomatous angitis of the central nervous system: report on two cases. *Clin Neuropathol* 1985; **4**:250-259.
52. Rawlinson DG, Braun C. Granulomatous angitis of the nervous system first seen as relapsing myelopathy. *Arch Neurol* 1981; **38**:129-131.
53. Reik L. Granulomatous angitis presenting as chronic meningitis and ventriculitis. *Neurology* 1983; **33**:1609-1612.
54. Reid AH, Maloney AF. Giant cell arteritis and arteriolitis with amyloid angiopathy in an elderly mongol. *Acta Neuropathol* 1974; **27**:131-137.
55. Rewcastle NB, Tom MI. Non-infectious granulomatous angitis of the nervous system associated with Hodgkin's disease. *J Neurol Neurosurg Psychiatry* 1962; **25**:51-58.
56. Reyes MG, Fresco R, Chokroverty S, Salud EQ. Virus-like particles in granulomatous angitis of the central nervous system. *Neurology* 1976; **26**:797-799.
57. Rosenblum WI, Hadfield MG, Young HF. Granulomatous angitis with preceding varicella-zoster. *Ann Neurol* 1978; **3**:374-375.
58. Rosenblum WI, Hadfield MG. Granulomatous angitis of the central nervous system in cases of herpes zoster and lymphosarcoma. *Neurology* 1972; **22**:348-354.
59. Rothenburg R. Isolated angitis of the brain. *Am J Med* 1985; **79**:629-632.
60. Rush PJ, Inman R, Bernstein Carlen P, Resch L. Isolated vasculitis of the central nervous system in a patient with coeliac disease. *Am J Med* 1986; **81**:1092-1094.
61. Russi E, Aebi M, Kraus-Ruppert R, Mumenthaler M. Intracranial giant cell arteritis. *J Neurol* 1979; **221**:219-224.
62. Sabharwal VK, Keogh LH, Weisman MH, Zvaifler NJ. Granulomatous angitis of the nervous system: case report and review of the literature. *Arthritis Rheum* 1982; **25**:342-345.
63. Sandhu R, Alexander S, Hornabrook RW, Stehbens WE. Granulomatous angitis of the CNS. *Arch Neurol* 1979; **36**:433-435.
64. Scully RE, ed. Case records of the Massachusetts General Hospital (Case 35-1985). *N Engl J Med* 1985; **313**:566-574.
65. Scully RE, ed. Case records of the Massachusetts General Hospital (Case 8-1989). *N Engl J Med* 1989; **320**:514-529.
66. Scully RE, Galdabini JJ, McNeely BU. CPC 43-1976. *N Engl J Med* 1976; **295**:944-950.
67. Seradaru M, Chiras J, Cujas M, Lhermitte F. Isolated benign cerebral vasculitis or migranous vasospasm? *J Neurol Neurosurg Psychiatry* 1984; **47**:73-76.
68. Shintaku M, Osawa K, Toki J, Maeda R, Nishiyama T. A case of granulomatous angitis of the central nervous system associated with amyloid angiopathy. *Acta Neuropathol* 1986; **70**:340-342.
69. Shuangshoti S. Localized granulomatous (giant cell) angitis of brain with eosinophil infiltration and sacular aneurysm. *J Med Assoc Thai* 1974; **62**:281-288.
70. Stewart SS, Ashizawa T, Dudley AW, Goldberg J, Lindsay M. Cerebral vasculitis in relapsing polychondritis. *Neurology* 1988; **38**:150-152.
71. Valvanis A, Friede R, Schubiger O, Hayek J. Cerebral granulomatous angitis stimulating brain tumor. *J Comput Assist Tomogr* 1979; **3**:536-538.
72. Vanderzant C, Bomberg M, MacGuire A, McCune J. Isolated small-vessel angitis of the central nervous system. *Arch Neurol* 1988; **45**:683-687.
73. Vinters HV, Guerra WF, Eppolito L, Keith PE. Necrotizing vasculitis of the nervous system in a patient with AIDS-related complex. *Neuropathol Appl Neurobiol* 1988; **14**:417-424.
74. Yanker BA, Skolnik PR, Shoukimas GM, Gabuzda DH, Sobel RA, Ho DA. Cerebral granulomatous angitis associated with isolation of human T-lymphotrophic virus type III from the central nervous system. *Ann Neurol* 1986; **20**:362-364.
75. Younger DS, Hays AP, Brust JCM, Rowland LP. Granulomatous angitis of the brain. An inflammatory reaction of diverse etiology. *Arch Neurol* 1988; **45**:514-518.
76. Sigal LH. Therapy of isolated angitis of the central nervous system. *Neurology* 1989; **39**:164-165.
77. Sigal LH. The neurologic presentation of vasculitic and rheumatologic syndromes: a review. *Medicine* 1987; **66**:157-180.
78. Ferris EJ, Levine HL. Cerebral arteritis: classification. *Radiology* 1973; **109**:327-341.
79. Moore P, Cupps T. Neurological complications of vasculitis. *Ann Neurol* 1983; **14**:155-157.
80. Ewald EA, Aisen AM, Alpin R, Gebarski S, Vanderzant C, McCune J. Magnetic resonance imaging (MRI) abnormalities in isolated angiopathy of the central nervous system (IACNS) [Abstract]. *Arthritis Rheum* 1988; **31**:5120.
81. Miller DH, Ormerod IE, Gibson A, duBouley EP, Rudge P, McDonald WI. MR brain scanning in patients with vasculitis: differentiation from multiple sclerosis. *Neuroradiology* 1987; **29**:226-231.
82. Calabrese LH, Ropos T, Gragg LA, Furlan AJ. Primary angitis of the CNS (PACNS): an analysis of angiographic versus pathologically documented cases [Abstract]. *Arthritis Rheum* 1990; **33**:C158.
83. Tabbaa MA, Snyder BD. Vasospasm versus vasculitis in cases of benign cerebral vasculitis. *Ann Neurol* 1986; **19**:109.
84. Kistler JP, Crowell RM, Davis KR, et al. The relation of cerebral vasospasm to the extent and location of subarachnoid blood visualized by CT scan: a prospective study. *Neurology* 1984; **34**:636-638.
85. Rumbaugh CL, Begeron RT, Fang HCH, McCormick R. Cerebral angiographic changes in the drug abuse patient. *Radiology* 1971; **101**:335-344.
86. Lake R, Gallant S, Masson E. Adverse drug effects attributed to

- phenylpropanolamine: a review of 142 case reports. *Am J Med* 1990; 89:195-208.
87. Khodadad G. Middle cerebral artery embolectomy and prolonged widespread vasospasm. *Stroke* 1973; 4:446-450.
88. Suwanwela C, Suwanwela N. Intracranial arterial narrowing and spasm in acute head injury. *J Neurosurg* 1972; 35:314-323.
89. Masuzawa T, Shinoda S, Furuse M, Nakahara N, Abe F, Sato F. Cerebral angiographic changes on serial examination of a patient with migraine. *Neuroradiology* 1983; 24:277-281.
90. Call GK, Fleming MC, Sealfon S, Levine H, Kistler JP, Fisher CM. Reversible cerebral segmental vasoconstriction. *Stroke* 1988; 19:1159-1170.
91. Rascol A, Guiraud B, Manelfe C, et al. Accidents vasculaires cerebraux de la grossesse et du post partum. In: 2e Conference de la Salpetriere sur les maladies vasculaires cerebrales. 1980; 84-127.
92. Dupuy B, Lechevalier B, Chevalier D, et al. Complications vasculaires a rechute liees a la prise de methergin en milieu obstetrical. *Rev Otoneuroophthalmol* 1979; 51:293-299.
93. Rousseaux P, Scherpereel B, Bernard MH, et al. Angiopathie cerebrale aigue benigne. Six observations. *Presse Med* 1983; 12:2163-2168.
94. Masuzawa T, Shinoda S, Furuse M, et al. Cerebral angiographic changes on serial examination of a patient with migraine. *Neuroradiology* 1983; 24:277-287.
95. Armstrong FS, Hayes GJ. Segmental cerebral arterial constriction associated with pheochromocytoma. *J Neurosurg* 1961; 18:843-846.
96. Rodda RD, Denny-Brown D. The cerebral arterioles in experimental hypertension. I. The nature of arteriolar constriction and its effects on the collateral circulation. *Am J Pathol* 1966; 49:53-76.
97. Henry PY, Larre P, Aupy M, et al. Reversible cerebral arteriopathy associated with the administration of ergot derivatives. *Cephalgia* 1984; 4:171-178.
98. Rose AG. Diseases of medium-sized arteries, including hypertension. [In] Silver ND, ed. *Cardiovascular pathology*. New York: Churchill-Livingston, 1982:739-793.
99. Benson WR, Sealey WC. Arterial necrosis following research of coarctation of the aorta. *Lab Invest* 1956; 5:359-371.
100. Delany P, Estes M. Intracranial hemorrhage with amphetamine abuse. *Neurology* 1980; 30:1125-1128.
101. Kasorsky G, Zaidi IH, Tansy MF. LD50 and pathologic effects of acute and chronic administration of methamphetamine HCL in rabbits. *Res Commun Chem Pathol Pharmacol* 1972; 3:215-231.
102. Rumbaugh CL, Bergesson T, Scanlon R, et al. Cerebral vascular changes secondary to amphetamine abuse in the experimental animal. *Radiology* 1971; 101:345-351.
103. Mandybur TI. Cerebral amyloid angiopathy: the vascular pathology and complications. *J Neuropathol Exp Neurol* 1986; 45:79-90.
104. Anders KH, Latta H, Chang BS, et al. Lymphoid granulomatosis and malignant lymphoma of the central nervous system in acquired immunodeficiency syndrome. *Hum Pathol* 1989; 20:326.
105. Jaffe ES. Pathologic and clinical spectrum of post-thymic T cell malignancies. *Cancer Invest* 1984; 2:413.
106. Kave B, Gainstat M. Cerebral vasculitis associated with cocaine abuse. *JAMA* 1987; 258:2104-2106.
107. Tomsick TA, Lukin RR, Benton C. Neurofibromatosis and intracranial arterial occlusive disease. *Neuroradiology* 1976; 11:229-234.
108. Calabrese LH. Vasculitis and infection with the human immunodeficiency virus. *Rheum Dis Clin North Am* (in press).
109. Reik L, Burgdorfer W, Donaldsen JO. Neurologic abnormalities in Lyme disease without erythema chronicum migrans. *Am J Med* 1986; 81:73-78.
110. Vatz RA, Scheibel RL, Keiffer SA, Ansari KA. Neurosyphilis and diffuse cerebral angiopathy: a case report. *Neurology* 1974; 24:172-176.
111. Scheie HG, Albert DM. *Textbook of ophthalmology*. 9th ed. Philadelphia: WB Saunders, 1977:32-37, 204-207, 366.
112. Haynes BF, Kaiser-Kupfer MI, Mason P, Fauci AS. Cogan's syndrome: studies in 13 patients, long-term follow-up and a review of the literature. *Medicine* 1980; 59:426-441.
113. Olson ME, Chernik ML, Posner JB. Infiltration of the leptomeninges by systemic cancer: a clinical and pathologic study. *Arch Neurol* 1974; 30:122-137.
114. Wenzel RP, Hayden FG, Groshel DH, et al. Acute febrile cerebrovasculitis: a syndrome of unknown, perhaps rickettsial, cause. *Ann Intern Med* 1986; 104:606-615.
115. Smith CH, Savino PJ, Beck RW, Schatz NJ, Sergott RC. Acute posterior multifocal placoid pigment epitheliopathy and cerebral vasculitis. *Arch Neurol* 1983; 40:48-50.
116. Bowles CA. Vasculopathy associated with antiphospholipid antibody syndrome. *Rheum Dis Clin North Am* 1990; 16:417-490.
117. Whitely RJ, Cobbs G, Alford CA. Diseases that mimic herpes simplex encephalitis: diagnosis, presentation, outcome. *JAMA* 1989; 262:234-239.
118. Kovarsky J. Clinical pharmacology and toxicology of cyclophosphamide: emphasis on its use in rheumatic disease. *Semin Arthritis Rheum* 1983; 12:359-372.