



Doppler echocardiographic assessment of constrictive pericarditis, cardiac amyloidosis, and cardiac tamponade

ALLAN L. KLEIN, MD, AND GERALD I. COHEN, MD

■ Doppler echocardiography is useful in assessing diastolic dysfunction. Pulsed-wave Doppler echocardiographic interrogation of the atrioventricular valves and the central veins has been used in conjunction with respiratory monitoring to characterize abnormal diastolic function of the heart in diseases such as constrictive pericarditis, restrictive cardiomyopathy, and cardiac tamponade. Constrictive pericarditis has distinct Doppler flows with marked respiratory variation because the pericardial shell separates the intracardiac pressures from intrathoracic pressure. This is not the case with restrictive cardiomyopathy, as in cardiac amyloidosis. Cardiac amyloidosis shows a spectrum of the Doppler flows which evolve as the disease progresses from abnormal relaxation in the early phase to pseudo-normal in the intermediate phase and to restrictive in the advanced phase. Doppler echocardiography can be used to assess the hemodynamic significance of pericardial effusion and to detect cardiac tamponade.

□ INDEX TERMS: ECHOCARDIOGRAPHY, DOPPLER; PERICARDITIS, CONSTRICTIVE; CARDIOMYOPATHY, RESTRICTIVE; CARDIAC TAMPONADE; AMYLOIDOSIS □ CLEVE CLIN J MED 1992; 59:278-290

DOPPLER echocardiography is emerging as an excellent noninvasive technique to assess diastolic function of the heart.^{1,2} Its major application has been in diseases characterized by impaired diastolic filling, including constrictive pericarditis, restrictive cardiomyopathy, and cardiac tamponade.³⁻⁷ Recently, pulsed-wave Doppler echocardiographic interrogation of atrioventricular and central venous flow with respiratory monitoring has been successfully applied to differentiate constrictive pericarditis and restrictive cardiomyopathy.³ It has been used to comprehensively assess right and left ventricular diastolic function in cardiac amyloidosis and to provide important prognostic information for

these patients.^{4,8-11} It has also been used to assess the hemodynamic significance of cardiac tamponade. This review summarizes our current understanding of Doppler evaluation of constrictive pericarditis, restrictive myocardial disease, and cardiac tamponade.

DOPPLER EXAMINATION

Left ventricular diastolic function can be assessed by pulsed-wave Doppler echocardiography of the left ventricular inflow (transmitral) and pulmonary venous flow.^{4,8} Similarly, right ventricular diastolic function can be assessed by pulsed-wave Doppler echocardiography of the right ventricular inflow (transtricuspid) and superior vena cava and hepatic venous flow velocities.^{9,12} Phases of respiration are recorded by using a nasal thermistor which measures temperature changes in flow associated with inspiration, expiration, and apnea.²⁻⁴ The thermistor is connected to the

From the Department of Cardiology, The Cleveland Clinic Foundation.

Address reprint requests to A.L.K., The Cleveland Clinic Foundation, Department of Cardiology, 9500 Euclid Avenue, Cleveland, OH 44195-5064.

TABLE 1
DIASTOLIC FILLING PARAMETERS

Left ventricular filling dynamics	Right ventricular filling dynamics
Left ventricular inflow	Right ventricular inflow
Peak E (cm/second)	Peak E (cm/second)
Peak A (cm/second)	Peak A (cm/second)
E/A	E/A
DT (milliseconds)	DT (milliseconds)
IVRT (milliseconds)	
Pulmonary vein	Superior vena cava
Forward flow	Hepatic vein
Peak S (cm/second)	Forward flow
Peak D (cm/second)	Peak S (cm/second)
Reverse flow	Peak D (cm/second)
Peak AR (cm/second)	Reverse flow
	Peak AR (cm/second)
	Peak VR (cm/second)
	Inferior vena cava size (cm)

DT, deceleration time; IVRT, isovolumic relaxation time; peak A, peak late diastolic flow velocity; peak AR, peak atrial reversal flow velocity; peak D, peak venous diastolic forward flow velocity; peak E, peak early diastolic flow velocity; peak S, peak venous systolic forward flow velocity; peak VR, peak V wave reversal flow velocity

Adapted from Klein et al⁸

patient by a nasal clip which is attached to the input of an amplifier, which in turn is connected to the auxiliary input of the ultrasound machine.²⁻⁴ A moving line on the pulsed-wave Doppler spectral display indicates the phase of respiration. A crisp electrocardiography (ECG) signal is necessary to time systole and diastole.

Transthoracic echocardiography

Obtaining a reliable Doppler echocardiographic examination depends on meticulous technique and takes 30 minutes. The pulsed-wave Doppler sample volume must be precisely positioned, using color-flow Doppler echocardiography for guidance.⁴ Using transthoracic echocardiography in the apical four-chamber view, left ventricular and right ventricular inflow velocities are obtained by placing the sample volume at the leaflet tips of the mitral and tricuspid valves.^{4,9} Pulmonary venous flow recordings are obtained by placing the sample volume at the orifice of the right upper pulmonary vein; however, the quality of the recording may be limited by the fact that the orifice of the pulmonary vein is a far-field structure.⁴ Flow velocities in the superior vena cava are obtained by using a supraclavicular approach, placing the sample volume at a depth of 5 to 7 cm.^{9,12} Similarly, using the subcostal approach, hepatic venous flow velocities are recorded by placing the

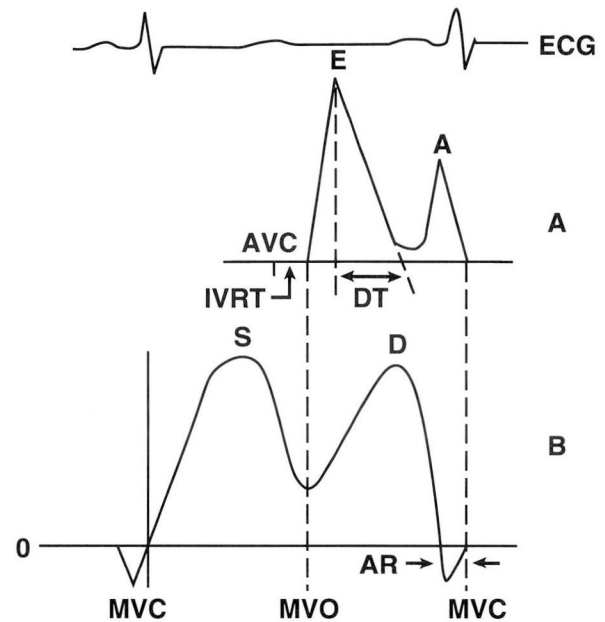


FIGURE 1. A. Diagram of normal left ventricular inflow velocities, showing a biphasic diastolic filling pattern with a greater peak early (E) flow velocity and smaller peak late (A) flow velocity. Deceleration time (DT) is the time required for the E velocity to decline from its peak to the baseline. Isovolumic relaxation time (IVRT) is the time from aortic valve closure (AVC) to mitral valve opening (MVO). B. Diagram of normal pulmonary venous flow velocity, showing a biphasic forward filling pattern with slightly greater systolic (S) than diastolic (D) flow velocities and reverse flow with atrial contraction (AR). MVC, mitral valve closure. (From Klein et al.⁴)

sample volume in the right superior hepatic vein 1 to 2 cm just proximal to the inferior vena cava.^{9,12} Subcostal M-mode echocardiography is commonly used to demonstrate the width of the inferior vena cava during respiration and its response to sniffing.¹³

Transesophageal echocardiography

Transesophageal echocardiography (using monoplane or biplane imaging) is useful in assessing left ventricular diastolic filling dynamics, since it allows pulsed-wave Doppler study of pulmonary venous flow in virtually all patients.^{14,15} The sample volume is placed within 1 to 2 cm of the entry of the left or right upper pulmonary vein with the left atrium.¹⁴⁻¹⁶ As in transthoracic echocardiography, left and right ventricular inflow velocities can be obtained by placing the sample volume at the leaflet tips of the mitral

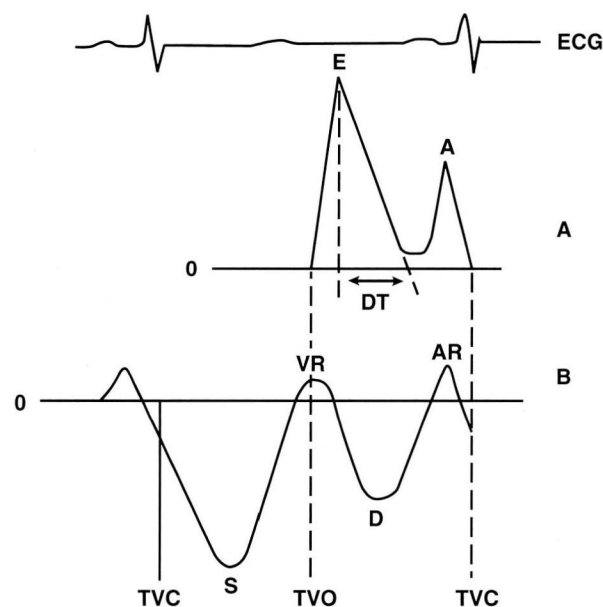


FIGURE 2. A. Diagram of normal right ventricular inflow velocities, showing a biphasic diastolic filling pattern with a greater peak early (E) flow velocity and a smaller peak late (A) flow velocity. Deceleration time (DT) is the time interval required for the E velocity to decline from its peak to the baseline. B. Diagram of normal superior vena cava or hepatic vein flow velocity showing a biphasic forward filling pattern with greater systolic (S) than diastolic (D) filling and reverse flow during late ventricular systole (VR) and with atrial contraction (AR). Usually, the hepatic vein has more prominent flow reversals than does the superior vena cava. TVC, tricuspid valve closure; TVO, tricuspid valve opening. (From Klein et al.⁹)

and tricuspid valves.¹⁴⁻¹⁶ Hepatic venous flow velocities and inferior vena cava width can also be obtained using transesophageal echocardiography.¹⁷

Measurements

Both on-line (immediate) and off-line (delayed) measurements are essential to diagnose diastolic dysfunction.^{4,8} The isovolumic relaxation time (IVRT) can be measured in the apical five-chamber view by placing the pulsed-wave or continuous-wave Doppler cursor between the left ventricular outflow and left ventricular inflow to record the time from aortic valve closure to mitral valve opening.^{4,8} The deceleration time of the left and right ventricular inflow is the time required for the peak early (E) filling velocity to

decline to zero. Values which can easily be measured at the patient's bedside include the following: the peak early and atrial (A) filling velocities of the left ventricular and right ventricular inflow; the deceleration time; the IVRT^{4,8}; the peak forward systolic and diastolic flow velocities of the superior vena cava, hepatic vein, and pulmonary vein; flow reversals with atrial contraction (AR) and with late ventricular systole (VR); and the size of the inferior vena cava.^{9,12} The right and left diastolic filling parameters which are routinely measured are shown in Table 1. Often, the filling pattern can be visually assessed from the flow recording as normal or restrictive, or as abnormal relaxation.^{4,8,12}

The flow velocities are recorded on hard copy at either 50 mm/second or 100 mm/second during respiratory monitoring. The data can be digitized off-line, using a commercially available digitizer work station to obtain the systolic and diastolic flow time velocity integrals (the area under the Doppler curve) and the reverse flow velocity integrals.^{4,9}

Normal Doppler flows

Normal left ventricular inflow and pulmonary venous flow velocities are diagrammed in Figure 1. Normal pulmonary venous flow is composed of a uniphasic or biphasic forward systolic flow component and a diastolic forward flow component.^{4,16,18} There is usually a small reversal of flow with atrial contraction.⁴ The left ventricular inflow and pulmonary venous flow velocities change very little with respiration (4% and 7%, respectively); however, age, heart rate, and loading conditions that affect left atrial pressure may significantly influence the flow velocities.^{16,19} Normal values for left ventricular filling parameters are shown in Table 2.¹⁹

Normal right ventricular inflow, hepatic vein, and superior vena cava flow velocities are shown in Figure 2. Like the pulmonary veins, the superior vena cava and hepatic vein show forward systolic and diastolic flow with small reversals with late ventricular systole (VR) and with atrial contraction (AR).^{9,12} The right ventricular inflow is more affected by the phase of respiration, showing increased flow with inspiration and a decrease with expiration and apnea.^{2,9,12} Hepatic vein and superior vena cava flow shows an accentuation of forward systolic and diastolic flow in inspiration compared to expiration and apnea, while the reversals of flow are typically more prominent in expiration.^{2,9,12} Normal values for right ventricular filling parameters are shown in Table 3.²⁰

CONSTRUCTIVE PERICARDITIS

Constrictive pericarditis is characterized by pericardial thickening that impairs filling into the heart by the central veins and across the valves, resulting in severe heart failure and low cardiac output.³ It is imperative to accurately diagnose constrictive pericarditis and to differentiate it from restrictive cardiomyopathy, since it can be cured by thoracotomy and pericardial stripping.^{21,22} Many techniques, including cardiac catheterization, radionuclide angiography, and echocardiography, have been applied in the attempt to differentiate these two similar disease states, but they are unreliable.²³

Hemodynamic signs

The hemodynamic signs of constrictive pericarditis and restrictive myocardial diseases are very similar. Right and left atrial pressures are elevated, with a preserved x descent and a prominent y descent with equal and small a and v waves, giving the appearance of the typical "M" or "W" configurations. Right and left ventricular diastolic pressure curves consist of a square root and a dip-and-plateau configuration with equalization of end-diastolic pressures in all cardiac chambers.^{24,25}

In constrictive pericarditis, right and left ventricular end-diastolic pressures are essentially the same (within 5 mm Hg) at rest and during exercise. Pulmonary hypertension occurs with only mild elevation of pulmonary systolic pressure, between 35 and 45 mm Hg. The right ventricular diastolic pressure during the plateau phase is at least one third of the right ventricular systolic pressure. When the hemodynamic profile is not consistent with constrictive pericarditis but suspicion of the condition is high, a fluid challenge of 500 to 1000 mL of saline over 5 to 10 minutes may

TABLE 2
LEFT VENTRICULAR FILLING DYNAMICS IN NORMAL SUBJECTS

	< 50 years (n = 61)	≥ 50 years (n = 56)	P value
Left ventricular inflow			
Peak E (cm/second)	72 ± 14	62 ± 14	< 0.01
Peak A (cm/second)	40 ± 10	59 ± 14	< 0.01
E/A	1.9 ± 0.6	1.1 ± 0.3	< 0.01
DT (milliseconds)	179 ± 20	210 ± 36	< 0.01
IVRT (milliseconds)	76 ± 11	90 ± 17	< 0.01
Pulmonary vein	(n = 44)	(n = 41)	
Peak S (cm/second)	48 ± 9	71 ± 9	< 0.01
Peak D (cm/second)	50 ± 10	38 ± 9	< 0.01
Peak AR (cm/second)	19 ± 4	23 ± 14	< 0.01

Abbreviations: See Table 1
From Klein et al¹⁹

TABLE 3
RIGHT VENTRICULAR FILLING DYNAMICS IN NORMAL SUBJECTS

	< 50 years (n = 61)	≥ 50 years (n = 56)	P value
Right ventricular inflow			
Peak E (cm/second)	51 ± 7	41 ± 8	< 0.01
Peak A (cm/second)	27 ± 8	33 ± 8	< 0.01
E/A	2.0 ± 0.5	1.34 ± 0.4	< 0.01
DT (cm/second)	188 ± 22	198 ± 23	< 0.01
Superior vena cava	(n = 59)	(n = 53)	
Peak S (cm/second)	41 ± 9	42 ± 12	(not significant)
Peak D (cm/second)	22 ± 5	22 ± 5	(not significant)
Peak AR (cm/second)	13 ± 3	16 ± 3	< 0.01

Abbreviations: See Table 1
From Klein et al²⁰

bring out the typical hemodynamic changes of the disease.²⁴⁻²⁶

In contrast, in restrictive cardiomyopathy, the left ventricular end-diastolic pressure typically exceeds the right ventricular end-diastolic pressure by greater than 5 mm Hg, especially with exercise. Pulmonary systolic pressures are markedly elevated (>45 mm Hg), and the right ventricular diastolic pressure during the plateau phase is usually less than one third of the right ventricular systolic pressure.^{24,25}

Echocardiographic signs

Several M-mode and two-dimensional criteria for assessing pericardial constriction are recognized.^{23,27,28} M-mode criteria include thickened pericardium, premature opening of the pulmonary valve, abnormal diastolic flattening of the left ventricular posterior wall, an early diastolic notch, and an atrial filling and diastolic wall abnormality in the ventricular septum.²⁸

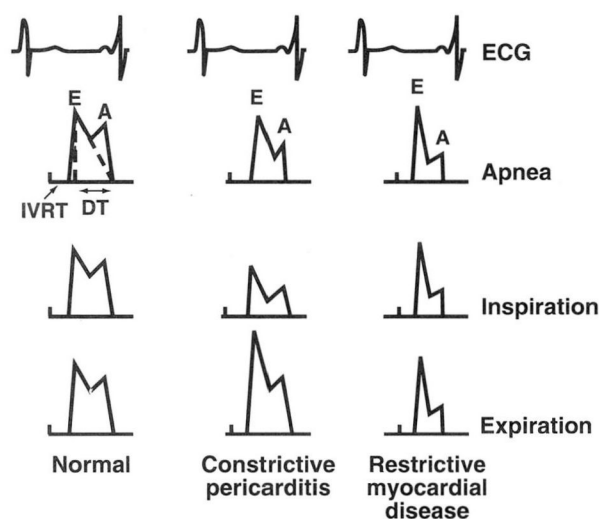


FIGURE 3. Diagram of left ventricular inflow velocities during different phases of respiration. In normal subjects, there is little change in E/A ratio, deceleration time (DT), and isovolumic relaxation time (IVRT) during apnea, inspiration, and expiration. In constrictive pericarditis, Doppler flow velocities show marked respiratory variation, with increased peak E and peak A flow velocities and a shortened IVRT in expiration vs inspiration, and with intermediate values for apnea. In restrictive myocardial disease (cardiac amyloidosis) there is an increased E/A ratio, a markedly shortened deceleration time, and a decreased IVRT; however, there is minimal respiratory variation in the Doppler flow velocities.

Two-dimensional criteria for constrictive pericarditis include a jerking motion of the ventricular septum in early diastole (diastolic septal bounce) and a dilated inferior vena cava (plethora). In addition, the myocardium may be tethered to the pericardium.^{13,27} These signs have a sensitivity and specificity varying from 62% to 93%.¹³

Differential diagnosis

In constrictive pericarditis, the constricted pericardium shields the cardiac chambers (but not the pulmonary veins) from changes in intrathoracic pressure; moreover, interventricular dependence is exaggerated because of the constraints of the intrapericardial space. These two factors cause accentuated respiratory variations of Doppler flows in the right and left heart.^{2,3}

Hatle and associates used Doppler echocardiography to differentiate constrictive pericarditis from restrictive cardiomyopathy.³ Seven patients with surgically documented constrictive pericarditis were com-

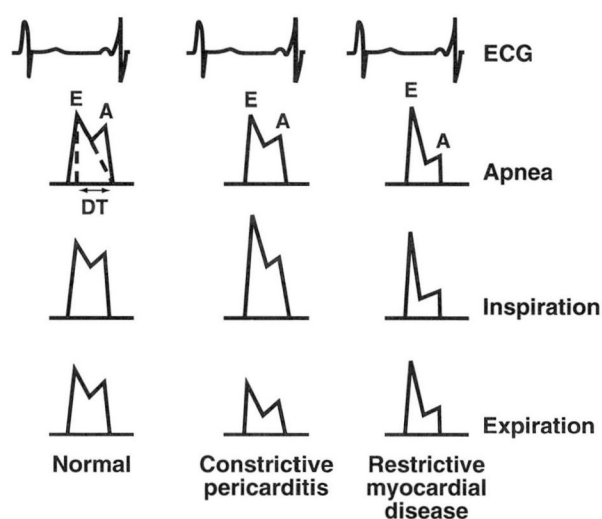


FIGURE 4. Diagram of right ventricular inflow velocities during different phases of respiration. In normal subjects there is a mild increase in the peak early (E) and peak late (A) velocities with inspiration compared with expiration and apnea. In constrictive pericarditis, there is markedly decreased peak E velocity and peak A velocity in expiration compared with inspiration, with intermediate values for apnea. In restrictive myocardial disease, there is markedly increased E/A ratio, shortened deceleration time (DT) with a further shortening during inspiration. There is no significant change in the E/A ratio with respiration.

pared to 12 patients with restrictive myocardial disease and 20 healthy volunteers. The main cause for constrictive pericarditis was previous cardiac bypass surgery and radiation, while the main etiology in the restrictive group was chronic rejection after transplantation. The hemodynamic conditions in the two groups were very similar. Equalization of end-diastolic pressures occurred in five of seven patients (71%) with constrictive pericarditis, compared with 7 of 12 (58%) with restrictive cardiomyopathy.³

While both groups had similar baseline hemodynamics, only patients with constrictive pericarditis showed a pronounced respiratory effect on hemodynamics. The reason for this is that the pulmonary veins, which are not surrounded by pericardium, demonstrate greater respiratory variation in pressures than do the left atrium and ventricle. Hence, the diastolic pressure gradient between the pulmonary vein and the left ventricle is reduced during inspiration and increased during expiration. Furthermore, respiratory variation in ventricular filling and inter-

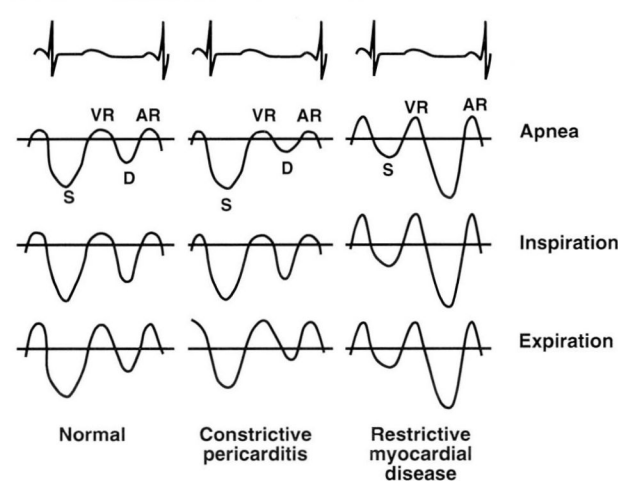


FIGURE 5. Diagram of hepatic venous flow velocities during different phases of respiration. In normal subjects there is a greater peak systolic (S) to diastolic (D) flow velocity with an increase in forward flow on inspiration, with small reversals of flow associated with a late ventricular systole (VR) and atrial contraction (AR). The reversals are usually more prominent in expiration compared with inspiration and apnea. In constrictive pericarditis, there is a normal increase in peak systolic-to-diastolic flow velocities in inspiration; however, in expiration, systolic flow velocity decreases and diastolic flow velocities decrease, reflecting decreased flow velocities in the right ventricular inflow. There is also a markedly increased reversal of flow in expiration compared with inspiration and apnea. In restrictive myocardial disease, there is greater peak diastolic-to-systolic flow during all phases of respiration, with increased reversals of flow during inspiration compared with expiration and apnea.

ventricular dependence result in pronounced changes in right and left ventricular systolic pressures: on inspiration, right ventricular systolic pressure is increased and left ventricular systolic pressure is decreased. In contrast, restrictive cardiomyopathy patients showed little respiratory variation in the pulmonary vein-to-left ventricular diastolic pressure gradient and right and left ventricular systolic pressures.³

Left and right ventricular flow velocities

As a result of these pressure gradients, Doppler flow velocities in constrictive pericarditis show marked respiratory variation (Figures 3 and 4). From expiration to inspiration, isovolumic relaxation time increased 50%, left ventricular inflow peak E velocity decreased 33%, right ventricular inflow peak E velocity increased 44%, and right ventricular inflow peak A velocity increased 38%. In contrast, patients with restrictive

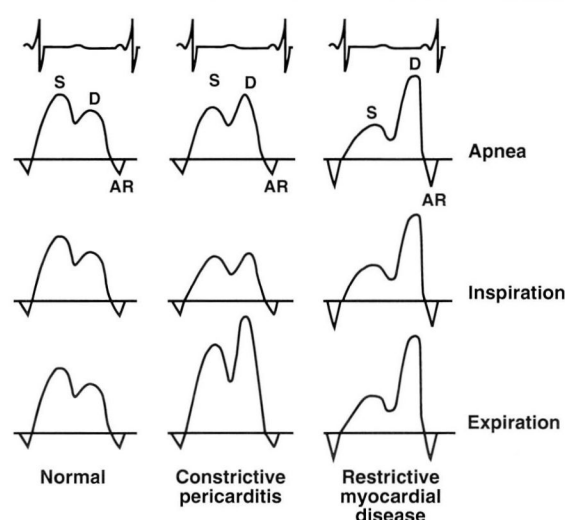


FIGURE 6. Diagram of pulmonary venous flow velocities during different phases of respiration. In normal subjects, there is very little respiratory change in the pulmonary venous flow velocities, with a greater peak systolic (S)-to-diastolic (D) flow velocity and a small reversal flow at atrial contraction (AR). In constrictive pericarditis there is a slight decrease in the peak systolic-to-diastolic flow for all phases of respiration; however, there is a marked increase in the systolic and especially the diastolic flow velocities in expiration compared with inspiration and apnea. In restrictive myocardial disease, peak diastolic-to-systolic flow is increased and atrial reversal (AR) is markedly increased and there is only little respiratory change in the flow velocities.

myocardial diseases and normal volunteers had a mean variation of less than 5% variation in left and right ventricular inflow peak E velocities, with no subject showing a variation greater than 15%.³

To recognize the effects of respiration on Doppler findings in constrictive pericarditis requires attention to the timing of these changes. In Hatle's study, the smallest left ventricular peak E velocity and largest IVRT in constrictive pericarditis occurred on the first beat after the onset of inspiration; the opposite changes occurred on the first beat after the onset of expiration. Similar reciprocal changes in aortic and pulmonary flow velocities occurred slightly later in the respiratory cycle than the changes in left ventricular and right ventricular inflow velocities. After pericardiectomy, the respiratory changes disappeared and Doppler flows were normal.³

In the Hatle study, the predominant Doppler finding in restrictive cardiomyopathy was a shortened deceleration time (<150 milliseconds) in the left

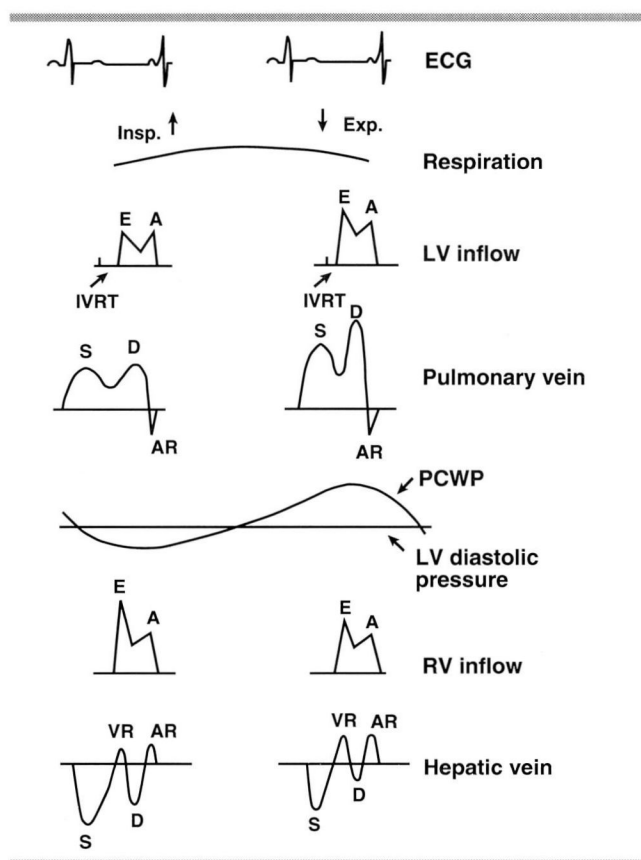


FIGURE 7. Diagram showing the effect of respiration on the left ventricular inflow, pulmonary vein, pulmonary capillary wedge (PCWP)-to-left ventricular diastolic pressure gradient, right ventricular inflow, and hepatic vein. With the onset of inspiration (Insp.), the gradient is decreased, which is reflected in decreased left ventricular peak E velocity, prolonged isovolumic relaxation time (IVRT), and decreased pulmonary venous systolic (S) and diastolic (D) flow velocities. In contrast, the right ventricular inflow peak E velocity and hepatic vein systolic and diastolic flow velocities are increased. With the onset of expiration (Exp.), the gradient is increased, which is reflected in an increased left ventricular peak E velocity, a shortened IVRT, and increased pulmonary systolic and diastolic flow velocities. In contrast, the right ventricular inflow peak E velocity is decreased and the hepatic vein diastolic flow velocities are decreased or absent with increased reversals of flows. (AR, peak atrial reversal of flow; VR, peak late systolic reversal of flow.)

ventricular and right ventricular inflow peak E velocities, with further reduction in the deceleration time of the right ventricular inflow on inspiration. Also, the right and left ventricular inflow peak A velocity was decreased, causing an increased E/A ratio, and diastolic tricuspid and mitral regurgitation was very common. This was usually detected by placing the

sample volume at the level of the mitral annulus.^{3,29,30}

Patients with chronic obstructive pulmonary disease had respiratory changes in Doppler flows similar to constrictive pericarditis; however, in chronic obstructive pulmonary disease there was less respiratory change in the left ventricular peak E velocity, IVRTs, and right ventricular inflow deceleration time. Moreover, the timing of the changes was delayed to the second or third beat after inspiration, in contrast to the first beat in constrictive pericarditis.³

Central venous flow velocities

Appleton and associates described the respiratory changes in the superior vena cava and hepatic venous flow velocities in constrictive pericarditis which reflect changes in the right ventricular inflow.³¹ On the first beat of inspiration, systolic and diastolic flow velocities increase and reversals of flow decrease compared with expiration and apnea. On the first beat of expiration, diastolic forward flow decreases, and sometimes disappears (reflecting the decrease in the right ventricular inflow velocities), and reversals of flow are accentuated compared with apnea and inspiration (Figure 5).^{2,31}

Recently transesophageal echocardiography has been used to demonstrate the effect of respiration on pulmonary venous flow in constrictive pericarditis, which is reflected in changes in the left ventricular inflow.^{32,33} Pulmonary venous flow shows marked respiratory changes: a decrease in systolic and diastolic flows on inspiration, and an increase (especially in diastolic flows) during expiration (Figure 6).^{32,33}

In restrictive myocardial disease, there is usually a greater diastolic-to-systolic flow (prominent y descent) in the superior vena cava, hepatic vein, and pulmonary vein, and only small respiratory changes (Figure 6).^{4,12,33}

Mechanism

In constrictive pericarditis, the changes in intrathoracic pressure with respiration are not transmitted to the cardiac chambers because the encompassing thick pericardial scar separates intrathoracic pressures (pulmonary vein) from intracardiac pressures (left atrium and ventricle).³ During inspiration, intrathoracic pressure falls, with little effect on left ventricular diastolic pressure, whereas the pulmonary venous pressure decreases significantly. Thus, there is less respiratory variation in left ventricular diastolic pressure, whereas the pulmonary venous or left atrial pressure decreases significantly with inspiration. Thus, the gradient across the mitral valve (reflecting the pulmonary vein-to-left ventricular pressure gradient) is

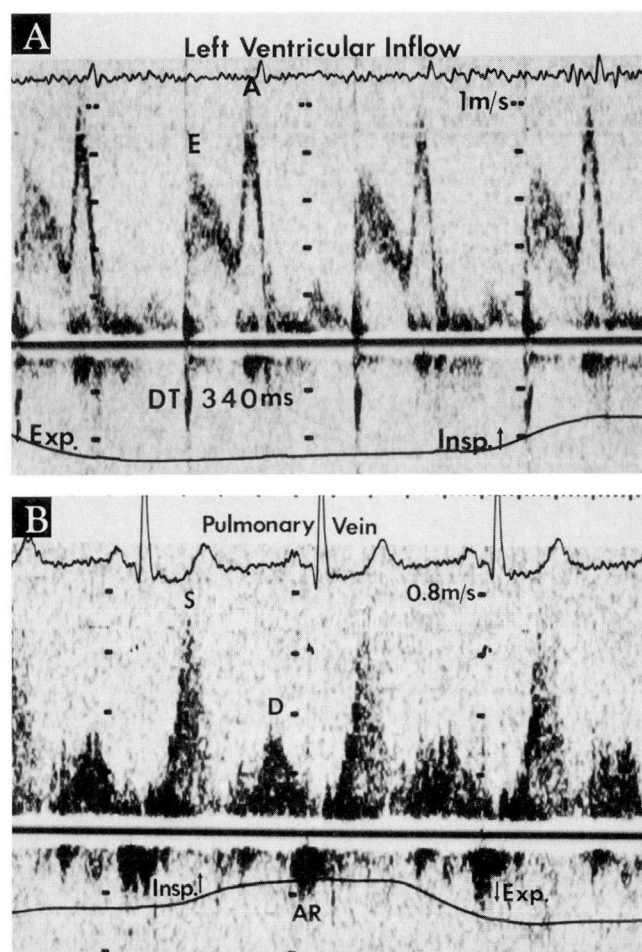


FIGURE 8. Abnormal relaxation flow pattern of left ventricular inflow in early cardiac amyloidosis. A. Pulsed-wave Doppler recording of a left ventricular inflow profile with decreased peak E velocity and increased peak A velocity. The E/A ratio was decreased (0.6) and deceleration time (DT) was prolonged (340 ms). B. Pulsed-wave Doppler recording of right upper pulmonary vein flow profile with increased peak forward systolic (S) and decreased diastolic (D) flow velocities and normal reversal of atrial filling (AR). (Exp., expiration; Insp., inspiration.)

decreased, causing decreased left ventricular inflow velocities. The IVRT is prolonged in inspiration because left atrial pressure is lower due to the decreased pressure gradient and the left ventricular isovolumic pressure must fall further before the mitral valve will open.³

The opposite changes are seen with expiration, and there are reciprocal changes across the right and left ventricles because of enhanced interventricular dependence.³⁴ This occurs because the pericardial scar limits the space available for ventricular filling, and

TABLE 4
EFFECT OF VENTRICULAR WALL THICKNESS ON LEFT VENTRICULAR FILLING DYNAMICS IN CARDIAC AMYLOIDOSIS

	Early (< 15mm)	Advanced (≥ 15mm)
Left ventricular inflow		
Peak E	Decreased	Increased
Peak A	Increased	Decreased
E/A	Decreased	Increased
DT	Normal to prolonged	Short
IVRT	Prolonged	Decreased
Pulmonary vein		
Peak S	Increased	Decreased
Peak D	Decreased	Increased
Peak AR	No change	Increased

DT, deceleration time; IVRT, isovolumic relaxation time; peak A, peak late diastolic flow velocity; peak AR, peak atrial reversal flow velocity; peak D, peak venous diastolic forward flow velocity; peak E, peak early diastolic flow velocity; peak S, peak venous systolic forward flow velocity

because the cardiac volume is relatively fixed.³ Thus, during inspiration, when the left ventricular inflow and pulmonary venous flow velocities decrease, the right ventricular inflow velocities, hepatic vein, and superior vena cava increase. In contrast, during expiration, when the left ventricular inflow and pulmonary venous flows increase, there is a decrease in the right ventricular inflow velocities and a decrease or complete loss of diastolic forward filling in the superior vena cava and hepatic vein (Figure 7).³

In restrictive cardiomyopathy, noncompliance of the ventricle (rather than the pericardium) limits ventricular filling.^{29,30} Thus, the intrathoracic pressure is transmitted into the left ventricular cavity, so that with respiration there is tracking of the pulmonary vein-to-left ventricular pressure gradient, and thus, the gradient across the mitral valve is not altered with respiration, similar to the normal state.^{29,30}

RESTRICTIVE MYOCARDIAL DISEASE: CARDIAC AMYLOIDOSIS

Systemic amyloidosis is a multisystem disorder in which amyloid fibrils are deposited in various organs of the body, including the heart. In this disorder, cardiac complications are the most frequent cause of death.³⁵ Cardiac amyloidosis has been termed "stiff heart syndrome" because amyloid infiltration interferes with diastolic filling of the heart.³⁶ Cardiac amyloidosis has been traditionally considered a restrictive myocardial disease³⁷⁻⁴¹; however, recent investigations have shown a spectrum of diastolic filling abnormalities in this disease.^{4,9}

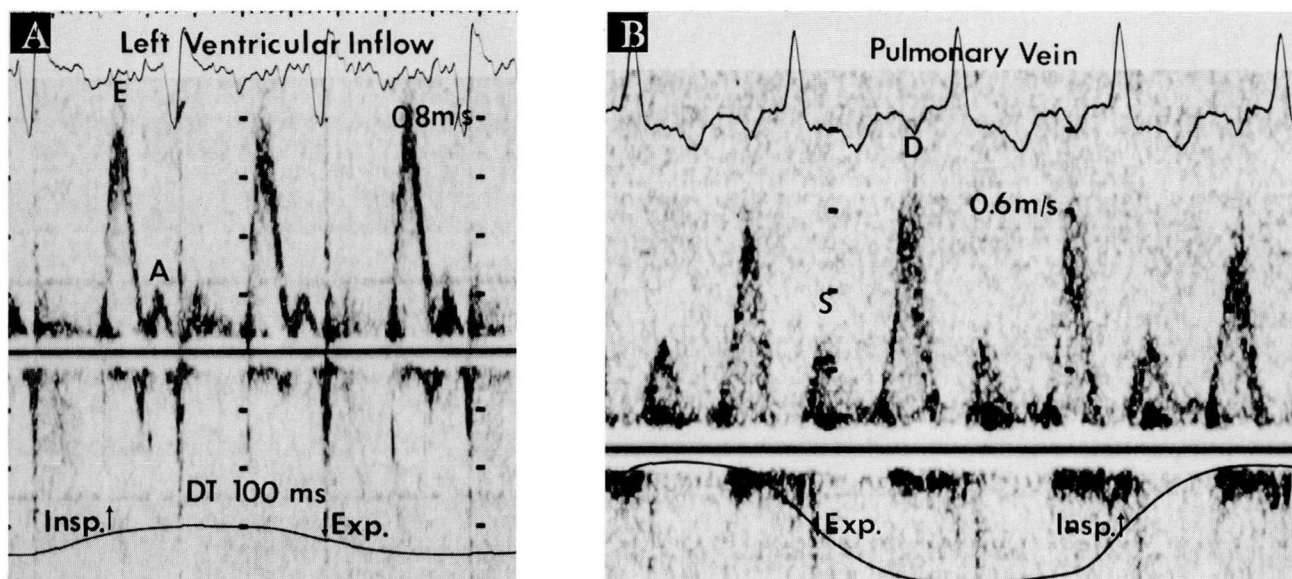


FIGURE 9. Restrictive flow patterns of left ventricular inflow in advanced cardiac amyloidosis. A. Pulsed-wave Doppler recording of a left ventricular inflow profile with an increased E/A ratio (4.5) and short deceleration time (100 milliseconds). B. Pulsed-wave Doppler recording of a right upper pulmonary vein flow profile with decreased peak forward systolic (S) and increased peak diastolic (D) velocities. The left-sided flow velocities are influenced minimally by respiration.

Left ventricular diastolic function

We studied 53 patients with cardiac amyloidosis using pulsed-wave Doppler interrogation of the left ventricular inflow and pulmonary veins.⁴ By subdividing the patients into early and advanced subgroups based on mean left ventricular wall thickness (as a measure of amyloid infiltration), a very uniform diastolic velocity profile was observed. The early subgroup (wall thickness <15 mm) showed evidence of abnormal relaxation characterized by a prolonged IVRT, decreased left ventricular inflow peak E velocity, increased peak A velocity, and decreased E/A ratio (Table 4). The deceleration time ranged from usually normal to prolonged in this subgroup (Figure 8). In contrast, the advanced subgroup (wall thickness \geq 15 mm) showed a markedly shortened deceleration time (<150 milliseconds) and an increased E/A ratio compatible with restrictive physiology (Figure 9).

We also recorded pulmonary venous flow velocities and found a close relationship between left ventricular inflow and pulmonary venous flow. The early subgroup usually showed an increased systolic-to-diastolic flow characteristic of abnormal relaxation, while the advanced subgroup showed a greater diastolic-to-systolic flow characteristic of restrictive physiology

(Figures 8 and 9). The increased pulmonary venous diastolic flow velocity was associated with the increase in the left ventricular peak E velocity.⁴

Right ventricular diastolic function

We also examined the effects of amyloid infiltration of the right ventricular myocardium on diastolic function.⁹ We studied 41 patients using pulsed-wave Doppler interrogation of the right ventricular inflow, superior vena cava, and hepatic vein. Patients with a marked increase in right ventricular free wall thickness (\geq 7 mm) showed restrictive physiology, while the group with a wall thickness that was normal to mildly increased (<7 mm) demonstrated abnormal relaxation (Table 5). In most patients, equivalent findings of restriction were suggested by the superior vena cava and hepatic vein flow velocities, which showed greater peak diastolic-to-systolic flow (similar to the prominent y descent seen in the right atrial pressure tracing). Hepatic vein flow velocities were similar to those of the superior vena cava, except for greater reversals of flow in the hepatic vein. The reversal of flows that were normally increased in expiration showed a marked increase in both inspiration and expiration.⁹ Filling patterns in both ventricles was similar

in 85% of the patients.⁹

Mechanism

The mechanism for the altered right and left ventricular diastolic filling in cardiac amyloidosis has not been elucidated. It is well known that patients with early signs of cardiac dysfunction show relaxation abnormalities, so it is not surprising that patients with early cardiac amyloidosis show abnormal relaxation. It is possible that the relaxation process is altered by mild amyloid infiltration, which can affect calcium fluxes within the myocardial cells or cause nonuniformity of contraction and relaxation. This results in the decreased E/A ratio and a compensatory increased peak A filling velocity. With advanced amyloid infiltration, the ventricles become stiff, which results in very rapid early filling and a restrictive Doppler filling pattern.^{4,9}

Serial follow-up

From our initial observations we hypothesized that Doppler echocardiographic patterns in patients with cardiac amyloidosis evolve from an abnormal relaxation pattern to a pseudonormal filling pattern and, eventually, to a restrictive pattern of advanced disease.¹⁰ To test this hypothesis, we followed 41 consecutive patients for 13 months. The early subgroup showed significant changes in 7 of 24 patients (29%). Two patients changed from an abnormal relaxation pattern to normal flow, and five patients changed from normal to restriction with increased symptoms (Figure 10). As expected, patients with advanced cardiac amyloidosis showed very little change in Doppler flows since they were already restricted.¹⁰

Prognostic significance

We also studied the value of Doppler filling patterns in predicting prognosis in cardiac amyloidosis.¹¹ We studied 63 patients and divided them according to deceleration time into a restrictive group and a nonrestrictive group. During an 18-month follow-up, we found that the relative risk of cardiac death was approximately five times higher in the restrictive group than in the nonrestrictive group. Similarly, 1-year survival in the restrictive group was 49%, compared with 92% in the nonrestrictive group. The best predictor of cardiac death was the E/A ratio; in fact, the E/A ratio and the deceleration time, both simple measures of diastolic filling function, were more predictive of cardiac death than the typical echocardiographic variables of mean ventricular wall thickness and fractional shortening. This study was the first to document that

TABLE 5
EFFECTS OF VENTRICULAR WALL THICKNESS ON RIGHT VENTRICULAR FILLING DYNAMICS IN CARDIAC AMYLOIDOSIS

	Early (RV < 7mm)	Advanced (RV ≥ 15mm)
Right ventricular inflow		
Peak E	Decreased	Increased
Peak A	Increased	Decreased
E/A	Decreased	Increased
DT	Normal/prolonged	Short
With inspiration	No change	Further shortening
Hepatic vein, superior vena cava		
Peak S	Increased	Decreased
Peak D	Decreased	Increased
Peak AR	Normal	Increased
Peak VR	Normal	Increased
With inspiration	No change	Increased

DT, deceleration time; peak A = peak late diastolic flow velocity; peak AR, peak atrial reversal flow velocity; peak D, peak venous diastolic forward flow velocity; peak E, peak early diastolic flow velocity; peak S, peak venous systolic forward flow velocity; peak VR, peak late ventricular systolic reversal flow velocity

diastolic filling variables can be important predictors of survival in this patient population.¹¹

CARDIAC TAMPONADE

Classic cardiac tamponade is characterized by rising venous pressure, decreasing arterial pressure, a small, quiet heart, and pulsus paradoxus.²⁵ The typical hemodynamic signs of cardiac tamponade include elevation and equalization of right atrial, right ventricular end-diastolic, and pulmonary capillary wedge pressures.^{25,42} The right atrial waveform shows a prominent systolic x descent but an absent or diminished y descent, unlike constrictive pericarditis.^{25,42}

Echocardiographic signs

A number of M-mode and two-dimensional echocardiographic signs may suggest the presence of cardiac tamponade. Diastolic right atrial, right ventricular, and left atrial collapse are important findings but are not entirely reliable indicators.⁴³⁻⁴⁷ Chamber collapse is a function of the difference in intracardiac and pericardial pressures.⁴⁷ This may be accentuated by hypotension and minimized by elevation of right ventricular diastolic pressure, as with right ventricular hypertrophy and elevation of left ventricular diastolic pressure with left ventricular dys-

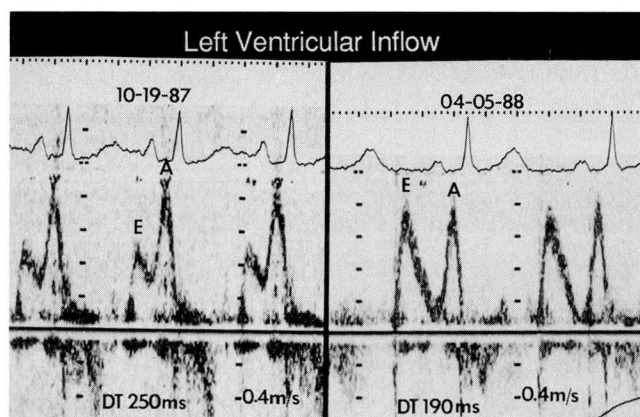


FIGURE 10. Serial left ventricular inflow patterns (pulsed-wave Doppler recordings) in a 63-year-old woman with symptomatic cardiac amyloidosis whose pattern changed from abnormal relaxation to “pseudonormalization” over 5.5 months. Left, decreased E/A ratio (0.5) and prolonged deceleration time (DT) (250 milliseconds). Right, 5.5 months later, E/A ratio (1.0) and deceleration time (190 milliseconds) are normal. (From Klein et al.¹⁰)

function.^{47,48} Dilatation of the inferior vena cava with failure to collapse by more than 50% upon inspiration (inferior vena cava plethora) is another useful sign.⁴⁹

All clinical and echocardiographic findings must be considered before a diagnosis of tamponade is made. Recently, Doppler echocardiography with respiratory monitoring has been used to assess the hemodynamic changes in pericardial effusion.⁵⁻⁷ Several investigators have found a marked change in Doppler flow velocities with respiration in cardiac tamponade that disappears after pericardiocentesis.⁵⁻⁷ Patients with tamponade showed the following: a marked respiratory change in left ventricular inflow velocities from expiration to inspiration; a 34% to 85% increase in IVRT; a 34% to 43% decrease in left ventricular inflow peak E velocity; and a 25% decrease in left ventricular peak A velocity. Similarly, there was a marked respiratory change in right ventricular inflow velocities from expiration to inspiration, a 77% to 85% increase in right ventricular peak E velocity, and a 58% increase in right ventricular peak A velocity. As in constrictive pericarditis, the changes were most evident on the first beat after the onset of inspiration and on the first beat after the onset of expiration.^{5,7}

Central venous flows

Superior vena cava and hepatic vein flow velocities show a marked predominance of systolic flow (compatible with prominent x descent in the right atrial

pressure tracing) with the onset of inspiration in tamponade. On the first beat after the onset of expiration, diastolic flow velocity decreases or disappears (corresponding to the decrease in right ventricular peak E velocity at the onset of expiration), and reversals of flow increase.^{5,7} After pericardiocentesis, the flow velocities return to normal in the hepatic veins.^{5,7} In some patients, the respiratory variations do not disappear: this may suggest effusive-constrictive pericarditis.⁷

Recently, our laboratory found a spectrum of respiratory variation in the left ventricular inflow peak E velocities in patients with small to large pericardial effusion, and a significant correlation between respiratory change in the Doppler flow velocities and right atrial collapse and right ventricular collapse.⁵⁰

Pulsus paradoxus

The respiratory variation in Doppler flow velocities in tamponade seems closely related to the mechanism of pulsus paradoxus.⁵¹ Shabetai et al demonstrated that the effect of respiration on right heart filling was mainly responsible for the inspiratory decrease in arterial pressure seen in pulsus paradoxus.⁵² Pulsus paradoxus may be also primarily related to the left heart, with an inspiratory decrease in the gradient from intrathoracic pulmonary veins to the intrapericardial left ventricle causing variation in flow velocities similar to those seen in constrictive pericarditis.^{53,54} During inspiration, the pulmonary vein-to-left ventricular filling gradient decreases, resulting in delayed mitral valve opening and, therefore, prolongation of the IVRT and decreased peak E velocity. Because of intraventricular dependence, the reciprocal changes will occur on the other side of the heart.⁵

Similarities between constrictive pericarditis and tamponade are evident. Pulsus paradoxus may occur in both conditions, though it is more common in tamponade.^{25,42} Isolation of intracardiac pressure from the thorax and enhanced interventricular dependence contribute to the hemodynamic findings of both conditions.^{3,5} There is one important difference: with tamponade, all four chambers must compete for space within a fixed fluid volume. Venous return occurs only with atrial relaxation (or descent of the base heart), thus preserving the x descent of the atrial pressure tracing (the systolic forward flow velocity in the central veins). The y descent (the diastolic forward flow velocity) disappears because intrapericardial pressure stays constant during ventricular filling.^{5,25,42} In contrast, the x and y descents (systolic and diastolic flow) are preserved in constrictive pericarditis.^{3,25,42}

There also may be overlap with effusive constrictive pericarditis.⁷

PRESENT LIMITATIONS AND FUTURE RESEARCH

Doppler echocardiography has a number of pitfalls and limitations in assessing right and ventricular diastolic filling in pericardial diseases and restrictive cardiomyopathy.² The study must be performed with meticulous attention to detail. Many variables can affect diastolic filling, including heart rate, preload, and afterload.^{12,16} Atrial arrhythmias or ventricular-paced rhythm may cause difficulties.² Chronic lung disease may produce findings similar to those of constrictive pericarditis.^{3,55} Differentiating restrictive cardiomyopathy with pericardial effusion from constrictive pericarditis may be difficult because both conditions change Doppler flows during respiration.^{2,4}

Further research is needed to determine the effect of

respiration on transvalvular flow velocities in patients with surgical vs medical-pericardial effusions, and in patients with low-pressure cardiac tamponade,⁵⁶ as well as the effect of a localized pericardial scar vs circumferential pericardial scar in constrictive pericarditis. Also, occult constrictive pericarditis and effusive constrictive pericarditis have not yet been characterized by Doppler echocardiography. However, real-time intracardiac two-dimensional echocardiography is an exciting development with the potential for viewing pericardial effusions from the inside looking out, as well as for obtaining flow velocities across the valves.⁵⁷

At present, Doppler echocardiography with respiratory monitoring can distinguish a spectrum of diastolic filling abnormalities. Its findings can be used clinically to distinguish constrictive pericarditis from restrictive cardiomyopathy, assess the severity and prognosis of cardiac amyloidosis, and diagnose cardiac tamponade.

REFERENCES

- Labovitz NJ, Pearson AL. Evaluation of left ventricular diastolic function: clinical relevance and recent Doppler echocardiographic insights. *Am Heart J* 1987; 114:836-851.
- Nishimura RA, Abel MD, Hatle LK, Tajik AJ. Assessment of diastolic function of the heart: background and current applications of Doppler echocardiography: Part II. *Mayo Clin Proc* 1989; 64:181-204.
- Hatle LK, Appleton CP, Popp RL. Differentiation of constrictive pericarditis and restrictive cardiomyopathy by Doppler echocardiography. *Circulation* 1989; 79:357-370.
- Klein AL, Hatle LK, Burstow DJ, et al. Doppler characterization of left ventricular diastolic function in cardiac amyloidosis. *J Am Coll Cardiol* 1989; 13:1017-1026.
- Appleton CP, Hatle LK, Popp RL. Cardiac tamponade and pericardial effusion: respiratory variation in transvalvular flow velocity studied by Doppler echocardiography. *J Am Coll Cardiol* 1988; 11:1020-1030.
- Leeman DE, Levine MJ, Come PC. Doppler echocardiography in cardiac tamponade: exaggerated respiratory variation in transvalvular blood flow velocity integrals. *J Am Coll Cardiol* 1988; 11:572-578.
- Burstow DJ, Oh JK, Bailey KR, Seward JB, Tajik AJ. Cardiac tamponade: characteristic Doppler observations. *Mayo Clin Proc* 1989; 64:312-324.
- Klein AL, Oh JK, Miller FA, Seward JB, Tajik AJ. Two-dimensional and Doppler echocardiographic assessment of infiltrative cardiomyopathy. *J Am Soc Echocardiogr* 1988; 1:48-59.
- Klein AL, Hatle LK, Burstow DJ, et al. Comprehensive Doppler assessment of right ventricular diastolic function in cardiac amyloidosis. *J Am Coll Cardiol* 1990; 15:99-108.
- Klein AL, Hatle LK, Taliercio CP, et al. Serial Doppler echocardiographic follow-up of left ventricular diastolic function in cardiac amyloidosis. *J Am Coll Cardiol* 1990; 16:1135-1141.
- Klein AL, Hatle LK, Taliercio CP, et al. Prognostic significance of Doppler measures of diastolic function in cardiac amyloidosis. A Doppler echocardiography study. *Circulation* 1991; 83:808-816.
- Appleton CP, Hatle LK, Popp RC. Superior vena cava and hepatic vein Doppler echocardiography in healthy adults. *J Am Coll Cardiol* 1987; 10:1032-1039.
- Himelman RB, Lee E, Schiller NB. Septal bounce, vena cava plethora, and pericardial adhesion: informative two-dimensional echocardiographic signs in the diagnosis of pericardial constriction. *J Am Soc Echocardiogr* 1988; 1:333-340.
- Seward JB, Khandheria BK, Oh JK, et al. Transesophageal echocardiography: technique, anatomic correlations, implementation, and clinical applications. *Mayo Clin Proc* 1988; 63:649-680.
- Orihashi K, Goldiner PL, Oka Y. Intraoperative assessment of pulmonary vein flow. *Echocardiography* 1990; 7:261-271.
- Nishimura RA, Abel MD, Hatle LK, Tajik AJ. Relation of pulmonary vein to mitral flow velocities by transesophageal Doppler echocardiography. Effect of different loading conditions. *Circulation* 1990; 81:1488-1497.
- Pinto FJ, Wranne B, St FG, Schnitger I, Popp RL. Hepatic venous flow assessed by transesophageal echocardiography. *J Am Coll Cardiol* 1991; 17:1493-1498.
- Keren G, Sherez J, Megidish R, Levitt B, Laniado S. Pulmonary venous flow pattern—its relationship to cardiac dynamics. A pulsed Doppler echocardiographic study. *Circulation* 1985; 71:1105-1112.
- Klein AL, Burstow DJ, Taliercio CP, et al. Effects of age on pulmonary venous flow velocities in normal subjects [abstract]. *J Am Coll Cardiol* 1989; 13:50A.
- Klein AL, Burstow DJ, Zachariah PK, et al. Influence of age and phase of respiration on right ventricular diastolic function in normal subjects [abstract]. *J Am Soc Echocardiogr* 1990; 3:237.
- Nishimura R, Connolly DC, Parkin TW, Stanson AW. Constrictive pericarditis: assessment of current diagnostic procedures. *Mayo Clin Proc* 1985; 60:397-401.
- Schiavone WA, Rice TW. Pericardial disease: current diagnosis and management methods. *Cleve Clin J Med* 1989; 56:639-645.
- King SW, Pandian NG, Gardin JM. Doppler echocardiographic findings in pericardial tamponade and constriction. *Echocardiography* 1988; 5:361-372.
- Benotti JR, Grossman W, Cohn PF. Clinical profile of restrictive cardiomyopathy. *Circulation* 1980; 16:1206-1212.
- Shabetai R, Fowler NO, Guntheroth WG. The hemodynamics of cardiac tamponade and constrictive pericarditis. *Am J Cardiol* 1970; 26:480-489.
- Bush CA, Stang JM, Wooley CF, Kilman JW. Occult constrictive pericardial disease. Diagnosis by rapid volume expansion and correction by pericardiectomy. *Circulation* 1977; 56:924-930.
- Lewis BS. Real time two dimensional echocardiography in constrictive pericarditis. *Am J Cardiol* 1982; 49:1789-1793.

28. Voelkel AG, Pietro DA, Follard ED, Fisher ML, Parisi AF. Echocardiographic features of constrictive pericarditis. *Circulation* 1978; 58:871-875.
29. Appleton CP, Hatle LK, Popp RL. Demonstration of restrictive ventricular physiology by Doppler echocardiography. *J Am Coll Cardiol* 1988; 11:757-768.
30. Appleton CP, Hatle LK, Popp RL. Relation of transmitral flow velocity patterns to left ventricular diastolic function: new insights from a combined hemodynamic and Doppler echocardiographic study. *J Am Coll Cardiol* 1988; 12:426-440.
31. Appleton CP, Hatle LK, Popp RL. Central venous flow velocity patterns can differentiate constrictive pericarditis from restrictive cardiomyopathy [abstract]. *J Am Coll Cardiol* 1987; 9:119A.
32. Schiavone WA, Calafiore PA, Salcedo EE. Transesophageal Doppler echocardiographic demonstration of pulmonary venous flow velocity in restrictive cardiomyopathy and constrictive pericarditis. *Am J Cardiol* 1989; 63:1286-1288.
33. Klein AL, Cohen GI, Pietrolungo JF, et al. Respiratory changes in pulmonary venous flow distinguish constrictive pericarditis from restrictive cardiomyopathy [abstract]. *Circulation* 1991; 84 Suppl II:5.
34. Santamore WP, Bartlett R, Van Buren SJ, Dowd MK, Kutcher MA. Ventricular coupling in constrictive pericarditis. *Circulation* 1986; 74:597-602.
35. Kyle RA, Greipp PR. Amyloidosis (AL). Clinical and laboratory features in 229 cases. *Mayo Clin Proc* 1983; 58:665-683.
36. Ziady GM, Raphael MJ, Oakley CM. The function and defect of amyloid heart disease: the stiff heart syndrome. *Am J Cardiol* 1975; 36:438-444.
37. Meaney E, Shabetai R, Bhargava V, et al. Cardiac amyloidosis, constrictive pericarditis, and restrictive cardiomyopathy. *Am J Cardiol* 1976; 38:547-556.
38. Swanton RH, Brooksby IA, Davies MJ, Coltart DJ, Jenkins BS, Webb-Peploe MM. Systolic and diastolic ventricular function in cardiac amyloidosis. Studies in 6 cases diagnosed with endomyocardial biopsy. *Am J Cardiol* 1977; 39:658-664.
39. Cueto-Garcia L, Reeder GS, Kyle RA, et al. Echocardiographic findings in systemic amyloidosis: spectrum of cardiac involvement and relation to survival. *J Am Coll Cardiol* 1985; 6:737-743.
40. St. John Sutton MJ, Reichel N, Kastor JA, Giulini ER. Computerized M-mode echocardiographic analysis of left ventricular dysfunction in cardiac amyloid. *Circulation* 1982; 66:790-799.
41. Tyberg TI, Goodyer AV, Hurst VW, Alexander J, Langou RA. Left ventricular filling in differentiating restrictive amyloid cardiomyopathy and constrictive pericarditis. *Am J Cardiol* 1981; 47:791-796.
42. Spodick DH. The normal and diseased pericardium: current concepts of pericardial physiology, diagnosis and treatment. *J Am Coll Cardiol* 1983; 1:240-251.
43. Schiller NB, Borvinick EH. Right ventricular compression as a sign of cardiac tamponade: an analysis of echocardiographic ventricular dimensions and their clinical implications. *Circulation* 1977; 56:774-779.
44. Armstrong WF, Schilt BF, Helper DJ, Dillon JC, Feigenbaum H. Diastolic collapse of the right ventricle with cardiac tamponade: an echocardiographic study. *Circulation* 1982; 65:1491-1496.
45. Gillam LD, Guyer DE, Gibson TC, King ME, Marshall JE, Weyman AE. Hemodynamic compression of the right atrium: a new echocardiographic sign of cardiac tamponade. *Circulation* 1983; 68:294-301.
46. Singh S, Waan LS, Schuchard GH, et al. Right ventricular and right atrial collapse in patients with cardiac tamponade: a combined hemodynamic and echocardiographic study. *Circulation* 1984; 70:966-971.
47. Klopstein HS. The pathophysiology of pericardial disease: contributions derived from echocardiography/Doppler studies in animal models. *Echocardiography* 1990; 7:5-9.
48. Hoit BD, Gabel M, Fowler NO. Cardiac tamponade in left ventricular dysfunction. *Circulation* 1990; 82:1370-1376.
49. Himelman RB, Kircher B, Rockey DC, Schiller NB. Inferior vena cava plethora with blunted respiratory response; a sensitive echocardiographic sign of cardiac tamponade. *J Am Coll Cardiol* 1988; 12:1470-1477.
50. Schutzman JJ, Klein AL, Obarski TP, Pearce GL, Salcedo EE. Echo-Doppler assessment of pericardial effusion: a comparison of Doppler to two-dimensional echocardiographic techniques [abstract]. *Circulation* 1990; 82 Suppl II:28.
51. Fowler NO. The significance of echocardiographic-Doppler studies in cardiac tamponade. *J Am Coll Cardiol* 1988; 11:1031-1033.
52. Shabetai R, Fowler NO, Fenton JC, Masangkay M. Pulsus paradoxus. *J Clin Invest* 1965; 44:1882-1890.
53. Gauchat HW, Katz LN. Observations of pulsus paradoxus (with special reference to pericardial effusions) I. Clinical. *Arch Intern Med* 1924; 33:371-393.
54. Katz LN, Gauchat HW. Observations of pulsus paradoxus (with special reference to pericardial effusions) II. Experimental. *Arch Intern Med* 1924; 33:371-393.
55. Hoit B, Sahn DJ, Shabetai R. Doppler-detected paradoxus of mitral and tricuspid valve flows in chronic lung disease. *J Am Coll Cardiol* 1986; 8:706-709.
56. Hayes SN, Freeman WK, Gersh BJ. Low pressure cardiac tamponade diagnosis facilitated by Doppler echocardiography. *Br Heart J* 1990; 63:136-140.
57. Schwartz SL, Pandian NG, Kusay BS, et al. Real-time intracardiac two-dimensional echocardiography: an experimental study of in vivo feasibility; imaging planes, and echocardiographic anatomy. *Echocardiography* 1990; 7:443-455.