

A practical approach to coma diagnosis in the unresponsive patient

MARTIN A. SAMUELS, MD

■ Diagnosis of coma in the unresponsive patient can be done in a relatively short time by making key observations that will confirm disease of either the brain stem or the hemispheres, the two locations in which coma originates. Determining the location of the lesion is the primary goal in early assessment of the unresponsive patient. Examination of the patient's eyes is the single most important step in understanding coma.

□ INDEX TERMS: UNCONSCIOUSNESS; BRAIN STEM; EYE MANIFESTATIONS; □ CLEVE CLIN J MED 1992; 59:257-261

DIAGNOSIS OF THE unresponsive patient is a major issue in the practice of neurological medicine, internal medicine, and emergency medicine. If the patient is in a coma, the disease is either in the ascending reticular activating system (a diffuse array of nuclei and tracts extending from the brain stem to the thalamus), or the disease is bilateral and diffuse in the hemispheres. In assessing an unconscious person, the primary goal is to determine the location of the lesion. Certain simple observations made in an orderly fashion will provide the information necessary for a diagnosis in an hour's time.

DEGREES OF UNCONSCIOUSNESS

The unresponsive patient may be at any depth of unconsciousness along a spectrum from nearly alert to

coma, the deepest level of unconsciousness. The variations in a patient's mental status along the spectrum are somewhat analogous to the conditions produced by anesthesia. The first signpost is confusion or inattention, the inability to maintain a coherent stream of thought or action. The ability to count backwards by sevens from 100 (the "serial sevens" test) is a classic test of attention. Drugs, toxins, and metabolic encephalopathy can cause inattention or confusion, which is the most common abnormality in mental status seen in a general hospital setting. Generally, the cause can be attributed to drugs.

The next step toward coma is drowsiness, the state of apparent sleep that is overcome with a verbal command. A still greater degree of unconsciousness is stupor, in which the patient looks asleep, cannot be aroused by a verbal command, but responds to a painful or noxious stimulus. Placing a small piece of cotton inside the patient's nostril will produce the necessary stimulus, as well as provide a means for assessing the motor system of the comatose person.

The greatest degree of unconsciousness is coma, in which a stimulus produces either a reflex response or no response at all. When a stimulus elicits antigravity

From the Department of Neurology, Harvard Medical School, Boston.

Address reprint requests to M.S., Division of Neurology, Brigham and Women's Hospital, 75 Francis Street, Boston, MA 02115.

*This article was adapted from a talk given at The Cleveland Clinic Foundation's "Intensive Review of Internal Medicine"

posturing from the comatose person, the response could indicate either decerebration or decortication, or both. In humans, the location of lesions in decerebration or decortication is not well defined, but both are common in coma caused by brain stem pathology.

Finally, pseudocoma, or hysterical coma, is a condition in which the patient is in a deep trance and cannot be aroused by painful stimuli. A coma for which there is no physiological cause, pseudocoma is diagnosed by excluding all known causes of coma.

CHARACTERISTICS OF COMA

Consciousness is characterized by two qualities: (1) wakefulness, which is regulated by nuclei in the core of the brain stem, and (2) awareness, which is controlled in the cortex, bilaterally and diffusely. Conversely, unconsciousness has two qualities: (1) permanent unwakefulness and/or (2) lack of awareness. Accordingly, there are only two causes of unconsciousness: (1) brain stem coma, which looks like sleep and renders a patient incapable of arousal, and (2) bilateral hemisphere disease, in which the patient looks awake but is neither aware nor able to respond in any way to any stimulus. The latter, which may be termed “hemisphere coma,” is often regarded as a “vegetative state.”

From a practical perspective, determining whether the patient looks awake or asleep is the first observation to be made, for it reveals something about the underlying pathogenesis of unresponsiveness. In assessing unresponsive patients, two important points should be stressed. First, assume that the unresponsive patient can hear every word that you speak. Second, never move the head or neck of an unresponsive patient, awake or asleep, until the possibility of a neck injury has been ruled out.

Unresponsive, with open eyes

Although the unresponsive patient who appears to be asleep is the type of patient commonly seen, it is appropriate to discuss the unresponsive patient whose eyes are open and who appears to be awake. The unresponsive patient who appears to be awake is actually in a state of akinetic mutism, which may be attributed to one of three syndromes—abulia, psychiatric diseases, and locked-in syndromes.

Abulia is the absence of effervescence and spontaneity. The abulic patient will respond in a slow, viscous manner, with long delays between the question and answer. Abulia of varying degrees can be caused by a number of conditions, including hydrocephalus, frontal meningioma, metastatic or primary tumors, hemorrhages in the brain, and contusions. Prefrontal lobe disease, usually bilateral, tends to produce abulia. An unusual and unexplained characteristic of abulic patients is their ability to carry on a telephone conversation, even though they are unable to talk face-to-face. This phenomenon is called the “telephone sign” and is almost pathognomonic of frontal lobe trouble. In this situation, the clinician can resort to taking a history via telephone.

Among psychiatric conditions, only catatonia and the dissociative state can produce akinetic mutism. Catatonic schizophrenia, once a common disease and still prevalent in developing countries, is now very rare in industrialized societies. A century ago, catatonic schizophrenics existing in states of waxy rigidity as immobilized akinetic mutes were a common sight in mental hospitals. Today, however, catatonia is generally produced by severe depression.

The dissociative state, in which part of the personality is split off from the rest, can produce hysterical mutism. Such patients may believe that a weakness of their nervous system renders them incapable of speaking above a whisper. Speech therapy over a period of several weeks may “give the patient a way out” and restore the ability to speak.

The “locked-in” syndromes refer to patients who are paralyzed and are, in fact, awake. The classic condition is the pontine infarct, but high cervical spinal cord injuries and severe dystonias from drugs like prochlorperazine can also cause paralysis and acute loss of function.

The “locked-in” syndromes refer to patients who are paralyzed and are, in fact, awake. The classic condition is the pontine infarct, but high cervical spinal cord injuries and severe dystonias from drugs like prochlorperazine can also cause paralysis and acute loss of function.

DIAGNOSIS OF THE COMATOSE PATIENT

The history

In dealing with a comatose patient, who is incapable of providing a history, it is important to find family, police, ambulance personnel, or anyone who can provide the answers to key questions in the history. How rapid was the onset? Are there possible drugs or toxins? Has this happened before?

Studies have shown that drugs and toxins are the most common causes of coma in emergency departments, regardless of socioeconomic status. All drugs—over-the-counter, prescription, and illegal, including alcohol—taken singly or in combination, are suspect.

Trauma, fever, and headaches are all obvious clues in the diagnosis of coma. The trauma that occurred in the recent past, however, is an important part of the history that must be provided by family or friends. The

simple question "Any theories?" can often elicit vital information from family members.

Examination of the patient

If the history has failed to differentiate between hemisphere disease and brain stem disease, an evaluation of brain stem functions is the appropriate next step in the examination of the comatose patient.

The brain stem sets posture. If, therefore, the patient looks comfortable, the brain stem is not involved. On the other hand, a patient who looks uncomfortable is likely to have a brain stem problem. This is an important triage point and one that can be made by radio communication with an emergency medical technician in the field.

Respiratory patterns are useful in the diagnosis of the source of the coma. Cheyne-Stokes breathing is a complicated respiratory pattern that is not seen in the critically ill patient with brain stem disease. One must consider hyperventilation as the nervous system's effort to compensate for systemic acidosis, but hyperventilation per se does not provide information to localize the problem.

Apneustic breathing, on the other hand, is an unequivocal brain stem pattern characterized by a deep inspiration followed by a long pause—the "inspiratory cramp"—and a slow expiratory phase, with perhaps five cycles per minute. Even more critical is ataxic breathing, which is a grave sign of brain stem failure. Both apneustic and ataxic breathing call for intubation.

Finally, automatisms are measures of brain stem function. Although coughing, swallowing, and hiccuping are nonspecific automatisms, yawning and sneezing are not present in the patient with brain stem disease.

Quite simply, then, a patient who looks comfortable, has normal or Cheyne-Stokes breathing, and yawns spontaneously probably has good brain stem function. On the other hand, uncomfortable-looking posture, apneustic breathing, and occasional swallows or coughs suggest brain stem failure and the need for intubation.

Examination of the cranial nerves is the final step in determining the location of the impairment. In the comatose patient, observation of pupillary reaction and eye movements will provide the necessary information. Indeed, examination of the patient's eyes is the single most important step in understanding coma. The shape and size of the pupils and their reaction to direct and consensual light should be recorded.

Testing for eye movements

The eye movements come from the brain stem. It follows, therefore, that if the eyes are moving, the brain stem is intact. However, if the eyes are roving, with rapid and smooth motion, a loss of inhibition resulting from bihemisphere coma is indicated. On the other hand, if the eyes aren't moving, it will be necessary to make them move. Since one must never turn the head of a comatose patient, it is impossible to use the doll's head maneuver to test the vestibular ocular reflex, which tends to turn the eyes in the direction opposite that in which the head is turned. The alternative practice of putting ice water in one ear inactivates the vestibular system on that side for about 30 to 40 seconds, thus achieving the same effect as that of turning the head.

The diagnosis of the comatose patient with no eye movement can be accomplished by putting 50 mL of ice water in the left ear and observing any eye movement. If the brain stem is normal, the eyes will turn conjugately and fully toward the side of the ice water infusion in what is the slow phase of the eye movement. If the hemispheres are functioning, the slow phase will be followed by a fast phase in which the eyes come jerking back to the right. Likewise, ice water infused into the right ear will effect eye movement to the right during the slow phase and a jerking movement to the left during the fast phase in the patient who has neither brain stem coma nor hemisphere coma.

Thus, ice water caloric-induced nystagmus, in which the slow phase is driven by the brain stem and the fast phase is driven by the cortex, is the perfect test of a comatose patient in whom the differential diagnosis is brain stem coma vs hemisphere coma. Furthermore, it is the perfect test for hysterical coma, a condition that can generally be reversed by the power of suggestion.

Other diagnostic observations

In the unresponsive patient with a dilating pupil (called Hutchinson's pupil), the dilating pupil is always on the side of the herniating mass. Hutchinson's pupil indicates a surgical emergency.

When a patient has good pupillary reaction and poor eye movements, a drug is likely to be involved. A sedative (eg, benzodiazepine) plus alcohol, a barbiturate plus alcohol, or some combination of these products is a highly possible cause of unresponsiveness.

If there is the slightest reason to suspect meningitis, the spinal fluid of a comatose patient should be checked. If a radiologic image can be obtained in a matter of

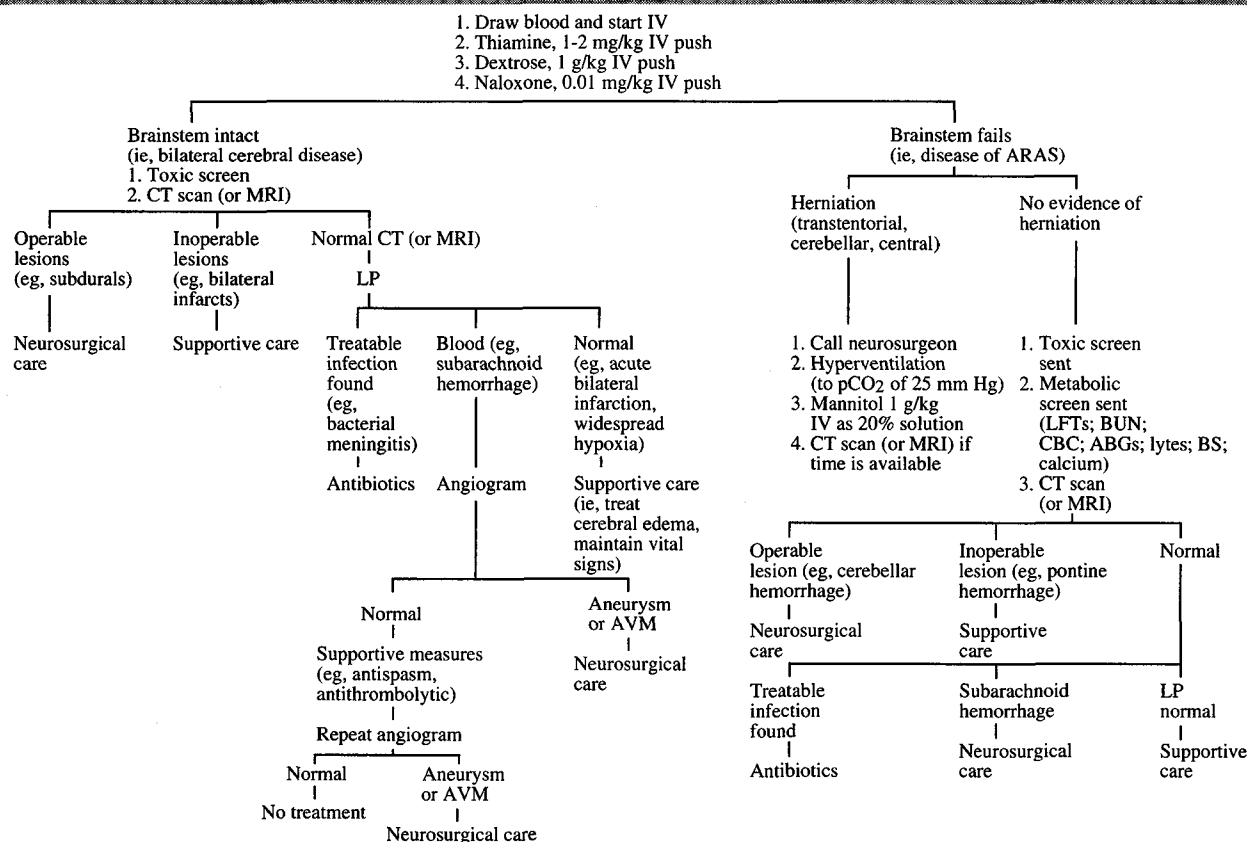


FIGURE. Diagnosis and treatment protocol in the comatose patient. (From: Samuels MA, ed. *Manual of neurologic therapeutics*. 4th ed. Boston: Little, Brown and Company, 1991. Reprinted with permission)

a few minutes, that should precede the spinal tap; however, if several hours will be required to get an image, proceed with the spinal tap immediately. More people die when a spinal tap is not done than die when it is done.

Unnecessary procedures

An electroencephalogram (EEG) is almost never called for in an emergency department, and certainly not before testing for blood levels of barbiturates and allowing time to pass. Brain death is not diagnosed in an emergency department.

Testing for reflexes is not particularly useful in diagnosing coma. Proprioceptive (deep tendon) reflexes are tests of the peripheral nerve, the root, and the spinal cord, but not of the brain stem or the hemispheres. One is unable to test coordination in unconscious people.

The Glasgow coma scale was invented for trauma research and is not a very useful measure of non-

traumatic comas.

PROTOCOL FOR DIAGNOSIS AND TREATMENT

Assume that certain basic procedures—clearing of the airway, application of a collar to immobilize the neck, intubation—have been carried out by emergency personnel in the field or in the emergency department. The treatment of every unresponsive patient begins with steps 1 through 4 of the accompanying protocol flowchart (Figure). If the coma does not reverse, a history is obtained, and the patient is examined in the manner described in this article. On the basis of information obtained from the history and physical examination, the clinician determines whether or not the brain stem is intact. Depending on the state of the brain stem, a protocol in the accompanying flowchart is selected. In this manner, the definitive diagnosis is made and appropriate treatment is determined.

BIBLIOGRAPHY

- Anch A, Browman CP, Mitler MM. Sleep, a scientific perspective. Englewood Cliffs, New Jersey: Prentice Hall, 1988.
- Fisher CM. The neurological evaluation of the comatose patient. *Acta Neurol Scand* 1969; **1**(Suppl 36):56.
- Fishman RA. Brain edema. *N Engl J Med* 1975; **293**:706.
- Levy DE, et al. Predicting outcome from hypoxic-ischemic coma. *JAMA* 1985; **253**:1420.
- Matheson JK. Sleep and its disorders. In: Stein JH, ed. *Internal medicine*. 3rd ed. Boston: Little, Brown, 1990:1904-1912.
- Plum F, Posner JB. *Diagnosis of stupor and coma*. 3rd ed. Philadelphia: Davis, 1980.
- Rockoff MA, Marshall LF, Shapiro HM. High dose barbiturate therapy in humans: a clinical review of 60 patients. *Ann Neurol* 1978; **6**:194.
- Ropper AH, Kennedy SK, Zervas NT. *Neurological and neurosurgical intensive care*. Baltimore: University Park Press, 1983.

