



Catheter ablation for recurrent ventricular tachycardia

RONALD McCOWAN, MD; BRUCE L. WILKOFF, MD; HUGH McALISTER, MB, ChB; TONY W. SIMMONS, MD

■ A 78-year-old man had sustained ventricular tachycardia refractory to drug therapy. An antitachycardia pacemaker and a cardioverter-defibrillator were implanted. It was suspected that rate crossover was occurring between his sinus rhythm and his antitachycardia pacemaker detection rate. He also had frequent discharges from his implantable cardioverter-defibrillator. Because of these problems, he was considered a candidate for catheter ablation treatment of his ventricular tachycardia. The procedure was completed successfully and long-term follow-up has been uneventful. Catheter ablation is recommended as a treatment option for patients who have ventricular tachycardia that is refractory to drug therapy and combined-device therapy, and who have rate crossover.

□ INDEX TERMS: CATHETER ABLATION; TACHYCARDIA, VENTRICULAR □ CLEVELAND CLIN J MED 1992; 59:203-207

TODAY'S TREATMENT options for sustained ventricular tachycardia (VT) include the implantation of an antitachycardia pacemaker.^{1,2} Such a device may provide rapid, well-tolerated treatment and may obviate the need for antiarrhythmic medications.

Because of the considerable risk of pacing-induced VT acceleration,^{3,4} a cardioverter-defibrillator is usually implanted along with the antitachycardia pacemaker.⁵ The indications for device combination are VT rates below the implantable defibrillator cutoff rate and frequent pace-terminable VT.

Some patients continue to have frequent spontaneous VT despite the implantation of these devices and the concomitant use of antiarrhythmic medica-

tions. The associated pacing-induced VT acceleration, rapid VT, or both, may lead to an increased number of defibrillator shocks. Adjustments in antiarrhythmic medications may or may not decrease the frequency of recurrent VT.

Spontaneous VT that has a slow rate requires that the pacemaker be programmed at a low tachycardia detection rate. In that setting, when the sinus rate exceeds the tachycardia detection rate, rate crossover may occur, and pacemaker stimuli may then induce VT. Rate crossover may be difficult to eliminate with adjustment of antiarrhythmic medications and pacemaker programming. The treatment of last resort is either surgical or catheter ablation of the VT focus (or foci).

Between January 1987 and January 1989, nine patients underwent catheter ablation at The Cleveland Clinic Foundation for treatment of drug-refractory VT. Three patients had implanted antitachycardia devices: an antitachycardia pacemaker (one patient), an implantable defibrillator (one

From the Department of Cardiology, The Cleveland Clinic Foundation.

Address reprint requests to T.W.S., Department of Cardiology, F-15, The Cleveland Clinic Foundation, 9500 Euclid Avenue, Cleveland, OH 44195.

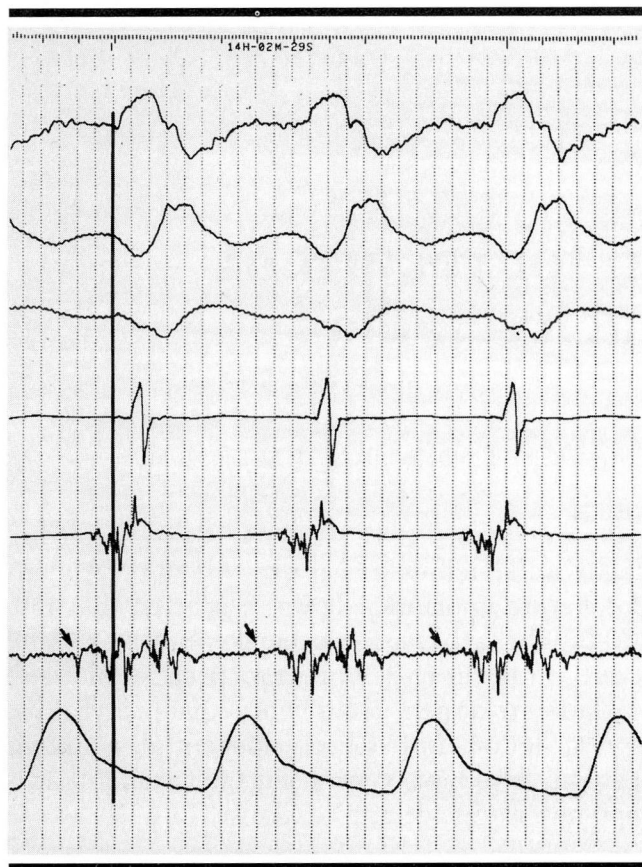


FIGURE 1. Diastolic fractionated electrogram (arrows) was recorded from the inferior apical region of the left ventricle during ventricular tachycardia. The electrogram occurred 100 milliseconds before the onset of the QRS.

patient), and both an implantable defibrillator and antitachycardia pacemaker (one patient). Catheter ablation in the last patient is described in this report.

CASE REPORT

A 78-year-old man with a history of remote myocardial infarction, ischemic cardiomyopathy with severe left ventricular dysfunction, and coronary bypass graft surgery presented in March 1987 with sustained, hemodynamically stable VT. The rate was 109 to 115 beats per minute (bpm). The episode of VT occurred while the patient was taking a type IA antiarrhythmic drug.

Following electrophysiologic study with serial drug testing, oral amiodarone was started and, 1 month later, discontinued because of gastrointestinal side effects. Given the absence of a ventricular aneurysm, VT

surgery was not considered a treatment option; however, an antitachycardia pacemaker (Intertach #262-14; Intermedics Inc, Freeport, Tex) was implanted along with a cardioverter-defibrillator (#1520, rate cutoff 172 bpm; CPI, St Paul, Minn). The patient's tachycardia was easily terminated with pacing techniques, but defibrillator implantation was necessary to manage possible pacing-induced tachycardia acceleration.

The pacemaker tachycardia detection rate was set at 105 bpm. Encainide, 35 mg tid, and mexiletine, 200 mg tid, were prescribed to control the recurrence of tachycardia. On this regimen, the patient continued to have spontaneous VT with rates of 130 to 140 bpm; at one point, he received nine defibrillator shocks over a 24-hour period.

Because of the possibility of rate crossover with subsequent induction of VT, the pacemaker detection rate was reset to 120 bpm. The antiarrhythmic drugs were not thought to be proarrhythmic, but the mexiletine was discontinued in order to allow for a more rapid spontaneous VT rate.

Subsequently, the patient had an exercise treadmill test, during which his sinus rate increased to a maximum of 118 bpm. The antitachycardia pacemaker detection rate was then increased to 125 bpm. Three days later, an episode of VT was terminated by a single defibrillator shock.

Metoprolol, 25 mg/day, was started and then discontinued because of dyspnea. The defibrillator again discharged 1 week later. A magnet test indicated first and second charge times of 9 seconds (exceeded the elective replacement indicator charge time) with a shock count of 19. Three weeks earlier the charge time had been 6.4 seconds.

The defibrillator pulse generator was subsequently replaced (CPI, #1510, rate cutoff 172 bpm). One week later the patient had recurrent VT at 114 bpm. The pacemaker did not terminate the tachycardia until after lidocaine infusion. The patient was transferred to this institution for further management.

Admission findings

On arrival the patient had VT, 115 to 120 bpm. His blood pressure was 132/94 mm Hg. The tachycardia response of the pacemaker was reprogrammed with subsequent termination of the VT.

Physical examination revealed no jugular venous distention, minimal end-inspiratory rales over the left posterior lung base, and a fourth heart sound. The serum electrolytes were normal; the digoxin level was

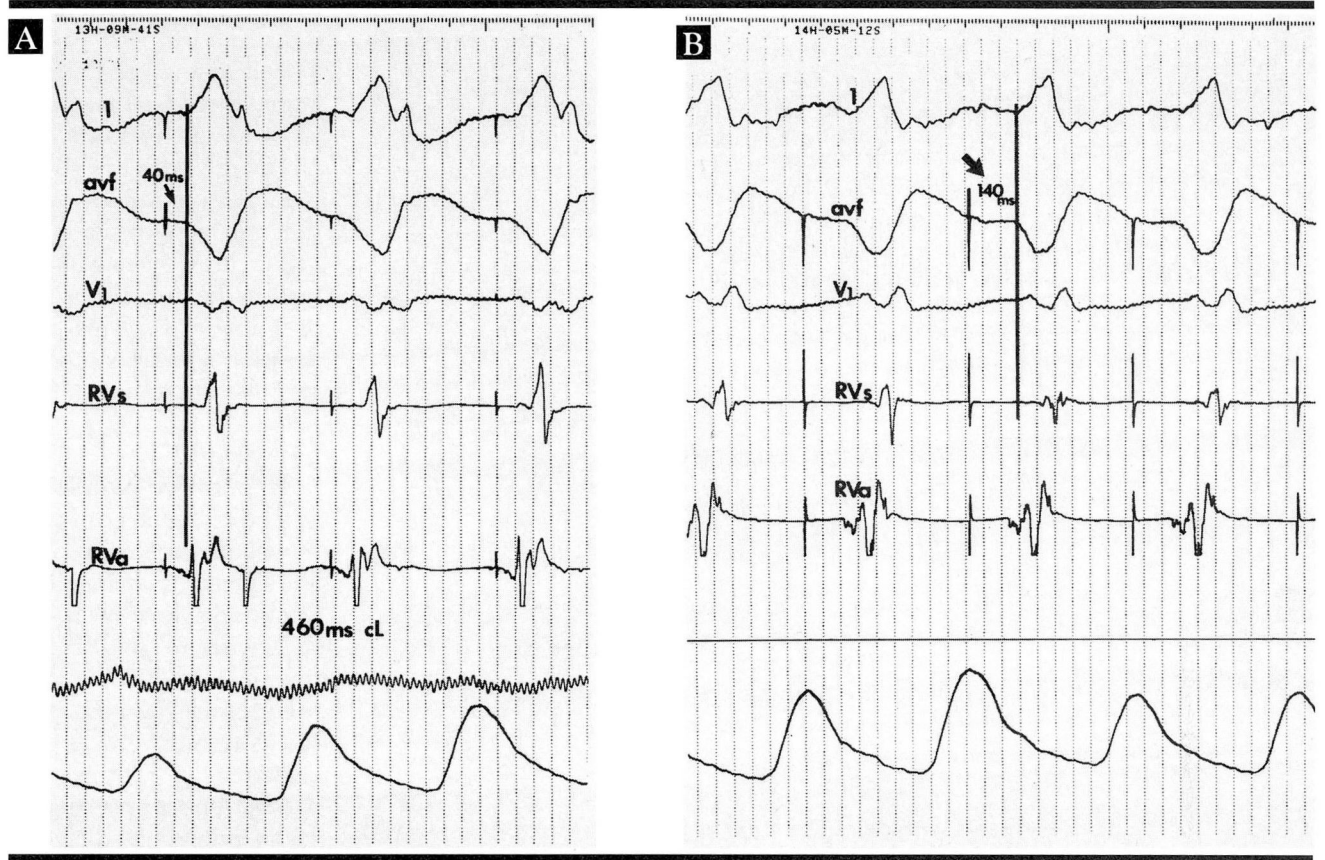


FIGURE 2. Left ventricular pace-mapping (A) at the inferior apical region of the left ventricle. The stimulus to response interval (B) is delayed by 100 milliseconds (arrow) with pacing at the posterior interventricular septum.

0.4 ng/mL (therapeutic level, 0.3 to 1.9); and the mexiletine level was 0.9 μ g/mL (therapeutic level, 0.8 to 2.0). An echocardiogram showed severe global left ventricular dysfunction.

The patient had no history of syncope or cardiac arrest, but during prolonged episodes of VT, symptoms of heart failure developed. The patient was considered to be a candidate for catheter ablation because of recurrent drug-refractory VT, rate crossover, and frequent defibrillator shocks.

Ablation procedure

Following cessation of antiarrhythmic drug therapy for 48 hours, electrophysiologic study was performed. The implantable defibrillator and the pacemaker were inactivated. Quadripolar catheters were positioned at the right ventricular apex and the right ventricular septum. A bipolar catheter was passed into the left ventricle. All catheters had been assessed preopera-

tively for electrical integrity. After all catheters were in place, heparin, 5,000 U, was given intravenously followed by 1,000 U each hour thereafter. Ventricular tachycardia was easily induced with single and double ventricular extrastimuli during sinus rhythm.

Catheter activation mapping of both ventricles was performed. Early activation during the VT was initially noted at the inferior wall of the left ventricle approximately 1 cm from the apex (Figure 1). A 300-J shock of synchronized direct current was delivered between the distal pole (cathode) of the left ventricular catheter and the R2 pad (R2 Corp, Skokie, Ill [anode]) on the patient's back. A second synchronized shock of 200 J was delivered in the same configuration. VT remained inducible.

Further mapping of the left ventricle revealed earlier activation at the mid-portion of the posterior interventricular septum. Pace-mapping at this site revealed increased latency consistent with pacing

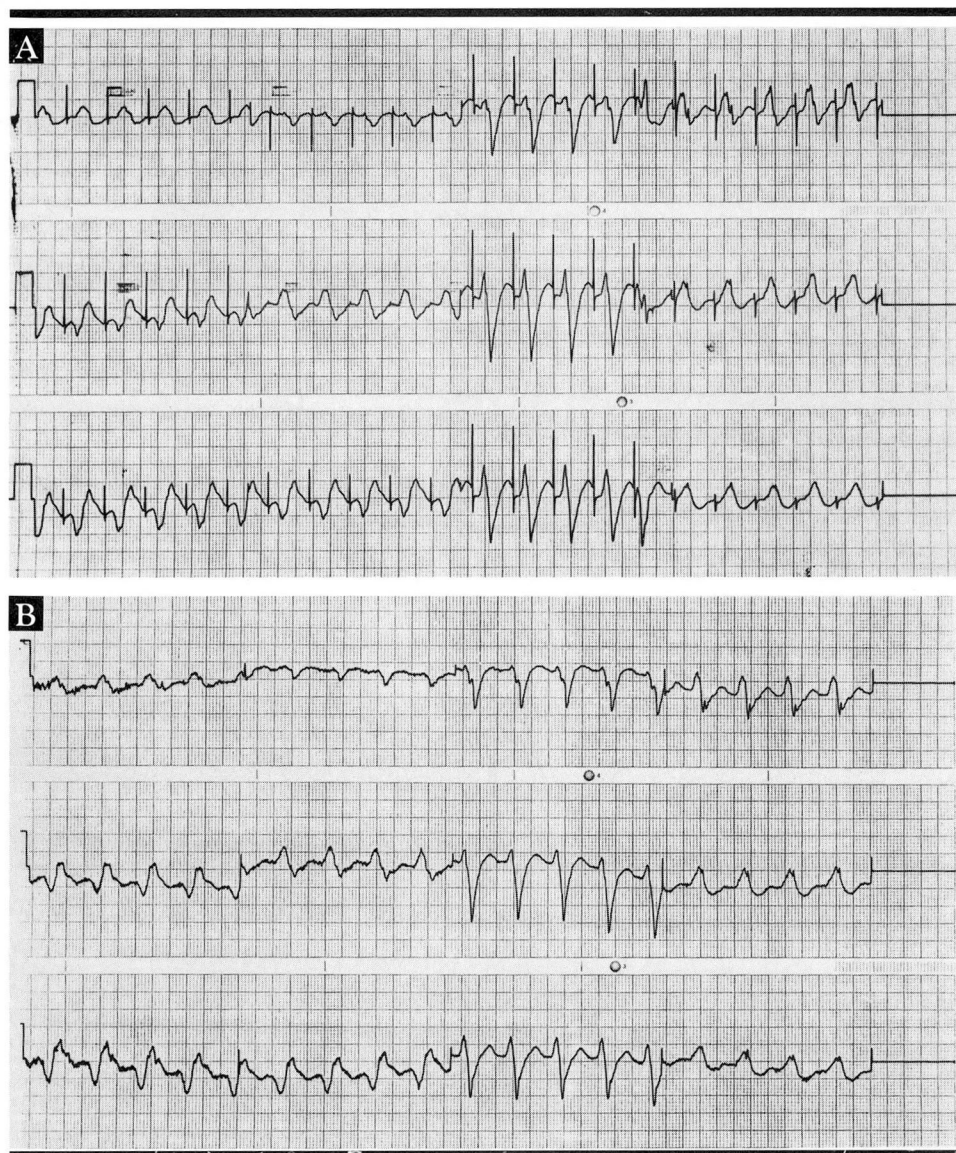


FIGURE 3. Pacing at the left posterior interventricular (A) septum demonstrated complete concordance with the clinical VT (B).

catheter proximity to an area of slow conduction (Figure 2). There was concordance between the clinical VT and pace-mapping in all 12 electrocardiographic leads (Figure 3). Two shocks (300 J and 200 J) were delivered to this area in the posterior interventricular septum. A third shock of 300 J was delivered to the area transeptally, between the left and right ventricular catheters. Ventricular tachycardia was no longer inducible.

Immediately following catheter ablation,

ventricular fibrillation was induced with burst pacing. The implantable defibrillator sensed and terminated the arrhythmia appropriately with one shock. Noninvasive assessment of the antitachycardia pacemaker lead revealed satisfactory pacing thresholds of 2.7 V at 0.27-ms pulse duration and 5.4 V at 0.12-ms pulse duration.

Uneventful postoperative course

The patient's postoperative course was uneventful. The peak creatine phosphokinase level was 427 IU/L with a 26% MB fraction. No spontaneous VT occurred in the postoperative course. Five days after catheter ablation, the patient underwent noninvasive programmed electrical stimulation using the antitachycardia pacemaker. A sustained VT of multiple morphologies was induced using a 400-cycle-length drive train with triple extrastimuli. The tachycardia was recognized and terminated by the antitachycardia pacemaker on the first attempt.

The patient was discharged from the hospital on encainide and mexi-

etine. At a follow-up of 5 months, the patient had had no defibrillator shocks or clinical recurrence of VT.

DISCUSSION

Catheter ablation as a therapeutic intervention for recurrent sustained VT is a recent addition to the available treatment modalities. The first patients who underwent catheter ablation for VT were reported in 1983.⁶ There are few reports of catheter ablation for

recurrent VT in patients with implanted antitachycardia devices. Of 88 patients who underwent catheter ablation for VT,⁷ only 4 had antitachycardia pacemakers and 2 had implantable cardioverter-defibrillators. Morady and colleagues⁸ reported 2 patients with antitachycardia devices in their series of 33 patients undergoing catheter ablation.

In our case, catheter ablation is presented as a possible solution to the problems of recurrent drug-refractory slow VT and rate crossover in a patient with both an antitachycardia pacemaker and a defibrillator.

Potential limitations

Catheter ablation may adversely affect the function of implanted pacemakers. Transient and chronic elevations in stimulation threshold, with failure to capture, may occur. Loss of telemetric function and pacemaker reprogramming have also been reported.⁹

No immediate or delayed adverse affects were noted with our patient's antitachycardia pacemaker. This may be related to the ability to program the pacemaker to the 000 mode and turn off the sense amplifiers. Although there have been no reports of implantable defibrillator damage as a result of catheter ablation, some investigators have suggested temporary disconnection of the pulse generator before ablation.¹⁰

Recommendations

The immediate and long-term ablation success in this patient might be related to the ability to localize and ablate an area of slow conduction. Ablation of a critical slow-conduction zone is thought to provide better VT control than ablation of the site of earliest activation.¹¹ The use of catheters previously assessed for electrical integrity may also contribute to the success of the procedure.

Catheter ablation is an alternative therapy for refractory VT in patients not considered candidates for an operative procedure. Success rates of 56% have been reported. The addition of antiarrhythmic medications increases the rate to 85% to 90%.^{10,12} Prior to the ablation procedure, implanted pacemakers should be programmed off or to the simplest backup pacing mode; and following ablation, pacemaker function and lead integrity should be assessed. The same protocol should be adhered to for implantable defibrillators.

Although the follow-up of the patient presented in this report is limited to 5 months, the ablative procedure achieved marked improvement in the clinical course. Catheter ablation should be considered in the small group of patients with combined antitachycardia devices who present with refractory slow VT and rate crossover.

REFERENCES

1. Fisher JD, Johnston DR, Kim SG, Furman S, Mercando AM. Implantable pacers for tachycardia termination: stimulation techniques and long term-efficacy. *PACE* 1986; 9:1325-1333.
2. Fisher JD, Kim SG, Matos JA, Ostrow E. Comparative effectiveness of pacing techniques for termination of well-tolerated sustained ventricular tachycardia. *PACE* 1983; 6:915-922.
3. Fisher JD, Mehra R, and Furman S. Termination of ventricular tachycardia with bursts of rapid ventricular pacing. *Am J Cardiol* 1978; 41:94-102.
4. Holley LK, Cooper M, Uther JB, Ross D. Safety and efficacy of pacing for ventricular tachycardia. *PACE* 1986; 9:1316-19.
5. Masterson M, Maloney JD, Wilkoff B, et al. Automatic antitachycardia pacemaker and the automatic implantable cardioverter defibrillator as therapy for recurrent drug refractory ventricular tachycardia [abstract]. *J Am Coll Cardiol* 1988; 11(Suppl):17A.
6. Hartzler GD. Electrode catheter ablation of refractory focal ventricular tachycardia. *J Am Coll Cardiol* 1983; 2:1107-13.
7. Evans GT Jr, Scheinman MM, Zipes DP, et al. The percutaneous cardiac mapping and ablation registry: final summary of results. *PACE* 1988; 11:1621-26.
8. Morady F, Scheinman MM, Di Carlo LA Jr, et al. Catheter ablation of ventricular tachycardia with intracardiac shocks: results in 33 patients. *Circulation* 1987; 75:1037-1049.
9. Bowes RJ, Bennett DH. Effect of transvenous atrioventricular nodal ablation on the function of implanted pacemakers. *PACE* 1985; 8:811-814.
10. Fontaine G, Tonet JL, Frank R, Rougier I. Clinical experience with fulguration and antiarrhythmic therapy for the treatment of ventricular tachycardia. Long-term follow-up of 43 patients. *Chest* 1989; 95:785-797.
11. Fontaine G, Frank R, Tonet J, Grosogoeat Y. Identification of a zone of slow conduction appropriate for VT ablation: theoretical and practical considerations. *PACE* 1989; 12:262-267.
12. Haissaguerre M, Warin JF, Lemetayer P, Guillem JP, Blanchot P. Fulguration of ventricular tachycardia using high cumulative energy: results in thirty-one patients with a mean follow-up of twenty-seven months. *PACE* 1989; 12:245-251.