



Stereotactic biopsy of non-neoplastic lesions in adults

DONALD M. WHITING, MD; GENE H. BARNETT, MD; MELINDA L. ESTES, MD; CATHY A. SILA, MD; RICHARD A. RUDICK, MD; SAMUEL J. HASSENBUSCH, MD, PhD; CHARLES F. LANZIERI, MD

■ Stereotactic biopsy of intracranial lesions has been used primarily for the diagnosis of neoplastic lesions. A series of 158 consecutive stereotactic biopsies performed at The Cleveland Clinic Foundation resulted in 28 diagnoses of non-neoplastic disorders (18%). The majority of these were infectious, inflammatory, or demyelinating disorders. Stereotactic biopsy alone was diagnostic in 17 cases (61%), and biopsy in conjunction with clinical and laboratory data established definitive diagnoses in six cases (22%). All 23 definitive diagnoses led to modifications in patient management. Permanent neurologic morbidity occurred in only two patients (7%). We maintain that this procedure is underused. Stereotactic biopsy is safe, accurate, and useful for diagnosis of non-neoplastic neurologic disorders when the diagnosis is unclear by conventional means. In such cases, its use can lead to early diagnosis and treatment.

□ INDEX TERMS: STEREOTACTIC TECHNIQUES; BIOPSY □ CLEVE CLIN J MED 1992; 59:48-55

STEREOTACTIC NEUROSURGERY is commonly used to aid in the diagnosis and treatment of intracranial neoplasms. The most common and simple use of this technique is for diagnostic biopsy of radiographically evident lesions.

■ See commentary p. 55

Image-guided stereotactic brain biopsy has been proven to be accurate and safe for this purpose.¹⁻¹¹ In the vast majority of cases the lesions are suspected neoplasms.^{4,12-20} Occasionally, a lesion that preoperatively was believed to be a neoplasm is found upon

stereotactic biopsy to be non-neoplastic.^{12,16,17} However, the use of this technique to aid in the diagnosis of suspected non-neoplastic lesions has seldom been reported.

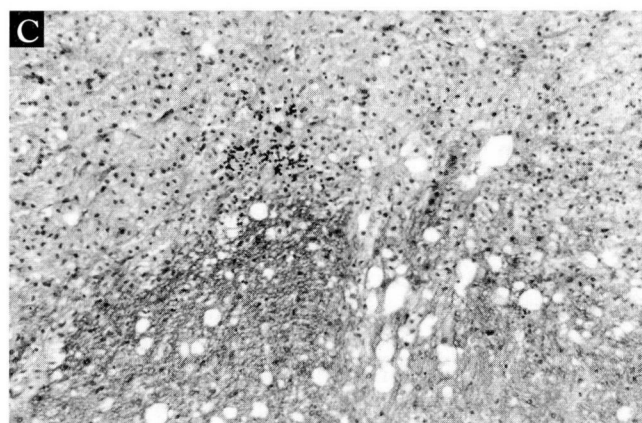
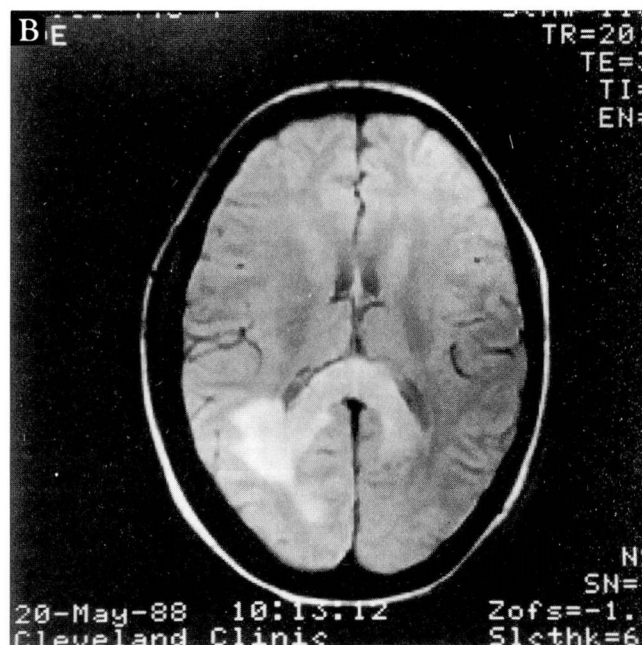
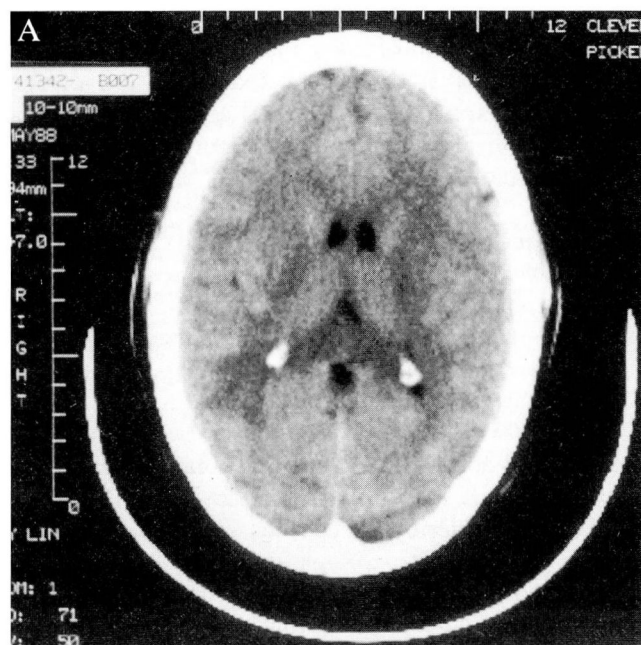
We present the Cleveland Clinic experience with image-directed biopsy of non-neoplastic lesions in adults. In the majority of these cases (79%) the lesion was believed preoperatively to be non-neoplastic. In fewer cases (21%), lesions which had been thought to be tumors were found to be non-neoplastic. Representative case histories are presented to illustrate the utility of this procedure. We contend that this technique is a useful adjunct in the diagnosis of many non-neoplastic disorders, and is as safe and accurate for non-neoplastic lesions as it is for those that are neoplastic.

METHODS

We reviewed the records of 158 consecutive patients who had stereotactic biopsy of radiographical-

From the Center for Computer Assisted Neurosurgery (G.H.B.), and the Departments of Neurosurgery (D.M.W., G.H.B., S.J.H.), Neurology (M.L.E., C.A.S., R.A.R.), Pathology (M.L.E.), and Neuroradiology (C.F.L.), The Cleveland Clinic Foundation.

Address reprint requests to G.H.B., Center for Computer Assisted Neurosurgery, The Cleveland Clinic Foundation, 9500 Euclid Avenue, Cleveland, OH 44195.



ly identified brain lesions performed at The Cleveland Clinic Foundation between June 1987 and November 1989. All patients age 18 or older who underwent stereotactic biopsy during this period were reviewed, regardless of preoperative or postoperative diagnosis. One neurosurgeon (G.H.B.) performed 86% of the procedures.

The stereotactic procedures used the Brown-Roberts-Wells or Cosman-Roberts-Wells stereotactic systems in conjunction with a Picker 1200 SX computed tomography (CT) scanner (Picker International, Solon, Ohio) and/or a General Electric Signa 1.5 Tesla magnetic resonance imager. A programmable Epson HX-20 computer was used to calculate arc angles for probe trajectories from coordinates acquired during the localization procedure. A side-cutting biopsy instrument was used to obtain 10-mm \times 1-mm specimens.

The stereotactic technique used was similar to that described by Apuzzo and others.^{12,16,17} Most procedures were performed under local anesthesia. At surgery, several fragments of tissue (typically 4 to 12) were obtained. A portion of each specimen was quick-frozen in liquid nitrogen, sectioned on a cryostat, and examined. Diagnosis of the frozen sections guided the need for obtaining additional specimens and adjusting the depth of biopsy.

The remaining tissue was divided and fixed in Hollande's fixative for paraffin embedding, or in 3.75%

FIGURE 1. (A) CT scan of the brain without contrast shows decreased attenuation in the corpus callosum and right parietal white matter. (B) Axial MRI shows thickening and increased signal within the splenium of the corpus callosum extending into the right parietal white matter (TR = 2010 ms, TE = 32 ms). (C) Section of lesion edge demonstrates a demyelinated area sharply demarcated from well-myelinated white matter. Numerous gitter cells, reactive astrocytes, and lymphocytes are seen within the demyelinated area (Luxol fast blue, hematoxylin-eosin, $\times 200$).

glutaraldehyde for high-resolution light microscopy and electron microscopy. Paraffin sections were cut 5- μ m thick, deparaffinized, and stained with hematoxylin-eosin. Sections were stained with Luxol fast blue/hematoxylin-eosin, Movat's pentachrome, and Masson trichrome where appropriate.

SELECTED CASE HISTORIES

The following case histories are selected from our study population. They represent examples of the use of stereotactic biopsy in the diagnosis of non-neoplastic lesions.

Case 1: multiple sclerosis

A 23-year-old white woman complained of blurred vision in the left eye, dizziness, and paresthesias in both hands extending proximally from left to right. These symptoms had been progressing over a period of 2 weeks. Her medical history was significant for an episode of head trauma 4 weeks earlier associated with the feeling of "blacking out," but without true loss of consciousness.

Visual field testing revealed a right homonymous inferior quadrantanopia. Rotatory nystagmus was present on primary and right gaze. Her gait was wide-based, and vibratory sensation was decreased in the feet and right hand. Muscle tone was increased in both lower limbs, and she had generalized hyperreflexia.

A CT scan of the head without intravenous contrast showed an area of decreased density in the right parietal white matter and a thickened splenium of the corpus callosum (Figure 1, A).

A few days later, the patient noted the onset of generalized "numbness." Examination now showed upbeat nystagmus, worsening of her spastic paraparesis, and bilateral astereognosis (tactile amnesia). A CT scan with contrast showed peripheral enhancement of the areas noted previously with minimal edema. Magnetic resonance imaging (MRI) demonstrated a thickened corpus callosum with increased signal on T2-weighted imaging (Figure 1, B), as well as increased signal in the right parietal white matter.

The lesion was thought to represent a tumor or, less likely, a zone of demyelination. Auditory and visual evoked potentials were normal, and cerebrospinal fluid analysis revealed a slight increase in daily central nervous system (CNS) immunoglobulin G synthesis.

CT-directed stereotactic biopsy of the right parieto-occipital lesion was performed. Histopathological examination revealed demyelination and perivascular inflammation consistent with multiple sclerosis. Hematoxylin-eosin-stained sections from the center of the lesion demonstrated myelin debris with macrophages. Sections from the border revealed an area of discrete demyelination with sharp demarcation from intact myelinated areas (Figure 1, C). Mild astrocytosis surrounded the lesion.

The patient was treated with steroids and had nearly complete resolution of her symptoms. MRI performed 2 months after discharge showed resolution of the lesions. Six months later she had another episode of diplopia, gait imbalance, and dizziness that again responded to a course of steroids.

Case 2: necrotizing vasculitis

A 35-year-old white man was diagnosed with acquired immunodeficiency syndrome (AIDS) in 1986. Since then, he has had multiple systemic infections including *Pneumocystis carinii*, cytomegalovirus, histoplasmosis, and herpes zoster. His complaints of blurred vision and a right facial droop began 3 months prior to this admission. MRI of the brain at that time showed a left basal ganglion lesion and a few periventricular lesions (Figure 2, A). These findings were consistent with toxoplasmosis, and the patient was treated empirically. One month later he developed *Staphylococcus aureus* bacteremia and was treated with vancomycin. MRI showed a decrease in size of the intracranial lesions.

Two months later, the patient developed progressive weakness and paresthesias of the right upper limb and worsening facial droop. Broad-spectrum antibiotics were started, but his condition continued to worsen. Numbness of the left lower limb developed, and his gait became unsteady. CT showed multiple poorly defined regions of decreased density in the periventricular white matter, left frontal lobe, and left occipital lobe. MRI showed an increase in the number of subcortical white matter lesions as compared with the previous studies (Figure 2, B).

Tissue from the left frontal lesion was obtained by stereotactic biopsy. Vasculitic changes were seen in both meningeal and parenchymal vessels (Figure 2, C and D) and subacute hemorrhagic infarction was noted, which was diagnostic of acute necrotizing vasculitis. The patient displayed mild improvement with medical therapy. Though he had no new neurologic deficits postoperatively, he was left with a permanent deficit.

Case 3: progressive multifocal leukoencephalopathy

A 77-year-old white man, a retired executive, presented to the Cleveland Clinic with progressive mental and neurological deterioration. His symptoms began 6 months prior to admission, when his family noted that he was having difficulty using his left leg, concentrating on a given subject, and balancing his

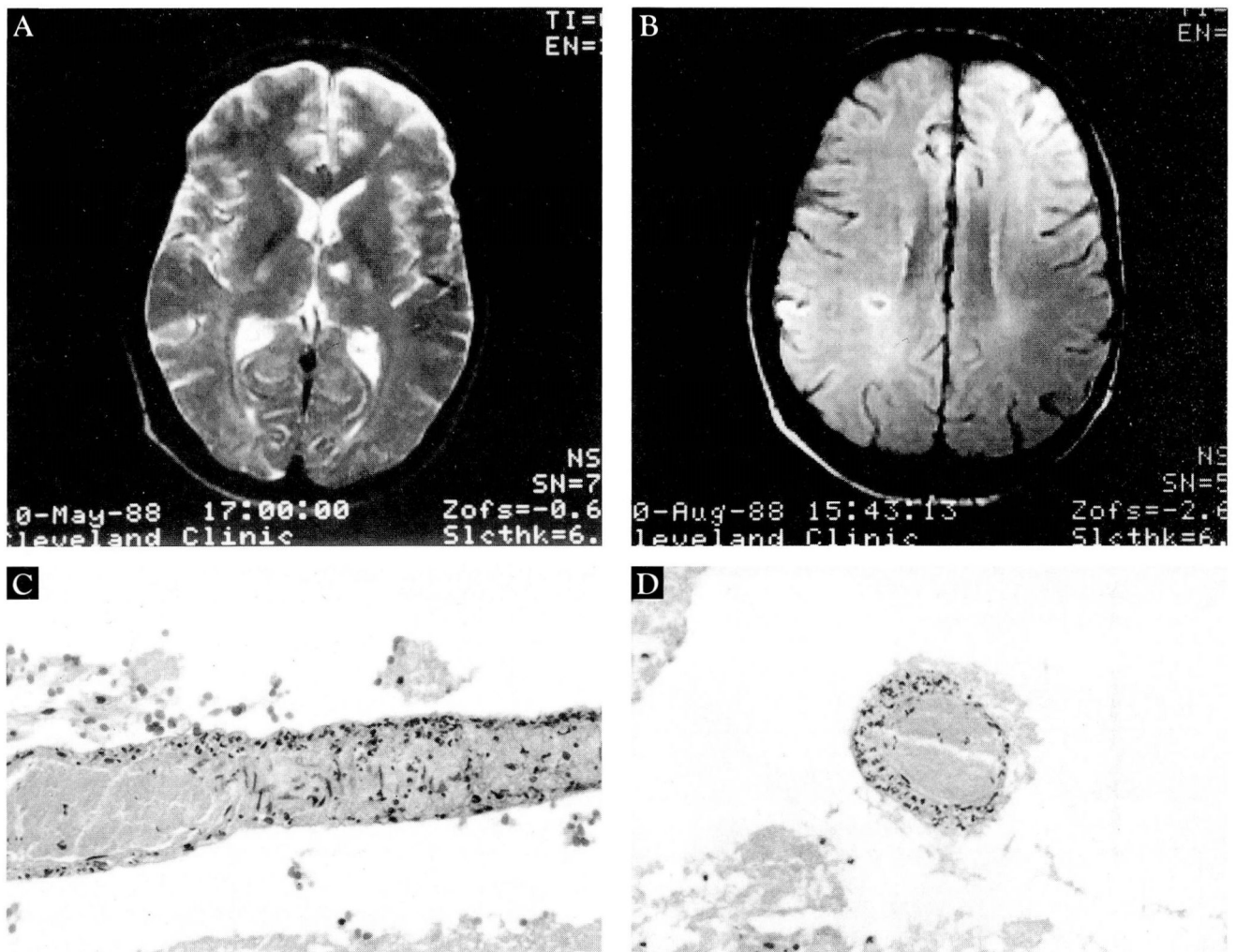


FIGURE 2. (A) Axial MRI reveals a well-defined area of increased signal in the left basal ganglia (TR = 2010 ms, TE = 120 ms). (B) Axial MRI 6 months later fails to demonstrate the previously identified left basal ganglia abnormality. Several new ring lesions are seen in the right parietal white matter (TR = 2010 ms, TE = 32 ms). (C, D) Section of a small vessel within the meninges shows infiltration and destruction of the vascular wall by inflammatory cells (hematoxylin-eosin, $\times 200$).

checkbook. He underwent neurological evaluation at another institution and was felt to have had a "slight stroke."

His condition continued to deteriorate, and he was referred to the Cleveland Clinic for further evaluation. On examination, the patient displayed apathy and neglect of his left side. He had difficulty with complex tasks and dressing and had a modest impairment of short-term memory. He had left central facial nerve weakness and neglect of the left side with arm drift. Muscle bulk, tone, and myotatic reflexes were normal. The sensory exam was normal except for diminished stereognosis on the left.

Imaging studies included CT (with and without contrast) and MRI of the head. CT showed a large region of decreased density in the right parietal and frontal lobes, as well as moderate supratentorial atrophy and mild dilatation of the lateral and third ventricles (Figure 3, A). MRI demonstrated similar ventricular findings, as well as poorly defined confluent areas of increased signal intensity in the parietal white matter, adjacent to the frontal horn and in the centrum semiovale bilaterally (Figure 3, B). Progressive multifocal leukoencephalopathy was suspected.

Stereotactic biopsy was performed and was diagnos-

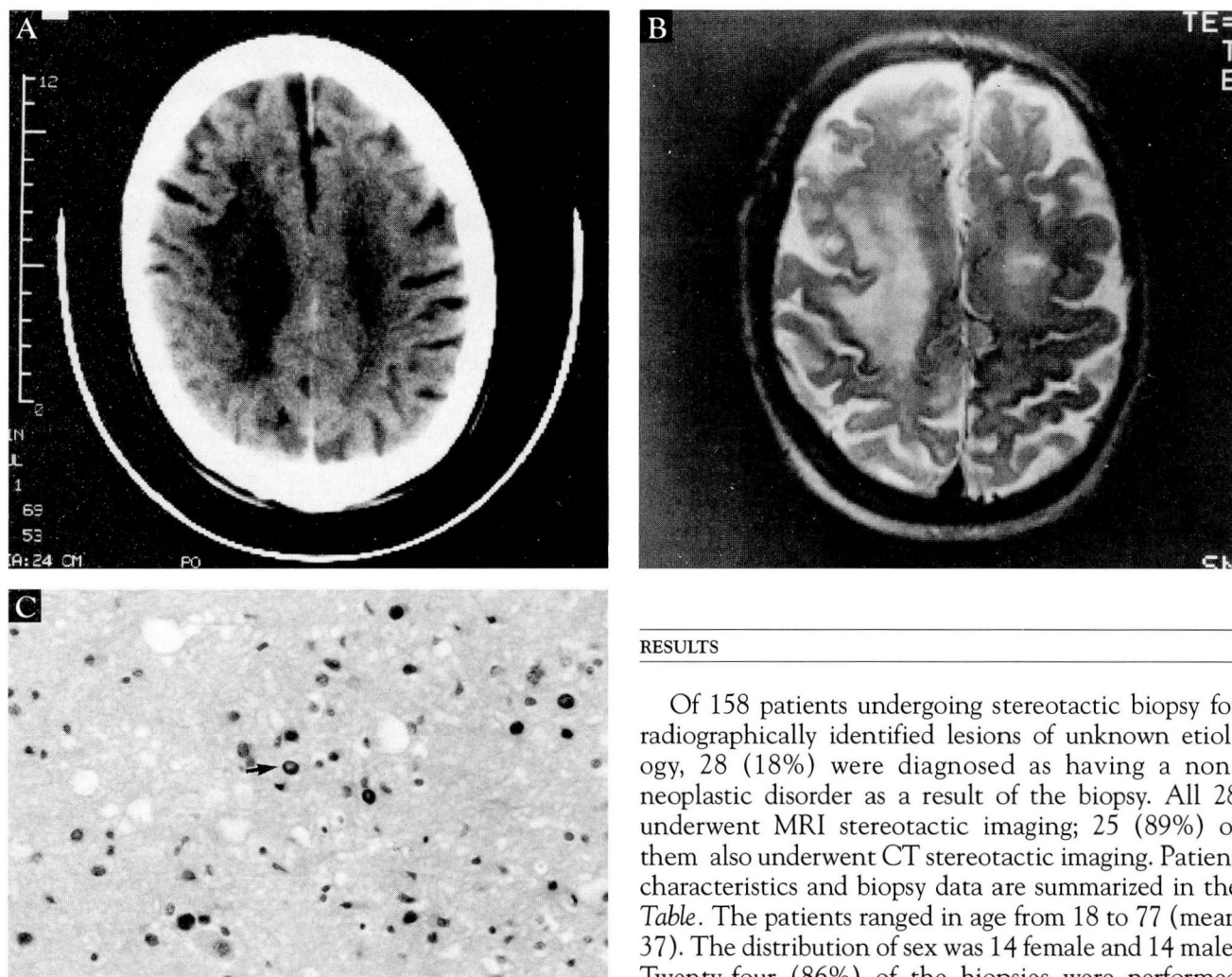


FIGURE 3. (A) Non-enhanced axial CT of the brain shows a poorly defined region of decreased attenuation in the right frontal and parietal white matter. (B) Axial MRI identifies increased signal in the right cerebral white matter (TR = 2010 ms, TE = 120 ms). (C) Section of demyelinated white matter shows numerous intranuclear inclusions within oligodendrocytes (arrow) (hematoxylin-eosin, $\times 200$).

tic for progressive multifocal leukoencephalopathy. Hematoxylin-eosin-stained frozen and permanent sections showed multiple segments of white matter containing numerous gitter cells, bizarre reactive astrocytes, sparse perivascular lymphocytic infiltration, and multiple basophilic intranuclear inclusion within oligodendrocytes (Figure 3, C). Since there were no remediable immunosuppressive causes of the progressive multifocal leukoencephalopathy, the patient was transferred to a chronic nursing facility.

RESULTS

Of 158 patients undergoing stereotactic biopsy for radiographically identified lesions of unknown etiology, 28 (18%) were diagnosed as having a non-neoplastic disorder as a result of the biopsy. All 28 underwent MRI stereotactic imaging; 25 (89%) of them also underwent CT stereotactic imaging. Patient characteristics and biopsy data are summarized in the Table. The patients ranged in age from 18 to 77 (mean 37). The distribution of sex was 14 female and 14 male. Twenty-four (86%) of the biopsies were performed supratentorially, and four (14%) were in the brainstem. Of the supratentorial biopsies, eight (33%) were in the left hemisphere. Thirteen lesions (46%) were located in the frontal lobes, five (18%) were in the parietal lobes, and one each was in the temporal lobe, occipital lobe, and insula. Three lesions (11%) were in the pons, one in the midbrain, two (7%) in the basal ganglia, and one in the thalamus.

Stereotactic biopsy in conjunction with clinical and other laboratory features led to diagnoses in 23 (82%) of the 28 patients with non-neoplastic lesions. Biopsy alone was diagnostic in 19 (68%) of these cases. In 5 of the 28 patients, biopsy was not helpful in establishing a definitive diagnosis even after extensive evaluation.

Biopsy alone was diagnostic for the following conditions: inflammatory lesions (vasculitis, encephalitis, and cerebritis), progressive multifocal leukoencephalopathy, vasculopathy, multiple sclerosis, hamar-

toma, thrombosed arteriovenous malformation, organized hematoma, and radiation necrosis. In four cases, biopsy contributed to the diagnosis of anoxic encephalopathy, vasculitis, Pick's disease, and lymphomatoid granulomatosis.

Among the 17 patients in whom stereotactic biopsy alone was diagnostic, the diagnosis was unsuspected in 6 (35%). The diagnosis was considered possible but unlikely in 10 (59%) of the 17. In only 1 (6%) of the 17 was the diagnosis strongly suspected preoperatively. The 6 unsuspected diagnoses were of lesions that were thought preoperatively to be neoplastic, but which proved on biopsy to be non-neoplastic. They represent 21% of the 28 non-neoplastic lesions diagnosed.

The results of stereotactic biopsy led to modified patient management in all 23 diagnosed cases and did not affect the management of the five patients who remained without a definitive diagnosis.

Permanent or prolonged worsening of the neurologic exam after stereotactic biopsy was found in two (7%) patients. In one, pre-existing hemiparesis and dysphasia due to hemorrhage worsened after biopsy; the other was comatose after biopsy of a frontal interhemispheric hamartoma, but returned to the preoperative level of function after several months. Transient worsening of pre-existing deficits, which resolved over a few weeks, was seen in four (14%) patients. There was no postoperative mortality.

DISCUSSION

Over the past decade, the use of stereotactic biopsy has become standard for the diagnosis of many intracranial neoplastic lesions. Diagnostic rates of greater than 95% and morbidity of 5% or less are com-

TABLE
PATIENTS UNDERGOING BIOPSY OF NON-NEOPLASTIC LESIONS

Patient	Sex/Age (years)	Location of lesion	Post-biopsy deficit	Role of biopsy	Diagnosis
1.	M/64	L frontal	None	D	Progressive multifocal leukoencephalopathy
2.	M/56	L frontal	Permanent	ND	Unknown
3.	M/77	R parietal	None	D	Progressive multifocal leukoencephalopathy
4.	F/36	L pons	Temporary	D	Radiation necrosis
5.	M/18	L frontal	None	D	Cerebritis
6.	F/23	R parietal	None	D	Multiple sclerosis
7.	F/34	R basal	Temporary	D	Organized hematoma
8.	M/35	L frontal	None	D	Necrotizing vasculitis
9.	F/25	R frontal	None	D	Multiple sclerosis
10.	F/38	R frontal	None	A	Vasculitis
11.	F/18	R occipital	None	ND	Unknown
12.	F/23	L frontal	None	D	Thrombosed arteriovenous malformation
13.	M/40	R parietal	None	A	Pick's disease
14.	F/46	R thalamus	Temporary	D	Degenerated hamartoma
15.	M/25	R frontal	None	A	Anoxic encephalopathy
16.	M/31	L basal ganglia	None	D	Multiple sclerosis
17.	M/62	R frontal	None	D	Vasculopathy
18.	F/18	R temporal	None	D	Necrotizing vasculitis
19.	F/48	R frontal	None	D	Sclerosing vasculopathy
20.	M/38	L pons	None	ND	Unknown
21.	M/30	L occipital	None	D	Progressive multifocal leukoencephalopathy
22.	F/18	R frontal	None	D	Multiple sclerosis
23.	F/40	L pons	Temporary	ND	Unknown
24.	F/44	R frontal	Permanent	D	Hamartoma
25.	M/31	L midbrain	None	A	Lymphomatoid granulomatosis
26.	M/73	L parietal	None	D	Viral encephalitis
27.	F/18	R parietal	None	D	Multiple sclerosis
28.	M/32	R frontal	None	ND	Migraine vs. vasculitis

D, diagnostic; A, assisted in diagnosis; ND, not diagnostic

mon.^{4,12,13,16,17,21,22} Despite the efficacy of this technique for tumors, little has been written regarding its use for diagnosing non-neoplastic lesions. Traditionally, stereotactic biopsy is not considered part of the diagnostic evaluation of a non-neoplastic disorder, even when a definitive diagnosis is lacking. This may be due to the belief that biopsy probably will not be helpful, or that it carries a high risk of clinical deterioration.

In many large review series, non-neoplastic lesions were discovered only as unexpected findings following biopsy for suspected tumors,^{12,13,16,17,23} whereas in our series 79% (22) of the non-neoplastic lesions found were believed preoperatively to be non-neoplastic.

Open brain or leptomeningeal biopsies have proven to be useful diagnostic aids in several neurologic disorders, including encephalitis, vasculitis, and degenerative disorders. However, there have been few reports of the use of stereotactic biopsy in these settings. In 1974, Hankinson et al¹⁴ reported a case of CNS demyelination related to porphyria that was diagnosed by

stereotactic biopsy. Recently, several case reports have documented the utility of stereotactic biopsy for the diagnosis of CNS granulomatous angiitis²⁴ and histiocytosis X.²⁵

Young reported the only series dealing primarily with stereotactic biopsy of non-neoplastic lesions.²⁰ He reviewed the usefulness of stereotaxis in immunocompromised patients with intracranial lesions (primarily infectious), and concluded that stereotactic biopsy techniques were "widely under-utilized" and that "except under extraordinary circumstances, stereotactic biopsy should be performed to define and establish a histologic diagnosis of unknown cause in the immunocompromised patient." Friedman et al, in a recent review of their experience with stereotactic biopsy procedures, noted a significant incidence of unexpected pathological findings upon biopsy, and emphasized tissue diagnosis as the foundation for appropriate therapy.²³

In our series, 18% (28 of 158) of all diagnostic stereotactic biopsies resulted in diagnoses of non-neoplastic disorders. Of these, 79% (22 cases) were performed to aid in the diagnosis of a suspected non-neoplastic disorder, the nature of which was unclear. The technique proved useful in a variety of neurological disorders. Often these biopsies were performed because standard nonsurgical evaluation was not helpful in defining the etiology of a neurological deficit that correlated to an abnormality on MRI or CT.

The diagnostic rate for non-neoplastic lesions by stereotactic biopsy in this series is not as high as some of the rates quoted for tumors,^{11,12,16,17} but these two types of disorders have dissimilar clinical and radiologic

profiles. Neoplasms often have characteristics that make stereotactic biopsy merely confirmatory, and biopsy results frequently do not significantly alter patient management. In the case of non-neoplastic lesions, biopsy can be confirmatory, as in progressive multifocal leukoencephalopathy (case 3, above), or it can provide an unsuspected diagnosis, as in multiple sclerosis and necrotizing vasculitis (cases 1 and 2, above). Even in instances where biopsy alone was not sufficient to establish a diagnosis (11 cases out of 28, or 39%), stereotactic biopsy usually provided information that was helpful (82%).

In all 23 diagnosed cases the biopsy had a substantial impact on patient management compared with the preoperative plan. When rational treatment was available (as for vasculitis, multiple sclerosis, and certain encephalitides), it was instituted. Diagnoses of disorders that are presently untreatable allowed accurate prognostication and appropriate patient disposition without the need for further lengthy diagnostic evaluations, unrewarding trials of medications, and costly hospitalizations.

The accuracy and minimal morbidity of this procedure strongly support the notion that stereotactic biopsy of certain non-neoplastic lesions is a safe and useful diagnostic option in the evaluation of non-neoplastic CNS disorders. This procedure should be considered for patients with abnormal brain imaging and progressive neurologic dysfunction in cases where non-surgical testing has failed to establish a definitive diagnosis. Early stereotactic biopsy may allow more prompt initiation of rational treatment (if available) and improved prognostication of these neurologic disorders.

REFERENCES

- Coffey RJ, Friedman WA. Interstitial brachytherapy of malignant brain tumors using computer tomography-guided stereotaxis and available imaging software: technical report. *Neurosurgery* 1987; 20:4-7.
- Davis DH, Kelly PJ, Marsh R, Kall BA, Goerss SJ. Computer-assisted stereotactic biopsy of intracranial lesion in pediatric patients. *Pediatr Neurosci* 1988; 14:31-36.
- Horsley V, Clarke RH. The structure and function of the cerebellum examined by a new method. *Brain* 1908; 31:45-124.
- Kelly PJ. Applications and methodology for contemporary stereotactic surgery. *Neurol Res* 1986; 8:2-12.
- Kelly PJ, Kall BA, Goerss S, Cascino TL. Results of computer assisted stereotactic laser resection of deep-seated intracranial lesions. *Mayo Clin Proc* 1986; 61:20-27.
- Kelly PJ, Kall BA, Goerss S, Earnest F. Computer-assisted stereotactic laser resection of intra-axial brain neoplasms. *J Neurosurg* 1986; 64:427-439.
- Leksell L, Leksell D, Schwebel J. Stereotaxis and nuclear magnetic resonance. *J Neurol Neurosurg Psychiatry* 1985; 48:14-18.
- Maroon JC, Bank WO, Drayer BP, Rosenbaum AE. Intracranial biopsy assisted by computerized tomography. *J Neurosurg* 1977; 46:740-744.
- Reichart T, Munding F. Beschreibung und Andwerdung eines zeilgerates fur stereotaktische Hirnoperationen. II model. *Acta Neurochir Suppl (Wien)* 1955; 3:308-337.
- Spiegel EA, Wycis T. Stereoccephalotomy (Part 1). Methods and stereotaxis atlas of the human brain. Orlando, Florida: Grune & Stratton, 1952.
- Talairach J. Les explorations stereotaxiques. *Rev Neurol* 1954; 90:556-84.
- Apuzzo MLJ, Chandrasoma PT, Cohen D, Zee C, Zelman V. Computed imaging stereotaxy: experience and perspective related to 500 procedures applied to brain masses. *Neurosurgery* 1987; 20:930-937.
- Black P, Mechanic A, Markowitz R. CT guided stereotaxis biopsy of brain tumors: new technology for an old problem. *Am J Clin Oncol* 1987; 10(4):285-288.
- Hankinson J, Hudgson P, Pearce GW, Morris CJ. A simple method for obtaining stereotaxis biopsies from the human basal ganglia. A case of cerebral porphyria. *Acta Neurochir Suppl (Wien)* 1974; 21:227-233.
- Kaufman HK, Catalano LW. Diagnostic brain biopsy: A series of 50 cases and a review. *Neurosurgery* 1979; 4(2):129-136.

16. Kelly PJ. Computer-assisted stereotaxis: new approaches for the management of intracranial intra-axial tumors. *Neurology* 1986; **36**:535–541.
17. Lunddsford LD, Martinez AJ. Stereotactic exploration of the brain in the era of computed tomography. *Surg Neurol* 1984; **22**:222–230.
18. Nauta JHW, Briner RP, Eisenberg HM. Computed tomogram guided stereotaxic biopsy in pediatric patients. *Pediatr Neurosci* 1986; **12**:63–67.
19. Tarantuto AL, Sevlever G, Piccardo P. Stereotactic biopsy of the central nervous system. *J Neuropathol Exp Neurol* 1989; **48**:302.
20. Young B. Role of stereotaxic biopsy in the management of transplant patients with intracranial lesions. *Neurol Clin* 1988; **6**(3):639–644.
21. Colbassani HJ, Nishio S, Sweeney KM, Baray RAE, Takei Y. CT-assisted stereotaxic brain biopsy: value of intraoperative frozen section analysis. *J Neurol Neurosurg Psychiatry* 1988; **51**:332–341.
22. Hadley MN, Shetter AG, Amos MR. Use of the BRW stereotactic frame for functional neurosurgery. *Proceedings IXth Meeting World Soc Stereo and Functional Neurosurgery, Toronto* 1985. *Appl Neurophysiol* 1985; **48**:61–68.
23. Friedman WA, Sceats DJ, Nestok BR, Ballinger WE. The incidence of unexpected pathological findings in an image guided biopsy series: review of 100 consecutive cases. *Neurosurg* 1989; **25**:180–184.
24. Johnson M, Maciunas R, Dutt P, Clinton ME, Collins R. Granulomatous angiitis masquerading as a mass lesion. *Surg Neurol* 1989; **31**:49–53.
25. Goldberg R, Han JS, Gary E, Roessman U. Computed tomography demonstration of multiple parenchymal central nervous system nodules due to histiocytosis X. *Surg Neurol* 1989; **27**:377–80.

Commentary

Using stereotactic biopsy alone or in conjunction with clinical and laboratory data, Whiting and co-workers diagnosed 82% of the non-neoplastic lesions in 28 patients, and 61% could be diagnosed on biopsy alone. These results compare favorably with previous series of open biopsies for suspected medical neurologic disease which were performed before MRI or CT based stereotaxic surgery became available. The diagnostic yield in a fairly extensive unpublished series of open biopsies for undiagnosed medical neurologic disease performed between 1969 and 1977 was slightly below 50%. Modern imaging and stereotactic biopsy clearly improves diagnostic yield. Serious morbidity—mainly due to hemorrhage—is probably slightly higher with stereotactic biopsy than with open biopsy, and the mortality rate from the procedure, while low, is not zero. On the other hand, stereotactic biopsy can

probably be carried out in more seriously ill patients, and recovery is much more rapid and hospitalization is shorter than with open biopsy, if there are no sequelae.

When serious undiagnosed and potentially treatable neurologic disease is localizable on MRI or CT, the diagnostic yield and the economic and medical advantages of stereotactic biopsy often make it a reasonable option in cases where the only alternatives are watching the patient deteriorate or open biopsy. The diagnostic yield still needs to be improved, but in properly selected cases the procedure can provide new and valuable information and is worth the inherent risks.

ROBERT M. HERNDON, MD
Good Samaritan Hospital
Portland, OR