



Transesophageal echocardiography in the critical care unit

VICENTE E. FONT, MD, TIMOTHY P. OBARSKI, DO, ALLAN L. KLEIN, MD, JAMES C. BARTLETT, DO,
JAMES J. NEMEC, MD, WILLIAM J. STEWART, MD, ERNESTO E. SALCEDO, MD

■ Transthoracic echocardiography may be of limited value for patients in intensive care units because of suboptimal patient positioning, surgical wounds, and mechanical ventilation. By contrast, transesophageal echocardiography provides a new window for cardiac imaging, even in critically ill patients. We report our indications based on findings comparing transesophageal and transthoracic echocardiography in 112 studies in intensive care units. The transesophageal approach diagnosed 131 significant findings, compared to only 95 (73%) found transthoracically. Transesophageal echocardiography was superior to the transthoracic approach in patients with significant (higher than 2+) mitral regurgitation, with improved detection in 10 (9%) cases ($p < 0.05$). Transesophageal echocardiography also provided additional information in the evaluation of vegetations, diseases of the aorta, visualization of the left ventricle, intracardiac masses, intracardiac thrombi, and congenital heart disease. Transesophageal echocardiography provides a useful diagnostic tool for evaluation of critically ill patients.

□ INDEX TERMS: ECHOCARDIOGRAPHY/METHODS; INTENSIVE CARE UNITS; CRITICAL CARE □ CLEVE CLIN J MED 1991; 58:315-322

Echocardiography, the mainstay of noninvasive cardiac imaging, is highly sensitive in the detection of cardiac abnormalities. In acutely ill patients seen in intensive care units, transthoracic echocardiography (TTE) provides the capability for immediate diagnosis at the bedside.^{1,2} However, this approach can often yield poor images due to suboptimal patient positioning, surgical wounds, and mechanical ventilation. The recent

evolution of transesophageal echocardiography (TEE) has brought a better understanding and identification of cardiac pathology because it provides a new acoustic window to the heart.

The purpose of this study was to comparatively evaluate transesophageal and transthoracic echocardiography by using both techniques in a population of intensive care patients. In this article we present the results of this study and indications for optimal use of this new modality.

From the Department of Cardiology (V.E.F., A.L.K., J.C.B., J.J.N., W.J.S., E.E.S.), The Cleveland Clinic Foundation, and the Department of Cardiology (T.P.O.), Riverside Hospital, Columbus, Ohio.

Address reprint requests to A.L.K., Department of Cardiology, Cleveland Clinic Florida, 3000 W. Cypress Creek Road, Ft. Lauderdale, Florida 33309.

METHODS

Between June 1987 and October 1989, 890 TEE studies were performed at the Cleveland Clinic Foundation, of which 152 were performed in the various

TABLE 1
INDICATIONS FOR TRANSESOPHAGEAL
ECHOCARDIOGRAPHY IN 112 STUDIES*

Indication	Total(%)
1 Rule out vegetation	51 (46%)
Prosthetic	24
Native	18
Unspecified	9
2 Rule out valve dysfunction	48 (43%)
Prosthetic	23
Native	25
3 Assess ventricular function [†]	21 (19%)
4 Rule out intracardiac thrombus/mass or source of embolus	13 (12%)
5 Rule out aortic dissection or aneurysm	10 (9%)
6 Assess or rule out congenital heart disease	6 (5%)
7 Rule out tamponade	4 (4%)
8 Rule out subvalvular LVOT obstruction	4 (4%)
9 Rule out constriction or restriction	1 (1%)

*Patients with more than one indication are included

[†]Includes right ventricular function in one patient

LVOT = Left ventricular outflow tract

intensive care units, including the cardiothoracic postsurgical unit, the coronary care unit, and the medical, surgical, and neurological intensive care units (ICUs). From this group we selected 104 patients (a total of 112 TEE studies); these patients also had TTE performed without intervening significant events. Of the 112 TEE studies completed along with comparable TTE studies, 93 were performed within 5 days of the TTE, and 70 were done on the same or following day. Sixty-eight percent of the TTEs were described as fair to poor imaging quality. The mean age was 59 ± 17 ; 56 were performed in men and 56 were in women. Sixty-three (56%) patients were postoperative from cardiac or noncardiac surgery. Chest radiography revealed cardiomegaly in 53 (47%) patients. Forty-five patients (40%) were respirator-dependent. Sixty-three (56%) had a history of congestive heart failure, and 72% of these cases were in New York Heart Association Functional Class III-IV.

Echocardiography

The transthoracic studies were recorded using commercially available equipment. Although attempts were made to do studies in the left lateral decubitus position, many patients were too ill for this and were imaged in the supine position. The M-mode echocardiograms were recorded with two-dimensional guidance, and measurements were obtained from all TTEs with adequate parasternal windows in accord-

ance with the criteria outlined by the American Society of Echocardiography.³

The transesophageal studies were recorded using 5.0-MHz phased-array transducers. The TEE probe was introduced following topical pharyngeal anesthesia and mild sedation (usually low-dose midazolam and meperidine) and was advanced into the esophagus with the patient in the recumbent position. A comprehensive examination of the heart and aorta was done using standard tomographic projections. All studies were recorded on 1/2-inch VHS videotape.

Visual estimation of left ventricular contractility was made by categorizing patients into five groups according to systolic function. The categories were as follows: normal systolic function, and mild, moderate, moderately severe, or severe systolic dysfunction. The left ventricular ejection fraction was calculated from the transthoracic two-dimensional images using a system formulated by Quiñones.⁴

The severity of valvular regurgitation was assessed by visual estimation following previously described echocardiographic and angiographic criteria^{5,7} and classified as none (0), mild (1+), moderate (2+), moderately severe (3+), and severe (4+). For the purpose of analysis, we defined "insignificant" valvular regurgitation as up to and including moderate (2+), and "significant" regurgitation as greater than moderate severity. For purposes of comparing the effectiveness of TEE and TTE in diagnosing the severity of regurgitation, we assigned each case to one of four groups. Group A was defined as $\leq 2+$ regurgitation by both TEE and TTE; group B as $> 2+$ by TEE but $< 2+$ by TTE; group C as $\geq 2+$ by both TEE and TTE; and group D as $< 2+$ by TEE and $> 2+$ by TTE.

Statistical analysis

Comparability of TEE and TTE groups was tested by using McNemar's test. Comparability of TEE and TTE for detection of other cardiac lesions was tested by using the chi-square statistical method. Any level below 0.05 was considered significant.

RESULTS

Echocardiographic indications and findings

The indications for TEE in our series (Table 1) are primarily for patients with suspected endocarditis, valvular dysfunction, and hemodynamic problems that require determination of ventricular function. The indications were obtained from physician notes in the patient charts.

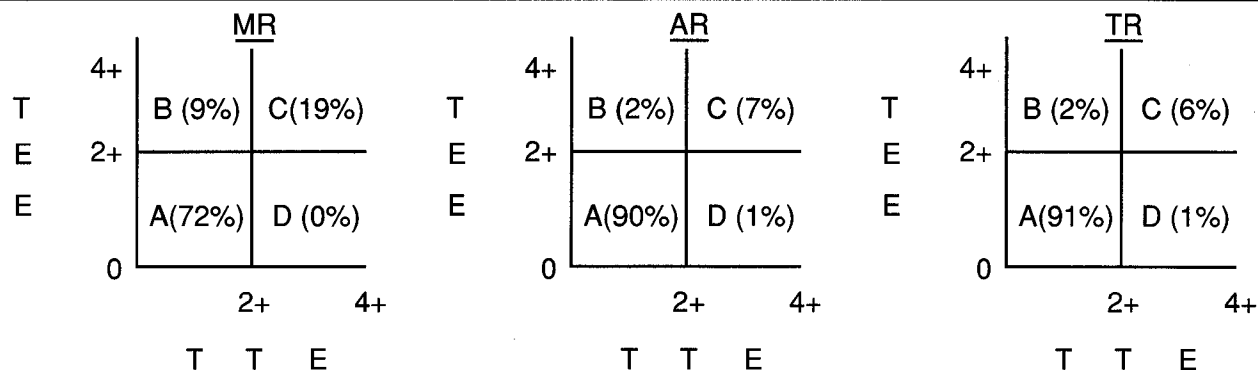


FIGURE 1. Concordance (groups A and C) and discordance (groups B and D) between transesophageal and transthoracic echocardiography (TEE and TTE) for regurgitant lesions in ICU patients according to severity.

TEE identified 131 significant lesions or findings in this series, whereas TTE found only 95 (73%) ($p < 0.001$). Table 2 outlines the frequency of diagnoses made by TTE vs TEE in various abnormal conditions.

Complications

Despite the severity of illness present in this population, no serious complications occurred as a result of any of the studies. One patient suffered a cardiac arrest after the physicians unexpectedly found normal ventricular function on the TEE and abruptly discontinued inotropic support. After removing the scope, the patient was successfully resuscitated, and the arrest was not considered a complication of the TEE examination.

Assessment of valvular regurgitation

In the 112 cases studied, 23 had prosthetic mitral valves (13 biologic, 10 mechanical) and 89 had native mitral valves, of which 13 had been previously repaired. Twenty-five had prosthetic aortic valves (15 biologic, 10 mechanical) and 87 had native aortic valves, of which 4 had previously undergone repair. All tricuspid valves were native, although three had previously undergone ring annuloplasty.

Suspected valvular regurgitation was an indication for TEE in 48 cases and was confirmed in 34 (71%). TEE detected 166 regurgitant lesions in 94 patients, or 84% of the entire population. Of the lesions identified, 81 were mitral, 40 aortic, and 45 tricuspid. The transesophageal method found significant ($>2+$) regurgitation in 31 of 81 mitral valve lesions (24 native valves, 7 prosthetic), 10 of 40 aortic valve lesions (7 native, 3 prosthetic), and 9 of 45 tricuspid valve lesions

TABLE 2
FREQUENCY OF DIAGNOSIS: TRANSTHORACIC v
TRANSESOPHAGEAL ECHOCARDIOGRAPHY

Lesion	Frequency of TTE/TEE diagnosis	p value
Tamponade	1/1 (100%)	1.0
Congenital heart disease	9/11 (82%)	0.24
Significant regurgitation*	38/50 (76%)	<0.001
Thrombus/mass	6/8 (75%)	0.78
Vegetation	19/26 (73%)	0.31
Aortic pathology	8/12 (67%)	0.48
LV visualization	13/20 (65%)	<0.005
LVOT obstruction	1/3 (33%)	0.2
Total significant findings	95/131 (73%)	<0.001

LV = Left ventricle; LVOT = Left ventricular outflow tract

*Significant defined as greater than moderate (2+) in severity

(all native valves), for a total of 50 significant lesions. Of these 50, only 38 (76%) were detected by TTE ($p < 0.001$).

Figure 1 shows the concordance (groups A and C) and discordance (groups B and D) between TEE and TTE for detecting regurgitation in the ICU. TEE identified significant mitral regurgitation in 31 cases (28%), which was significantly higher than the 21 (19%) identified by TTE ($p = 0.0016$). Figure 2 illustrates the discrepancy in the amount of mitral valve regurgitation found transesophageally (4+) v transthoracically (1+) in a patient with a prosthetic mitral valve. The detection rate of TTE for aortic and tricuspid valve regurgitation was similar to TEE ($p = 0.55$ for both).

The etiology of regurgitation was either not determined or not apparent by TEE in 37% (62 of 166) of all valvular regurgitations. However, the great majority of these lesions of unknown cause were of mild to

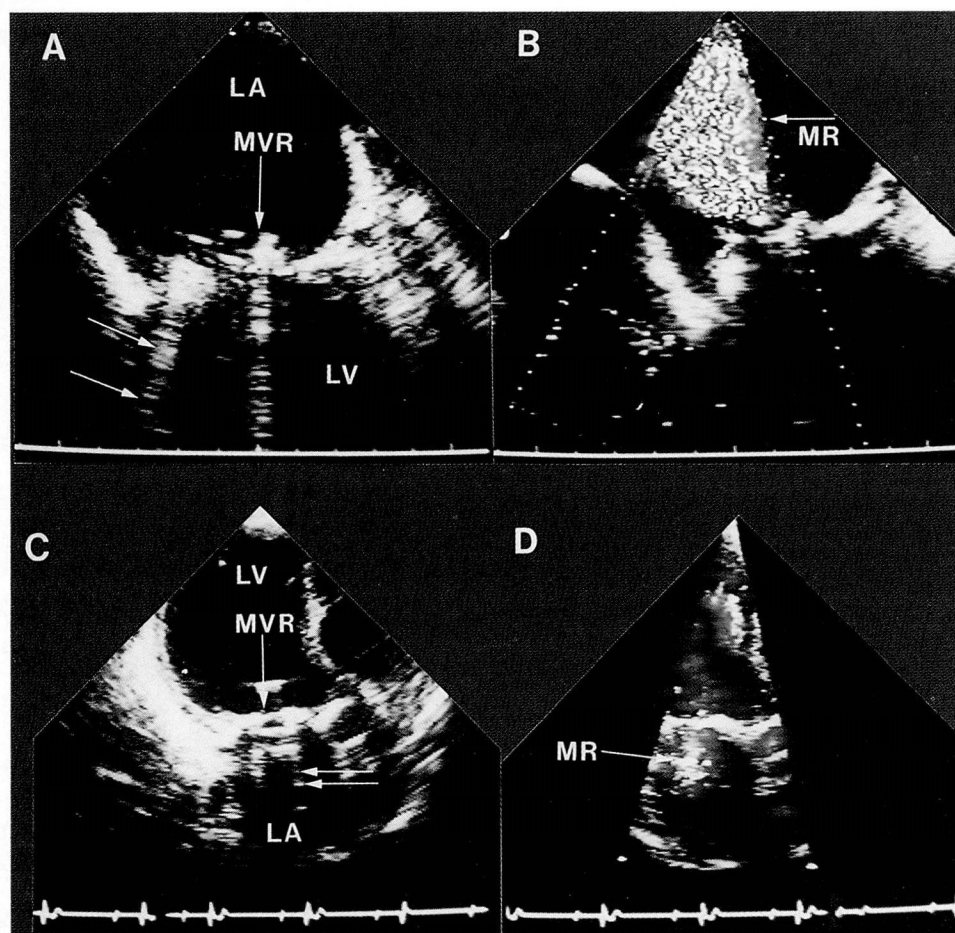


FIGURE 2. Composite of TEE and TTE showing underestimation of mitral valve regurgitation (MR) by TTE in the same patient. Two-dimensional TEE (A) in four-chamber view demonstrates ultrasonic shielding (double arrows) of the left ventricle by mitral valve prosthesis (MVR) (single arrow). Color Doppler TEE (B) shows severe mitral valve regurgitation. Two-dimensional TTE (C), in apical long axis view, shows ultrasonic shielding in the left atrium (arrows) caused by mitral valve prosthesis (MVR); and color Doppler TTE (D) detected mild mitral valve regurgitation.

moderate severity, and only 3 mitral and 3 tricuspid regurgitative lesions of >2+ severity remained of unknown etiology. As shown in Table 3, the etiologies for >2+ mitral regurgitation were as follows: papillary muscle dysfunction, including one rupture (7 of 31); vegetations (7 of 31); flail leaflet (5 of 31); degenerative/calcified mitral valve (4 of 31); periprosthetic (3 of 31); unknown (3 of 31); prolapse (1 of 31); and annulus dilatation (1 of 31). The etiologies for >2+ aortic valve regurgitation were vegetations (3 of 10); degenerative/calcified aortic valve (2 of 10); dilated aorta (3 of 10); flail prosthetic leaflet (1 of 10); and periprosthetic (1 of 10). The etiologies for >2+ tricuspid valve regurgitation were pulmonary hypertension (4 of 9); un-

known (3 of 9); prolapse (1 of 9); and Ebstein's anomaly (1 of 9).

Endocarditis

A search for vegetations was the indication for TEE in 51 cases. Twenty-six vegetations were seen by TEE (17 definite, 9 possible) compared to 19 (13 definite, 6 possible) seen by TTE ($p=0.31$). TEE identified 12 vegetations in the aortic valve and 14 in the mitral valve, compared to 10 aortic and 9 mitral with TTE. Figure 3 shows a large vegetation attached to a mitral prosthesis prolapsing into the left atrium during systole.

Of the 26 vegetations that were found by TEE, 14 had positive blood cultures. Of the 12 cases of vegetation documented by TEE shown to have negative blood cultures, 11 had a clinical picture indicative of endocarditis, and this may represent a false-positive study or silent healed subacute bacterial endocarditis.

Eight cases with vegetations were confirmed at the time of cardiac surgery, and pathologic documentation was made in 10 cases.

Aortic dissection

TEE identified 11 aortic dissections and one thoracic aortic aneurysm without dissection, and three (25%) of these were unsuspected. Comparatively, only 8 of the 12 were found by TTE, and one had a negative TTE but was suspected from the clinical situation. TTE did not identify the diseased aorta in 4 out of 12 (33%). The difference between TTE and TEE, however, did not reach statistical significance ($p=0.48$). One of the 12 was studied in follow-up after repair of a

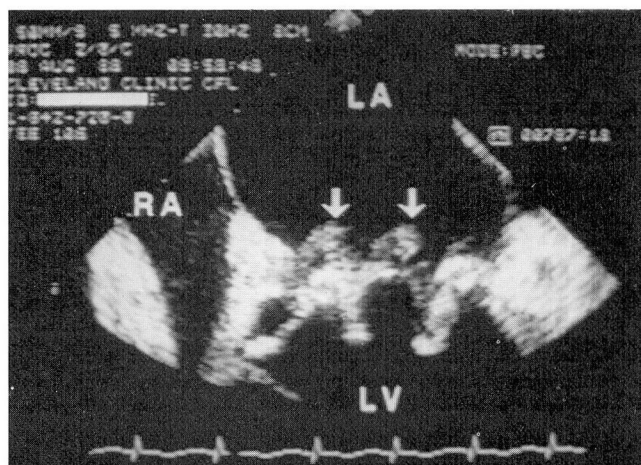


FIGURE 3. Transesophageal echocardiogram in four-chamber view shows large vegetative lesions (arrows) attached to a mitral bioprosthesis prolapsing into the left atrium (LA) during systole.

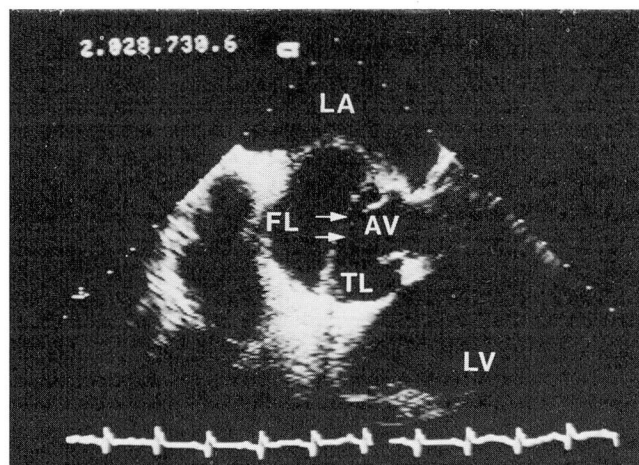


FIGURE 4. Transesophageal echocardiogram at level of aortic root showing dissection of the ascending thoracic aorta and intimal flap (arrows). FL = false lumen; TL = true lumen; AV = aortic valve; LV = left ventricle; LA = left atrium.

dissection. Figure 4 illustrates an ascending thoracic aortic dissection with clear visualization of the intimal flap.

LV function

Assessment of left ventricular function was an indication for TEE in 20 of the 112 (18%) echocardiograms; however, the retrospective design of the study may have kept this figure relatively low. Using TTE, the left ventricle could not be visualized at all in 6 of 20 cases, whereas TEE visualized it in all 20. Severe left ventricular dysfunction was found in half of the 20 patients in this group.

For all 112 echocardiograms studied by TTE and TEE, the mean percentage of fractional shortening was $31\% \pm 11\%$, and left ventricular ejection fraction was $52\% \pm 15\%$. Visual estimation of left ventricular contractility was grossly normal in 74 of 112 cases (66%), mildly or moderately impaired in 25 of 112 (22%), and moderately severe to severely impaired in 13 of 112 (12%).

Thrombi and intracardiac masses

Possible intracardiac mass was an indication for TEE in 13 of the 112 (12%) cases but was found in only 3. An additional five masses were found unexpectedly, for a total of eight in 112 cases. As shown in Table 2, 2 (25%) were not seen by TTE ($p=0.78$). Of the eight total, seven were described as thrombus (two in the left atrium, one in the right atrium, one in the left

TABLE 3
ETIOLOGY OF SIGNIFICANT (>2+) VALVULAR
REGURGITATION IN ICU PATIENTS

Etiology	
	Mitral regurgitation
1 Papillary muscle dysfunction	7
2 Vegetation	7
3 Flail leaflet	5
4 Calcified/degenerative	4
5 Periprosthetic regurgitation	3
6 Unknown/not apparent	3
7 Prolapse	1
8 Annulus dilatation	1
Total regurgitant lesions	31
	Aortic regurgitation
1 Calcified/degenerative	3
2 Dilated aortic root	3
3 Vegetation	2
4 Flail leaflet	1
5 Periprosthetic regurgitation	1
Total regurgitant lesions	10
	Tricuspid regurgitation
1 Pulmonary hypertension	4
2 Unknown/not apparent	3
3 Prolapse	1
4 Ebstein's anomaly	1
Total regurgitant lesions	9
Total significant regurgitant lesions	50

ventricle, two in the superior vena cava, and one in the inferior vena cava), and one was described as a mass

(in the right atrium). In one patient, intravenous urokinase was given for a suspected atrial thrombus; later echocardiographic examination revealed complete resolution of the mass.

Miscellaneous

Congenital heart disease was identified in 11 of the 112 TEEs done in the ICU; 4 of the 11 involved only a patent foramen ovale (PFO). Two abnormalities (one muscular ventricular septal defect and one PFO) were not detected by TTE. Three of the 11 patients underwent corrective cardiac surgery on the basis of the TEE.

Although cardiac tamponade was suspected in only 4 of the 112 cases, only 1 case proved to have tamponade by TEE, and this was also identified by a transthoracic study.

Dynamic left ventricular outflow tract obstruction with systolic anterior motion of the mitral leaflets after aortic valve replacement was seen in three cases (4%) using TEE. Two of these were not diagnosed by TTE due to poor quality of the studies. The ability to identify this problem is particularly important in the ICU patient, since hypotension may be found early after cardiac surgery.

DISCUSSION

The nature of critical illnesses in ICU patients demands accurate cardiac imaging. Yet high-quality transthoracic echocardiograms are frequently difficult to obtain in such patients. Parker et al⁸ showed that one third to one half of patients on respirators cannot be studied satisfactorily with transthoracic echocardiography. In patients requiring more than 10 cm of positive end-expiratory pressure, only poor TTE images were usually obtained.⁸

TEE may provide a readily accessible solution to this problem because of the improved resolution of high-frequency transducers, access to a transducer position inside the chest, and the ability to image posterior cardiac structures in the near field of the transducer. TEE is becoming a well-accepted diagnostic technique and a safe, standard clinical tool for many cardiologists,⁹⁻¹¹ producing very sharp, high-quality images.^{12,13} TEE can provide valuable clinical information in a large variety of cases.¹⁴⁻¹⁸

Valve dysfunction

TEE has been shown to be extremely helpful in the recognition and characterization of mitral valve

pathology such as ruptured chordae tendineae and flail leaflets.^{19,20} Furthermore, several investigators have reported superior accuracy, sensitivity, and reliability of TEE over TTE for mitral prosthetic dysfunction, where ultrasonic shadowing of the left atrium frequently occurs with the standard surface studies.^{6,21-23}

In the present study, we were able to determine the etiology of significant mitral valve lesions in 28 of 31 cases (90%), aortic valve lesions in 10 of 10 cases (100%), and tricuspid valve lesions in 6 of 9 cases (67%). Although such determinations were not pathologically confirmed in the majority of this group, such anatomic information is helpful in understanding the natural history of the valve dysfunction, whether progressive or nonprogressive, infectious or noninfectious. For the evaluation of etiology, we purposefully selected lesions with greater than moderate regurgitation, because the question of etiology is moot in a large percentage of patients with mild or physiologic regurgitation.²⁴

Our experience is in agreement with previous observations that TEE is more sensitive than TTE for detection of mitral valve regurgitation. In our series, 10 cases (9%) with >2+ mitral regurgitation were detected by the transesophageal approach, but not the transthoracic. In seven cases this was due to poor-quality surface studies and three were due to prosthetic shielding artifact. This finding proved to be highly significant. Although color Doppler echocardiography is highly sensitive and specific in identifying mitral valve regurgitation and in providing an accurate estimation of severity when compared to routine angiography, one must bear in mind that the severity grading scale was designed for transthoracic color Doppler,²⁵ and that no validated criteria currently exist for transesophageal color Doppler. Using different methodology than we used, Smith et al²⁶ recently found some overestimation of regurgitant jets by TEE.

Endocarditis

Echocardiography is the test of choice for the non-invasive diagnosis of endocarditis. Use of M-mode echocardiography alone can identify vegetations in 57% of cases; adding two-dimensional echocardiography increases the detection rate to 73%.²⁷ Mügge et al²⁷ compared TEE and TTE and found a detection rate of vegetations of 90% for TEE and 58% for TTE. In the present study at the Cleveland Clinic, vegetation or endocarditis was suspected in 51 of 112 cases (46%) on the basis of fever, hypotension, and/or positive blood cultures, with or without a positive TTE. TEE in-

creased the detection rate of vegetations by 27% compared to TTE (from 19 with TTE to 26 cases with TEE). Unfortunately, as with other echocardiographic studies, only 10 of 26 "cases" (38%) of endocarditis were confirmed surgically or histopathologically.

Aortic pathology

TEE is a superb technique for the evaluation of aortic dissections and is emerging as the procedure of choice for the diagnosis and follow-up of this condition.^{28,29} Erbel et al³⁰ described a sensitivity and specificity for diagnosing aortic dissection of 97% and 100%, respectively, using combined TTE and TEE.³⁰ Of the 12 dissections or aortic aneurysms seen by TEE in the present study, 4 (33%) were not identified by TTE, confirming the superiority of TEE for this diagnosis.

Thrombi and masses

Echocardiography is an excellent technique for the assessment of intracardiac masses. However, TTE has limitations, particularly in visualizing the left atrial appendage and when prosthetic valves or extensive annular calcification shield the cardiac chambers.^{31,32} TEE has been shown superior to TTE in the evaluation of atrial myxomas and thrombi, cerebral ischemic events (in young patients), and intracardiac foreign bodies.³³⁻³⁶ In addition, it has been shown that TEE-detected spontaneous-echo contrast of the left atrium is an indicator for increased thromboembolic events in patients with mitral stenosis or a mitral prosthesis.^{37,38} In addition, Klein et al³⁹ reported a case in which TEE made the diagnosis of severe life-threatening pulmonary embolus due to its ability to visualize the main and the right pulmonary arteries.³⁹

Other applications

In our experience, TEE provided clinically important information for estimation of ventricular function in all patients and should be considered the test of choice for the noninvasive assessment of left ventricular function when a transthoracic study is not feasible or is substandard in quality.

Standard TTE has become a useful diagnostic method in the evaluation of the critically ill child who may suffer from congenital heart disease. Doppler and contrast echocardiography are very sensitive techniques for detecting intracardiac shunts, obtaining hemodynamic information, and finding other anatomic anomalies.^{40,41} Although our ICU group included no pediatric patients, TEE was probably most useful in the evaluation of PFO due to the close proximity of the lesion to the ultrasound transducer. This is particularly a question in unexplained cerebrovascular accidents.

CONCLUSIONS

The present study represents the largest reported series of transesophageal echocardiograms in an ICU. Our experience has led us to conclude that transesophageal echocardiography can be performed in the ICU without complications and may be superior to transthoracic echocardiography in identifying significant cardiac lesions, especially valvular regurgitation, vegetations, thrombi, and diseases of the aorta. Standard transthoracic echocardiographic examination may risk a percentage of false-negative results, and transesophageal imaging often provides additional information of great clinical utility.

REFERENCES

1. Woolridge JD. Echocardiography in the coronary care unit. *Australas Radiol* 1984; **28**(4):339-340.
2. Widimsky P, Gregor P, Cervenka V, et al. The role of echocardiography in a coronary care unit. *Cor Vasa* 1985; **27**(4):272-279.
3. Sahn DL, DeMaria A, Kisslo J, et al. The Committee on M-Mode Standardization of the American Society of Echocardiography. Recommendations regarding quantitation in M-mode echocardiographic measurements. *Circulation* 1978; **58**:1072.
4. Quiñones MA, Waggoner AD, Reduto LA, et al. A new, simplified, and accurate method for determining ejection fraction with two-dimensional echocardiography. *Circulation* 1981; **64**(4):744-753.
5. van den Brink RBA, Visser CA, Basart DCG, et al. Comparison of transthoracic and transesophageal color Doppler flow imaging in patients with mechanical prostheses in the mitral valve position. *Am J Cardiol* 1989; **63**:1471-1474.
6. Nellessen U, Schnittger I, Appleton CP, et al. Transesophageal two-dimensional echocardiography and color Doppler flow velocity mapping in the evaluation of cardiac valve prostheses. *Circulation* 1988; **78**:848-855.
7. Sellers RD, Levy JM, Amplatz K, et al. Left retrograde cardioangiography in acquired cardiac disease. Technique, indications, and interpretations in 700 cases. *Am J Cardiol* 1964; **14**(4):437-447.
8. Parker MM, Cunnion RE, Parillo JE. Echocardiography and nuclear cardiac imaging in the critical care unit. *JAMA* 1985; **254**(2):2935-2939.
9. Geibel A, Wolfgang K, Behroz A, et al. Risk of transesophageal echocardiography in awake patients with cardiac diseases. *Am J Cardiol* 1988; **62**:337-339.
10. Schlüter M, Hinrichs A, Wolfgang T, et al. Transesophageal two-dimensional echocardiography: comparison of ultrasonic and anatomic sections. *Am J Cardiol* 1984; **5**:1173-1178.
11. Erbel R, Börner N, Steller D, et al. Detection of aortic dissection by transesophageal echocardiography. *Br Heart J* 1987; **58**:45-51.
12. Currie PJ. Transesophageal echocardiography, a new window to the heart [Editorial]. *Circulation* 1989; **80**(1):215-217.
13. Gussenhoven EJ, Taams MA, Roelandt JRTC, et al. Transesophageal two-dimensional echocardiography: its role in solving clinical problems. *J Am Coll Cardiol* 1986; **8**:975-979.
14. Frazin L, Talano JV, Stephanides L, et al. Esophageal echocardiography. *Circulation* 1976; **54**:102-108.

15. Hisanaga K, Hisanaga A, Nagata K, et al. A new transesophageal real-time two-dimensional echocardiographic system using a flexible tube, and its clinical application. *Proceedings of the Japanese Society of Ultrasonic Medicine* 1977; **32**:43-44.
16. Oh JK, Seward JB, Khandheria BK, et al. Transesophageal echocardiography in the intensive care unit [Abstract]. *Circulation* 1988; **74**(Suppl):II-298.
17. Chan KL. Transesophageal echocardiography in the management of intubated cardiac patients [Abstract]. *Circulation* 1988; **74**(Suppl):II-299.
18. Seward JB, Khandheria BK, Oh JK, et al. Transesophageal echocardiography: technique, anatomic correlations, implementations, and clinical applications. *Mayo Clin Proc* 1988; **63**:649-680.
19. Schlüter M, Kremer P, Hanrath P. Transesophageal 2-D echocardiographic feature of flail mitral leaflet due to ruptured chordae tendineae. *Am Heart J* 1984; **108**(3):609-610.
20. Mills TJ, Taliercio CP, Bailey KR, et al. Transthoracic versus transesophageal two-dimensional echo/Doppler flow imaging in surgical patients with mitral regurgitation [Abstract]. *J Am Coll Cardiol* 1989; **13**(Suppl):68a.
21. Currie PJ, Calafiore P, Stewart WJ, et al. Transesophageal echo in mitral prosthetic dysfunction: echo-surgical correlation [Abstract]. *J Am Coll Cardiol* 1989; **13**(Suppl):69a.
22. Khandheria B, Seward J, Oh J, et al. Mitral prosthesis malfunction: utility of transesophageal echocardiography [Abstract]. *J Am Coll Cardiol* 1989; **13**(Suppl):69a.
23. Taams MA, Gussenhover EJ, Cahalan MK, et al. Transesophageal Doppler color flow imaging in the detection of native and Bjork-Shiley mitral valve regurgitation. *J Am Coll Cardiol* 1989; **13**:95-99.
24. Klein AL, Burstow DJ, Jamil Tajik A, et al. Age-related prevalence of valvular regurgitation in normal subjects: a comprehensive color flow examination of 118 volunteers. *Journal of the American Society of Echocardiography* 1990; **2**:54-63.
25. Helmcke F, Nanda NC, Hsiung MC, et al. Color Doppler assessment of mitral regurgitation with orthogonal planes. *Circulation* 1987; **75**(1):175-183.
26. Smith MD, Harrison MR, Kandil H, et al. Overestimation of regurgitant jet area by transesophageal as compared to transthoracic color Doppler [Abstract]. *J Am Coll Cardiol* 1989; **13**(Suppl):68a.
27. Mügge A, Daniel WG, Frank G, et al. Echocardiography in infective endocarditis: reassessment of prognostic implications of vegetation size determined by the transthoracic and the transesophageal approach. *J Am Coll Cardiol* 1989; **14**:631-638.
28. Erbel R, Borner N, Steller D, et al. Detection of aortic dissection by transesophageal echocardiography. *Br Heart J* 1987; **58**:45-51.
29. Mohr-Kahaly S, Erbel R, Rennollet H, et al. Ambulatory follow-up of aortic dissection by transesophageal two-dimensional and color-coded Doppler echocardiography. *Circulation* 1989; **80**:24-33.
30. Erbel R, Mohr-Kahaly S, Rennollet H, et al. Diagnosis of aortic dissection: the value of transesophageal echocardiography. *Thorac Cardiovasc Surg* 1987; **35**:126-133.
31. Sprecher DL, Adamick R, Adams D, et al. In vitro color flow, pulsed, and continuous-wave Doppler ultrasound masking of flow by prosthetic valves. *J Am Coll Cardiol* 1987; **9**:1306-1310.
32. Come PC, Riley MF, Markis JE, et al. Limitations of echocardiographic techniques in evaluation of left atrial masses. *Am J Cardiol* 1981; **48**:947-953.
33. Obeid AI, Marvasti M, Parker F, et al. Comparison of transthoracic and transesophageal echocardiography in diagnosis of left atrial myxoma. *Am J Cardiol* 1989; **63**:1006-1008.
34. Zenker G, Erbel R, Krämer G, et al. Transesophageal two-dimensional echocardiography in young patients with cerebral ischemic events. *Stroke* 1988; **19**:345-348.
35. Aschenberg W, Schlüter M, Kremer P, et al. Transesophageal two-dimensional echocardiography for the detection of left atrial appendage thrombus. *J Am Coll Cardiol* 1986; **7**:163-166.
36. Reeves WC, Movahed A, Chitwood R, et al. Utility of precordial, epicardial and transesophageal two-dimensional echocardiography in the detection of intracardiac foreign bodies. *Am J Cardiol* 1989; **64**:406-409.
37. Daniel WG, Nellessen U, Schroder E, et al. Left atrial spontaneous echo contrast in mitral valve disease: an indicator for an increased thromboembolic risk. *J Am Coll Cardiol* 1988; **11**:1204-1211.
38. Obarski TP, Stewart WJ, Klein AL, et al. Left atrial smoke in mitral valve area, atrial fibrillation, and embolic events [Abstract]. *Journal of the American Society of Echocardiography* 1990; **3**(3):242s.
39. Klein AL, Stewart WC, Cosgrove D, et al. Transesophageal echocardiography in diagnosis of acute pulmonary emboli. *Journal of the American Society of Echocardiography* 1990; **3**:412-415.
40. Fripp RR, Berman W. Noninvasive assessment of cardiopulmonary function in critically ill infants and children. *Clin Chest Med* 1987; **8**(4):619-633.
41. O'Loughin JE, Snyder MS. Pediatric echocardiography 1987. *Pediatr Ann* 1987; **16**(7):572-579.