



The value of echocardiography in mitral valve repair

WILLIAM J. STEWART, MD; ERNESTO E. SALCEDO, MD; DELOS M. COSGROVE, MD

■ Valve repair is the best operation currently available for patients with mitral valve disease. However, repair is technically more difficult than valve replacement and has a risk of early and late failure. Echocardiography permits better diagnosis and management of these problems. Preoperative echocardiography, including Doppler color flow mapping to evaluate intracardiac flow, is used to assess the feasibility of repair. Intraoperatively, epicardial and transesophageal echocardiography are used to monitor surgical results immediately after repair, ensuring successful outcome of surgery.

□ INDEX TERMS: ECHOCARDIOGRAPHY; MITRAL VALVE REPAIR □ CLEVE CLIN J MED 1990; 57:177-183

SURGICAL valvuloplasty to correct mitral regurgitation is increasingly preferred over implantation of a prosthetic valve.¹⁻³ Figure 1 illustrates this trend at our institution from 1980 through 1988, where mitral valve repairs now comprise 70% of all mitral valve operations performed.

In patients who require surgery for mitral regurgitation, valve repair is preferable to valve replacement for several reasons, including lower operative mortality, fewer postoperative complications, better preservation of ventricular function, decreased requirement for anticoagulation, fewer episodes of endocarditis, lower cost, and better long-term survival.^{1,3-10}

REPAIR AND REPLACEMENT COMPARED

At the Cleveland Clinic, 792 patients underwent isolated primary mitral valve operations (repair or replacement without other valve or coronary proce-

dures) from 1980 through 1987 (Cosgrove DE, 1990, unpublished data). This group provides a unique population for comparison of repair with replacement because these patients were operated on by the same surgeons in the same era.

Except for age, the most significant determinant of perioperative and postoperative survival in this group was whether the operation was valve repair or replacement. The perioperative mortality was 4.1% in those who had valve replacement, compared to 0.8% ($P = 0.004$) in those who had valve repair. Mortality was higher in the elderly—greater than 7% in patients over 70 years of age. Mortality was also higher in those with more severe preoperative symptoms or more severe ventricular dysfunction.

The risk of mortality was lower in patients without coronary disease, and three to four times higher in patients who underwent concomitant coronary artery bypass grafting. These findings are similar to those of previous reports of large series of mitral operations. The perioperative mortality rates in our series of mitral operations varied with the cause of the mitral regurgitation—13% in those with ischemic disease, 3% with rheumatic disease, 2.4% with degenerative valve disease.¹

From the Department of Cardiology, The Cleveland Clinic Foundation.

Address reprint requests to W.J.S., Department of Cardiology, The Cleveland Clinic Foundation, One Clinic Center, 9500 Euclid Avenue, Cleveland, Ohio 44195.

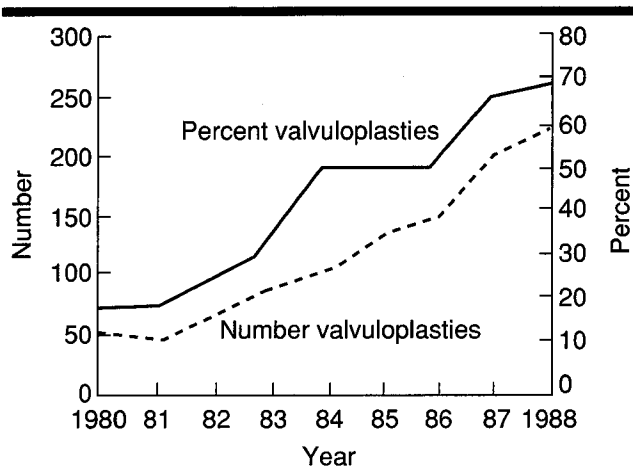


FIGURE 1. Mitral valve procedures. Since 1980, the number (dotted line) and percent (solid line) of mitral valve repairs performed at The Cleveland Clinic Foundation has increased to 250 operations per year. Mitral valve repairs now comprise 70% of all mitral valve operations (from Cosgrove¹).

TABLE
ECHOCARDIOGRAPHY IN MITRAL VALVE REPAIR

Timing	Purpose
Preoperative	Identify candidates for, and timing of, surgery Determine mechanism of regurgitation and feasibility of repair Assess ventricular function Assess severity of regurgitation
Intraoperative, pre-pump	Refine understanding of mechanism Transesophageal echocardiography Obtain baseline information about ventricular and valvular function under anesthesia
Intraoperative, post-pump	Identify failed repairs (8% incidence) Identify surgical complications Determine mechanism of persistent regurgitation
Postoperative	Document successful repair Compare preoperative and postoperative ventricular function Identify late failed repairs Follow patient serially

The lower incidence of adverse outcomes with mitral valve repair compared to replacement has led to our growing use of this surgical option. However, valvuloplasty is technically more difficult than valve replacement and carries a finite risk of early and late failure.¹¹ These problems can be anticipated, diagnosed, and managed with the aid of echocardiography.

Echocardiography is indicated at four points in the management of patients undergoing repair of regurgitant mitral valves (*Table*): preoperatively, in the operating room before and after cardiopulmonary bypass, and postoperatively.¹²

PREOPERATIVE ECHOCARDIOGRAPHY

In patients with mitral valve disease, echocardiography can define the severity¹³ and mechanism of mitral regurgitation, identify other valvular lesions, assess left ventricular function, and estimate the pulmonary artery pressure.¹⁴ Transthoracic echocardiography (TTE) is noninvasive and can be used serially to monitor the progression of the valvular lesion and its hemodynamic consequences. This information aids in identifying candidates for valve surgery and deciding on the timing of surgery.

When surgery is indicated for patients younger than 50 years who have neither angina nor significant risk factors for atherosclerotic disease, preoperative cardiac catheterization may be avoided if echocardiographic data are conclusive. We perform cardiac catheterization primarily to identify coronary atherosclerosis and when echocardiographic results are equivocal or suboptimal in quality.

Predicting feasibility of valve repair

The precise mechanism of mitral valve dysfunction must be ascertained in order to estimate the feasibility of surgical repair and ensure a successful operation. Findings on echocardiography can accurately define the underlying pathologic mechanisms.¹⁵ For example, the direction of the jet, as depicted by Doppler color flow mapping, can define the type of mitral regurgitant lesion and predict the surgical techniques required to repair it.

Echocardiography aids in preoperative counseling regarding available options and the likely outcome of surgery. For example, the ability to repair the valve varies substantially with the type of dysfunction.^{1,15,20} The types of lesions that can be most easily repaired include an isolated area of ruptured chordae to one leaflet (especially the middle scallop of the posterior leaflet), pure annular dilatation, and pure mitral stenosis without substantial subvalvular involvement or severe calcification. If the chordae to the posterior leaflet are ruptured, the likelihood of successful repair is 88% (*Figure 2*). The success rate drops in the presence of extensive calcifications, billowing leaflets, fibrosis, chordal rupture, or leaflet disruption, or when

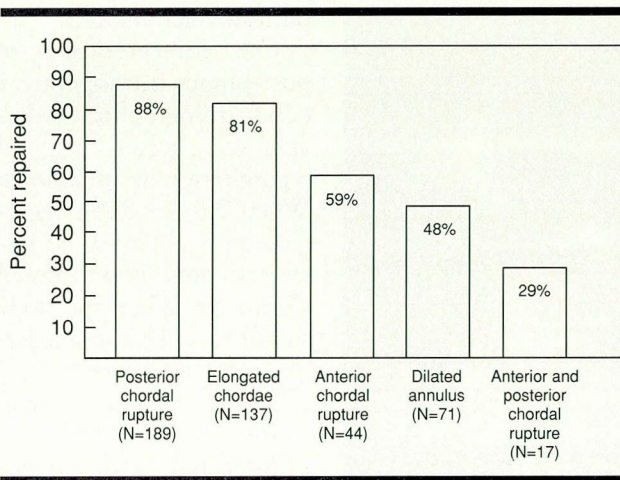


FIGURE 2. In patients with mitral regurgitation caused by degenerative disease, such as mitral prolapse and myxomatous degeneration, the feasibility of mitral valve repair varied with the type of leaflet abnormality (from Cosgrove¹).

both leaflets are involved.^{1,15} Our growing experience with complex abnormalities, such as extensive chordal rupture involving both the anterior and posterior leaflets, has emphasized the value of echocardiography in understanding the mechanism of mitral regurgitation.

INTRAOPERATIVE ECHOCARDIOGRAPHY

In the operating room, we use either transesophageal echocardiography (TEE) or epicardial echocardiography or both, depending on the needs in the individual case and what questions need to be answered during surgery. Intraoperative echocardiographic studies may be done before or after cardiopulmonary bypass; often we do both.^{1,21-31}

The imaging method we use most in mitral valve repair is TEE.^{23,30,31} The TEE transducer is a special endoscope mounted with an echocardiographic transducer (Figure 3). After endotracheal intubation and emptying of the stomach with suction, the scope is inserted and the transducer is positioned in the retrocardiac portion of the esophagus. A series of images is made of the heart to determine structure (with two-dimensional echocardiography) and flow (with Doppler color flow mapping) information.

Our method for using epicardial echocardiography on the surface of the heart during surgery has been published in text and video form.^{21-23,27-29} We use a standard echocardiographic transducer, similar to that

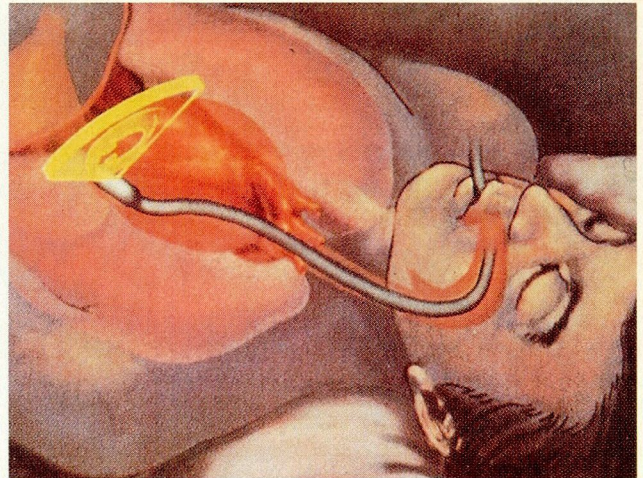


FIGURE 3. Artist's rendering of a patient undergoing TEE during cardiac surgery. The transducer is posterior to the heart, imaging the left ventricle in short axis (from Stewart¹² and by permission from the Hewlett-Packard Company).

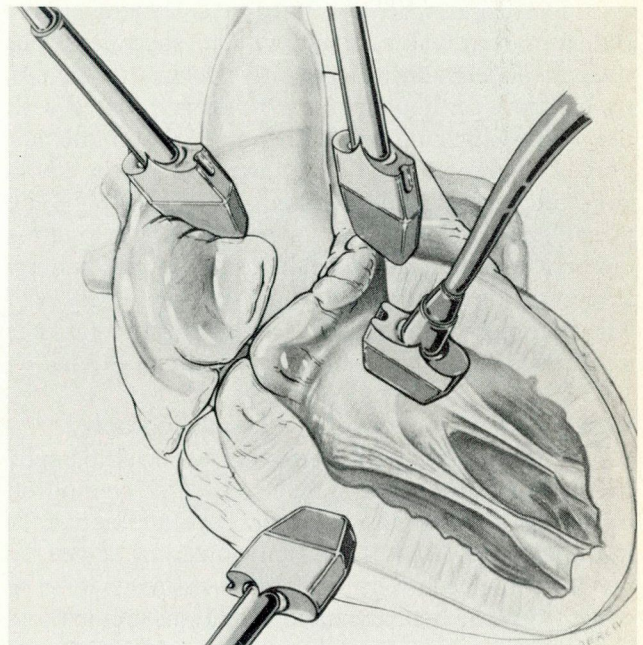


FIGURE 4. Artist's drawing of the four transducer positions used for epicardial echocardiography (from Stewart²¹).

used in the echocardiography laboratory. The transducer is inserted within two sterile sleeves and placed directly on the heart, using each of four transducer positions we have developed (Figure 4).

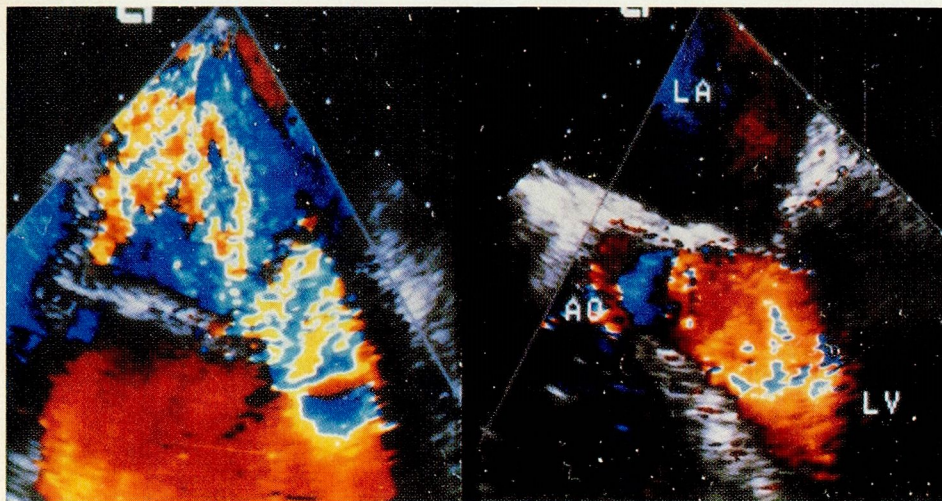


FIGURE 5. Transesophageal color flow images in successful mitral repair, showing the multicolored jet of severe mitral regurgitation pre-pump (left) and no mitral regurgitation post-pump (right). LA, left atrium; LV, left ventricle.

Pre-pump intraoperative echocardiography

In most cases, when preoperative echocardiography indicates that valve repair will be successful, our patients undergo an intraoperative echocardiographic study before cardiopulmonary bypass is initiated with the heart-lung pump. We therefore obtain the improved resolution of TEE in many patients in whom the study was not performed preoperatively. The primary purpose of the intraoperative study is to refine our understanding of the mechanism of mitral dysfunction in the operating room before starting surgery.^{15,16,18} The findings also establish a baseline for the patient's ventricular and valvular function under anesthesia.

Post-pump intraoperative echocardiography

We re-evaluate the patient with echocardiography in the operating room immediately after coming off cardiopulmonary bypass to ensure successful repair. In most instances TEE is the primary screening device. To be valid, these echocardiographic assessments must be made when the hemodynamic conditions mimic those present when the patient is ambulatory. The patient's intravascular volume status, afterload and preload measurements, and cardiac rhythms must be considered so as not to misinterpret the implications of the echocardiographic findings. When the TEE suggests problems, epicardial echocardiography is indicated; this provides more extensive information from multiple planes with more transducers, including continuous wave Doppler measurement of left ventricular

outflow tract velocity.

Our interpretation of post-pump intraoperative echocardiographic studies after valve repair for mitral regurgitation is as follows: When 0 to 1+ mitral regurgitation is observed, no further surgery is performed (Figure 5). When the study shows 3+ to 4+ mitral regurgitation, any adverse complication, or a new problem, cardiopulmonary bypass is reinstituted and further repair or valve replacement is performed (Figure 6). When the mitral regurgitation is moderately severe (2+), more clinical judgment must be applied. In

most cases, in the absence of contraindications, we favor further surgery to improve the result. In some cases, we artificially raise the systemic arterial pressure with phenylephrine, which may bring out latent mitral regurgitation.²⁴

Fortunately, echocardiography can aid in the identification of several complications unique to valve repair, such as dynamic outflow tract obstruction caused by implantation of a fixed annular ring.³²⁻³⁴ During mitral valve repair in patients with normal coronary arteries, we have seen inferior myocardial infarction develop which may be due to right coronary air embolism.³⁹

From 1987 to 1989, we studied 611 patients with intraoperative echocardiography immediately after mitral valve repair. Absence of significant mitral regurgitation after repair was documented in 557 patients (91.2%), a finding which provides great reassurance that further hemodynamic aberrations do not represent valve failure. Significant dysfunction was found in 54 patients (8.8%), leading to a second pump run for immediate correction of the problem (Figure 7). Among patients with immediate failed repair,^{1,11,22} 33 (5.4%) had persistent mitral regurgitation. Fourteen (2.2%) patients required a second pump run because of left ventricular outflow tract obstruction; this phenomenon involves systolic anterior motion of the mitral valve and obstruction similar to that which occurs in hypertrophic cardiomyopathy.³²⁻³⁴ After additional surgery during the same thoracotomy, all 54 patients left the operating room with satisfactory results.

TEE v epicardial echocardiography

During surgery for mitral regurgitation, TEE is our method of choice for routine intraoperative imaging. TEE interrupts the surgical process less than epicardial echocardiography and provides accurate information. When the results of TEE suggest problems, we perform immediate epicardial echocardiography because of its better diagnostic power. For example, it is possible with epicardial echocardiography to image any area of the heart from a greater number of planes, reducing sampling error. In cases of left ventricular outflow tract obstruction, it is possible to estimate the gradient with continuous wave Doppler recordings using the epicardial approach; this cannot be done with transesophageal echocardiographic imaging.

Pitfalls in intraoperative echocardiography

Suboptimal technique can lead to spurious results and erroneous decisions. Intraoperative echocardiography requires that images be interpreted online so that surgical decisions can be made immediately. This task should not be attempted without considerable practical experience in interpreting echocardiograms. The intraoperative study requires precision to ensure accuracy and reliability. Insufficient time, inadequate imaging planes, or suboptimal instrument machine settings will give less reliable information. Interpretation is easier if the overhead lights in the operating room are dimmed during echocardiographic imaging. Electrocautery causes artifacts, which interfere with image quality.

Indications for intraoperative echocardiography

We believe intraoperative echocardiography should be used in all patients undergoing nonprosthetic valve repair surgery—including repair of the aortic valve³⁵

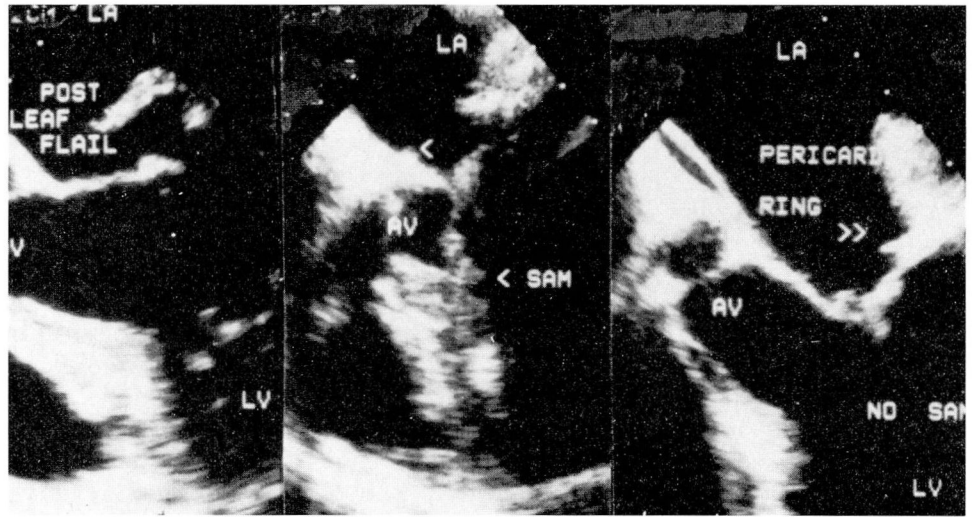


FIGURE 6. Sequential intraoperative transesophageal two-dimensional echocardiographic images in a patient whose attempted valve repair for mitral regurgitation initially failed because of systolic anterior motion (SAM) of the mitral valve, which caused left ventricular outflow tract obstruction. Left: pre-pump, showing posterior (POST) leaflet flail. Middle: after attempted repair with a Carpentier-Edwards ring (arrows), marked SAM is touching the interventricular septum; the patient also had severe persistent mitral regurgitation and high velocity flow in the left ventricular outflow tract measured by continuous wave Doppler. Right: after further valve repair, with substitution of an annuloplasty using a strip of glutaraldehyde-treated pericardium, there is resolution of the mitral regurgitation and the SAM. LA, left atrium; LV, left ventricle.

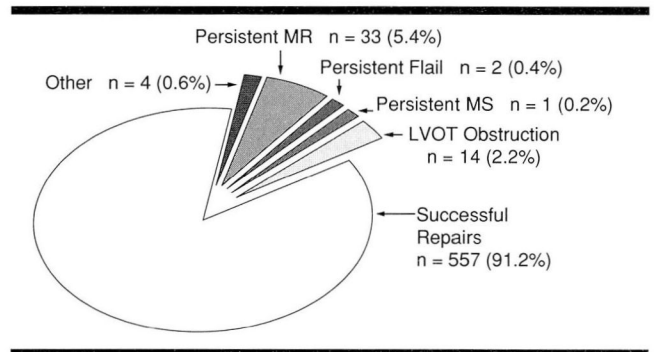


FIGURE 7. Summary of Cleveland Clinic experience with post-pump intraoperative echocardiography in a total of 611 patients: 492 undergoing valve repair for mitral regurgitation (MR), 72 for mitral stenosis (MS), and 42 for both MR and MS. The repair was shown to be successful in 557 patients (91.2%). In 54 patients (8.8%), abnormalities diagnosed by intraoperative echocardiography led to a second run of cardiopulmonary bypass for further repair or mitral valve replacement.

and tricuspid valve,³⁶ as well as the mitral valve. Echocardiography is also useful during myectomy for hypertrophic cardiomyopathy.^{27,37}

Echocardiography allows the surgeon to visualize the abnormalities dynamically in real time, rather than relying on assessments made with the heart flaccid under cardioplegia. The study helps to shorten the surgeon's learning curve³⁸; ie, it provides a "safety net" for unsuccessful valve repair, permitting an immediate second pump run without a second thoracotomy when difficulties are discovered.

POSTOPERATIVE ECHOCARDIOGRAPHY

We usually obtain an echocardiogram prior to discharge or in the first 2 months after surgery. The purpose is to document that the repair was successful, to assess early post-repair left ventricular function, to determine the degree of improvement in pulmonary hypertension, and to provide a baseline under ambulatory conditions for serial postoperative comparisons.

The durability of mitral valve repair appears to be

quite good. Late postoperative failure of mitral valvuloplasty requiring reoperation has occurred in approximately 2% of patients per year.^{1,10} Most of these patients have valves with severe myxomatous degeneration which, in some instances, progresses with further chordal elongation and rupture despite successful repair.¹¹

CONCLUSION

Mitral valve repair has substantial advantages over mitral valve replacement, including a significantly lower incidence of adverse outcomes. The technique of valvuloplasty is a more refined art than that of valve replacement because the surgeon must understand the mechanism of dysfunction in order to correct it. The echocardiogram provides the "road map" for the valve repair surgeon in the same way that the coronary arteriogram is the "road map" for the coronary surgeon.

REFERENCES

1. Cosgrove DM, Stewart WJ. Mitral valvuloplasty. *Curr Probl Cardiol* 1989; 14:355-415.
2. Carpentier A, Deloche A, Dauplain J, et al. A new reconstructive operation for correction of mitral and tricuspid insufficiency. *J Thor Cardiovasc Surg* 1971; 61:1-13.
3. Duran CG, Pomar JL, Revuelta JM, et al. Conservative operation for mitral insufficiency: critical analysis supported by postoperative hemodynamic studies in 72 patients. *J Thor Cardiovasc Surg* 1980; 79:326-332.
4. Loop FD. Long-term results of mitral valve repair. *Semin Thor Cardiovasc Surg* 1989; 1:203-210.
5. Perier P, Deloche A, Chauvaud S, et al. Comparative evaluation of mitral valve repair and replacement with Starr, Bjork, and porcine valve prostheses. *Circulation* 1984; 70(suppl 1):I-187-I-192.
6. Angell WW, Oury JH, Shah P. A comparison of replacement and reconstruction in patients with mitral regurgitation. *J Thor Cardiovasc Surg* 1987; 93:665-674.
7. Galloway AC, Colvin SB, Baumann FG, et al. A comparison of mitral valve reconstruction with mitral valve replacement: intermediate term results. *Ann Thorac Surg* 1989; 47:655-662.
8. Sand ME, Naftel DC, Blackstone EH, et al. A comparison of repair and replacement for mitral valve incompetence. *J Thor Cardiovasc Surg* 1987; 94:208-219.
9. Rankin JS, Feneley MP, Hickey MS, et al. A clinical comparison of mitral valve repair v valve replacement in ischemic mitral regurgitation. *J Thor Cardiovasc Surg* 1988; 95:165-177.
10. Cosgrove DM. Surgery for degenerative mitral valve disease. *Semin Thor Cardiovasc Surg* 1989; 1:183-193.
11. Marwick T, Currie PJ, Stewart WJ, Calafiore PC, Salcedo EE, Loop FD. Echocardiographic evaluation of immediate and late failed mitral valve repair (abstract). *J Am Coll Cardiol* 1989; 13:114A.
12. Stewart WJ, Salcedo EE. Echocardiography in patients undergoing mitral valve surgery. *Semin Thor Cardiovasc Surg* 1989; 1:194-202.
13. Helmcke T, Nanda NC, Hsiung MC, et al. Color Doppler assessment of mitral regurgitation with orthogonal planes. *Circulation* 1987; 75:175-183.
14. Yock PG, Popp RL. Noninvasive estimation of right ventricular systolic pressure by Doppler ultrasound in patients with tricuspid regurgitation. *Circulation* 1984; 70:657-666.
15. Stewart WJ, Chavez AM, Currie PJ, et al. Echocardiographic determination of mitral pathology and the feasibility of repair for mitral regurgitation. *Circulation* 1987; 76:III-434. Abstract.
16. Stewart WJ, Currie PJ, Salcedo EE, et al. Jet direction by color-flow mapping accurately depicts the mechanism of mitral regurgitation (abstract). *Circulation* 1988; 78:II-434.
17. Stewart WJ, Kerber RD. Intraoperative echocardiography. In: Marcus ML, ed. *Cardiac Imaging—Principles and Practice*. Philadelphia: WB Saunders; 1990.
18. Stewart WJ et al. Echocardiography in predicting the feasibility and mechanism of valve repair for mitral regurgitation: assessment of valve motion and Doppler color jet direction. Submitted for publication.
19. Izumi S, Miyatake K, Beppu S, et al. Mechanism of mitral regurgitation in patients with myocardial infarction: a study using real-time two-dimensional Doppler flow imaging and echocardiography. *Circulation* 1987; 76:777.
20. Cosgrove DM, Chavez AM, Lytle BW, et al. Results of mitral valve reconstruction. *Circulation* 1986; 74:1-82.
21. Stewart WJ, Currie PJ, Agler DA, Cosgrove DM. Intraoperative epicardial echocardiography: technique, imaging planes, and use in valve repair for mitral regurgitation. *Dyn Cardiovasc Imag* 1987; 1:179-184.
22. Stewart WJ, Currie PJ, Lytle BW, et al. Intraoperative Doppler color-flow mapping for decision-making in valve repair for mitral regurgitation: technique and results in 100 patients. *Circulation* 1990; 81:556-563.
23. Currie PJ, Stewart WJ, Salcedo EE, et al. Comparison of intraoperative transesophageal and epicardial color-flow Doppler in mitral valve repair (abstract). *J Am Coll Cardiol* 1988; 11:2A.
24. Czer LS, Maurer G, Bolger AF, et al. Intraoperative evaluation of mitral regurgitation by Doppler color-flow mapping. *Circulation* 1987; 76:108-116.
25. Maurer G, Czer LS, Chaux A, et al. Intraoperative Doppler color-flow mapping for assessment of valve repair for mitral regurgitation. *Am J Cardiol* 1987; 60:333-342.
26. Goldman ME, Fuster V, Guarino T, et al. Intraoperative echocardiography for the evaluation of valvular regurgitation: experience in 263 patients. *Circulation* 1986; 74:1-143.

27. Stewart WJ, Schiavone WA, Salcedo EE, Lever HM, Cosgrove DM, Gill CC. Intraoperative Doppler echocardiography in hypertrophic cardiomyopathy: correlations with the obstructive gradient. *J Am Coll Cardiol* 1987; **10**:327.
28. Klein AL, Stewart WJ, Cosgrove DM, Salcedo, EE. Intraoperative epicardial echocardiography: technique and imaging planes. *Echocardiography* 1990; **7**:241-251.
29. Salcedo, EE, Stewart WJ, Klein, A, Cosgrove DM. Intraoperative epicardial echocardiography: epicardial approach, preparation, method of imaging and echographic anatomy. *Am J Card*. In press.
30. Seward JB, Khandheria BK, Abel MD, et al. Transesophageal echocardiography: technique, anatomic correlations, implementations, and clinical applications. *Mayo Clin Proc* 1988; **63**:649-680.
31. DeBruijn NP, Klements FM. Transesophageal echocardiography. Dordrecht, The Netherlands: Nijhoff Publishing; 1987.
32. Kreindel MS, Schiavone WA, Lever HM, et al. Systolic anterior motion of the mitral valve after Carpentier ring valvuloplasty for mitral valve prolapse. *Am J Cardiol* 1986; **57**:408.
33. Schiavone WA, Cosgrove DM, Lever HM, Stewart WG. Long-term follow-up of patients with left ventricular outflow tract obstruction following Carpentier ring mitral valvuloplasty. *Circulation* 1988; **78**(suppl 1):1-60.
34. Stewart WJ, Currie PJ, Schiavone WA. Intraoperative echocardiography in patients with left ventricular outflow tract obstruction. In: Maurer G, Mohl W, eds. *Echocardiography and Doppler in Cardiac Surgery*. New York: Igaku-Shoin; 1989:331-345.
35. Stewart WJ, Currie PJ, Salcedo EE, et al. Intraoperative echocardiography in aortic valve repair (abstract). *Circulation* 1988; **78**:II-434.
36. Klein AK, Stewart WJ, Salcedo EE, et al. The role of intraoperative echocardiography in valve repair for tricuspid regurgitation (abstract). *J Am Coll Cardiol* 1990.
37. Marwick TH, Stewart WJ, Karam R, et al. Intra-operative echocardiography guides extent of myectomy in hypertrophic cardiomyopathy (abstract). *Circulation* 1989; **80**:II-268.
38. Antunes MJ, Colsen PR, Kinsley RH. Mitral valvuloplasty: A learning curve. *Circulation* 1983; **68**:II-70-II-75.
39. Obarski T, Stewart WJ, Cosgrove DM, et al. Increased incidence of inferior myocardial infarction after valve repair for mitral regurgitation, a possible role for coronary air embolism. *Am J Cardiol* 1990; **65**:65-4.

