



# Myelodysplastic syndrome and transient acantholytic dermatosis

PAUL F. ROCKLEY, MD; WILMA F. BERGFELD, MD; KENNETH J. TOMECKI, MD; JAN K. BRYDON, MD

■ Focal acantholytic dyskeratosis consistent with the clinical and histological features of Darier's type of transient acantholytic dermatosis occurred in a man with myelodysplasia. Topical steroids and systemic antihistamines provided temporary and moderate relief from pruritus, but failed to control the dermatosis.

□ INDEX TERMS: ACANTHOLYSIS; MYELODYSPLASTIC SYNDROMES □ CLEVE CLIN J MED 1990; 57:575-577

**T**RANSIENT ACANTHOLYTIC DERMATOSIS (TAD) is an entity of unknown etiology described initially by Grover in 1970.<sup>1</sup> It is characterized by self-limited, pruritic papules and vesicles, usually located on the trunk and extremities of middle-aged and older persons. Focal acantholysis with cleft formation is a consistent histological feature. In 1977, Chalet and associates<sup>2</sup> recognized four histopathologic patterns of TAD: Darier's type, Hailey-Hailey type, pemphigus vulgaris type, and spongiotic type. We present a case of a focal acantholytic dyskeratosis consistent with the clinical and histologic features of Darier's type of TAD in a patient with myelodysplasia.

## CASE REPORT

A 64-year-old white man had severely pruritic, diffuse, red papules, vesicles, and pustules that began in May 1987. He had previously enjoyed excellent health.

From the Department of Dermatology, The Cleveland Clinic Foundation. Dr. Brydon is in private practice in Erie, Pennsylvania.

Address reprints to K.J.T., Department of Dermatology, The Cleveland Clinic Foundation, One Clinic Center, 9500 Euclid Avenue, Cleveland, Ohio 44195.

Skin changes initially affected his back and chest with episodic paroxysms of pruritus. He had discrete, red papulovesicles and papulopustules that measured 1 mm to 2 mm in diameter. During June, the papules and vesicles spread to his upper and then lower extremities, sparing only his palms, soles, mucous membranes, nails, head, and neck (*Figure 1*).

Further evaluation revealed that his white blood cell count was  $2.6 \times 10^3/\text{mm}^3$  with 96% lymphocytes; hematocrit was 24%; erythrocyte count was  $2.4 \times 10^6/\text{mm}^3$ ; hemoglobin was 8.5 g/dL; and platelet count was 40,000/ $\text{mm}^3$ . A bone marrow aspiration showed myelodysplasia. The results of a liver-spleen scan were normal.

A skin biopsy from the left calf revealed surface encrustation, focal areas of acantholytic epidermal cells that formed enlarged subcorneal bullae containing neutrophils, and a perivascular mononuclear infiltrate in the dermis, compatible with impetigo or subcorneal pustular dermatosis.

He applied triamcinolone acetonide (Aristocort A) 0.1% cream three times daily to affected sites and, initially, that reduced the pruritus. With discontinuation, the pruritus recurred and the papules persisted. Other therapy with natural sunlight exposure, topical erythromycin (2%) solution, and systemic antihistamines failed to control the itch and skin disease.

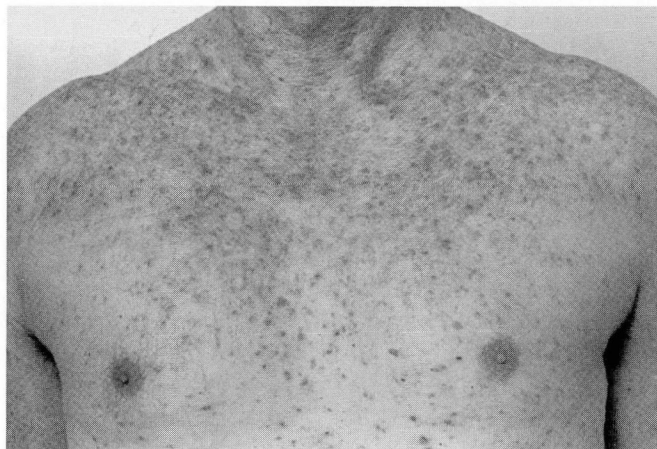

FIGURE 1. Discrete and confluent red papules on the chest consistent with a diagnosis of TAD.

Two additional biopsies showed focal acantholytic dyskeratosis consistent with Darier's type of TAD. The stratum corneum was hyperkeratotic with regions of orthokeratosis and parakeratosis and there was sharply circumscribed focal acantholysis of the epidermis with suprabasal cleft formation (Figure 2 and 3). Dyskeratotic cells were present in the upper epidermis and there was a perivascular lymphohistiocytic infiltrate in the papillary dermis. Direct immunofluorescent microscopy of papules and vesicles revealed no deposition of IgG, IgM, IgA, C3, and fibrinogen.

In light of his advanced age and mild cytopenia, chemotherapy was not administered and supportive transfusions were used to maintain stable blood counts. Because of his myelodysplasia, the usual therapies for TAD, such as UVB, PUVA, prednisone, dapsone, and isotretinoin, were withheld. Topical steroids and systemic antihistamines provided only temporary and moderate relief of symptoms and disease. The patient died in 1988, following the development of leukemia.

#### COMMENT

Ackerman<sup>3</sup> coined the term "focal acantholytic dyskeratosis" to describe the dominant histologic features seen in a variety of clinical entities, including Darier's type of TAD and Darier's disease. These features include suprabasal clefts, acantholytic and dyskeratotic cells within the epidermis, hyperkeratosis, and parakeratosis. Despite these similarities, Darier's type of TAD can usually be distinguished from Darier's disease because the lesions in TAD are focal, involve only a few

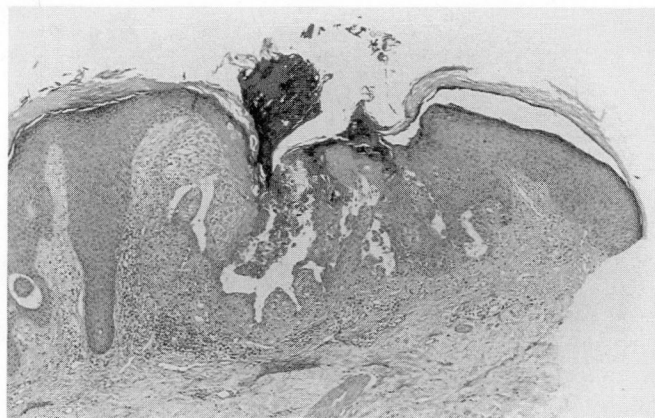


FIGURE 2. Skin biopsy results showed a crusted papule with superficial scale crust, epidermal acanthosis with suprabasilar acantholysis and vesicle formation. Prominent acantholytic cells are observed within the vesicle (original magnification  $\times 20$ ).

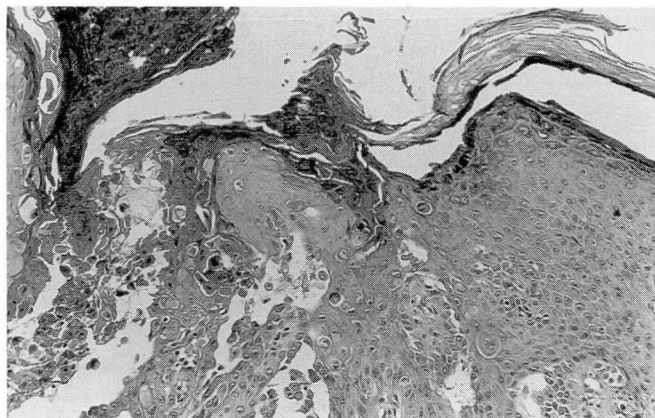


FIGURE 3. On high power, there is demonstration of a superficial keratin plug and a scale crust with associated prominent epidermal acantholysis, vesicle formation, and dyskeratotic cells (original magnification  $\times 40$ ).

rete ridges, and are separated from each other by normal skin. In contrast, the lesions in Darier's disease are frequently confluent and have significantly more overlying parakeratosis.<sup>4</sup>

The present case of Darier's type of TAD shares several features with previously reported cases.<sup>2</sup> The patient was an elderly, white man without a personal or family history of any skin disease. His lesions exhibited a typical morphology (randomly scattered papules and vesicles) and distribution (involvement of the trunk and extremities with sparing of the palms, soles, nails, and mucous membranes).



The etiology of TAD is unknown. Actinic exposure, initially thought to be a causal link to TAD,<sup>5</sup> has no proven relationship with the development of TAD. Excessive body heat and sweating may precipitate pruritus and TAD.<sup>6</sup> Horn and associates<sup>7</sup> reported four cases of TAD in febrile, neutropenic patients who were immunocompromised by malignant neoplasms or chemotherapy.

Myelodysplastic (dysmyelopoietic) syndromes are a heterogeneous group of stem cell dyscrasias characterized by less than 30% type I and II myeloblasts in the bone marrow and a decrease in one or more formed elements of the blood.<sup>8</sup> The syndromes can present with anemia, neutropenia (with or without monocytosis), and thrombocytopenia, alone or in various combinations. The syndromes represent a preleukemic stage of

variable duration between isolated cytopenia and acute leukemia.

In contrast to the multitude of nonspecific cutaneous diseases associated with leukemic states, acute febrile neutrophilic dermatosis (Sweet's syndrome) and pernio are the only specific cutaneous diseases associated with preleukemic states. Cooper and associates<sup>9</sup> described two patients with Sweet's syndrome and preleukemic pancytopenia. There have been five case reports of pernio associated with idiopathic myelodysplasia.<sup>10</sup>

This is the first reported case of TAD associated with myelodysplasia. It is not clear whether this association is coincidental or represents a definite relationship. We encourage physicians to report additional cases in order to clarify this issue.

# REFERENCES

1. Grover RW. Transient acantholytic dermatosis. *Arch Dermatol* 1970; **101**:426-434.
2. Chalet M, Grover RW, Ackerman AB. Transient acantholytic dermatosis, a re-evaluation. *Arch Dermatol* 1977; **113**:431-435.
3. Ackerman AB. Focal acantholytic dyskeratosis. *Arch Dermatol* 1972; **106**:702-706.
4. Ackerman AB. Intraepidermal vesicular and pustular dermatitis. [In] *Histologic Diagnosis of Inflammatory Skin Diseases*. Philadelphia, Lea and Febiger, 1978, pp 538-539.
5. Fawcett HA, Miller JA. Persistent acantholytic dermatosis related to actinic damage. *Br J Dermatol* 1983; **109**:349-354.
6. Hu CH, Michael B, Farber EM. Transient acantholytic dermatosis: a skin disorder related to heat and sweating. *Arch Dermatol* 1985; **121**:1439-1441.
7. Horn TD, Groleau GE. Transient acantholytic dermatosis in immunocompromised febrile patients with cancer. *Arch Dermatol* 1987; **123**:238-240.
8. Bennett JM, Catovsky D, Daniel MT, et al. The French-American-British (FAB) Cooperative Group: proposals for the classification of the myelodysplastic syndromes. *Br J Haematol* 1982; **51**:189-199.
9. Cooper PH, Innes DJ, Greet KE. Acute febrile neutrophilic dermatosis (Sweet's syndrome) and myeloproliferative disorders. *Cancer* 1983; **51**:1518-1526.
10. Kelly JW, Dowling JP. Pernio—a possible association with chronic myelomonocytic leukemia. *Arch Dermatol* 1985; **121**:1048-1052.

# Errata

In the June 1990 (Volume 57) issue, there are two errors in the article "Pacemaker and defibrillator combination therapy for recurrent ventricular tachycardia," by Martin Masterson, MB, BCh, and associates. On page 331, the second sentence of the first paragraph of the section, "Patient population," should read: "These patients had been referred to our institution because of

hypotensive VTs or sudden cardiac death that was refractory to conventional antiarrhythmic therapy."

On page 335, the last sentence of the section, "Complications," should read: "This was managed by reprogramming the lower rate or inactivating the antibradycardia backup function."