

Clinical features of the yellow nail syndrome

EDWARD M. CORDASCO, JR, DO; S. BEDER, MD; ADELE COLTRO, MD; S. BAVBEK, MD; H. GURSES, MD; ATUL C. MEHTA, MD

■ The yellow nail syndrome is a rare cause of exudative pleural effusions. Diagnosis is based on the presence of typical clinical features, striking nail changes, lymphedema, and pleural effusions of undetermined etiology. There is no direct relationship between the syndrome and primary immunologic disorders, malignancies, endocrine abnormalities, or connective tissue diseases. In patients with symptomatic pleural effusions, pleurodesis is beneficial but no treatment for the nail changes has been devised.

□ INDEX TERMS: LYMPHEDEMA, PLEURAL EFFUSION, YELLOW NAIL SYNDROME □ CLEVE CLIN J MED 1990; 57: 472-476

THE YELLOW NAIL SYNDROME is characterized by extremity and facial lymphedema, pleural effusions, and slowly growing, distorted, discolored nails. In 1964, Samman and White¹ first coined this term in their report of 13 patients with yellow nails, 10 of whom also had primary lymphedema. Emerson,² in 1966, described several patients with chronic, primary lymphedema, pleural effusions, and yellow nails and is credited with recognizing the triad composing the complete syndrome.

Impaired lymphatic drainage as a consequence of deficient, hypoplastic lymphatic vessels produces the edema and effusions characterizing this syndrome.¹ As suggested by Emerson, nail discoloration may also result from impaired lymphatic flow. However, others have suggested that oxidation of lipid components within the nail (producing lipofuscin) may account for the peculiar nail color.³

Other nail changes in patients with this syndrome have been described and include prominent transverse and longitudinal ridges, nail opacity with or without onycholysis, nail thickening, and over-curvature.^{1,4-6} As

originally noted by Emerson, these nail changes and the discoloration may herald the onset of the syndrome, preceding the appearance of lymphedema and pleural effusions by months or years.² All patients with the syndrome do not have all of these nail changes nor do all the reported cases of patients with yellow nails describe the presence of lymphedema or effusions.

We report a case of an individual with the yellow nail syndrome who displays the classical clinical features comprising this condition. In addition, we review the literature of reported cases summarizing the clinical features of this syndrome.

CASE REPORT

A 45-year-old man was admitted to Ankara University Medical Faculty, Ankara, Turkey, for evaluation of chest discomfort and exertional dyspnea of 1 year's duration. He described a constant aching sensation in the anterior chest most noticeable with deep inspiration. The patient also noted facial puffiness and discolored, thickened, and slowly growing finger- and toenails during the preceding 6 months (*Figure 1*). He also reported sinus fullness and nasal drainage over the past several years necessitating frequent courses of antibiotics for treatment of presumed sinusitis. He was an active, 25 pack/year cigarette smoker, had worked in man-

From the Department of Pulmonary Disease, The Cleveland Clinic Foundation, and Ankara University Medical Faculty (H.G.), Ankara, Turkey.

Address reprint requests to A.C.M., Department of Pulmonary Diseases, The Cleveland Clinic Foundation, One Clinic Center, 9500 Euclid Avenue, Cleveland, Ohio 44195.

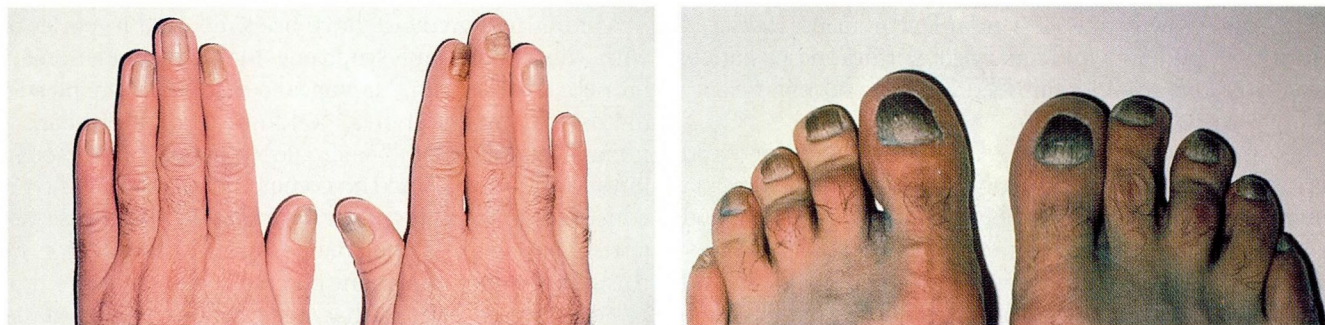


FIGURE 1. Typical finger- and toenail changes in a patient with yellow nail syndrome: yellowish-brown discoloration, prominent horizontal and transverse ridges, and increased side-to-side curvature of the nails.

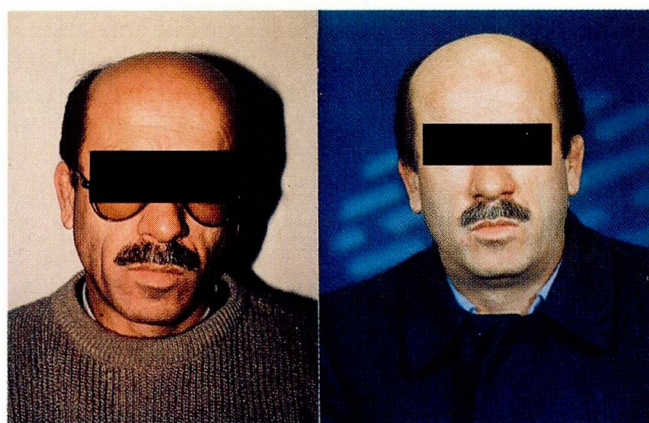


FIGURE 2. Facial edema in a patient with yellow nail syndrome (right), compared with facial features before (left) the syndrome developed.

agement positions throughout his life, and had no unusual hobbies. His family and earlier medical histories were unremarkable.

Physical examination disclosed a healthy-appearing male with normal vital signs. Extremity examination was notable for thickened, yellow-green nails with prominent transverse ridges. Chest examination revealed dullness to percussion of both bases and diminished, bibasilar breath sounds on auscultation. The remainder of the physical examination was unremarkable.

A chest radiograph revealed bilateral pleural effusions. Pulmonary function testing demonstrated reduction of the FVC, FEV₁, and TLC to 57%, 78%, and 56% of predicted maximal values respectively. Arterial blood gases on room air showed a pH of 7.4, PCO₂ of 45 mmHg, and PaO₂ of 46 mmHg. Results of a complete blood count with differential, urinalysis, electrolyte studies,

liver function testing, coagulation parameters, and serum and urine protein electrophoresis were normal. Antinuclear antibody and rheumatoid factor from several serum samples were negative. An electrocardiogram showed sinus rhythm. Tuberculin skin testing was negative with reactive controls. Pleural fluid analysis from multiple thoracentesis of both the right and left thorax revealed the fluid to be an exudate. Cytology, acid-fast smears, and cultures of the pleural fluid were negative. Bilateral Cope needle pleural biopsies revealed only a chronic inflammatory state.

Normal airway and endobronchial mucosa were noted on fiberoptic bronchoscopy. Bronchial washings for cytology, acid-fast bacilli, and fungi were negative.

Upper abdominal ultrasound, abdominal lymphangiography, and bilateral lower extremity lymphangiograms were all normal. Based on the patient's clinical course and unremarkable laboratory studies, the diagnosis of yellow nail syndrome was established. He subsequently underwent successful bilateral pleurodesis with bleomycin and *Corynebacterium parvum* (Coparvax) for control of the pleural effusions. This intervention resulted in symptomatic improvement and relief of hypoxemia. At follow-up several months later the patient was asymptomatic and his physical examination was unchanged.

DISCUSSION

The yellow nail syndrome is a rare entity; approximately 100 cases have been reported since its original description.⁷ About twice as many females as males are affected.⁷⁻⁹ The median age of onset is 40 years,⁷ although it has been recognized as early as birth^{2,10-12} and as late as the seventh decade.^{8,13} Approximately 40% of patients with this syndrome present initially with the characteristic nail changes,⁷ which include yellow-green to brown discoloration.

tion, slow growth rate (less than 0.25 mm per week),^{7,14} transverse and longitudinal ridging, thickening, cuticle loss, over-curvature, diminished lunulae and nail opacity with or without onycholysis.^{1,4-6}

Nail yellowing is not specific to this syndrome and has occurred following treatment with tetracycline and after using certain nail polishes.¹⁵ Nail discoloration and thickening may be age related. Onychomycosis can produce asymmetrical destruction of the nail plate and thickening, with resulting distortion of the nail.¹⁶ These conditions may mimic some of the changes characteristic of yellow nail syndrome but the history, patient age, and mycological assessment of nail clippings should clarify the diagnosis.

Although lymphedema develops in 80% of patients during the course of illness, only one third report lymphedema as the initial manifestation.⁷ The face, lower extremities, and hands are most commonly involved (Figure 2). Ascites has been rarely described as an initial presenting feature.¹⁶

When present, pleural effusion is usually bilateral. It may be unilateral, with no preference for the right or left hemithorax. The effusions tend to persist, infrequently resolve spontaneously, and rapidly reaccumulate within days of a thoracentesis.^{2,8,15}

Two thirds of patients with the syndrome manifest pleural pulmonary symptoms including cough, dyspnea, and chest discomfort.⁷ Chronic infectious respiratory illnesses have been associated with this syndrome and include bronchitis, bronchiectasis, sinusitis, pneumonia, pleuritis, tuberculosis, and empyema.^{2,7,8,17,18} As a result of this association, respiratory tract infections are thought to produce both the pulmonary symptoms and pleural effusions by damaging bronchioles and lymphatic vessels.^{8,19}

Since hypogammaglobulinemic immune states are known to permit the development of chronic, recurrent infectious respiratory tract diseases, several authors have attempted to verify the presence of this immune state in patients with the yellow nail syndrome.⁸ Few reports have documented concomitant hypogammaglobulinemia and the yellow nail syndrome^{10,12,20,21}; hence, the role of respiratory infections and immune deficiency in the genesis of this syndrome is speculative.

Acquired immunodeficiency syndrome (AIDS) has been described in association with yellow nails and some of the classical nail changes, but none of the patients in these reports has yet developed lymphedema or pleural effusions.^{22,23} The relationship between the cell-mediated and humoral deficiencies of AIDS and the development of yellow nails is unclear.

Various malignancies have been reported in patients with the yellow nail syndrome including melanoma,² bronchial carcinoma,²⁴ laryngeal carcinoma,²⁵ anaplastic metastatic malignancies,⁸ endometrial adenocarcinoma,²⁶ Waldenstrom's macroglobulinemia,²⁷ and Hodgkin's lymphoma.¹² Since no common malignant cell type consistently accompanies the syndrome, these case reports may represent the chance, sporadic association of this syndrome to malignant processes.

An array of diseases has been reported in patients with the yellow nail syndrome, including Raynaud's disease,¹⁴ rheumatoid arthritis,^{20,28} Hashimoto's thyroiditis,²⁹ thyrotoxicosis,¹⁹ hypothyroidism,^{24,30,31} hyperthyroidism,³² diabetes mellitus,^{7,18,33} sleep apnea,³⁴ nephrotic syndrome,³⁵ intestinal lymphangiectasis,^{36,37} protein-losing enteropathy,³⁸ and postmyocardial infarction.³⁹ Additionally, one case each of idiopathic pericardial effusion,⁴⁰ asthma,³¹ and penicillamine therapy⁴¹ have been reported in association with the syndrome. Given the wide spectrum of these illnesses, it is difficult to determine a "common etiological thread" between these diseases and the yellow nail syndrome.

Pulmonary function testing in patients with this syndrome has most frequently shown combined obstructive and restrictive patterns.^{10,12,16,42,43} Purely restrictive and normal air flow patterns have also been demonstrated.¹¹ Since some of the associated or underlying diseases likely cause some ventilatory impairment, no pattern seems specific for this syndrome.

Microscopic examination of pleural biopsy specimens has revealed fibrosis, nonspecific inflammation, and lymphocytic cellular infiltrate with nodular lymphoid aggregates and occasionally, dilated lymphatic channels.^{2,12,18,27,41,43,44} However, none of these features is specific for or pathognomonic of pleural involvement in this syndrome.

Typically, the pleural fluid is straw-colored and can be characterized as an exudate with total LDH greater than 200 IU/L, the LDH pleural fluid to serum ratio greater than 0.6, and the total protein content greater than 3 g/dL.⁷ The pleural fluid glucose is usually normal, the pH close to 7.4, the erythrocyte count less than 100,000/ μ L, and the white blood cell count less than 100,000/ μ L with a lymphocytic predominance (greater than 80% of the differential).⁷

The pleural fluid albumin kinetics have been studied separately by Emerson,² Runyan,⁴² and Mambretti-Zumwalt.²⁶ Emerson noted a "slow turnover rate,"² Runyan was able to quantify the lymph flow (0.16 mm/h/kg) and formation (0.13 mm/h/kg) rates,⁴² and Mambretti-Zumwalt calculated a prolonged pleural fluid half-life of 5

days.²⁶ These studies and observations support the notion that impaired lymphatic flow from the pleural space rather than "overproduction" of pleural fluid leads to the development of pleural effusions.

Lymphangiographic studies performed in a limited number of patients with the syndrome have demonstrated deficient hypoplastic and varicose lymph trunks in the involved extremity.^{1,2,7,11,15,26,43,45} These results suggest that a primary structural abnormality of the lymphatic system is responsible for the development of lymphedema in this syndrome.

Treatment is directed toward symptomatic improvement. Patients with dyspnea related to pleural effusions usually undergo multiple thoracenteses since the pleural fluid reaccumulates rapidly.^{2,8,16} Frequent thoracic "taps" may produce systemic hypoalbuminemia and thus aggravate pleural fluid and lymphedema formation.⁷ Chemical or abrasive pleurodesis has been successful in preventing pleural fluid reaccumulation.^{8,28} Pleurectomies have been performed in patients who fail pleurodesis with varying success rates.^{10,12,44}

Extremity lymphedema must be treated early in the course of illness before chronic, fibrotic changes and connective tissue overgrowth occur.^{46,47} Elevation of the affected limb and support stockings help promote drainage.^{46,48} Aggressive antibiotic treatment of infectious complications such as cellulitis and lymphangitis is imperative in order to prevent further lymphatic damage and extremity injury.⁴⁷ Diuretics have not been successful in the long-term management of peripheral edema.^{8,29,43}

A variety of medications has been used specifically for treatment of the nails; there is no universally effective or accepted treatment modality. Orally administered Vitamin E and local steroid injections of the nailbed have been reported as successful in several case reports.^{3,33,49,50} Variable results have been reported with systemic steroids therapy.^{29,39} Periodic surgical debridement of the nail and permanent removal of severely inflamed nails have also been recommended therapies.⁴⁸ One case reported partial improvement of the nails with biotin, 100 mg per day.¹⁵

REFERENCES

- Samman PD, White WF. The "yellow nail" syndrome. *Br J Dermatol* 1964; **76**:153-157.
- Emerson PA. Yellow nails, lymphoedema and pleural effusions. *Thorax* 1966; **21**:247-253.
- Norton L. Further observations on the yellow nail syndrome with therapeutic effects of oral alpha-tocopherol. *Cutis* 1985; **36**:457-462.
- Venencie PY, Dicken CH. Yellow nail syndrome: Reports of five cases. *J Am Acad Dermatol* 1984; **10**:187-192.
- Pavlidakey GP, Hashimoto K, Blum D. Yellow nail syndrome. *J Am Acad Dermatol* 1984; **11**:509-512.
- Sammon PD. The yellow nail syndrome. *Trans St Johns Hosp Dermatol Soc* 1973; **59**:37-38.
- Nordkild P, Kromann-Andersen H, Struve-Christensen E. Yellow nail syndrome—the triad of yellow nails, lymphedema, and pleural effusions. *Acta Med Scand* 1986 **219**:221-227.
- Hiller E, Rosenow EC 3d, Olsen AM. Pulmonary manifestations of the yellow nail syndrome. *Chest* 1972; **61**:452-458.
- Tita JA, Wiedemann HP, Weinstein CE. Pleural effusions and abnormal nails. *Hosp Pract* 1986; **21**:65-68.
- Hurwitz PA, Pinals DJ. Pleural effusion in chronic hereditary lymphedema (Nonne, Milroy, Meigs's disease). Report of two cases. *Radiology* 1964; **82**:246-248.
- Kamatani M, Rai A, Hen H, et al. Yellow nail syndrome associated with mental retardation in two siblings. *Br J Dermatol* 1978; **99**:329-333.
- Siegelman SS, Heckman BH, Hasson J. Lymphedema, pleural effusion, and yellow nails; associated immunologic deficiency. *DIS Chest* 1969; **56**:114-117.
- Marks R, Ellis JP. Yellow nails. A report of six cases. *Arch Dermatol* 1970; **102**:619-623.
- Samman PD, Strickland B. Abnormalities of the fingernails associated with impaired peripheral blood supply. *Br J Dermatol* 1962; **74**:165-173.
- Meits HG, Gruel H, Perschmann U, Jost G, Hubbes A, Greithes A. Skleronychie-syndrom. *Dtsch Med Wochenschi* 1973; **40**:1829-1834.
- Dwek JH, Greenberg GM. Yellow nails, lymphedema, and pleural effusions. *N Y State Med J* 1973; **73**:1093-1097.
- Zerfas AJ. Yellow nail syndrome with bilateral bronchiectasis. *Proc Roy Soc Med* 1966; **59**:448.
- Prasad TR. Yellow nail syndrome. [letter] *Chest* 1980; **77**:580.
- Yellow nails syndrome and oedema. [editorial] *Br Med J* 1972; **4**:130.
- Nakielna EM, Wilson J, Ballon HS. Yellow nail syndrome: report of three cases. *Can Med Assoc J* 1976; **115**:46-48.
- Mattingly PC, Bossingham DH. Yellow nail syndrome in rheumatoid arthritis: report of three cases. *Ann Rheum Dis* 1979; **38**:475-478.
- Chernosky ME, Finley VK. Yellow nail syndrome in patients with acquired immunodeficiency disease. *J Am Acad Dermatol* 1985; **13**:731-736.
- Scher RK. Acquired immunodeficiency syndrome and yellow nails. [letter] *J Am Acad Dermatol* 1988; **18**:758-759.
- Thomas PS, Sidhu B. Yellow nail syndrome and bronchial carcinoma (letter). *Chest* 1987; **92**:191.
- Guin JD, Elleman JH. Yellow nail syndrome: Possible association with malignancy. *Arch Dermatol* 1979; **115**:734-735.
- Mambretti-Zumwalt J, Seidman JM, Higano N. Yellow nail syndrome: complete triad with pleural protein turnover studies. *South Med J* 1980; **73**:995-997.
- D'Souza MF, Mahon WE. Generalized lymphoedema with yellow nails, pleural effusions and macroglobulinemia. *Proc Roy Soc Med* 1970; **63**:456.
- Mattingly PC, Bossingham DH. Yellow Nail Syndrome in Rheumatoid Arthritis: report of three cases. *Ann Rheum Dis* 1979; **38**:475-478.
- Dilley JJ, Kierland RR, Randall RV, et al. Primary lymphedema associated with yellow nails and pleural effusions. *JAMA* 1968; **203**:670-673.
- Nelson LM. Yellow nail syndrome. *Arch Derm* 1969; **100**:499-500.
- Marks R, Ellis JP. Yellow nails. A report of six cases. *Arch Derm* 1970; **102**:619-623.
- Scher RK, Farrell DS. Yellow nail syndrome and half-and-half nail. [letter] *Arch Dermatol* 1987; **123**:710-711.
- Abell E, Samman PD. Intradermal triamcinolone acetone injection

- in the yellow nail syndrome. *Trans St Johns Hosp Derm Soc* 1973; **59**:114-117.
34. Knuckles ML, Hodge SJ, Roy TM, Snider HL. Yellow nail syndrome in association with sleep apnea. *Int J Derm* 1986; **25**:588-589.
 35. Cockram CS, Richards P. Yellow nails and nephrotic syndrome. *Br J Derm* 1979; **101**:707-709.
 36. Duhra PM, Quigley EM, Marsh MN. Chylous ascites, intestinal lymphangiectasis and the "yellow nail" syndrome. *Gut* 1985; **26**:1266-1269.
 37. Ocaña I, Bejarano E, Ruiz I, Ribera E, Pigrau C, Martinez-Vázquez JM. Intestinal lymphangiectasia and the yellow nail syndrome. [letter] *Gastroenterology* 1988; **94**:858.
 38. Battaglia A, diRicco G, Mariani G, Giuntini C. Pleural effusion and recurrent broncho-pneumonia with lymphedema, yellow nails and protein-losing enteropathy. *Eur J Respir Dis* 1985; **66**:65-69.
 39. Scott J. Cardiac infarction and the yellow nail syndrome. *Proc R Soc Med* 1974; **67**:323.
 40. Wakasa M, Imaizumi T, Suzama A, Takeshita A, Nakamura M. Yellow nail syndrome associated with chronic pericardial effusion. *Chest* 1987; **92**:366-367.
 41. Ilchyshyn A, Vickers CF. Yellow nail syndrome associated with penicillamine therapy. *Acta Dermatol Venerol* 1983; **63**:554-555.
 42. Runyon BA, Forker EL, Sopko JA. Pleural-fluid kinetics in a patient with primary lymphedema, pleural effusions, and yellow nails. *Am Rev Respir Dis* 1979; **119**:821-825.
 43. Beer DJ, Pereira W Jr, Snider GL. Pleural effusion associated with primary lymphedema: a perspective on the yellow nail syndrome. *Am Rev Respir Dis* 1978; **117**:595-599.
 44. Solal-Celigny P, Cormier Y, Fournier M. The yellow nail syndrome. Light and electron microscopic aspects of the pleura. *Arch Pathol Lab Med* 1983; **107**:183-185.
 45. Muller RP, Peters PE, Echternacht-Happle K, Happle R. Roentgenographic and clinical signs in the yellow nail syndrome. *Lymphology* 1979; **12**:257-261.
 46. Wilson SE, Veith FJ, Hobson RW, Williams RA. *Vascular Surgery Principles and Practices*. 1st ed. New York, McGraw-Hill, 1987.
 47. Schinger A, Harrison EG, James JM. Idiopathic lymphedema. Review of 131 cases. *JAMA* 1962; **182**:14-22.
 48. Buchbinder MJ, Brill LR, Louis JM. Lymphedema praecox and yellow nail syndrome. A literature review and case report. *J Am Podiatr Med Assoc* 1978; **68**:592-594.
 49. Ayers S Jr, Mihan R. Yellow nail syndrome. *Arch Dermatol* 1973; **108**:267.
 50. Hazzelrigg DE, McElroy RJ. The yellow nail syndrome. *J Assoc Milit Derm* 1980; **6**:14.

