



Hydrochlorothiazide-induced acute pulmonary edema

MANI S. KAVARU, MD; MUZAFFAR AHMAD, MD; K. N. AMIRTHALINGAM, MD

■ Hydrochlorothiazide-induced acute pulmonary edema has been reported rarely. Despite the frequency of hydrochlorothiazide use and the potential for this life-threatening side effect, it has received little organized attention in the literature. Treatment of the syndrome involves supportive therapy. The authors present a case report and review the 16 previously described cases.

□ INDEX TERMS: HYDROCHLOROTHIAZIDE; PULMONARY EDEMA □ CLEVE CLIN J MED 1990; 57:181-184

ACUTE noncardiogenic pulmonary edema associated with hydrochlorothiazide use is a severe, life-threatening clinical entity that has rarely been described. Since it was initially described by Steinberg in 1968,¹ a total of 16 cases have been reported.¹⁻¹⁵ Despite the widespread use of hydrochlorothiazide and the potential seriousness of this reaction, it has received remarkably little attention in the literature. We describe a case of hydrochlorothiazide-induced acute pulmonary edema and review the available experience. *Table 1* presents the clinical features of all 17 patients described to date. Acute noncardiogenic pulmonary edema should be considered in the differential diagnosis in patients with bilateral pulmonary infiltrates and exposure to hydrochlorothiazide.

CASE REPORT

A 57-year-old woman arrived at a community hospi-

tal emergency room on March 3, 1988 with acute onset of shortness of breath, chills, nausea, loose stools, dizziness, and weakness. She had an unremarkable medical history. She reported having taken a single 50-mg tablet of hydrochlorothiazide 1 to 2 hours prior to the onset of symptoms and arrival in the emergency room. She had taken hydrochlorothiazide a total of three to four times since December 1987, for symptomatic treatment of ankle edema. On one occasion, in February 1988, after having taken a single tablet of hydrochlorothiazide, she noted chills, dizziness, and abdominal cramps, all of which were self-limited and for which she did not seek medical attention.

The patient was cyanotic, in moderate respiratory distress, alert, and oriented. Blood pressure was 60/0 mmHg, pulse 100 beats per minute, temperature 101 °F (38.3 °C) rectally, and respiratory rate 20 breaths per minute. Neck veins were flat and cardiac examination revealed sinus tachycardia at a rate of 100 beats per minute, without murmurs or gallop. Lung examination revealed bibasilar rales. Extremities did not show clubbing or pedal edema.

A chest radiograph on admission (*Figure 1*) showed bilateral interstitial infiltrates without cardiomegaly. An ECG was normal. Initial arterial blood gases on 10 liters face mask showed a pH of 7.37, PO₂ 65 mmHg, PCO₂ 27

From the Department of Pulmonary Disease, The Cleveland Clinic Foundation (M.S.K., M.A.) and Trumbull Memorial Hospital, Warren, Ohio (K.N.A.).

Address reprint requests to Muzaffar Ahmad, M.D., Chairman, Department of Pulmonary Disease, The Cleveland Clinic Foundation, One Clinic Center, 9500 Euclid Avenue, Cleveland, Ohio 44195.

TABLE 1
CLINICAL FEATURES OF 17 PATIENTS WITH HYDROCHLOROTHIAZIDE-INDUCED ACUTE PULMONARY EDEMA

Case No.	Author	Year	Age/Sex	Ingestion to symptoms (min)	Prior hydrochlorothiazide exposure?	Duration of illness (days)	Mechanical ventilation	Pulmonary artery wedge pressure (mmHg)	Comments
1	Steinberg ¹	1968	44/F	45	N	2	N	N/A	
2	Steinberg ¹	1968	65/F	15	N	1	N	N/A	
3	Weddington et al ²	1973	39/F	30	Y	6	N	N/A	
4	Beaudry and Laplante ³	1973	32/M	60	Y	5	N	N/A	Rechallenged in hospital; recurrence of symptoms
5	Farrell and Schillaci ⁴	1976	42/F	45	Y	1	N	CVP-7	
6	Bell and Lippmann ⁵	1979	56/F	20	N	3	N	N/A	(See text)
7	Gould et al ⁶	1980	67/F	30	Y	1	Y	12	
8	Dorn and Walker ⁷	1981	66/F	60	N	4	Y	11	
9	Carlson et al ⁸	1981	44/F	30	Y	7	N	4	
10	Prupas and Brown ⁹	1983	50/F	150	Y	4	N	N/A	
11	Piper et al ¹⁰	1983	62/F	N/A	Y	N/A	Y	N/A	(See text)
12	Wagner ¹¹	1983	50/F	60	N	1	N	N/A	
13	Levay ¹²	1984	70/F	30	Y	2	N	9	
14	Kounis et al ¹³	1986	50/F	10	Y	3	N	N/A	Skin testing suggested immediate hypersensitivity
15	Altred et al ¹⁴	1987	55/F	60	N	4	Y	10	Rechallenge; required mechanical ventilation
16	Klein ¹⁵	1987	56/F	30	Y	8	Y	15	Rechallenge; required mechanical ventilation
17	Current case	1989	57/F	90	Y	4	N	N/A	

Y = yes; N = no; N/A = not available; CVP = central venous pressure

mmHg, and bicarbonate level of 16 mEq/L. Other laboratory values were as follows: hemoglobin, 14.7 g/100 mL; hematocrit, 44.7%; leukocyte count 4200/mm³ with 60% neutrophils, 5% band forms, 32% lymphocytes, and 3% monocytes. Serum chemistry values were normal.

A two-dimensional echocardiogram was normal, as were serial ECG and cardiac enzyme studies. Blood, sputum, and urine cultures were negative. All serologic studies were normal, including *Mycoplasma* and *Legionella* titers, fungal titers, and a hypersensitivity pneumonitis screening panel. Complement studies and collagen vascular studies were normal.

The patient was treated supportively with dopamine, dobutamine, and hydration. She responded rapidly; within 48 hours she was asymptomatic and a chest radiograph showed marked improvement. She did not require mechanical ventilation. She was discharged on March 9, 1988.

On a follow-up outpatient visit, the chest radiograph and pulmonary function survey were normal. Arterial blood gases on room air showed a PO₂ of 92 mmHg and

PCO₂ of 33 mmHg. A scratch test using a preparation of 50 mg hydrochlorothiazide and 10 mL normal saline did not reveal evidence of immediate hypersensitivity to the drug.

Cellular immunologic studies, using controls, were performed on the patient's blood mononuclear leukocytes (MNL) to determine if there was evidence of cell-mediated hypersensitivity to hydrochlorothiazide. The lymphocyte transformation test was performed as described previously.¹⁶ Briefly, 2.0 × 10⁵ MNL were cultured in each well of microtiter trays in 0.2 mL RPMI 1640 medium supplemented with 10% human AB serum, penicillin-streptomycin, and L-glutamine (GIBCO, Grand Island, NY). Each variable was tested in four replicate wells. The variables were MNL cultured in medium alone; in the presence of eight different concentrations of hydrochlorothiazide (10⁻¹ to 10⁻⁶ mg/mL); and in the presence of the T-lymphocyte mitogen, phytohemagglutinin (PHA) (250 µg/mL). Cells were cultured for 4 to 7 days with inclusion of 1 µCi (3.7 × 10⁴ Bq) tritiated thymidine (Amersham, U.K.) for the last 20 hours of culture. All cultures were harvested onto fil-

ter paper with an automated cell harvester. Radioactive contents of filter papers were determined by addition of scintillation fluid and quantitation in a liquid scintillation counter. Results were compatible with intact cell-mediated immunity (normal PHA) and absence of hypersensitivity to hydrochlorothiazide.

Supernatant fluids from the patient's leukocyte cultures were analyzed for content of soluble interleukin 2 receptor, a marker of T-lymphocyte activation.¹⁷ The assay used was a sandwich-type enzyme immunoassay that was carried out according to the manufacturer's instructions (T Cell Sciences, Cambridge, MA). The sensitivity of the assay is 50 units soluble interleukin 2 receptor/mL. The results confirm the lymphocyte transformation test results and are compatible with intact cell-mediated immunity (elevated response to PHA) and absence of response to hydrochlorothiazide.

DISCUSSION

Hydrochlorothiazide, a benzothiadiazide diuretic, is an agent widely used for the treatment of hypertension and congestive heart failure.¹⁸ A hydrochlorothiazide-containing preparation was the second most commonly dispensed drug for all new and refill prescriptions in 1987.¹⁹ In the same year, hydrochlorothiazide itself was the sixth most commonly dispensed generic drug.¹⁹

Hydrochlorothiazide-induced pulmonary edema, in its full-blown presentation, appears to have a very dramatic and acute onset, with an average interval of 50 minutes from drug ingestion to onset of symptoms. Dyspnea is a nearly universal symptom, having been present in 16 of 17 patients. However, the systemic nature of this reaction is evidenced by the fact that fever (present in 6 of 17 patients), chills, and gastrointestinal symptoms (8 of 17 patients) were often present. The mean age of the group is 54 years. The preponderance of women (16 of 17 patients) was impressive; this feature has not, to our knowledge, been pointed out in previous studies.

On presentation, patients have been acutely ill with hypotension and hypoxemia. No peripheral eosinophilia has been reported to date. Chest radiographic studies characteristically have shown bilateral diffuse pulmonary infiltrates, usually without cardiomegaly. In seven reported cases where hemodynamic parameters were available, findings supported a noncardiogenic etiology. Five of 17 patients required mechanical ventilation for a mean of only 2 days. Despite a typically serious condition on presentation, most patients recovered rapidly and chest radiographs and PO_2 values normalized in a

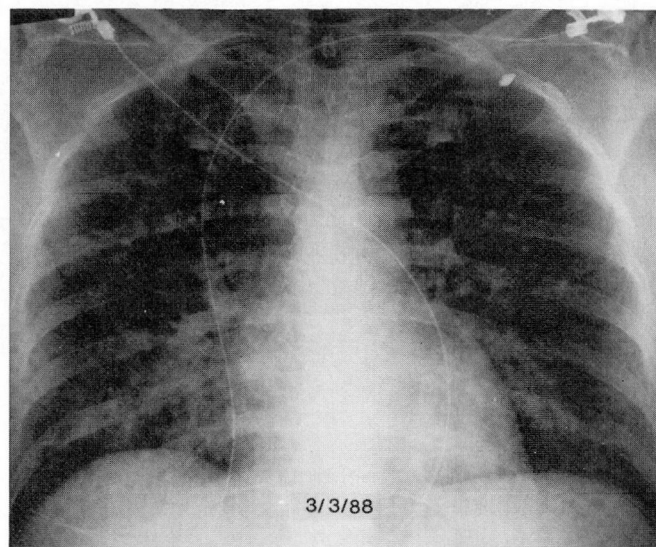


FIGURE 1. Chest radiograph at admission, demonstrating vascular congestion and bilateral perihilar infiltrates.

mean of 5 days. Therapy was usually supportive for the circulatory and ventilatory failure. However, in several instances, corticosteroids were used empirically as well.^{4,5,13} No fatalities were reported among the 17 cases.

Hydrochlorothiazide-induced acute pulmonary edema appears to be specific for hydrochlorothiazide alone, and has not been described with other thiazide preparations. This syndrome has occurred with or without prior exposure to the drug; in 6 of 17 patients, the syndrome occurred on first exposure to the drug, in 7 of 17, there was evidence of prior occasional use of hydrochlorothiazide associated with very mild symptoms, which were usually self-limited. This entity has not been seen in patients receiving chronic daily therapy with hydrochlorothiazide, but rather in patients receiving intermittent therapy.

The pathogenesis for hydrochlorothiazide-induced pulmonary edema has been the subject of speculation in the various case reports, without general agreement.²⁰ Farrell and Schillaci⁴ postulated an immune mechanism mediated by an antigen-antibody reaction causing endothelial damage. Bell and Lippmann,⁵ who described a patient with hydrochlorothiazide-induced pulmonary edema with no prior exposure to hydrochlorothiazide, performed in vitro lymphocyte transformation tests and postulated a nonimmune idiosyncratic mechanism. However, Piper et al¹⁰ described a patient in whom the lymphocyte transformation test was consistent with an immune basis. Our findings echo those of Bell and Lipp-

mann.⁵ In vitro lymphocyte transformation testing, along with soluble interleukin 2 receptor assay, both performed with control lymphocytes, did not suggest hypersensitivity to hydrochlorothiazide in our patient. The reason for the variability among these case reports is not clear. Potential explanations include variations in the diluents that are used to prepare the hydrochlorothiazide moiety itself. Variability in the reagents used to perform the lymphocyte transformation test could also confound the findings. Since this test was performed in only 3 of the 17 cases reported, it is difficult to make definite conclusions regarding a possible immune mechanism.

None of the patients had undergone bronchoalveolar lavage or lung biopsy, either transbronchial or open lung biopsy, during the acute episode. Such data might offer additional insight into the pathogenesis of this entity.

In summary, we have described a patient with hydrochlorothiazide-induced acute noncardiogenic pulmonary edema and reviewed 16 previously reported cases. Noncardiogenic pulmonary edema is a very uncommon side effect of hydrochlorothiazide use, but represents a potentially life-threatening problem. This entity needs to be considered in the differential diagnosis in patients with bilateral pulmonary infiltrates and exposure to hydrochlorothiazide. This may occur with or without prior hydrochlorothiazide exposure. The presentation is usually dramatic and life-threatening. Treatment involves supportive therapy and, most importantly, avoiding future therapy with hydrochlorothiazide. The pathogenesis of hydrochlorothiazide-induced acute pulmonary edema is not clear, but is likely idiosyncratic.

REFERENCES

1. Steinberg AD. Pulmonary edema following ingestion of hydrochlorothiazide. *JAMA* 1986; **204**:167-168.
2. Weddington WW, Mulroy MF, Sandri SR. Pneumonitis and hydrochlorothiazide. *Ann Intern Med* 1973; **79**:283.
3. Beaudry C, Laplante L. Severe allergic pneumonitis from hydrochlorothiazide. *Ann Intern Med* 1973; **78**:251-253.
4. Farrell TC, Schillaci RF. Hydrochlorothiazide-induced pulmonary edema mimicking metastatic carcinoma of the breast. *Cardiopulmonary Med* 1976; **15**:16-17.
5. Bell RN, Lippmann M. Hydrochlorothiazide-induced pulmonary edema. *Arch Intern Med* 1979; **139**: 817-819.
6. Gould L, Reddy CVR, Zen B, et al. Life-threatening reaction to thiazides. *NY State J Med* 1980; **80**:1975-1976.
7. Dorn MR, Walker MO. Noncardiogenic pulmonary edema associated with hydrochlorothiazide therapy. *Chest* 1981; **79**:482-483.
8. Carlson RW, Schaeffer RC, Puri VK, Brennan AP, Well MH. Hypovolemia and permeability pulmonary edema associated with anaphylaxis. *Critical Care Med* 1981; **9**:883-885.
9. Prupas HM, Brown D. Acute idiosyncratic reaction to hydrochlorothiazide ingestion. *West J Med* 1983; **138**:101-102.
10. Piper C, Wallern D, Wesche D, Brattig N, Diao GJ, Berg PA. Pulmonary edema after intake of hydrochlorothiazide. *Dtsch Med Wochenschr* 1983; **108**:1480-1483.
11. Wagner AC. Interstitial pulmonary edema due to hydrochlorothiazide; case report. *Virginia Medical* 1983; **110**:715-716.
12. Levay ID. Hydrochlorothiazide-induced pulmonary edema. *Drug Intell Clin Pharm* 1984; **18**:238-239.
13. Kounis NC, Nikolaou S, Zavnas G, Siablis D. Severe acute interstitial pulmonary edema from Moduretic (amiloride plus hydrochlorothiazide). *Ann Allergy* 1986; **57**:417-418.
14. Altred E, Navarro M, Cantalapiedra JA, Albarez JA, Blasco MA, Nunez A. Non-cardiogenic pulmonary edema after oral ingestion of hydrochlorothiazide. *Intensive Care Med* 1987; **13**:364-365.
15. Klein MO. Noncardiogenic pulmonary edema following hydrochlorothiazide ingestion. *Ann Emergency Medicine* 1987; **16**:901-902.
16. Maluish AE, Strong DM. Lymphocyte proliferation. [In] *Manual of Clinical Laboratory Immunology*. Washington, DC, American Society for Microbiology, 1986, pp 274-281.
17. Rubin LA, Kurman CC, Fritz ME, et al. Soluble interleukin-2 receptors are released from activated human lymphoid cells in vitro. *J Immunol* 1985; **135**:3172.
18. Mudge GH. Diuretics and other agents employed in the mobilization of edema fluid. [In] Goodman LS, Gillman A, eds. *The Pharmacological Basis of Therapeutics*. New York, MacMillan Publishing Co, 1980, pp 892-915.
19. Top 200 drugs of 1987. *Pharmacy Times* 1988; **54**:38-46.
20. Cooper JAD, White DA, Matthay RA. Drug-induced pulmonary disease. Part 2: Non-cytotoxic drugs. *Am Rev Respir Dis* 1986; **133**:488-505.