



# Distal hypospadias in the adult

DAVID P. WOOD, JR. MD AND ROBERT KAY, MD

■ The majority of patients with distal hypospadias undergo surgical reconstruction in childhood for social, emotional, and technical reasons. Rarely, patients with hypospadias do not receive repair during childhood and seek surgical treatment as adults. The authors recently performed reconstruction on two adult patients with primary distal hypospadias. One patient had voiding problems, necessitating sitting, and the other patient desired repair for cosmetic reasons. In performing the surgical repair, the authors observed that the amount, as well as the elasticity, of the redundant foreskin was less in adults than in children. Urologists with a full repertoire of surgical skills can expect excellent results in patients with primary distal hypospadias.

□ INDEX TERM: HYPOSPADIAS □ CLEVE CLIN J MED 1990; 57:82-85

**H**YPOSPADIAS is a congenital abnormality commonly encountered by pediatric urologists; it occurs at a rate of 8.2 per 1,000 live male births.<sup>1</sup> Surgical reconstruction is recommended at approximately one year of age for psychological, social, and technical reasons.<sup>2-5</sup> Most adult hypospadiacs seeking care are so called "hypospadiac cripples," having previously undergone unsuccessful reconstructive operations as children. In an unknown number of adults with primary hypospadias, repair of hypospadias either was not sought in childhood, or was declined on the basis of counsel that the complications associated with hypospadias repair outweighed the functional and cosmetic benefits, particularly in patients with distal hypospadias. The literature contains little about the special considerations pertaining to reconstructive surgery in the adult patient with primary hy-

pospadias. We have recently seen two adult patients with primary hypospadias who illustrate different reasons for repair as well as the technical problems unique to adults.

## CASE REPORTS

### Case 1

A 17-year-old white male complained of recurrent balanitis. Distal hypospadias with a hooded foreskin was noted on physical examination. During discussion of possible treatment options, the patient inquired as to the feasibility of repairing his hypospadias. Reconstruction had not been performed in childhood because the parents had been advised that the patient's hypospadias would not be functionally significant. The patient desired repair for cosmetic and psychological reasons. He successfully underwent a Mathieu hypospadias repair and postoperative result was excellent (*Figure 1*).

### Case 2

A 32-year-old white male had been unable to void while standing because his urinary stream deflected downward and sprayed on the floor. Consequently, he

From the Department of Urology, Section of Pediatric Urology, The Cleveland Clinic Foundation.

Address reprint requests to R.K., Section of Pediatric Urology, The Cleveland Clinic Foundation, One Clinic Center, 9500 Euclid Avenue, Cleveland, Ohio 44195.

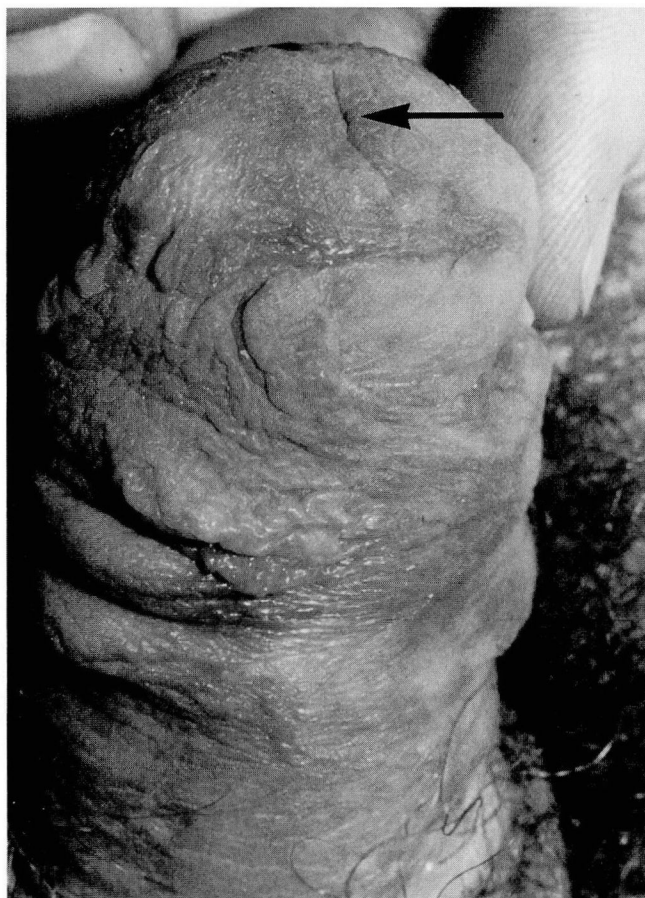

FIGURE 1. Case 1. Successful Mathieu hypospadias repair with meatus (arrow) at tip of glans penis.

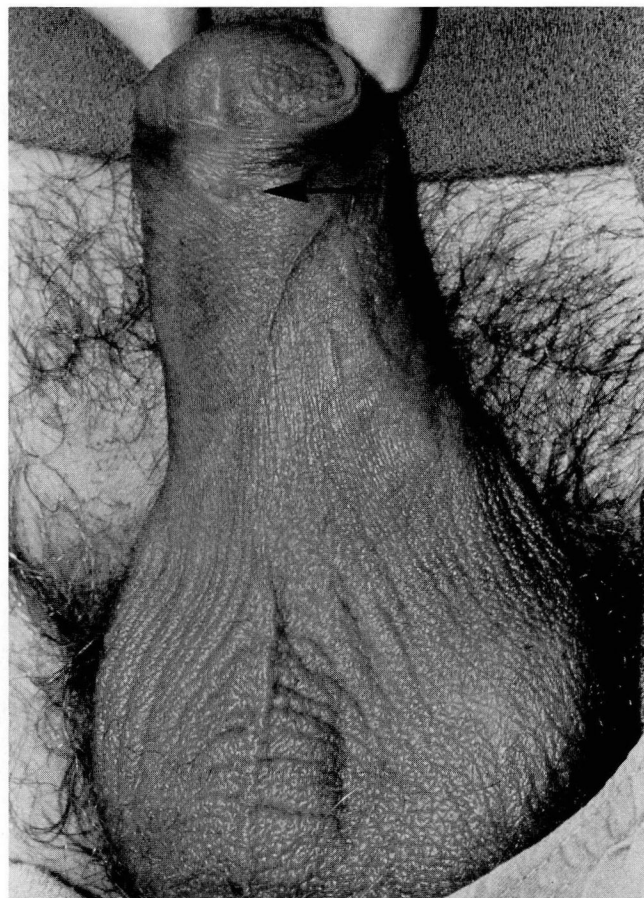


FIGURE 2. Case 2. Distal hypospadias—meatus at tip of arrow.

had needed to sit to urinate during his entire life. On physical examination, the patient had distal hypospadias (Figure 2). Hypospadias reconstruction had not been performed in childhood because of financial considerations. The patient had desired repair of his hypospadias since early childhood for functional as well as cosmetic reasons. He denied any difficulty with intercourse despite a mild chordee. He had three children. An artificial erection revealed a mild chordee, and he successfully underwent a Mathieu hypospadias repair with a scrotal rotational flap to cover the ventral skin defect (Figure 3). The postoperative result was excellent, and the patient was able to void well with a straight stream (Figure 4).

#### DISCUSSION

The goals of hypospadias repair are a normal voiding pattern, particularly the ability to void with a straight

stream while standing, normal sexual function and fertility, and a cosmetically normal-appearing penis. These goals of surgical repair are the same in adults as in children. One difference between children and adults is that adults seeking hypospadias repair are usually experiencing a practical problem, while children face potential difficulties that may or may not materialize in adulthood.

The two cases presented illustrate problems that distal hypospadias may present in adult life. In Case 1, the patient sought medical attention for recurrent balanitis. Upon further questioning, it was learned that he was quite bothered by the cosmetic appearance of his penis and desired repair of his hypospadias for both functional and cosmetic reasons. Case 2 illustrates that despite an apparent mild distal hypospadias, significant voiding problems may occur. Thus a spectrum of both functional and cosmetic problems may occur in adults with distal hypospadias.



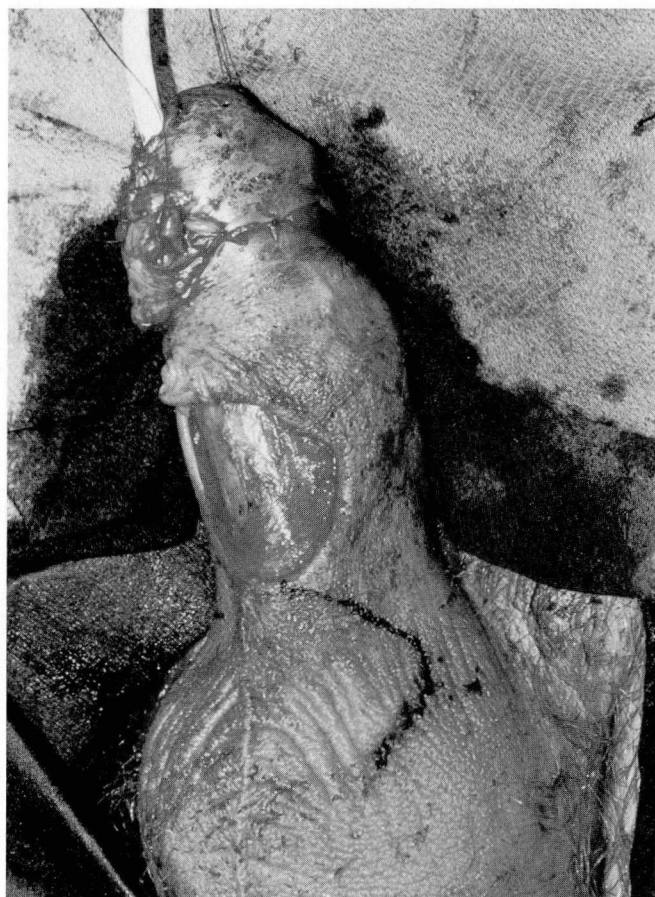

FIGURE 3. Case 2. Ventral skin defect after Mathieu repair.

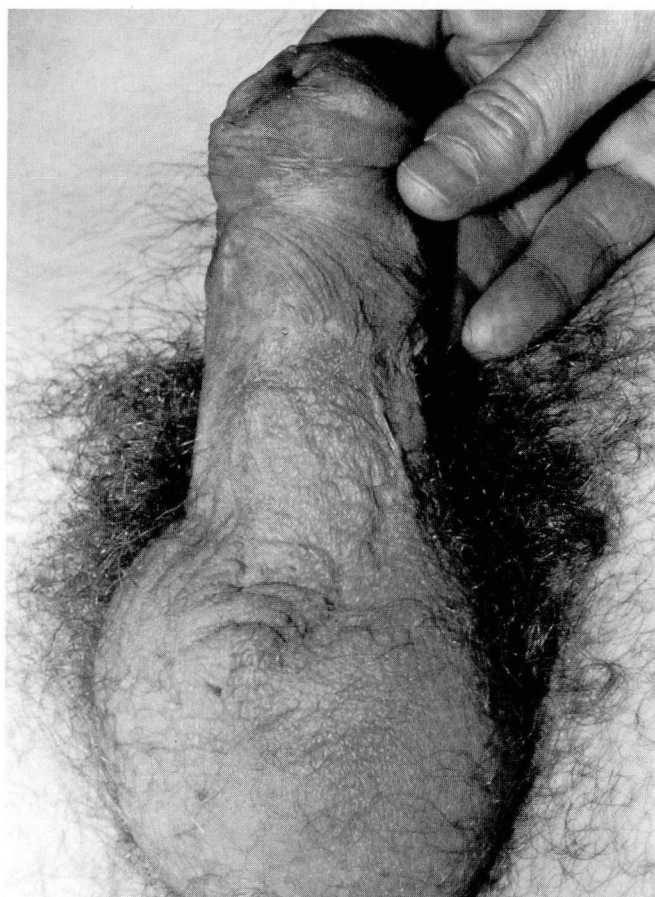

FIGURE 4. Case 2. Successful Mathieu hypospadias repair with excellent coverage of ventral penis.

Several technical problems in adult hypospadias reconstruction seem to be magnified when compared to the same anatomical abnormality in children. These problems include skin limitations and postoperative erections. We have observed that the amount of redundant foreskin available for repair compared to the size of the penis is less in adults than in children. Also adult skin is thicker and has stronger intracellular attachments and stiffer collagen bonds.<sup>6-8</sup> These factors, when combined, make coverage of skin defects more difficult in adults than in children, particularly if a chordee is present. To compensate for the potential skin defects, the use of scrotal and other skin flaps may be necessary to obtain adequate skin coverage after hypospadias repair, as seen in Case 2 (Figure 4).

Painful postoperative nocturnal erections may occur; in most cases, this is not a serious problem. However, in some patients, erections may cause severe pain and even suture disruption, particularly if the skin coverage is

tight. We have used amyl nitrate capsules intranasally (via nasal inhalation) for acute management of erections. Amyl nitrate may produce its effect by inducing vasodilatation and subsequent detumescence.<sup>9,10</sup> Amyl nitrate should be used cautiously in adults with atherosclerosis or aortic valve disease because of the marked hemodynamic changes that may occur.

#### SUMMARY

In summary, the optimal time for hypospadias repair appears to be in children approximately one year of age.<sup>4</sup> Some adults, however, have not undergone repair in childhood and present later in life requesting hypospadias repair. These adults should be offered surgical reconstruction, and excellent postoperative results can be expected. The surgeon should be aware of the unique qualities of the adult penile skin.

## REFERENCES

1. Belman AB. Urethra. [In] Kelalis PP, King LR, Belman AB, eds. *Clinical Pediatric Urology*. Vol. 2. Philadelphia, WB Saunders, 1985, pp 751-792.
2. Berg G, Berg R. Castration complex evidence from man operated for hypospadias. *Acta Psychiatr Scand* 1983; **68**:143-153.
3. Berg R, Berg G. Penile malformation, gender identity and sexual orientation. *Acta Psychiatr Scand* 1983; **68**:154-166.
4. Schultz JR, Klykylo WM, Wacksman J. Timing of elective hypospadias repair in children. *Pediatrics* 1983; **71**:342-351.
5. Manley CS, Epstein ES. Early hypospadias repair. *J Urol* 1981; **125**:698-700.
6. Grabb WC, Smith JW. Basic techniques of surgery. [In] Grabb WC, Smith JW, eds. *Plastic Surgery*. 2nd ed. Boston, Little, Brown and Co., 1973, p 23.
7. Hurwitz S. *Clinical Pediatric Dermatology, A Textbook of Skin Disorders of Children and Adolescence*. Philadelphia, WB Saunders, 1981, p 7.
8. Leider M. *Practical Pediatric Dermatology*. St. Louis, CV Mosby, 1956, p 20.
9. Rosoff MH, Cohen MV. Profound bradycardia after amyl nitrate in patients with a tendency to vasovagal episodes. *Br Heart J* 1986; **55**:97-100.
10. Bennett AH, Pilon RW. Nonincisional treatment for priapism. *J Urol* 1981; **125**:208-209.

