



The Lennox-Gastaut syndrome

J. ROGER, MD; C. DRAVET, MD; M. BUREAU, MD

THE Proposal for a Classification of Epilepsies and Epileptic Syndromes of the International League Against Epilepsy classifies the Lennox-Gastaut syndrome (LGS) into idiopathic and/or symptomatic epilepsies.¹ This proposal might be improved by reversing the terms and substituting cryptogenic for idiopathic; this group of epilepsies might thus be placed under the heading: symptomatic and/or cryptogenic. The differences between symptomatic generalized and idiopathic generalized epilepsies lie in the fact that, in the former, (1) evidence of a generally diffuse brain lesion is usually present, and (2) the electroclinical picture is completely different from that in the latter. The types of seizures (tonic, myoclonic-astonic, atypical absence seizures, infantile spasms, etc.) differ widely from those found in idiopathic generalized epilepsies; both interictal (hypsarrhythmia, diffuse slow spike waves [SWs]) and ictal electroencephalographic (EEG) changes (rapid rhythms during tonic seizures) also differ from those found in idiopathic epilepsies. Like other types of symptomatic generalized epilepsies, Lennox-Gastaut is age-dependent.

HISTORICAL PERSPECTIVES

Previous authors have already stressed the poor prognosis of certain clinical types of seizures (atypical absences, tonic and astatic seizures) occurring in the child. In 1938–1939, F. Gibbs, in collaboration with E. Gibbs and Lennox,² described a characteristic EEG pattern of slow SW discharges at 2 Hz (petit mal variant) as opposed to the 3 Hz SW characteristic of petit mal absence seizures. In 1945, Lennox³ and in 1950 Lennox and Davis⁴ established the clinical corre-

lates of this pattern and described in detail a clinical triad: diffuse slow SWs, mental retardation and occurrence of three types of seizures: myoclonic jerks, atypical absences and drops of the head on the chest or of the whole body on the ground, the latter described as akinetic or astatic seizures, or “drop attacks.”

Later works by Sorel in 1964,⁵ by Dooze in 1964⁶ and primarily by Gastaut et al in 1966⁷ helped in the electroclinical characterization of this syndrome, for which various patronyms were proposed, until the term “Lennox-Gastaut syndrome” was agreed upon in 1966. In the following years, numerous authors have shown an interest in the LGS, particularly Aicardi, 1973,⁸ Blume et al, 1973,⁹ Erba and Lombroso, 1973,¹⁰ Markand, 1977,¹¹ and Niedermeyer, 1969.¹² We will utilize principally the studies on the long-term evolution of a large number of cases: Gastaut, 1973,¹³ Loubier, 1974,¹⁴ Ohtahara, 1978,¹⁵ Beaumanoir, 1981,¹⁶ and Oller-Daurella, 1967.¹⁷

SYMPTOMATOLOGY OF SEIZURES

Seizures characteristic for this syndrome are tonic seizures, atypical absences, myoclonias, myoclonias associated with atonias, and atonic seizures, the different types often appearing in the same child, with one or another type predominating.

Tonic seizures are found in a large majority of patients, occurring during the day or during sleep. When they occur only during sleep, they may go unnoticed; therefore, their incidence has often been misjudged. Investigators who have used sleep EEG recordings report a prevalence of 74%,¹³ 87.5%,¹⁶ or 90%.¹⁴ Tonic seizures can be axial (flexor movement of the head and trunk), axial rhizomelic (elevation and abduction of proximal upper limbs) or global (leading to

From the Centre Saint-Paul, Marseille, France.

sudden falls). They can be asymmetrical or predominantly unilateral. When very brief, they can be limited to sursum vergens of the eyes with associated brief apnea, this picture often being found in sleep. When prolonged, they can end in a vibratory episode with very rapid and discrete clonias. After the tonic stage, some patients may show episodes of automatic behavior. These tonic-automatic seizures have been described by Oller-Daurella¹⁸ in 72% of late-onset cases; they were found in 16% of all cases by Loubier.¹⁴ Enuresis may occur, but there is no cyanosis, biting of the tongue or pronounced muscular relaxation with stertor, as in grand mal seizures. Loss of consciousness may not occur at the onset, and the return of a normal state of consciousness coincides with the end of the EEG discharge. In very young children, tonic seizures are often short, are sometimes followed by atonia, and occur frequently in clusters around waking time.

On the EEG, tonic seizures are characterized by either a flattening or a bilateral discharge of rapid rhythms generally predominant in anterior and vertex areas (Figure 1); sometimes these occur in succession.

This pattern may be preceded by a brief generalized discharge of slow SWs and followed by a burst of slow waves and generalized slow SWs of varying length, accompanied at times by confusion or automatic behavior. Unlike grand mal seizures, no postictal "electrical silence" is found. Polygraphic ictal recordings show apnea and tonic contraction of proximal muscles.

These seizures are facilitated by sleep, when they may lose some of their symptomatology and appear subclinical; they are revealed only by a polygraphic EEG recording. This ictal pattern during sleep has been inappropriately described by Gibbs and Gibbs¹⁹ as "grand mal pattern," but in our opinion it is both

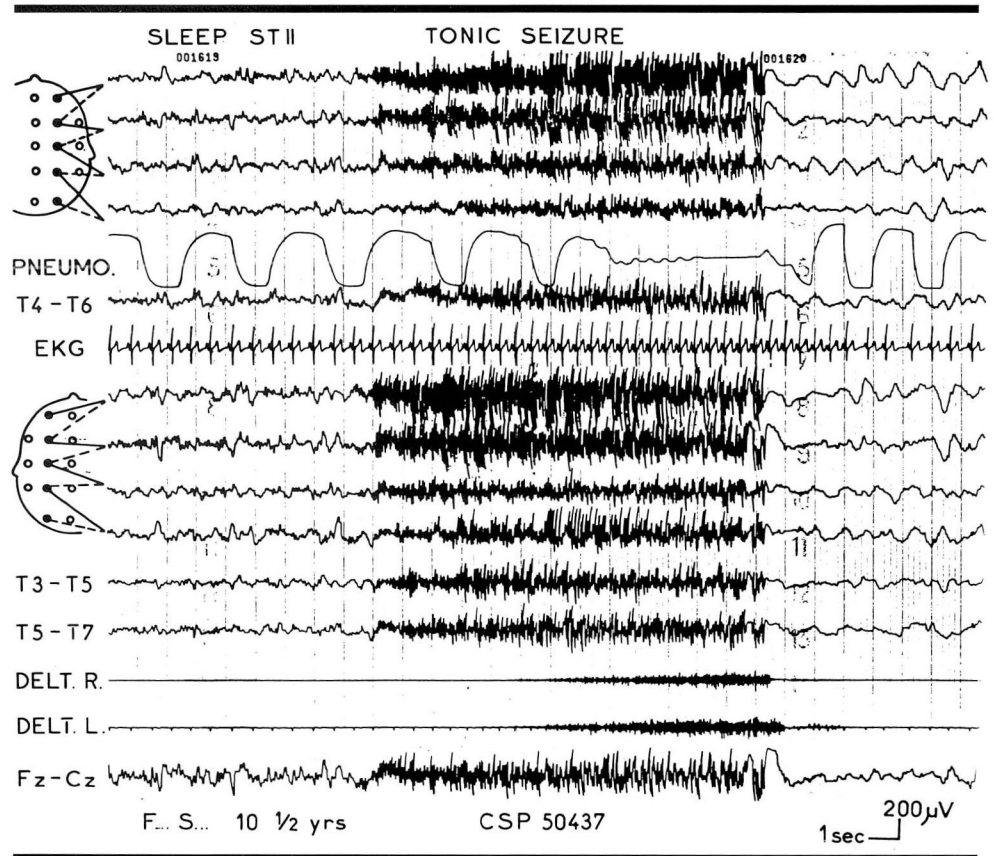


FIGURE 1. Tonic seizure during sleep stage II. EEG: fast rhythms of high voltage predominant in anterior and vertex areas. Polygraphy: tachycardia, apnea and hypertonia of both deltoids.

characteristic and necessary for the diagnosis of LGS. In some patients, these seizures may be precipitated by stimuli such as noise, contact or movement.

Atypical absence seizures are also found in a vast majority of cases. They may be difficult to see clinically, as both onset and ending are progressive; incomplete loss of consciousness may allow the patient to continue activities to some degree. They may be associated with eyelid myoclonias, less rhythmic than in typical absences, but they are more often associated with myoclonias around the mouth or progressive flexion due to a lowering of postural tonus, mostly of the head, with hypersalivation. The EEG shows irregular slow SW discharges around 2 to 2.5 Hz, diffuse and more or less symmetrical (Figure 2); sometimes discharges of rapid rhythms may also be seen.

Massive myoclonias, myoclonias-atonias and atonic seizures are very difficult to distinguish from one another through clinical observation alone. They always pro-

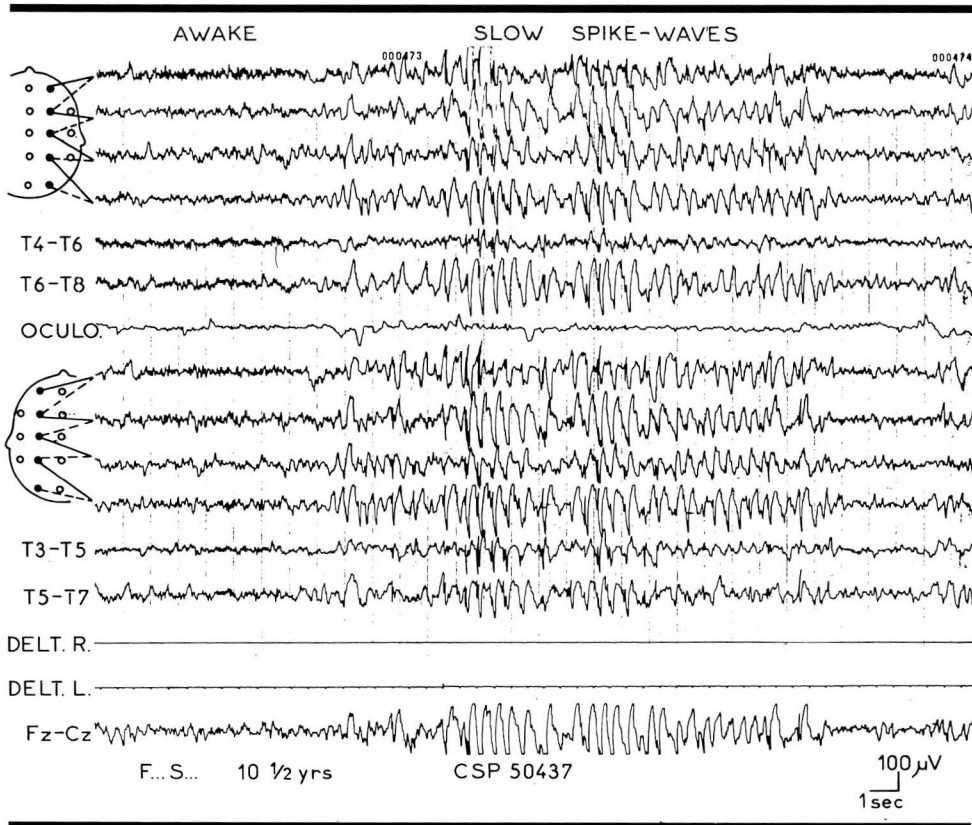


FIGURE 2. Atypical absence in the waking state. EEG: irregular slow SW discharges, more or less symmetrical, diffuse on both hemispheres.

duce sudden falls, sometimes limited to the head, sometimes involving the whole body and producing injuries; they are usually followed immediately by standing up. The EEG is polymorphous: most often it reveals slow polySWs, but there also may be SWs or diffuse rapid rhythms. Polygraphic recordings are necessary to differentiate between a massive jerk, a pure atonia or a jerk followed by atonia (Figure 3). In very young children, the picture may be that of a prolonged myoclonia or of a very short tonic seizure.

Most investigators include these seizures together with tonic seizures in a group labeled “akinetic” or “astatic” seizures, a description adopted by Gastaut.²⁰ They may also be called “drop attacks.”

In 95% of the cases, these three main types of seizures are associated in a single patient. Other non-specific types of seizures, such as tonic-clonic, clonic, or partial seizures, can also be found.

All types of seizures may present as episodes of status (54% to 75% of cases). There are three main types of

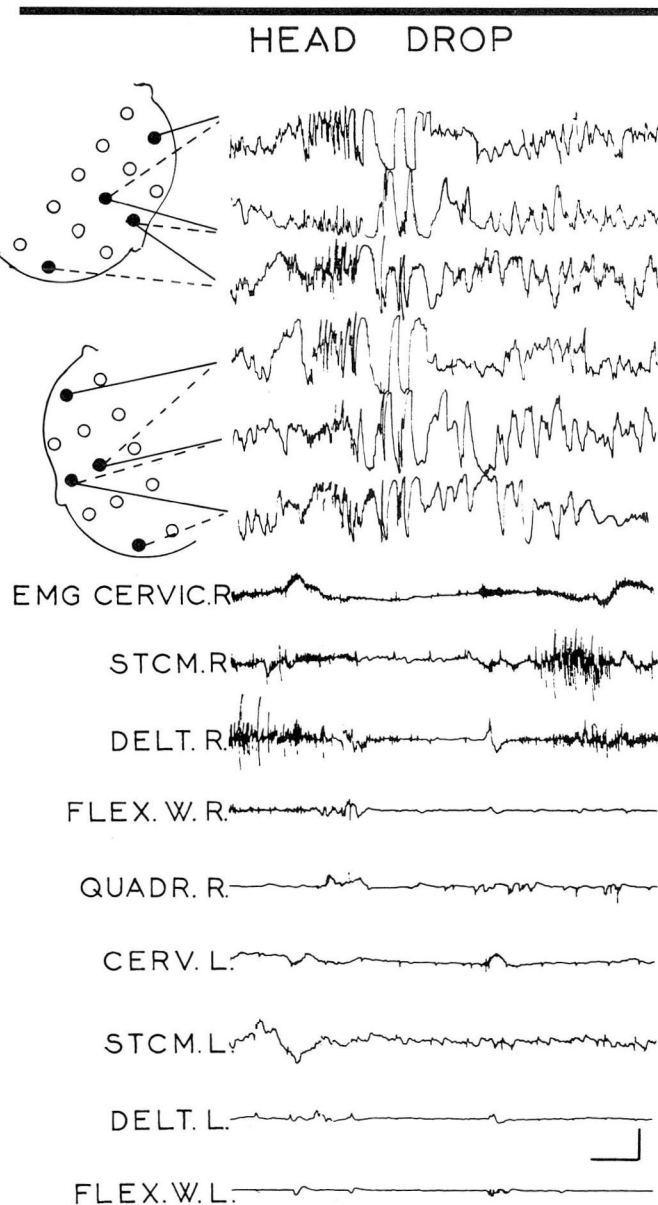
status: atypical absence status, associated with frequent myoclonias and myoclonias-atonias and rare tonic seizures; purely tonic status; and atypical absence status interrupted by series of tonic seizures and sometimes tonic-clonic seizures. The symptomatology of tonic seizures may then be considerably attenuated, these even appearing as partial seizures (Figure 4).

Episodes of status are characterized by long duration and resistance to drugs. In a study of 30 patients by Dravet et al,²¹ the duration of status was found to be longer than 1 week in 15 patients, the longest being up to 1 month. The longest episodes belong to the third type, with atypical absences interrupted by tonic seizures.

INTERICTAL SYMPTOMATOLOGY

Given the minority (20% to 30%) of subjects who are free from neurologic and neuropsychologic deficits prior to onset of LGS, the neuropsychologic symptomatology related to LGS is difficult to ascertain. Neuropsychologic and psychiatric symptoms are expressed differently according to age at onset of LGS. In young children, one sees slowing or arrest of psychomotor development or of educational progress, as well as instability, disturbance of character and personality disorders, often leading to psychosis. At onset, the psychologic evolution and occurrence of seizures seem to be closely related, but this relationship progressively fades and may result in a picture of pseudodeterioration. In older children and adolescents, an arrest of educational progress is also noted, but character problems are predominant. Acute psychotic episodes or a chronic form of psychosis, often atypical, may occur. The relationship with epilepsy or iatrogenic factors is difficult to analyze.

There are no neurologic symptoms specific for LGS.



HUGUEY... 4yrs (VI-65) CSP14006

FIGURE 3. Head drop in the waking state. EEG: Polyspikes, then diffuse slow SW discharge. Polygraphy: disappearance of the muscular activity on the neck muscles and the right deltoid.

In certain subjects, especially during episodes of aggravation, there may be cerebellar symptoms and, less often, pyramidal or extrapyramidal symptoms (i.e., abnormal movements, rigidity). Myoclonias are rare,

are usually transient and disappear as seizures are better controlled and EEG tracings improve. In some cases, however, episodes of aggravation are so long and occur so repeatedly that neurologic symptoms end by being permanent after more than 10 years of evolution of LGS. It is difficult to assess the part played by iatrogenic factors such as medication.

The EEG may show slowing and poor reactivity of background activity. The slowing may be constant (67% of cases) or only transient, and found most often in periods when seizures are frequent. Permanent slowing of background activity is a marker of bad prognosis, especially regarding mental development. Paroxysmal abnormalities such as diffuse slow SW and polySW discharges are constantly found in the waking state. In 75% of patients, focal or multifocal abnormalities are also found, particularly spikes and sharp waves in the temporal and frontal areas. During sleep, EEG abnormalities are markedly enhanced; their aspect is more bisynchronous, as very slow polySWs with prominent polyspikes, often appearing as subclinical ictal discharges (Figure 5).

Few investigators have studied sleep organization in this context. In our experience, it can be normal when clinical seizures are not too numerous. Degen and Degen²² recorded EEG in short sleep only. They recognized stages A, B and C in all their 30 patients. Baldy-Moulinier et al²³ studied sleep EEGs of 80 children with 200 all-night polygraphic recordings. They found abnormal nonREM sleep patterns in 77.8% and a decrease in total REM sleep duration in 50%. There was a marked relationship between these modifications and the severity of epilepsy and mental retardation.

NATURAL HISTORY

LGS can occur in widely differing circumstances. Boys are affected slightly more often (54% to 63% of patients) than girls.^{11,14,24} In a limited number of cases, about 30%,^{13,14,25} it appears in children without personal antecedents, without previous epilepsy, without clinical or neuroradiologic evidence of brain damage and with a previously normal psychomotor development. This may be called cryptogenic LGS.

The other cases reveal a history of pre-, peri-, or postnatal encephalopathy, mental retardation or prior epilepsy (West syndrome in one third of cases). These may be called symptomatic LGS. Data from computed tomography scans confirm the frequency of these symptomatic forms, since they are abnormal in 53%,²⁶

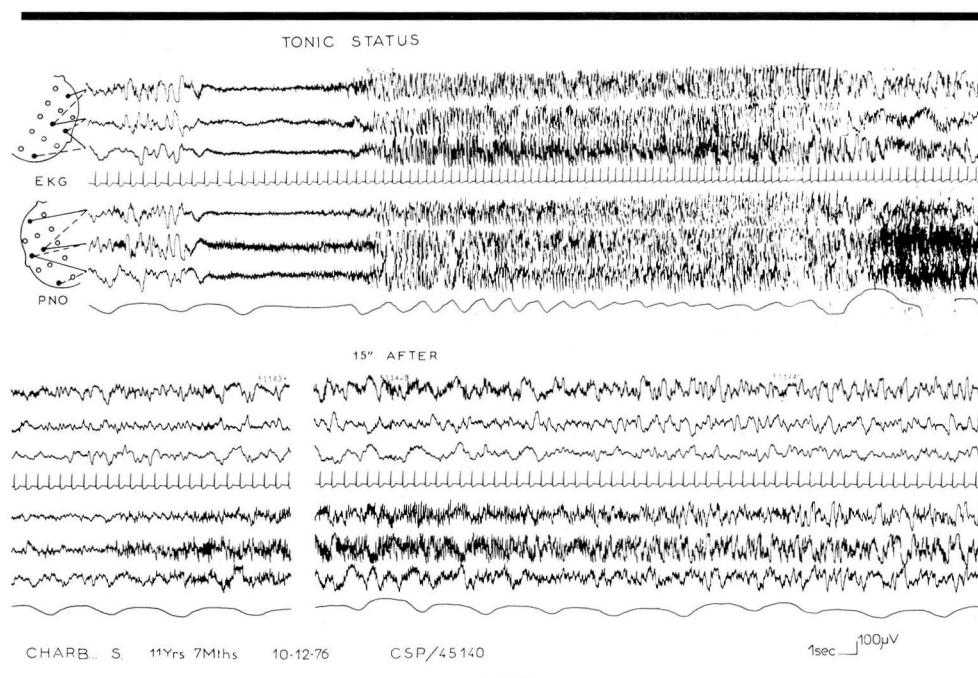


FIGURE 4. Tonic status in a girl aged 11 years 7 months. Top: a seizure consisting of diffuse, fast rhythms, followed by a burst of high voltage polyspikes intermixed with slow waves. Clinically: short apnea, then polypnea and tachycardia. At the end, intensive muscular activity on the left side. Bottom: a long seizure (55 sec) involving principally the left hemisphere with only anterior rapid rhythms and slow waves on the right. No clinical expression.

principally showing symmetrical and asymmetrical cerebral atrophy. In some cases (3%), cerebral tumors have been demonstrated.

Family history positive for epilepsy is present in a very wide range in different studies: 2.5%,²⁵ 4.2%,¹³ 28%,¹⁴ and 40%.²⁷ These differences can be explained by two facts: usually the researchers do not differentiate cryptogenic and symptomatic cases; and their inclusion criteria are not always the same. In our group of 23 cryptogenic LGS patients,²⁸ we found 47.8% with a family history of epilepsy and febrile convulsions.

Age at onset is between 3 and 5 years in the majority of patients: 69% between 2 and 7 years for Gastaut.¹³ An earlier onset is possible, particularly in symptomatic cases (20% between 0 and 2 years for Loubier¹⁴). In our group of purely cryptogenic cases,²⁸ the age at onset was between 8 months and 3 years in 11 out of 23 patients. Cases with a later onset, after 8 years, are rarer.

Mode of onset is not homogeneous. In symptomatic cases, LGS may follow a West syndrome, with or without a free interval, or follow seizures belonging to a partial epilepsy, or unilateral seizures, or generalized

convulsive seizures, often in clusters or episodes of status. Several studies have reported the possibility that LGS appears at puberty or in adulthood in patients presenting previously with idiopathic generalized epilepsies.

In cryptogenic cases, onset of seizures may be preceded by an infectious disease, vaccination or febrile episode, although the onset is usually unexpected. In very young children, head drops are the most frequent initial symptom, while drop attacks and behavioral disturbances are commonly found in school-age children. Sometimes neuropsychologic impairment and diffuse slow SWs on the EEG may precede the onset of seizures (16% of the cases of Gastaut¹³).

Evolution of this disorder is severe: seizures remain

frequent, periods of remission are short, episodes of status occur and intellectual and psychological impairment is progressive. The mortality rate has been evaluated by Gastaut¹³ at 3% (with a mean follow-up of 8 years and 7 months) and by Loubier¹⁴ at 7% (mean follow-up: 9 years and 9 months). Seizures persist in a majority of patients (from 60% to 80%). An intellectual deficiency is observed in almost all the patients, from 85% to 92% in various studies. It can be slight, but more often it is severe. Behavioral and personality disturbances are associated; the outcome is poorer in symptomatic cases. However, it is also bad in cryptogenic cases, as demonstrated by our study of 23 cases²⁸ with a mean follow-up of 6 years and 11 months: no patient is cured; four patients are seizure-free but only three show normal intelligence; 19 still have an active LGS.

Beaumanoir²⁹ and Oller-Daurella et al³⁰ have studied the long-term evolution of LGS. Beaumanoir evaluated 103 patients followed for 10 years or more (average follow-up, 19 years and 7 months): 62.1% of the cases ($n = 64$) had an unfavorable outcome, among whom

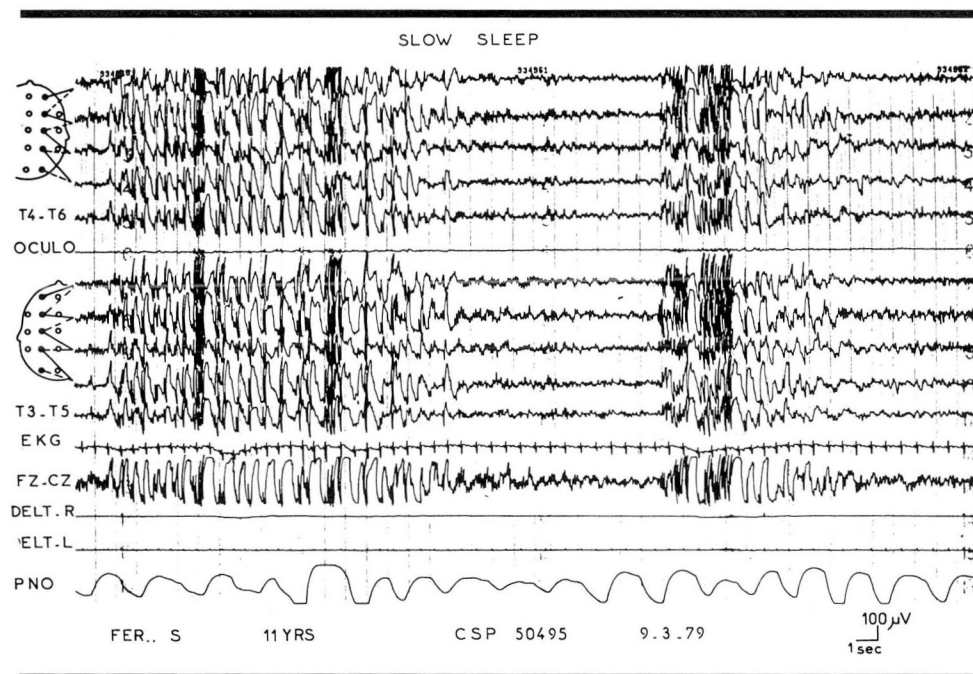


FIGURE 5. Typical aspect of slow sleep. Slow diffuse polyspikes and waves. Note the irregularity of respiration without close relationship with the discharges in this case.

75.0% ($n = 48$) kept in adulthood the characteristic symptomatic triad. Cases with poor outcome generally had an early onset (before age 4) with a complete clinical syndrome at the steady phase, associating the three typical seizure types (atypical absences, myoclonic-atic and tonic seizures). Cases with a better outcome (37.9%, $n = 39$) can be classified into two subgroups: those whose epilepsy has been cured, with minimal or absent intellectual sequelae (17.5%, $n = 18$) and those with persistent epilepsy, usually as infrequent partial seizures, and persistent severe neurologic or intellectual impairment (20.4%, $n = 21$). These two subgroups have a late onset (between ages 7 and 11), LGS is of short duration (2 to 4 years) and the electroclinical picture is usually incomplete. In the first subgroup, LGS may be preceded by an epilepsy resembling idiopathic generalized epilepsy with typical absences, or idiopathic partial epilepsy. This group may correspond, at least partially, to what has been described by Aicardi and Chevrie³¹ as "atypical benign epilepsy of childhood." The second subgroup includes patients with encephalopathy, in whom LGS may have represented an evolutive period of a partial, often multifocal, symptomatic epilepsy.

Oller-Daurella et al³⁰ evaluated 368 cases, of which

235 were followed longer than 5 years. Only 4% of the subjects have been considered to be cured (free of seizures and without mental impairment). The existence of mental retardation prior to the onset of LGS is a factor of bad prognosis.

In LGS, the evolution is thus somewhat individualized, as nearly one half the cases have a persistent and complete LGS through adulthood; in these cases, the syndrome can no longer be considered age-dependent.

CLINICAL VARIANTS OF LGS

Symptomatology

In the myoclonic variant of LGS, the predominant types of seizures are massive myoclonias and myoclonias-atonias (18% of the cases reported by Chevrie and Aicardi²⁵). Tonic seizures are rare and occur mainly during sleep; episodes of status are chiefly states of slightly impaired consciousness with myoclonias. The interictal waking EEG is not characteristic, but sleep recordings often fail to show tonic seizures. The myoclonic variant is often a cryptogenic form of LGS (64% of the cases), and the intellectual prognosis may be somewhat better than in typical forms of LGS.

Age at onset

Cryptogenic forms of LGS with onset before age 1 have a slightly different symptomatology and prognosis, but no investigator has individualized this particular group of patients. Oller-Daurella¹⁷ has stressed the poor prognosis of symptomatic forms appearing at this early age.

Do late forms of LGS, appearing after puberty, exist? A recent paper by Roger et al³² collected 44 cases of LGS with onset after the age of 13. This group is heterogeneous. In seven cases, LGS was cryptogenic and had its full symptomatology, while the EEG failed to show focal abnormalities. All these cases began between the ages of 13 and 15 and the outcome was

always poor, with LGS persisting through adulthood. In six cases with age at onset between 16 and 19, LGS was also apparently cryptogenic, and there were no focal EEG abnormalities, but the clinical picture was incomplete. Tonic seizures and rapid discharges during sleep EEGs were missing, and the inclusion of these cases in LGS is questionable.

A majority of cases (31 out of 44) showed the association of seizures and EEG changes typical for LGS with focal clinical and EEG abnormalities. The evolution of epilepsy and the intellectual prognosis were always poor. It seems that a distinction has to be made between (1) cases with true LGS appearing in a young adult with preexistent encephalopathy, and (2) more numerous cases where, in a patient with partial epilepsy, drop attacks and slow SW discharges appear at one point. The latter cases may be considered as focal or multifocal epilepsies with secondary bisynchrony. From the literature, it appears that favorable outcome of callosotomy was noted mainly in such cases, whereas successful operation in cases of true LGS is very uncommon.

PROGNOSIS

The main factors for a bad prognosis are as follows:

1. Symptomatic nature of LGS, particularly when West syndrome occurred prior to LGS. In the 42 cases of LGS following West syndrome reported by Ohtahara et al,²⁴ 40 remain mentally deficient and 80% still have seizures.
2. Early onset of LGS, before age 3, is often associated with a symptomatic form but is also associated with poor prognosis in cryptogenic cases of LGS.²⁵
3. High frequency of seizures, evolutive episodes of long duration, repeated episodes of status.³³
4. Constantly slow background activity on the EEG, without periods of improvement; association of focal changes with diffuse slow SWs.

TREATMENT

Treatment of LGS is difficult and disappointing. Classical antiepileptic drugs are not effective or are only transitorily effective. The drugs have to be chosen according to the type of seizures. Barbiturates are not very effective. Benzodiazepines, carbamazepine, corticosteroids, sometimes valproic acid, must be used preferentially. They will give results only if they are

prescribed at sufficiently high dosages to achieve therapeutic plasma levels. In our experience, hydrocortisone is better than ACTH because of its facility of oral administration and its lack of dangerous side effects if dosage is regulated. In fact, very high dosages are necessary (from 15 to 20 mg/kg/day) at the beginning; and treatment must be prolonged with decreasing dosages for several months. The results of prolonged corticotherapy can be excellent in cryptogenic cases if the drug is applied at the very onset. In other cases, it is necessary to repeat such a treatment two or three times. This can also be effective in epileptic status, or during periods of worsening in the course of evolution. Other types of treatment have been proposed: high doses of immunoglobulins and ketogenic or other diets. The results obtained by these methods are not really convincing. As has repeatedly been shown, it seems that no type of surgical treatment has given good results in patients with genuine LGS.

It is also important to look at the psychological problems in an effort to help the child overcome educational backwardness, and to offer psychological support to both child and family.

NOSOLOGY

The incidence of LGS has been diversely evaluated as 5% to 10% of all childhood epilepsies.^{13,16} The discrepancies may be caused by the more or less extensive frame covered by this syndrome according to individual researchers. The high number of symptomatic cases suggests that LGS is a nonspecific, age-related syndrome, a type of epileptic reaction to a probably diffuse encephalopathy. Some investigators have suggested an immune pathogenesis.

Roger and Gambarelli³⁴ have studied the results of neuropathologic examinations performed in 30 autopsy cases and of cortex biopsies in nine cases. In the autopsy material, dysplastic lesions were found in 16 cases, with major dysplastic lesions in nine cases and microdysgenesis in eight cases. In 23 cases (including nine cases with dysplastic lesions), selective neuronal necrosis was found. This was either diffuse (neocortex, hippocampus, thalamus, brain stem, cerebellum) or, in eight cases, localized and strictly limited to the cerebellum. In cortical biopsy cases, electron microscopic study showed vacuolization and distension of neuronal processes, particularly of postsynaptic bags. Quantitative morphologic analysis revealed regressive changes of cortical dendrites and reduction of synapses.

Positron emission tomography scan studies of 25 patients (15 cases reported by Chugani et al,³⁵ ten cases by Theodore et al³⁶) yield heterogeneous results. About half the patients show a diffuse reduction of cortical metabolic activity, while eight have apparently normal metabolism and five only focal metabolic abnormalities. Cryptogenic and symptomatic cases are not differentiated in these studies.

Diagnosis of LGS should not rely solely on the demonstration of diffuse slow SW discharges on the EEG. An important number of epileptic patients may, for a given time of their clinical course, present with diffuse slow SWs associated with atonic, myoclonic and/or atypical absence seizures; but tonic seizures are generally missing, as are discharges of rapid rhythms on the sleep EEG. These patients represent 39 of the 103 cases described by Beaumanoir. This symptomatology usually occurs later than typical LGS, between the ages of 9 and 13. The situation is usually transient, and can be found in three groups of patients: (1) those with a benign type of epilepsy, partial or generalized^{16,31} (an overload of drug medication may be responsible¹⁶); (2) subjects with a partial epilepsy related to structural lesions, usually frontal or mesial frontal. Similar situations have been described by Niedermeyer et al³⁷ in posttraumatic epilepsies. (3) Lastly, this situation may be found in children with previous signs of encephalopathy, with multifocal epilepsy associated with clinical and EEG signs of secondary generalization.

Apart from these cases where a picture of "pseudo-LGS" may be present, if the criteria developed by Beaumanoir³⁸ are strictly respected, the differential diagnosis is relatively easy.

Other types of symptomatic generalized epilepsies are completely different. Severe myoclonic epilepsy³⁹ is characterized by severe early clonic seizures, which can be febrile or nonfebrile, generalized or unilateral, later associated with myoclonic seizures and sometimes partial seizures, without tonic seizures. EEG tracings never show slow spikes and waves, and photosensitivity is frequent. Epilepsy with myoclonic status occurring in children with a nonprogressive encephalopathy⁴⁰ also

begins in the first year; nonmyoclonic seizures occur very rarely. EEG tracings show more or less regular, generalized SWs during status and continuous discharges during sleep, but never the typical burst of rapid rhythms as in LGS.

One problem is more arduous: the relationship between LGS and the syndrome described by Dooze et al²⁷ as "centrencephalic myoclonic-astatic petit mal." The latter disorder occurs between ages 2 and 5, is more frequent in boys, and differs from LGS in the following respects: it is always cryptogenic, a family history of epilepsy is frequent (37%), myoclonic-atonic and atypical absence seizures occur at onset without associated tonic seizures. The EEG shows 4 to 7 Hz theta activity and fast SWs. Nevertheless, a certain number of cases evolve into LGS, especially when generalized convulsive seizures are present early on. Actually, the cases described by Dooze seem heterogeneous; some patients beginning with generalized febrile seizures followed by myoclonic seizures and poor outcome may be classified as having severe myoclonic epilepsy.³⁹ Other patients have only one type of seizure (myoclonic jerks) with fast SWs and a good outcome, and are probably cases of benign myoclonic epilepsy.⁴¹ Others (but we have seen few of these) may constitute a further group. These are mentally deficient children, presenting with a single type of seizure (atonic drop attacks) that is highly resistant to medication. Finally, some of the cases may be myoclonic variants of LGS.

JOSEPH ROGER, MD
Centre Saint-Paul
300 Boulevard de Sainte-Marguerite
13009 Marseille, France

ACKNOWLEDGMENTS

We are very grateful to Dr. Pierre Genton for his help in translating this text, and to Mrs. Germaine Sisco for her excellent secretarial assistance.

REFERENCES

1. Commission on Classification and Terminology of the International League Against Epilepsy. Proposal for classification of epilepsies and epileptic syndromes. *Epilepsia* 1985; **26**:268-278.
2. Gibbs FA, Gibbs EL, Lennox WG. The influence of the blood sugar level on the wave and spike formation in petit mal epilepsy. *Arch Neurol Psychiatry* 1939; **41**:1111-1116.
3. Lennox WG. The petit mal epilepsies; their treatment with tri-dione. *JAMA* 1945; **129**:1069-1074.
4. Lennox WG, Davis JP. Clinical correlates of the fast and the slow spike-wave electroencephalogram. *Pediatrics* 1950; **54**:626-644.
5. Sorel L. L'épilepsie myokinétique grave de la première enfance avec pointe-onde lente et son traitement. *Rev Neurol* 1964; **110**:215-223.
6. Dooze H. Das Akinetische Petit Mal. *Arch Psychiatr Nervenkr* 1964; **205**:625-654.

7. Gastaut H, Roger J, Soulayrol R, et al. Childhood epileptic encephalopathy with diffuse slow spike waves (otherwise known as "petit mal variant") or Lennox syndrome. *Epilepsia* 1966; 7:139-179.
8. Aicardi J. The problem of the Lennox syndrome. *Dev Med Child Neurol* 1973; 15:77-80.
9. Blume WT, David RB, Gomez MR. Generalized sharp and slow wave complexes. Associated clinical features and long-term follow-up. *Brain* 1973; 96:289-306.
10. Erba G, Lombroso C. La sindrome di Lennox-Gastaut. *Prosp Pediatr* 1973; 10:145-165.
11. Markand O. Slow spike-wave activity in EEG and associated clinical features: often called "Lennox" or "Lennox-Gastaut" syndrome. *Neurology* 1977; 27:746-757.
12. Niedermeyer E. The Lennox-Gastaut syndrome, a severe type of childhood epilepsy. *Electroencephalogr Clin Neurophysiol* 1969; 24:283.
13. Gastaut H. Evolution clinique et pronostic du syndrome de Lennox-Gastaut. [In] Lugaresi E, Pazzaglia P, Tassarini CA, eds. *Evolution and Prognosis of Epilepsies*. Bologna, Aulo Gaggi, 1973, pp 133-154.
14. Loubier D. Le Syndrome de Lennox-Gastaut. Modalités évolutives. Marseille, Thesis, 1974.
15. Ohtahara S. Clinico-electrical delineation of epileptic encephalopathies in childhood. *Asian Med J* 1978; 21:7-17.
16. Beaumanoir A. Les limites nosologiques du syndrome de Lennox-Gastaut. *Rev EEG Neurophysiol* 1981; 11:468-473.
17. Oller-Daurella L. El Síndrome de Lennox. Barcelona, Espaxs, 1967.
18. Oller-Daurella L. Un type spécial de crises observées dans le syndrome de Lennox-Gastaut d'apparition tardive. *Rev Neurol* 1970; 122:459-462.
19. Gibbs FA, Gibbs EL. *Atlas of Electroencephalography*, ed 2. Reading, England, Addison-Wesley, 1952.
20. Gastaut H. The Lennox-Gastaut syndrome: comments of the syndrome's terminology and nosological position amongst the secondary generalized epilepsies of childhood. [In] Broughton RJ, ed. *Electroencephalogr Clin Neurophysiol* 1982; 35(suppl):71-84.
21. Dravet C, Natale O, Magaouda A, et al. Les états de mal dans le syndrome de Lennox-Gastaut. *Rev EEG Neurophysiol Clin* 1985; 15:361-368.
22. Degen R, Degen HE. Das Schlaf EEG bei Patienten mit myoklonisch-astatischen Anfällen (Lennox-Gastaut Syndrome). *Z EEG-EMG* 1983; 14:106-112.
23. Baldy-Moulinier M, Touchon J, Billiard M, Carriere A, Besset A. Nocturnal sleep studies in patients with Lennox-Gastaut syndrome. [In] Neidermeyer E, Degen R, eds. *The Lennox-Gastaut Syndrome, Neurology and Neurobiology*. New York, Allen Liss, 1988, vol 45, pp 243-260.
24. Ohtahara S, Yamatogi Y, Ohtsuka Y. Prognosis of the Lennox Syndrome. Long-term clinical and electroencephalographic follow-up study, especially with special reference to relationship with the West syndrome. *Folia Psychiatr Jpn* 1976; 30:275-287.
25. Chevrie JJ, Aicardi J. Childhood epileptic encephalopathy with slow spike-wave. A statistical study of 80 cases. *Epilepsia* 1972; 13:259-271.
26. Gastaut H, Gastaut JL, Regis H, Michel B. L'apport de la tomographie assistée par ordinateur au diagnostic étiologique des épilepsies. *Rev EEG Neurophysiol* 1977; 7:423-442.
27. Doose H, Gerken H, Leonhardt R, Völzke E, Völz C. Centrencephalic myoclonic-astatic Petit Mal. *Neuropädiatrie* 1970; 2:59-78.
28. Boniver C, Dravet C, Bureau M, Roger J. Idiopathic Lennox-Gastaut syndrome. [In] Wolf P, Dam M, Janz D, Dreifuss FE, eds. *Advances in Epileptology*. New York, Raven Press, 1987, vol 16, pp 195-200.
29. Beaumanoir A. The Lennox-Gastaut syndrome. A personal study. [In] Broughton RJ, ed. *Electroencephalogr Clin Neurophysiol* 1982; 35(suppl):85-99.
30. Oller-Daurella L, Oller-Ferrer-Vidal L, Sanchez ME. Evolucion del síndrome de Lennox-Gastaut. *Rev Neurol (Barcelona)* 1985; XIII, 63:169-184.
31. Aicardi J, Chevrie JJ. Atypical benign partial epilepsy of childhood. *Dev Med Child Neurol* 1982; 24:281-292.
32. Roger J, Remy C, Bureau M, Oller-Daurella L, Beaumanoir A, Favel P, Dravet C. Le syndrome de Lennox-Gastaut chez l'adulte. *Rev Neurol* 1987; 143:401-405.
33. Doose H, Völzke E. Petit mal status in early childhood and dementia. *Neuropädiatrie* 1979; 10:10-14.
34. Roger J, Gambarelli-Dubois D. Neuropathological studies of the Lennox-Gastaut syndrome [In] Neidermeyer E, Degen R, eds. *The Lennox-Gastaut Syndrome, Neurology and Neurobiology*. New York, Allen Liss, 1988, vol 45, pp 73-93.
35. Chugani HT, Mazziotta JC, Engel J Jr, Phelps ME. The Lennox-Gastaut syndrome—Metabolic subtypes determined by 2 Deoxy 2 (18F) fluoro-D-glucose positron emission tomography. *Ann Neurol* 1987; 21:4-13.
36. Theodore WH, Rose D, Patronas N, et al. Cerebral glucose metabolism in the Lennox-Gastaut syndrome. *Ann Neurol* 1987; 21:14-21.
37. Niedermeyer F, Walker AE, Burton C. The slow spike-wave complex as a correlate of frontal and fronto-temporal post-traumatic epilepsy. *Eur Neurol* 1970; 3:330-346.
38. Beaumanoir A. The Lennox-Gastaut syndrome. [In] Roger J, Dravet C, Bureau M, Dreifuss FE, Wolf P, eds. *Epileptic Syndromes in Infancy, Childhood and Adolescence*. London, John Libbey Eurotext, 1985, pp 89-99.
39. Dravet C, Bureau M, Roger J. Severe myoclonic epilepsy in infants. [In] Roger J, Dravet C, Bureau M, Dreifuss FE, Wolf P, eds. *Epileptic Syndromes in Infancy, Childhood and Adolescence*. London, John Libbey Eurotext, 1985, pp 58-67.
40. Dalla Bernardina B, Trevisan E, Colamaria V, Magaouda A. Myoclonic epilepsy ("myoclonic status") in nonprogressive encephalopathies. [In] Roger J, Dravet C, Bureau M, Dreifuss FE, Wolf P, eds. *Epileptic Syndromes in Infancy, Childhood and Adolescence*. London, John Libbey Eurotext, 1985, pp 68-72.
41. Dravet C, Bureau M, Roger J. Benign myoclonic epilepsy in infants. [In] Roger J, Dravet C, Bureau M, Dreifuss FE, Wolf P, eds. *Epileptic Syndromes in Infancy, Childhood and Adolescence*. London, John Libbey Eurotext, 1985, pp 51-57.