

Methotrexate for corticosteroid-resistant polymyalgia rheumatica and giant cell arteritis

PATRICIA L. KRALL, PA-C; DANIEL J. MAZANEC, MD; WILLIAM S. WILKE, MD

■ Three patients (one with polymyalgia rheumatica with jaw claudication and two with biopsy-proven giant cell arteritis) were initially treated using prednisone (40–60 mg daily). The response was good in all three, but each experienced exacerbation of symptoms and elevation of Westergren sedimentation rates (WSR) with dose reduction. The addition of methotrexate (7.5–12.5 mg/wk) resulted in diminished symptoms and lower WSR and proved to be steroid-sparing.

□ INDEX TERMS: METHOTREXATE; POLYMYALGIA RHEUMATICA; TEMPORAL ARTERITIS □ CLEVE CLIN J MED 1989; 56:253–257

POLYMYALGIA RHEUMATICA and giant cell arteritis are inflammatory conditions of unknown cause that affect the over-55 age group.¹ Corticosteroids, initially given in moderate to high doses (prednisone, 15–60 mg daily) then tapered to a lower maintenance dose (5–7.5 mg), are considered the treatment of choice and usually result in immediate and total remission of symptoms.² Because the course of treatment may last for many years,^{3,4} a major concern is the risk of corticosteroid side effects. This concern is heightened for patients whose symptoms are not controlled by a low maintenance dose of prednisone.

We report three patients, two with biopsy-proven giant cell arteritis and one with polymyalgia rheumatica and probably giant cell arteritis, who experienced recurrent active disease when prednisone was tapered to a safer maintenance level. As an alternative steroid-sparing agent, we chose low-dose oral methotrexate given

once weekly in combination with daily low-dose prednisone. Our objective was to simultaneously maintain disease remission and decrease the risk of steroid-related toxicity.

CASE 1

A 65-year-old white woman experienced sudden onset of left-sided dull headache, jaw pain, sore throat, and visual symptoms (“blurred” and “floaters”) in August 1984. The Westergren sedimentation rate (WSR) was 35 mm/h. Results of a left temporal artery biopsy showed changes in the internal elastic lamina and an infiltrate of mononuclear cells with very focal giant cells consistent with a diagnosis of giant cell arteritis. Prednisone was given at 60 mg daily and continued for six weeks. The dose was gradually tapered and eventually stopped five months later. Unfortunately, within seven to 10 days after discontinuing prednisone, she again experienced headaches. Prednisone was restarted at 60 mg daily, and she was referred to the Cleveland Clinic.

At the time of initial evaluation at the Cleveland Clinic, February 18, 1985, she had been taking 60 mg of prednisone daily for approximately 30 days. Headaches

From the Department of Rheumatic and Immunologic Disease, The Cleveland Clinic Foundation. Submitted Jan 1988; accepted Aug 1988.

Address reprint requests to W.S.W., Department of Rheumatic and Immunologic Disease, The Cleveland Clinic Foundation, One Clinic Center, 9500 Euclid Avenue, Cleveland, Ohio 44195.

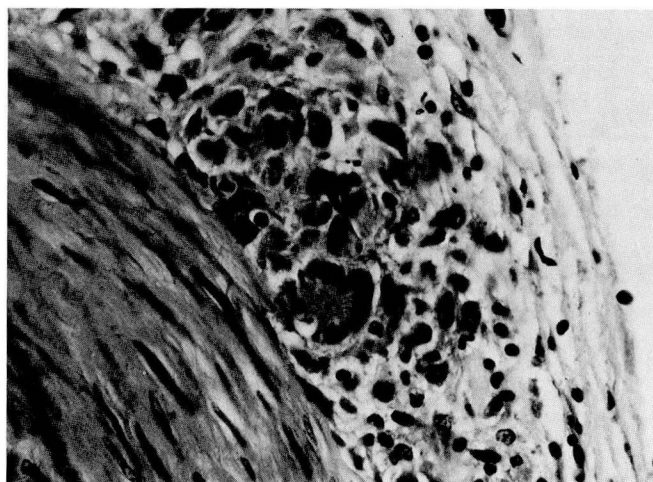
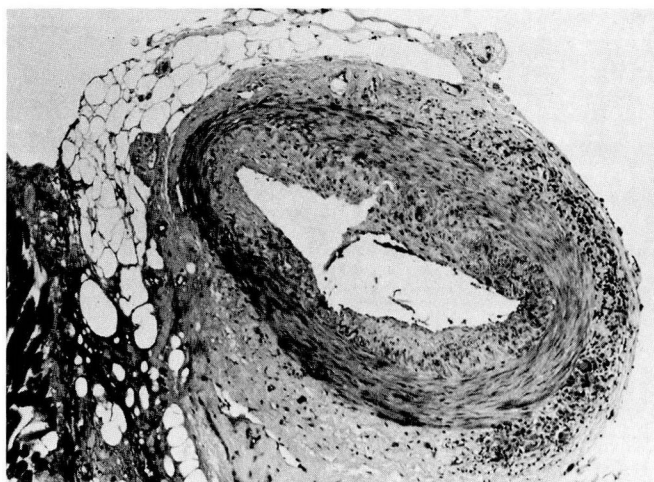
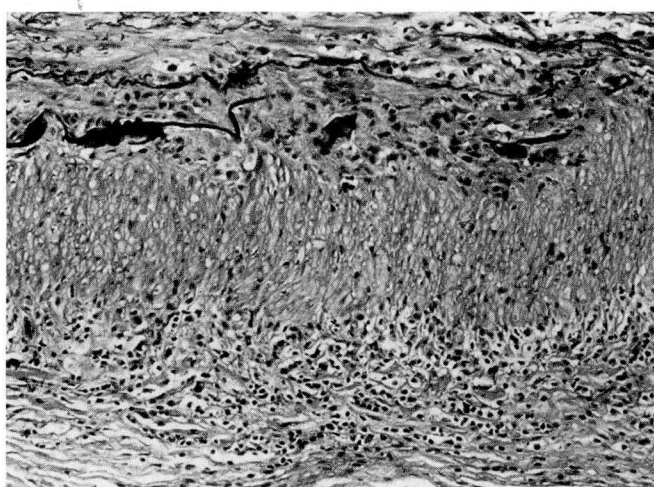
A, B
C

FIGURE 1A. A cross-section of the temporal artery, which shows granulomatous inflammation in the adventitia. FIGURE 1B. A higher-power view of the adventitia, which shows the mononuclear cell infiltrate and a typical giant cell. FIGURE 1C. A low-power cross-section, which shows fragmentation of the internal elastic lamina and absence of the external elastic lamina.

rheumatica. The WSR has remained below 30 mm/h during follow-up, and at the August visit was 13 mm/h.

Comments

It is unclear whether her headaches, experienced while taking 60 mg of prednisone, were related to her giant cell arteritis since her WSR was normal at that time. She continued to have intermittent occipital-frontal headaches throughout the course of her disease. Although initially she did not have polymyalgia rheumatica symptoms, after reduction of the prednisone dose, she complained of generalized myalgias and had an elevated WSR. A first occurrence of polymyalgia rheumatica symptoms in patients with giant cell arteritis after decreasing intake of prednisone has been reported by Fernandez-Herlihy.³

CASE 2

A 76-year-old white woman was well until mid-June 1983 when she experienced sudden onset of a constant "excruciating" bitemporal headache, "shooting" pains in the neck with movement, jaw claudication, and morning stiffness in the upper extremities lasting 30 minutes. She denied scalp tenderness, visual symptoms, fever, weight loss, depression, or proximal muscle pain with movement. The initial WSR was elevated to 43 mm/h. Other testing showed a positive antinuclear factor to a

continued. An examination did not reveal tenderness over the right temporal artery, the left temporal artery biopsy site, or the scalp. The joints appeared to be normal. The WSR was 12 mm/h. Based on history and laboratory testing, the diagnosis of giant cell arteritis with polymyalgia rheumatica was confirmed. The prednisone dose was rapidly tapered to 20 mg daily by February 28. Unfortunately, she again experienced generalized myalgias. The WSR was elevated to 38 mm/h. Methotrexate (12.5 mg each Monday) was started at this time.

Over the following 18 months, the prednisone dose was gradually tapered to 7.5 mg daily. As of her last follow-up visit on August 19, 1987, she continued to take prednisone (7.5 mg/d) and methotrexate (12.5 mg each Monday). She has experienced intermittent occipital frontal headaches and fatigue since her initial presentation at the Cleveland Clinic but has shown no clear signs of active giant cell arteritis or polymyalgia

dilution of 1:40, giving a speckled pattern and a positive latex fixation test for rheumatoid arthritis. Prednisone (40 mg daily) was initiated and provided immediate relief from symptoms. However, when the dose was rapidly tapered and discontinued twice during a six-week period, all symptoms returned. She was then referred to the Cleveland Clinic.

At the time of evaluation at the Cleveland Clinic, August 4, 1983, six weeks after her initial symptoms, she was taking 10 mg of prednisone daily. The temporal arteries were pulsatile and not tender. She complained of pain with passive and active movement of the shoulders and tenderness of the upper trapezii. She also complained of swelling and pain at the metacarpophalangeal joints of the index and middle fingers of both hands.

Laboratory tests showed the WSR elevated to 84 mm/h, rheumatoid factor positive at 38 RLS (equivalent to a latex fixation test at a titer of 1:320), and an antinuclear factor test positive at a dilution of 1:80. Results of a left temporal artery biopsy are shown (Figure 1). Granulomatous inflammation with giant cells primarily involved the adventitia. The internal elastic lamina was fragmented, and the external elastic lamina was absent. A diagnosis of giant cell arteritis and overlapping connective tissue disease was made. The prednisone dose was increased from 10 to 15 mg daily, which resulted in remission of all symptoms.

On September 20, 1983, she experienced transient decreased vision in the right eye. An ophthalmologic examination was normal. However, due to the possibility of giant cell arteritis affecting the ophthalmic artery, the prednisone dose was increased to 60 mg daily.

During the next three months, the dose was gradually decreased to 12.5 mg daily. On November 1, 1983, she reported new symptoms, including Raynaud's phenomenon and painful nodules on the fingertips. Erythematous nodules were noted at most fingertips, as well as small 1–2-mm ulcerations at the tips of the left fifth, right index, and right fourth finger. The WSR was elevated to 104 mm/h. Methotrexate was initiated (12.5 mg each Monday), and the prednisone dose was continued at 12.5 mg daily. Six weeks later, she was asymptomatic, the fingertip changes had resolved, and the WSR was 35 mm/h. Slow tapering of the prednisone dose was begun. In August 1984, nine months after she began taking methotrexate, the prednisone dose was reduced to 7.5 mg/d and the methotrexate dose was decreased to 7.5 mg each Monday. The patient was asymptomatic, and the WSR was normal at 11 mm/h.

Other than Raynaud's phenomenon, the patient was generally asymptomatic during the following two years.

The prednisone dose was adjusted to 2.5 and 5 mg on alternate days. The methotrexate dose continues at 7.5 mg per week.

Comments

This patient is particularly interesting because symptoms of giant cell arteritis complicated an overlapping connective tissue disease consisting of Raynaud's phenomenon, positive rheumatoid factor, low titer antinuclear antibodies, and rheumatoid arthritis symptoms. The laboratory and clinical findings have been described in patients with giant cell arteritis and polymyalgia rheumatica.^{1,4} Perez-Jimenez et al⁵ reported a case of biopsy-proven giant cell arteritis in a patient with progressive systemic sclerosis. Fauchald et al⁶ described three patients with biopsy-proven giant cell arteritis; rheumatoid arthritis developed later in two and systemic lupus erythematosus developed in the other. Hall et al⁷ reported three patients with coexistent seropositive rheumatoid arthritis and biopsy-proven giant cell arteritis.

We believe our patient's biopsy findings were consistent with a diagnosis of giant cell arteritis, based on the experience of Calamia and Hunder,¹ who documented the same adventitial histological changes in a patient with classic giant cell arteritis. Not only did methotrexate control her arteritic symptoms, it also diminished her arthritis symptoms.

CASE 3

A 53-year-old white man was well until May 1986, when he reported the onset of upper extremity pain, morning stiffness lasting one and a half hours, fevers, chills, night sweats, and a 25-pound weight loss over a two- to three-month period. He denied visual symptoms but did note discomfort suggestive of jaw claudication. He denied headache and scalp tenderness. The WSR was 125 mm/h. A clinical diagnosis of polymyalgia rheumatica and giant cell arteritis was made. No temporal artery biopsy was performed. He began taking prednisone (40 mg daily), and within 48 hours, all symptoms resolved.

The prednisone dose was gradually tapered over the ensuing four months to 10 mg daily, at which point his earlier symptoms recurred. Indomethacin (50 mg twice daily) was added, with no improvement. He was referred to the Cleveland Clinic in February 1987.

The medical history was significant because he had undergone a right corneal transplant in 1965, resulting in significant loss of vision in the right eye. More recently, he had had two episodes of iritis in the left eye

TABLE 1
CLINICAL COURSE OF PATIENTS WITH POLYMYALGIA RHEUMATICA/GIANT-CELL ARTERITIS
FOLLOWED FOR UP TO SIX MONTHS AFTER THE ADDITION OF METHOTREXATE

Duration	Case 1	Case 2	Case 3
Prior to methotrexate			
Symptoms			
Headache	—	+	—
Myalgia	+	—	+
Malaise	—	—	—
Westergren sedimentation rate	38 mm/h	104 mm/h	97 mm/h
Daily prednisone dose	20 mg daily	12.5 mg daily	20 mg
Six weeks of methotrexate			
Symptoms			
Headache	+	—	—
Myalgia	+	—	—
Malaise	—	—	—
Westergren sedimentation rate	27 mm/h	35 mm/h	45 mm/h
Daily prednisone dose	17.5 mg	12.5 mg	17.5 mg
Six months of methotrexate			
Symptoms			
Headache	+	—	—
Myalgia	+	—	—
Malaise	—	—	—
Westergren sedimentation rate	3 mm/h	11 mm/h	45 mm/h
Daily prednisone dose	15 mg	10 mg	10 mg

+ indicates presence of symptom; — indicates absence of symptom

and a central serous choroidopathy developed in the left eye as well.

Physical examination at the time of initial evaluation at the Cleveland Clinic revealed no other remarkable findings, with the exception of a mild loss of neck motion. The prednisone dose was increased to 20 mg daily and his symptoms diminished. However, on May 14, 1987, with tapering of the prednisone dose to 7.5 mg daily, he noted recurring myalgias and stiffness. His WSR was 97 mm/h with a quantitative C-reactive protein of 6.6 (<0.6 to 2.0 mg/dL). The prednisone dose was increased to 20 mg daily, and methotrexate was started as a steroid-sparing agent at a dose of 7.5 mg weekly.

At his next visit, on June 24, 1987, he reported improvement, with less aching, after two weeks on methotrexate. At that time, the WSR was 45 mm/h. Over the next five weeks, the prednisone dose was decreased in 2.5-mg increments at two-week intervals to 10 mg daily, and the methotrexate dose was increased to 10 mg weekly. On August 26, 1987, the WSR was still 45 mm/h.

By September 25, 1987, his WSR was elevated to 72 mm/h, although he denied experiencing any symptoms. The methotrexate dose was increased to 12.5 mg weekly. He continued to take prednisone (10 mg daily). On October 16, 1987, he was experiencing myalgias in his neck

and upper back but denied having eye symptoms or headache. The WSR was 62 mm/h. The prednisone dose was increased to 15 mg daily for two weeks, then lowered to 12.5 mg daily.

His symptoms had diminished by December 16, 1987; therefore, the prednisone dose was tapered to 10 mg daily. The WSR was 45 mm/h.

Comments

Although this patient did not undergo a temporal artery biopsy, he experienced jaw claudication, sore throat, fever, and weight loss, which may be symptoms of giant cell arteritis.^{1,6} The absence of local temporal artery pain or tenderness is common. Fauchald et

al⁶ reported a low incidence of negative temporal artery biopsy results when symptoms of giant cell arteritis were present. In 49 patients with polymyalgia rheumatica symptoms only, temporal artery biopsy showed arteritic changes in 20 specimens.

This information argues against a clear clinical distinction between giant cell arteritis and polymyalgia rheumatica and suggests that they represent points in a disease spectrum. Other investigators who have recently reported on large series of patients with both diseases support this hypothesis.^{8,9} We believe that the symptom of jaw claudication in our third patient, who unquestionably had polymyalgia rheumatica, strongly implies the presence of giant cell arteritis.

RESULTS

All three patients initially responded to moderate-dose prednisone but experienced recurrent symptoms and parallel elevation of the WSR when the dose was tapered toward an acceptable maintenance level. The addition of low-dose, oral, or weekly pulse methotrexate (7.5 to 12.5 mg/wk) resulted in rapidly diminishing symptoms and decreased WSR. It also allowed reduction of the prednisone dose to a lower, safer maintenance level (Table 1). No patient experienced gastrointestinal

symptoms, alopecia, mouth ulcers, or elevation of liver enzymes while taking methotrexate.

DISCUSSION

Corticosteroids are the treatment of choice for giant cell arteritis and polymyalgia rheumatica. Moderate to high doses of corticosteroids result in immediate and complete remission of clinical symptoms after initial treatment with doses ranging from 15 to 60 mg of prednisone or equivalent. The maintenance therapy dose can usually be tapered to an acceptable 5 to 7.5 mg of prednisone or equivalent per day.² However, a small number of patients have disease that resists low-dose maintenance therapy and becomes symptomatic despite low-dose prednisone.¹⁰

Prolonged moderate-dose corticosteroid therapy for polymyalgia rheumatica and giant cell arteritis is of concern because these conditions affect the over-55 age group, usually women—a population also at high risk for osteoporosis. Usually therapy must be continued for two to 10 years or longer,^{3,4} and long-term corticosteroid use may be associated with the development of osteoporosis.

Alternatives to corticosteroids alone are limited. A double-blind study suggests azathioprine in doses of 50 to 150 mg/d can be steroid-sparing in patients with giant cell arteritis.¹¹ Doury and colleagues¹² reported three cases of steroid-resistant giant cell arteritis in which dapsone proved to be steroid-sparing. Spiera and Swerdlow¹³ reported similar findings in a trial of eight patients with giant cell arteritis treated with dapsone. Utsinger¹⁴ found intravenous cyclophosphamide treatment useful in three patients with steroid-resistant giant cell arteritis.

Methotrexate has been shown to be effective in the treatment of rheumatoid arthritis.^{15,16} It has also been shown to be a relatively safe cytotoxic/immunomodulating agent that can be given as prolonged therapy without serious consequences in the majority of rheumatoid arthritis patients.¹⁷⁻²⁰ If the apparent steroid-sparing effect of methotrexate can be confirmed by controlled studies, its demonstrated long-term safety in patients with rheumatoid arthritis recommends it as the cytotoxic drug of choice for steroid-resistant giant cell arteritis and polymyalgia rheumatica.

REFERENCES

- Calamia KT, Hunder GG. Clinical manifestations of giant cell (temporal) arteritis. *Clin Rheum Dis* 1980; 6:389-403.
- Healey LA. Polymyalgia rheumatica and giant cell arteritis. [In] McCarty DJ, ed. *Arthritis and Allied Conditions*. 10th ed. Philadelphia, Lea & Febiger, 1985, pp 901-904.
- Fernandez-Herlihy L. Duration of corticosteroid therapy in giant cell arteritis. *J Rheumatol* 1980; 7:361-364.
- Behn AR, Perera T, Myles AB. Polymyalgia rheumatica and corticosteroids: how much for how long? *Ann Rheum Dis* 1983; 42:374-378.
- Perez-Jimenez F, Lopez-Rubio F, Cañadillas F, Jimenez-Alonso J, Jimenez-Perez J. Giant cell arteritis associated with progressive systemic sclerosis (letter). *Arthritis Rheum* 1982; 25:717-718.
- Fauchald P, Rygvold O, Oystese B. Temporal arteritis and polymyalgia rheumatica. *Ann Intern Med* 1972; 77:845-852.
- Hall S, Ginsburg WW, Vollertsen RS, Hunder GG. The coexistence of rheumatoid arthritis and giant cell arteritis. *J Rheumatol* 1983; 10:995-997.
- Boesen P, Sørensen SF. Giant cell arteritis, temporal arteritis, and polymyalgia rheumatica in a Danish country: a prospective investigation, 1982-1985. *Arthritis Rheum* 1987; 30:294-299.
- Bengtsson B-Å, Malmvall B-E. The epidemiology of giant cell arteritis including temporal arteritis and polymyalgia rheumatica. *Arthritis Rheum* 1981; 24:899-904.
- Graisely B, Audebert AA, Offret H, de Saint-Maur PP. Evolutive de la maladie de Horton sous corticothérapie. *Nouv Presse Med* 1980; 9:2736.
- De Silva M, Hazleman BL. Azathioprine in giant cell arteritis/polymyalgia rheumatica: a double-blind study. *Ann Rheum Dis* 1986; 45:136-138.
- Doury P, Pattin S, Eulry F, Thabaut A. The use of dapsone in the treatment of giant cell arteritis and polymyalgia rheumatica. *Arthritis Rheum* 1983; 26:689-690.
- Spiera H, Swerdlow F. Dapsone as a steroid-sparing agent in giant cell arteritis (GCA)(abst). *Arthritis Rheum* 1987; 30:S62.
- Utsinger PD. Treatment of steroid non-responsive giant cell arteritis (GCA) with cytoxan (abst). *Arthritis Rheum* 1982; 25:S31.
- Weinblatt ME, Coblyn JS, Fox DA, et al. Efficacy of low-dose methotrexate in rheumatoid arthritis. *N Engl J Med* 1985; 312:818-823.
- Wilke WS, Segal AM, Calabrese LH, et al. 24 week double-blind crossover study of methotrexate in rheumatoid arthritis (abstr). *Clin Res* 1985; 33:884A.
- Wilke WS, Calabrese LH, Krall PL, Segal AM. Incidence of toxicity in patients with rheumatoid arthritis treated with methotrexate. [In] Rau R, ed. *Rheumatology*. 9th ed. Basel, S Karger, 1986, pp 134-144.
- Healey LA. The current status of methotrexate use in rheumatic disease. *Bull Rheum Dis* 1986; 36:1-10.
- Segal AM, Koo A, Calabrese L, et al. Twenty year experience of methotrexate (MTX) toxicity in rheumatoid arthritis (RA). *Arthritis Rheum* 1987; 30:S59.
- Kremer JM, Lee JK. The safety and efficacy of the use of methotrexate in long-term therapy for rheumatoid arthritis. *Arthritis Rheum* 1986; 26:822-831.