

## Splenic infarction

A new thrombotic manifestation of the circulating lupus anticoagulant

TIMOTHY P. OBARSKI, DO; JAMES K. STOLLER, MD; CHERYL WEINSTEIN, MD; STEPHEN HAYDEN, MD

■ Thrombotic events are occasionally associated with circulating lupus anticoagulant and may take a variety of clinical forms. The authors report a thrombotic manifestation, spontaneous isolated splenic infarction that occurred in a young man with circulating lupus anticoagulant.

□ INDEX TERMS: LUPUS ERYTHEMATOSUS, SYSTEMIC; SPLENIC INFARCTION □ CLEVE CLIN J MED 1989; 56:174-176

CIRCULATING lupus anticoagulant is a spontaneously acquired IgG or IgM immunoglobulin that interferes with the activation of prothrombin by the activator complex. The lupus anticoagulant is detected by a prolonged activated partial thromboplastin time in all patients and a prolonged prothrombin time and thrombin time in some.<sup>1</sup> In fewer than 1% of patients, the disorder is associated with a hemorrhagic diathesis, but in roughly 30%, a paradoxical thrombotic tendency has been observed.<sup>2</sup> The described spectrum of thrombotic events includes recurrent deep venous thrombosis (DVT), pulmonary emboli, stroke, the Budd-Chiari syndrome, and multiple spontaneous abortions.<sup>3,4</sup> We report a spontaneous isolated splenic infarction in a man with the lupus anticoagulant.

### CASE REPORT

A 41-year-old man was admitted to the Cleveland Clinic in April 1985 with acute onset of sharp, stabbing

left upper quadrant and left lower chest pain. One year earlier, the patient had had recurrent episodes of DVT and pulmonary emboli, for which an inferior vena caval filter was placed. A circulating lupus anticoagulant was detected at that time, but no other features of systemic lupus erythematosus (SLE) were noted. The current left-sided pleuritic pain began three days before admission; at that time an outpatient chest radiograph and ventilation-perfusion (V/Q) scan were both normal. Because of continued pain, tachypnea, and clinical suspicion of pulmonary embolus, the patient was admitted for further evaluation.

On physical examination, the patient was tachypneic (36 breaths per minute), tachycardic (113 beats per minute), and hypertensive (176/84 mmHg). He appeared very nervous and anxious. The thyroid was diffusely enlarged and the right lobe was greater than the left. His lungs were clear to auscultation and percussion. A systolic ejection murmur was heard along the left sternal border with a loud pulmonic component of the second heart sound. There was tenderness to palpation in the left upper quadrant anteriorly and posteriorly.

Initial laboratory examination revealed a hemoglobin level of 13.3 g/dL, 123,000 platelets/mm<sup>3</sup>, negative VDRL, and normal levels of fibrinogen, plasminogen, and anti-thrombin III. The activated partial thromboplastin time was 63.8 seconds, prothrombin time was

From the Departments of Internal Medicine (T.P.O., C.W., S.H.) and Pulmonary Disease (J.K.S.), The Cleveland Clinic Foundation. Submitted July 1987; accepted Oct 1987; revision accepted April 1988.

Address reprint requests to J.K.S., Department of Pulmonary Disease, The Cleveland Clinic Foundation, One Clinic Center, 9500 Euclid Avenue, Cleveland, Ohio 44195.

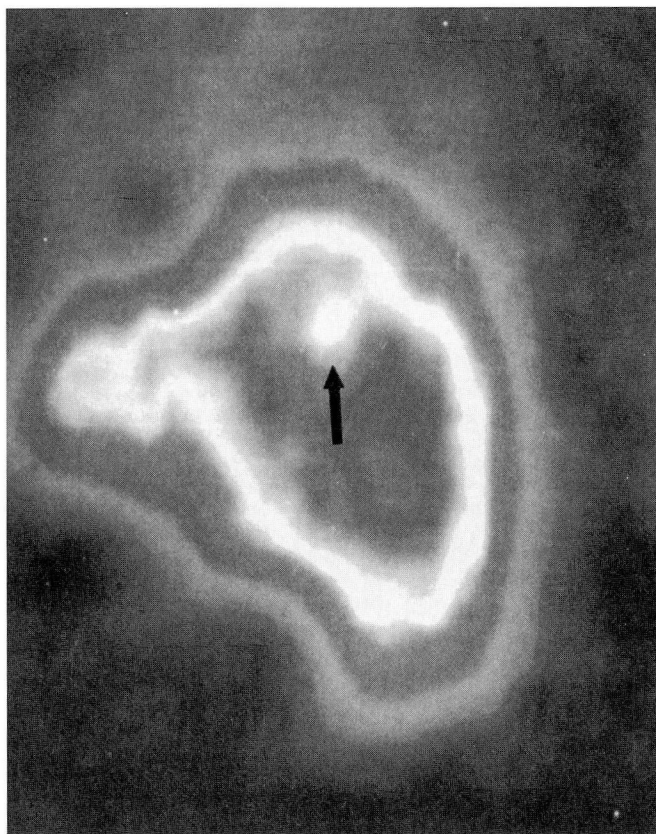


FIGURE 1. Sagittal section of the splenic SPECT scan (see text), showing the area of infarction in the posterolateral aspect of the spleen. The central lucency (arrow) represents hypoperfusion consistent with infarction.

13.7 seconds (control, 13 seconds), the anti-nuclear antigen (ANA) titer was 1:20, the anti-DNA was 15%, and the anti-ENA (extractable nuclear antigen) test was negative. Reaction to *Crithidia lucilia* was not tested. Thyroid function tests were consistent with Graves' disease. The chest radiograph was normal, and a repeat V/Q scan demonstrated multiple matched subsegmental defects and no interval change from the study done three days earlier. However, because of continued suspicion of pulmonary embolus, the patient underwent pulmonary angiography, which, although technically difficult, showed no filling defects and was interpreted as normal. The patient then underwent a single-photon emission computed tomographic (SPECT) scan of the liver and spleen, which showed a focal defect interpreted as a splenic infarction (Figure 1). The presence of a circulating lupus anticoagulant was again verified; using a mixture of normal plasma with the patient's plasma, the activated partial thromboplastin (aPTT)

showed a significant prolongation above the aPTT of normal plasma mixed with saline in similar proportions. The disease was managed conservatively with analgesics and the patient had an uneventful recovery.

#### DISCUSSION

Although thrombotic complications occur in 30% of patients with the circulating lupus anticoagulant and may present in various clinical ways, isolated splenic infarction has not, to our knowledge, been reported previously.

In addition to showing this new manifestation of lupus-anticoagulant-associated thrombosis, our patient again demonstrates that the clinical presentation of splenic infarction can closely mimic pulmonary embolus. In the current case, a liver-spleen scan confirmed the diagnosis of splenic infarction, as it has with 90% sensitivity in a series of patients with splenic infarction already reported from the Cleveland Clinic.<sup>5</sup> Pulmonary embolus was excluded by a normal pulmonary angiogram.

While an earlier report does describe splenic infarction in a patient with SLE and circulating anticoagulant,<sup>6</sup> laparotomy for acute abdominal symptoms in this earlier case revealed thrombosis of the celiac artery, which caused both ischemic colitis and splenic artery thrombosis. Thus, splenic infarction in this earlier report was a result of a more proximal arterial occlusion. Laparotomy was not performed in the current case, but clinical assessment suggested that splenic infarction was an isolated thrombotic event.

Though not previously described in association with a circulating anticoagulant, isolated splenic infarction has occasionally been observed in patients with SLE, and frequently has been ascribed to vasculitis. Itoh et al<sup>7</sup> described a 29-year-old woman with SLE whose splenic infarct was associated with splenic vein thrombosis and was diagnosed by sonography. In 15% of children with SLE, histologic examination of the spleen shows periarterial fibrosis, usually ascribed to antecedent splenic arteritis.<sup>8</sup> Splenic atrophy has also been described in SLE, sometimes without associated vasculitis.<sup>9</sup>

The reason for thrombosis in patients with the lupus anticoagulant remains poorly understood, but several theories have been proposed. An elevated level of fibrinopeptide A, which reflects increased activity of the coagulation system, is present in most patients with SLE,<sup>10</sup> but whether levels are still higher in patients with the lupus anticoagulant remains unknown. Another attractive hypothesis is that cryoglobulinemia, which is

present in 60%–70% of patients with lupus anticoagulant,<sup>11</sup> abets thrombosis, but no data supporting this relationship are available. Plasma from patients with SLE has been shown to inhibit prostacyclin (a platelet-aggregation inhibitor) in the rat aorta,<sup>2</sup> and a prostacyclin inhibitor has been observed in plasma from patients with thrombotic complications of a circulating anticoagulant.<sup>11</sup> Whether prostacyclin inhibition is due to the lupus anticoagulant, however, also remains unclear. Certainly, further investigation will be needed to clarify the

mechanism by which the circulating anticoagulant causes thrombosis.

# SUMMARY

Isolated splenic infarction is another thrombotic manifestation of the circulating lupus anticoagulant and should be included among already recognized thrombotic complications of this unusual clinical problem.

# REFERENCES

1. Schleider MA, Nachman RL, Jaffe EA, Coleman M. A clinical study of the lupus anticoagulant. *Blood* 1976; **48**:499–509.
2. Carreras LO, Vermeylen JG. "Lupus" anticoagulant and thrombosis—possible role of inhibition of prostacyclin formation. *Thromb Haemostas* 1982; **48**:38–40.
3. Mueh JR, Herbst KD, Rapaport SI. Thrombosis in patients with the lupus anticoagulant. *Ann Intern Med* 1980; **92**:156–159.
4. Pomeroy C, Knodell RG, Swaim WR, Areson P, Mahowald ML. Budd-Chiari syndrome in a patient with the lupus anticoagulant. *Gastroenterology* 1984; **86**:158–161.
5. Jaroch MT, Broughan TA, Hermann RE. The natural history of splenic infarction. *Surgery* 1986; **100**:743–750.
6. Asherson RA, Morgan SH, Harris EN, Gharavi AE, Krausz T, Hughes GRV. Arterial occlusion causing large bowel obstruction—a reflection of clotting diathesis in SLE. *Clin Rheum* 1986; **5**:102–106.
7. Itoh K, Hayashi A, Kawai T, Sumiya M, Kano S. Echography of splenic infarct in a case of systemic lupus erythematosus. *J Clin Ultrasound* 1978; **6**:113–114.
8. Kelley WN, Harris ED, Ruddy S, Sledge CB. *Textbook of Rheumatology*. 2nd ed. Philadelphia, WB Saunders, 1985, pp 1082–1083.
9. Dillon AM, Stein HB, English RA. Splenic atrophy in systemic lupus erythematosus. *Ann Intern Med* 1982; **96**:40–43.
10. Cronlund M, Hardin J, Burton J, Lee L, Haber E, Bloch KJ. Fibrinopeptide A in plasma of normal subjects and patients with disseminated intravascular coagulation and systemic lupus erythematosus. *J Clin Invest* 1976; **58**:142–151.
11. Budman DR, Steinberg AD. Hematologic aspects of systemic lupus erythematosus: current concepts. *Ann Intern Med* 1977; **86**:220–229.
12. McVerry BA, Machin SJ, Parry H, Goldstone AH. Reduced prostacyclin activity in systemic lupus erythematosus. *Ann Rheum Dis* 1980; **39**:524–525.