

Acquired factor X deficiency in systemic amyloidosis¹

Fred V. Lucas, M.D.
Andrew J. Fishleder, M.D.
Richard C. Becker, M.D.
Deborah S. Cavalier, M.D.
Raymond R. Tubbs, D.O.

Acquired factor X deficiency has been described in association with primary amyloidosis in a small number of patients. Although readily corrected in vitro by mixing patient plasma with normal plasma, the deficiency is not easily corrected in vivo because transfused factor X is rapidly cleared from the circulation. It has been suggested that the mechanism underlying this phenomenon may be the selective binding of factor X to amyloid and its consequent removal from the circulation. Two cases of primary amyloidosis and coexistent acquired factor X deficiency are reported. Immunostains for factor X and immunoglobulin light chains showed the coagulation factor in the region of the amyloid deposits. The findings directly support the hypothesis that factor X deficiency in primary amyloidosis is caused by clearance of factor X by binding to amyloid fibrils.

Index terms: Amyloidosis • Factor X

Cleve Clin J Med 54:399–406, Sep/Oct 1987

¹ Departments of Laboratory Hematology (F.V.L., A.J.F.), Internal Medicine (R.C.B.), and Pathology (R.R.T.), The Cleveland Clinic Foundation. Submitted for publication Feb 1987; accepted May 1987.

0891-1150/87/05/0399/08/\$3.00/0

Copyright © 1987, The Cleveland Clinic Foundation

Acquired factor X deficiency in previously healthy individuals has been described in association with primary amyloidosis¹⁻⁸ and is thought to be the result of extraction of the factor from the circulation rather than decreased hepatic synthesis. Furie et al⁷ studied the clearance of I-131-labeled factor X following intravenous infusion in a patient with this entity and demonstrated that 85% of the labeled factor disappeared from the circulation with a half-life of approximately 30 seconds.⁷ Triplett et al⁹ partially purified amyloid fibrils from another patient with factor X deficiency and observed that the fibrils adsorbed factor X procoagulant from normal plasma. Purified amyloid fibrils

Table 1. Mixing studies in patients with amyloidosis and factor X deficiency

Mixture	Patient 1		Patient 2	
	PT (sec)	APTT (sec)	PT (sec)	APTT (sec)
Patient alone	20.0	35.0	25.5	40.9
1 part patient: 1 part normal	12.0	—	13.9	26.8
1 part patient: 1 part aged serum	12.0	—	15.1	22.0
1 part patient: 1 part adsorbed plasma	20.0	—	27.1	37.8

PT = prothrombin time, normal = 10–13 sec; APTT = activated partial thromboplastin time, normal = 21–31 sec.

Table 2. Factor assays in patients with amyloidosis and isolated factor X deficiency

Coagulation factor	Patient 1	Patient 2	Normal
II (U/mL)	—	0.93	0.5–1.5
VII (U/mL)	0.84	0.55	0.5–1.5
IX (U/mL)	1.00	1.20	0.5–1.5
V (U/mL)	1.06	—	0.5–1.5
X			
Function (U/mL)	0.06	0.02	0.5–1.5
Antigen (μ g/mL)	2.26	—	4.09–7.67

from the spleen of a similar patient were utilized by Furie et al⁸ to prepare amyloid fibril agarose columns that retained I-125-labeled human factor X. These studies provide strong evidence for binding of factor X to amyloid deposits within tissue.

We recently evaluated two patients with unexpectedly prolonged prothrombin times (PT) and activated partial thromboplastin times (APTT). In both patients, further investigation revealed isolated deficiency of factor X in association with primary amyloidosis. The purpose of this report is to emphasize the clinical association of factor X deficiency with amyloidosis, outline the proper laboratory approach to the coagulation abnormality, and provide immunohistologic evidence that factor X antigen is present in amyloid deposits.

Case reports

Case 1. The patient was a 63-year-old white man with a seven-year history of hypertension and renal failure who experienced lethargy, 10-lb (4.5-kg) weight loss, and easy bruisability during two years before admission. On admission, his vital signs were normal. Physical examination revealed scleral and subungual hemorrhages and ecchymoses

over the eyelids. The liver was enlarged 8–10 cm below the costal margin in the midclavicular line. There was no splenomegaly. Laboratory studies showed a hemoglobin level of 8.9 g/dL with normocytic normochromic indices, BUN 30 mg/dL, and creatinine level 2.5 mg/dL. Alkaline phosphatase was 170 IU/L, and the remainder of liver function tests were within normal limits. The PT was 20 seconds (normal 10–13 seconds), and the APTT was 35 seconds (normal 21–31 seconds). The thrombin time was 11 seconds (normal 10–13 seconds), and the bleeding time was 3 minutes (normal less than 8 minutes). Serum protein electrophoresis was normal. Urine protein electrophoresis showed a mild diffuse elevation in alpha 2 globulin. Serum and urine immunoelectrophoresis were not performed. A bone marrow biopsy was normal. Prolonged clotting times were determined to be due to factor X deficiency. Unsuccessful attempts were made to correct the abnormality using vitamin K, fresh frozen plasma, and factor IX concentrate (Konyne, Cutter Laboratories, Berkeley, CA). These results suggested that the hepatomegaly might be due to amyloidosis, but a liver biopsy was not performed due to the coagulopathy. Three weeks following admission cardiac tamponade developed and the patient died; an autopsy was performed.

Case 2. The patient was a 60-year-old white man who experienced progressive shortness of breath, orthopnea, and paroxysmal dyspnea one year before referral to The Cleveland Clinic Foundation. He experienced moderate improvement initially when treated with digitalis and furosemide (Lasix), however, he returned with marked swelling of the lower extremities and laboratory findings consistent with nephrotic syndrome. A kidney biopsy demonstrated light and electron microscopic findings consistent with renal amyloid deposits. He was transferred to the Cleveland Clinic for further evaluation. Physical examination revealed scattered petechiae and ecchymoses. There was a grade IV systolic cardiac murmur. The liver measured 14.5 cm below the costal margin in the midclavicular line, and the tip of the spleen was palpable. There was 4+ pitting edema bilaterally. Laboratory evaluation demonstrated a hemoglobin level of 8.9 g/dL with normocytic normochromic indices. The white blood cell count was $10.6 \times 10^9/L$ with a normal differential and the platelet count was $516 \times 10^9/L$. Abnormalities in serum chemistry determinations included BUN 136 mg/dL, creatinine 2.1 mg/dL, total bilirubin 2.0 mg/dL, total protein 5.1 g/dL, and albumin 3.0 g/dL. The PT was 25.5 seconds, the APTT was 40.9 seconds, and the thrombin time was 11 seconds. Bone marrow aspiration biopsy revealed increased numbers of mature plasma cells. Serum and urine immunoelectrophoresis showed no monoclonal immunoglobulin. Further evaluation of the prolonged PT and APTT showed a factor X deficiency. The patient was discharged and lost to follow-up.

Materials and methods

In vitro coagulation studies

PT and APTT values were measured using an MLA 700 automated instrument (Medical Laboratory Automation, Inc., Mount Vernon, NY). The reagents for these tests were thromboplastin-C and actin (American Dade, Inc., Miami, FL).

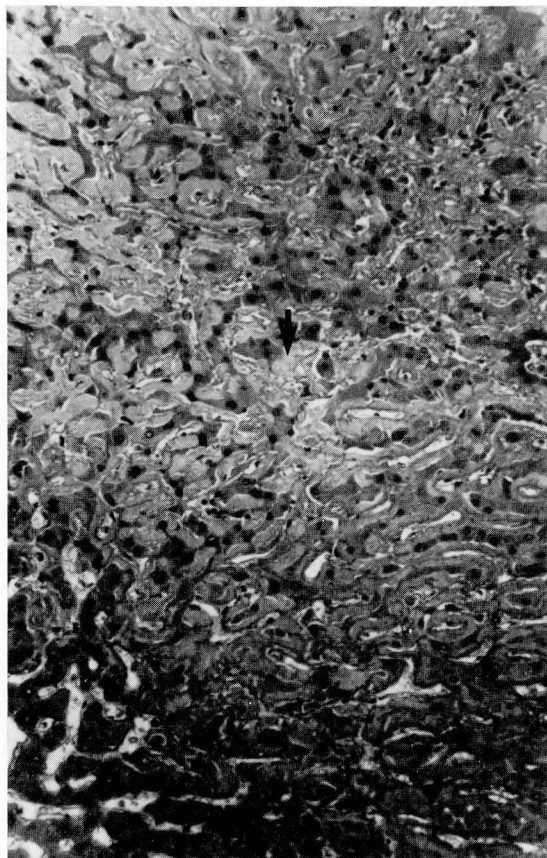


Fig. 1. Liver section with sinusoidal homogeneous amyloid material (arrow) adjacent to hepatocytes (hematoxylin and eosin $\times 160$).

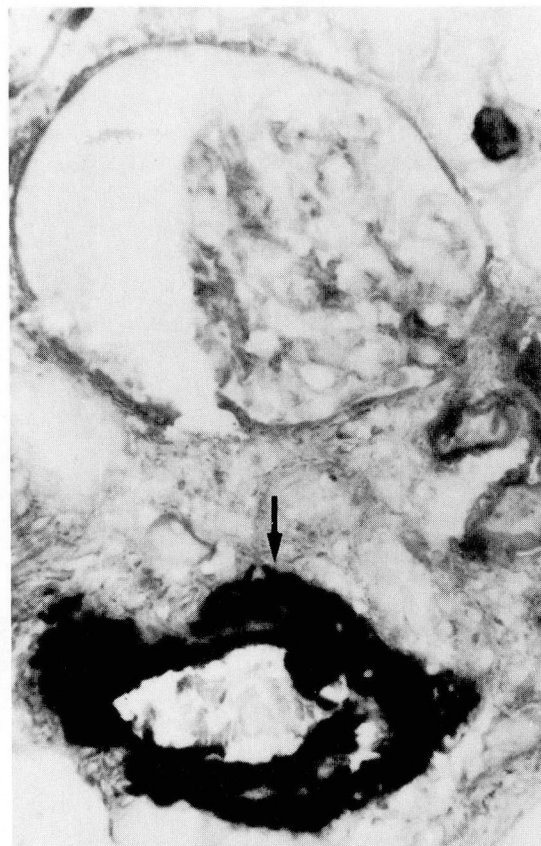

Fig. 2. Renal segment demonstrating amyloid deposition (arrow) within renal arteriole. No deposition was present in glomeruli (Immunoperoxidase: anti-kappa light chain antiserum, PAS counterstain $\times 400$).

Correction studies were performed using pooled normal plasma, aged serum (Dade, Inc.), and adsorbed plasma (Dade). Aged serum was deficient in fibrinogen, prothrombin, factor V, and factor VIII:C (antihemophilic factor). Adsorbed plasma was deficient in prothrombin, factor X, factor VII, and factor IX. One-stage factor assays were performed using factor-deficient plasma from Dade, Inc. and pooled plasma made in our laboratory from >25 normal volunteers. Standard curves were constructed using at least four dilutions of the normal pool. Patients' plasmas were tested using dilutions of 1:10, 1:20, and 1:40. Assays for factors in the common pathway were performed using prothrombin times.

A radioimmunoassay of factor X antigen¹⁰ in the plasma from patient 1 was kindly performed by Daryl S. Fair, Ph.D., of the Scripps Clinic and Research Foundation.

Morphologic studies

Fresh liver and kidney segments obtained at autopsy from the first patient were fixed in zinc-substituted Zenker's solution and buffered formalin and stained with hematoxylin and eosin (H&E), crystal violet, and Congo red. Segments of kidney and liver were fixed in glutaraldehyde, processed for electron microscopy using standard techniques, and examined with a Philips 400T transmission electron microscope.

Immunohistochemical demonstration of factor X in tissue was achieved using air-dried, cryostat-frozen sections that were incubated for 20 minutes with a 1:15 dilution of monospecific rabbit anti-X antibody (obtained from D. Fair, Scripps Clinic). After being washed in phosphate-buffered saline (PBS) the slides were incubated for 30 minutes with peroxidase-conjugated goat anti-

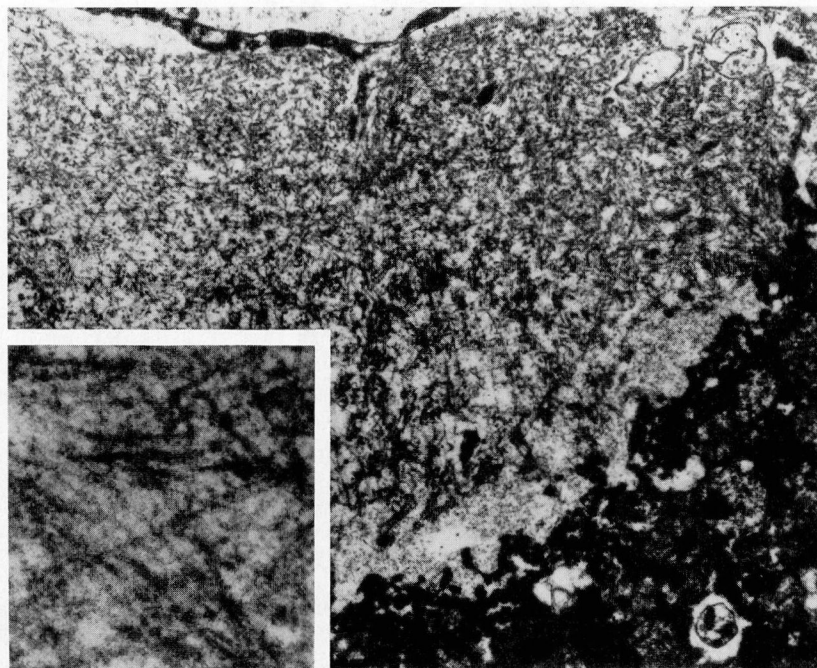


Fig. 3. Electron micrograph demonstrating amyloid deposition adjacent to hepatocyte in space of Disse. The amyloid fibrils vary in width from 12–16 nm ($\times 10,600$; inset $\times 80,000$).

rabbit IgG (Fc fragment specific, Cappel Laboratories, Malvern, PA). They were further washed in PBS and Tris-HCl and then incubated in four changes of Hanker-Yates reagent (paraphenylenediamine and pyrocatechol, HYR, Polysciences, Warrington, PA). Finally, the slides were washed, counterstained with H&E, and examined by light microscopy.

Tissue was similarly processed for immunofluorescence. Frozen sections were incubated with the monospecific rabbit anti-X antibody, washed with PBS, incubated with fluorescein-conjugated sheep anti-rabbit IgG, washed again, and examined with a Leitz fluorescent microscope. Frozen sections of kidney and liver were studied by direct immunoperoxidase and immunofluorescence for kappa and lambda light chains utilizing monospecific peroxidase-conjugated anti-human kappa and anti-human lambda light chains (DAKO). The method was similar to that described above, utilizing the identical Hanker-Yates reagent washes for color reaction product development.

To demonstrate further the specificity of the rabbit anti-factor X antibody, aliquots of antibody were incubated at 37°C for one hour either with human factor IX complex (Konyne, Cutter Laboratories, Berkeley, CA) or Bence Jones pro-

tein and centrifuged. The supernatant was then used in place of the primary anti-factor X antibody in the indirect immunoperoxidase method described above.

Results

The coagulation correction studies performed using plasma from these two patients are shown in *Table 1*. The prolonged clotting times were completely corrected by mixing patient plasma with normal plasma and were almost entirely corrected by mixing with aged serum. The times were not corrected by mixing patient plasma with adsorbed plasma. These studies ruled out the possibility that a circulating anticoagulant existed and further suggested that there was a deficiency of factor X.

Results of one-stage factor assays in these two patients are shown in *Table 2*. Both plasmas showed an isolated deficiency of factor X (0.06 U/mL and 0.02 U/mL). All dilutions of patient plasma tested gave identical results, confirming that a circulating anticoagulant was not present. In addition, the plasma concentration of factor X antigen in the first patient was 2.26 $\mu\text{g/mL}$ (normal 4.09–7.67 $\mu\text{g/mL}$). This antigen concentration was significantly lower than normal but

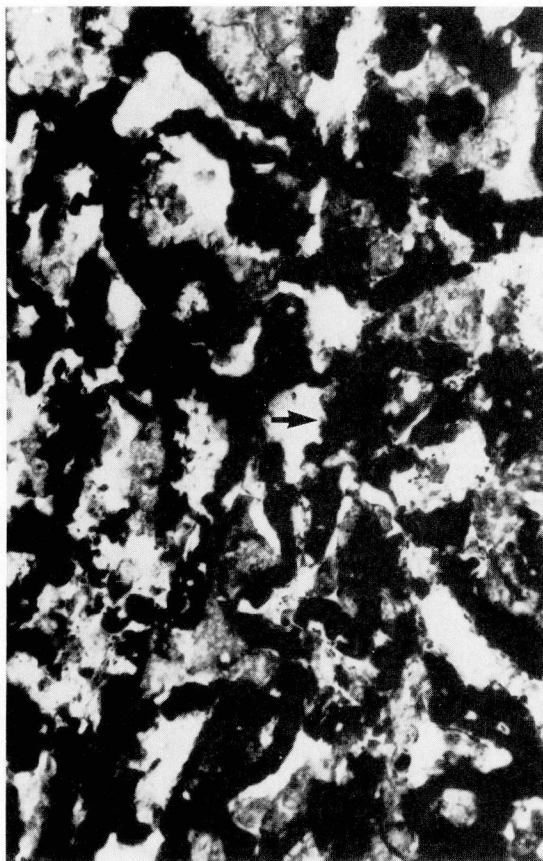


Fig. 4. Immunoperoxidase stain for factor X demonstrating deposits of factor X (arrow) adjacent to hepatocytes ($\times 400$).

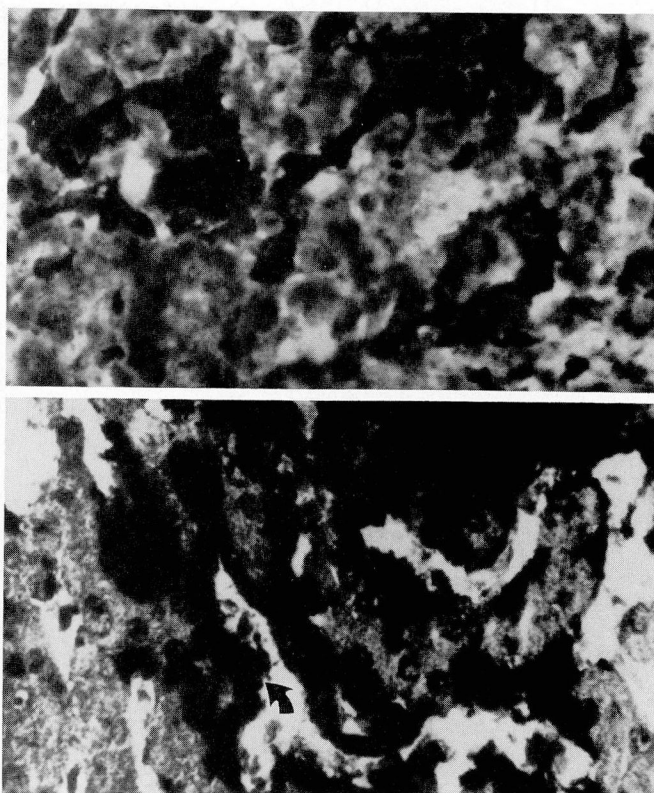


Fig. 5. Hepatic segment demonstrating monoclonal deposition of immunoglobulin light chains (arrow). Positive reaction on the left is demonstrated against kappa light chains (Immunoperoxidase: left: anti-kappa, right: anti-lambda, $\times 400$).

disproportionately reduced in relation to the one-stage functional assay.

An aggressive attempt was made to correct the coagulopathy in the first patient. Following infusion of 7 units of fresh frozen plasma, the factor X activity remained 0.06 U/mL and the PT was 20 seconds. An additional 6 units of factor IX concentrate (Konyne, Cutter Laboratories, Berkeley, CA) was infused. Immediately following this infusion, a plasma sample was obtained. The PT was 20 seconds and the factor X assay was 0.01 U/mL.

The autopsy performed on the first patient showed cardiomegaly (700 g) with fibrinous pericarditis; a pale, firm enlarged liver (3800 g); and splenomegaly (250 g). There was no evidence of immediate hemorrhage into the pericardial space. Microscopic examination revealed massive amyloid deposition within hepatic sinusoids, moderate masses of amyloid within splenic parenchyma, and lesser degrees of deposition within

medium and large vessels of the heart, lungs, testes, and kidneys.

Liver sections stained with H&E (*Fig. 1*) contained eosinophilic homogeneous material in the sinusoids, closely apposed to the adjacent hepatocytes. This material, which showed apple-green birefringence by Congo red staining, was also present in renal vessels (*Fig. 2*) but not in the glomeruli or tubules. Electron microscopic features of the material (*Fig. 3*) were typical for amyloid. Parallel longitudinal subunits having an average width of 12 nm were arranged in a crisscrossed, fibrillar pattern and were extracellular. Although the deposits appeared to be sinusoidal by light microscopy, they were identified principally within the space of Disse by transmission electron microscopy.

Immunoperoxidase and immunofluorescence staining of liver and kidney for factor X (*Fig. 4*) and immunoglobulin light chains (*Fig. 5*) showed prominent staining for kappa light chains and

factor X in the amyloid material. Stains for lambda light chains were negative. Positive staining for factor X was abolished by preadsorption of the antifactor X antibody with factor IX concentrate but was unaffected by preadsorption with kappa or lambda Bence Jones protein.

Discussion

Inherited deficiencies of factor X are rare disorders of coagulation.¹¹ Acquired deficiencies of factor X as isolated abnormalities are even more unusual and have been described as case reports in association with renal adenocarcinoma, fungicide exposure, and mycoplasma pneumonia.¹²⁻¹⁵ In addition, factor X deficiency may occur in patients with primary systemic amyloidosis and, as this report emphasizes, it may be responsible for an otherwise unexplained prolongation in the PT and APTT. Alternatively, the recognition of an isolated factor X deficiency in an adult should suggest, as it did in Case 1, that the patient may have amyloidosis.

Although a plasma cell dyscrasia was not identified in patient 1, the immunohistochemical reactivity of his amyloid for kappa light chains suggested that it was of the AL type. This type is usually found in the setting of plasma cell dyscrasia and is distinguished from the nonimmunoglobulin AA type and the hereditary AF type. The type of renal amyloid in patient 2 could not be characterized due to lack of tissue for study.

Bleeding is a frequent complication in amyloidosis, occurring in 41% of patients in a recently described series.¹⁶ There are additional hemostatic abnormalities in amyloidosis, which include prolonged thrombin times possibly due to dysfibrinogenemia, abnormal platelet aggregation, abnormal vascular integrity, and hepatic insufficiency with reduced coagulation factor synthesis.^{16,17} The general lack of correlation between bleeding and coagulation test abnormalities suggests that amyloid infiltration of vessel walls and resulting damage to vascular integrity is a major cause of most bleeding events.¹⁶

Failure of hepatic synthesis of factor X was judged to be an unlikely event in our two patients since other coagulation factors made in the liver were normal. In addition, the infusion of fresh frozen plasma or factor IX concentrate failed to raise the plasma factor X level, suggesting that the infused factor X was being removed rapidly from the circulation or converted to a nonfunctional form.

The mechanism of isolated factor X deficiency in primary systemic amyloidosis has received considerable attention. Immobilization of I-131-labeled factor X in vascular or extravascular deposits of amyloid was observed by Furie et al.⁷ They subsequently demonstrated that amyloid fibril-agarose columns tightly bind factor X, and to a lesser extent, factor IX and prothrombin.⁸ Amyloid fibrils prepared from patients with and without factor X deficiency showed similar binding properties. This is in contrast to a preliminary report by Triplett et al.⁹ suggesting that factor X did not bind to fibrils prepared from patients without factor X deficiency.

The present immunohistochemical study conclusively demonstrates that tissue deposits of amyloid from a patient with factor X deficiency contained factor X antigen and strongly supports the hypothesis that tissue binding causes a deficiency of this plasma protein. A similar recent study by Wolf and Fujihara¹⁸ echoes this finding. Two critical aspects should influence this binding: the affinity of the amyloid for factor X and the total amount of amyloid exposed to circulating blood. We have no data on the affinity of the interaction in our patient; however, based on morphologic evidence, a great deal of hepatic and splenic amyloid was exposed to circulating sinusoidal blood. A variable amount of exposure occurred in the pulmonary vasculature where a significant amount of endothelium remained intact.

The molecular basis of the selective interaction of factor X with some amyloids remains unexplained. The vitamin K-dependent coagulation proteins (prothrombin, factors VII, IX, X, protein C, and protein S) bear striking chemical similarity, and yet a deficiency of factor X seems to occur disproportionately in patients with amyloidosis. Binding studies performed *in vitro* further support a relative specificity of factor X interaction with amyloid fibrils. The ability of amyloid from different individuals to bind factor X varies widely, however, suggesting significant variation in the protein-protein interaction.

Several different classes of defects in factor X from patients with amyloidosis have been described by Fair and Edgington.¹⁰ These vary from a parallel reduction of factor X antigen and functional activity to a discordant reduction in functional measurements. Reduced function may be detected by assays measuring factor X activation either by the extrinsic pathway (PT), the intrinsic

pathway (APTT), Russell's viper venom, or any combination of these three methods. In none of the patients studied, however, was there a reduced concentration of a normally functional factor X. Instead, all samples contained functionally defective molecules. This observation suggests that amyloid may both remove factor X from the circulation and render it defective by some reversible interaction. Both mechanisms seem responsible for the factor X deficiency in our patient 1 since he had a low antigen concentration, functionally defective X molecules, and immunohistologic evidence of factor X in the liver.

The treatment of factor X deficiency is usually replacement therapy in the form of fresh frozen plasma. In life-threatening situations, prothrombin complex concentrates (containing factors II, VII, IX, and X) are indicated. In these situations, the half-life of transfused factor X is usually approximately 30–40 hours.¹⁹ However, in patients with primary systemic amyloidosis, the half-life of infused factor X is significantly shortened.⁷ Therefore, attempts to correct the abnormality using plasma products may be futile. In addition, the use of these products is associated with a risk of hepatitis, thromboembolic phenomenon, and acquired immunodeficiency syndrome.^{20–22} Successful short-term treatment of factor X deficiency with splenectomy may be achieved, but probably only if the spleen is the major site of amyloid deposition and if large deposits of amyloid do not exist in other sites.²³ Treatment of the underlying primary amyloidosis would seem to be the only real long-term solution to the disorder. However, combinations of various therapeutic agents for this purpose have only yielded mixed results.^{24–26}

In summary, an acquired factor X deficiency is identified in some patients with primary systemic amyloidosis. Its presentation may vary from easy bruisability to life-threatening hemorrhage. The diagnosis may be made if the entity is suspected clinically and if careful attention is paid to the screening coagulation tests. The mechanism of the factor X deficiency appears to be a relatively specific immobilization of this protein in amyloid deposits that are exposed to the circulation. However, the molecular nature of the factor X-amyloid binding remains unexplained. Treatment of the coagulopathy with vitamin K or infusion of plasma and prothrombin complex concentrate is predictably unsuccessful.

Fred V. Lucas, M.D.

Department of Laboratory Hematology
Cleveland Clinic Foundation
9500 Euclid Avenue
Cleveland, OH 44106

References

1. Korsan-Bengsten K, Hjort PF, Ygge J. Acquired factor X deficiency in a patient with amyloidosis. *Thromb Diath Haemorrh* 1962; **7**:558–566.
2. Howell M. Acquired factor X deficiency associated with systemic amyloidosis. *Blood* 1963; **21**:739–744.
3. Pechet L, Kastrul JJ. Amyloidosis associated with factor X (Stuart) deficiency. *Ann Intern Med* 1964; **61**:315–318.
4. Bernhardt B, Valletta M, Brook J, Lejniaks I. Amyloidosis with factor X deficiency. *Am J Med Sci* 1972; **264**:411–415.
5. Jacobson RJ, Sandler SG, Rath CE. Systemic amyloidosis associated with micro-angiopathic haemolytic anemia and factor X (Stuart factor) deficiency. *S Afr Med J* 1972; **46**:1634–1637.
6. Galbraith PA, Sharma N, Parker WL, Kilgour JM. Acquired factor X deficiency. Altered plasma antithrombin activity and association with amyloidosis. *JAMA* 1974; **230**:1658–1660.
7. Furie B, Greene E, Furie BC. Syndrome of acquired factor X deficiency and systemic amyloidosis: in vivo studies of the metabolic fate of factor X. *N Engl J Med* 1977; **297**:81–85.
8. Furie B, Voo L, McAdam K, Furie BC. Mechanism of factor X deficiency in systemic amyloidosis. *N Engl J Med* 1981; **304**:827–830.
9. Triplett DA, Bang NU, Harms CS, Benson MD, Miletich JP. Mechanisms of acquired factor X deficiency in primary amyloidosis. *Blood* 1977; **50**(Suppl 1):285. (abs)
10. Fair DS, Edgington TS. Heterogeneity of hereditary and acquired factor X deficiencies by combined immunochemical and functional analyses. *Br J Haematol* 1985; **59**:235–248.
11. Gonyea LM, Krivit W. Congenital coagulation deficiency of Stuart factor activity. *J Lab Clin Med* 1958; **51**:398–409.
12. Graham JB, Barrow EM, Synne TR. Stuart clotting defect III: An acquired case with complete recovery. [In] Brinkhous KM, ed. *Hemophilia and Other Hemorrhagic States*. Chapel Hill, University of North Carolina Press, 1958, pp 158–166.
13. Stefanini M, Wiggishoff CC. Stuart factor (Factor X) deficiency associated with renal and adrenal cortical insufficiency. *Ann Intern Med* 1966; **64**:1285–1291.
14. Bayer WL, Curiel D, Szeto ILF, Lewis JH. Acquired factor X deficiency in a Negro boy. *Pediatrics* 1969; **44**:1007–1009.
15. Peuscher FW, Van Aken WG, van Mourik JA, Swaak AJG, Sie LH, Statius van Eps LW. Acquired transient factor X (Stuart factor) deficiency in a patient with mycoplasma pneumonia infection. *Scand J Haematol* 1979; **23**:257–264.
16. Yood RA, Skinner M, Rubinow A, Talarico L, Cohen AS. Bleeding manifestations in 100 patients with amyloidosis. *JAMA* 1983; **249**:1322–1324.
17. Greipp PR, Kyle RA, Bowie EJW. Factor-X deficiency in amyloidosis. *Am J Hematol* 1981; **11**:443–450.
18. Wolf PL, Fujihara S. Immunoperoxidase identification of factor X in systemic amyloid tissues formalin-fixed and paraffin-embedded. *Lab Invest* 1981; **44**:77A.
19. Hellemans J, Vorlat M, Verstraete M. Survival time of prothrombin and factors VII, IX and X after completely synthesis blocking doses of coumarin derivatives. *Br J Haematol* 1963; **9**:506–512.

20. Update: Acquired Immune Deficiency Syndrome In The United States. MMWR 1985; **34**:245-248.
21. Fauci AS. Acquired immune deficiency syndrome: an update. Ann Intern Med 1985; **102**:800-813.
22. Broder S, Gallo RC. A pathogenic retrovirus (HTLV-III) linked to AIDS. N Engl J Med 1984; **311**:1292-1299.
23. Greipp PR, Kyle RA, Bowie EJW. Factor X deficiency in primary amyloidosis. N Engl J Med 1979; **301**:1050-1051.
24. Haber S. Norethynodrel in the treatment of factor X deficiency. Arch Intern Med 1964; **114**:89-94.
25. Kyle RA, Greipp PR. Primary systemic amyloidosis: comparison of melphalan and prednisone versus placebo. Blood 1978; **52**:818-827.
26. Kyle RA, Wagoner RD, Holley KE. Primary systemic amyloidosis: resolution of the nephrotic syndrome with melphalan and prednisone. Arch Intern Med 1982; **142**:1445-1447.