

Differentiation between AIDS-related and non-AIDS-related Kaposi's sarcoma¹

Wilma F. Bergfeld, M.D.
Alexander Zemtsov, M.D.
Richard S. Lang, M.D.

The epidemiology, clinical presentation, and clinical course of AIDS-related and non-AIDS-related Kaposi's sarcoma are reviewed and compared. The histopathological features for diagnosis of Kaposi's sarcoma are described. The authors confirm an earlier report that patients with non-AIDS-related Kaposi's sarcoma have no HIV antibodies, and recommend serologic HIV testing for all patients with a diagnosis of Kaposi's sarcoma.

Index terms: Acquired immunodeficiency syndrome • Sarcoma, Kaposi's

Cleve Clin J Med 54:315-319, July/Aug 1987

Kaposi's sarcoma (KS) was first described by the Hungarian Moricz Kaposi in Vienna in 1872. Until the AIDS epidemic, KS was a rare tumor; before 1980 its incidence in the United States was 0.02 to 0.06 per 100,000 population.¹ The new interest in the etiology and pathophysiology of KS was sparked by the fact that in 30% of clinically certified cases of AIDS KS is the initial manifestation of the disease or appears later in its course.²⁻⁴ The disease course, clinical presentation, and epidemiology of non-AIDS-related

KS are strikingly different from those of AIDS-related KS. This report reviews different types of KS with a special emphasis on the histopathology of this tumor and the recent advances in understanding the histopathology.

Classical Kaposi's sarcoma

The majority of patients with classical KS are white men of Eastern European and Mediterranean ancestry, especially Italians, Greeks, and Ashkenazi Jews of Polish and Russian descent. However, KS rarely occurs in more than one person in the same family.⁵ The male to female ratio is 15:1, and patients most commonly present in the sixth, seventh, or eighth decade of life.⁶

Clinically, patients have asymptomatic brownish-red to purple or blue patches, plaques, or nodular skin lesions on the lower extremities, including the soles of the feet.⁷ KS lesions do not bleed excessively when cut or bruised, despite their highly vascular appearance. Lesions increase in size slowly and often coalesce in time. Chronic venous stasis and lymphedema of the involved extremity frequently complicate the clinical course. Local invasion of surrounding subcutaneous tissue and bone occur rarely.⁷

The clinical course is normally chronic and indolent, and visceral involvement occurs late, if at all. Most patients die not of KS but of a different cause.⁶ Up to one-third of patients have secondary, primary malignancy. This second malignancy is often lymphoreticular, such as Hodgkin's lymphoma or lymphosarcoma.⁶

¹Department of Dermatology, The Cleveland Clinic Foundation. Submitted for publication Aug 1986; accepted Jan 1987.

0891-1150/87/04/0315/05/\$2.25/0

Copyright © 1987, The Cleveland Clinic Foundation

The treatment of choice is local radiation therapy. Patients with classical KS typically do not have antibodies for the HIV (HTLV-III) virus in their blood.² The authors of this paper are studying an elderly Greek man who has had classical

KS for twenty years; as of August 1986 his blood showed no antibodies for HIV retrovirus (*Tables 1 and 2*).

Kaposi's sarcoma in Africa

Non-AIDS-related KS is endemic in Equatorial Africa. The highest rates are found in North and Eastern Zaire, Rwanda, Burundi, French Equatorial Africa, Uganda, Malawi, Tanzania, Zimbabwe, and Kenya. The rates fall off toward West and South Africa. In some countries such as Uganda it accounts for 9% of all cancers. Unlike Burkitt's lymphoma, endomyocardial fibrosis, and idiopathic tropical splenomegaly syndrome, all of which occur in other tropical regions of the world, endemic KS is limited to sub-Saharan Africa.⁷

African KS occurs in two groups of patients: in adults (as with classical KS) it most commonly occurs in men (11:1 ratio) in the fourth to seventh decades,⁸ and in children it accounts for approximately 7% of cancer cases.⁸

Clinically, KS in African adults is similar to KS in elderly Europeans.⁸ However, occasionally in some patients it grows into deep fascia, resembles granuloma pyogenicum, and bleeds easily.⁷ A

Table 1. Predisposing factors for Kaposi's sarcoma

Groups predisposed to Non-AIDS Kaposi's sarcoma	Individuals at high risk for AIDS with or without Kaposi's sarcoma*
1. Elderly men of Mediterranean or Ashkenazi Jewish lineage	1. Homosexual or bisexual men
2. Black African men from Equatorial Africa	2. Intravenous drug abusers
3. Patients receiving immunosuppressive therapy	3. Hemophiliacs and other individuals who received numerous blood transfusion products after 1980
	4. Heterosexual partners of any of the three groups above
	5. Newborn children of mothers with AIDS or asymptomatic women carriers of the HIV virus

* In the past Haitians were also considered a risk group for developing AIDS.

Table 2. Types of Kaposi's sarcoma

Features	Non-AIDS-related Kaposi's sarcoma				AIDS-related Kaposi's sarcoma
	Classical Kaposi's sarcoma	African Kaposi's sarcoma		Kaposi's sarcoma in immunosuppressed patients	
		Adults	Children		
Location	Most common on lower extremities	Most commonly cutaneous sites	Lymph nodes and cutaneous sites	Frequent involvement of noncutaneous sites	Cutaneous lesion on upper half of body, mucous membrane, and viscera
Clinical course	Chronic indolent course	Normally chronic indolent course	Often rapid fulminant course	Tumor regression in some patients after immunosuppressive agent is withdrawn. Prognosis variable	Lethal disease. Often rapid fulminant course. Death due to infection, visceral Kaposi's sarcoma, or other types of cancer
Associated features	Often associated with second primary malignancy of lymphoreticular system	Second primary malignancy uncommon	—	General state of immunosuppression	Opportunistic infection. Increased incidence of lymphomas
Treatment	Local radiotherapy and/or IV vinblastine chemotherapy	Local radiotherapy and/or IV vinblastine chemotherapy	Systemic chemotherapy for rapidly progressive disease	Withdrawal of immunosuppressive agent. Radiotherapy for cutaneous lesions. Chemotherapy for visceral involvement	Chemotherapy for life-threatening visceral involvement

second primary malignancy is uncommon.⁸ In African children KS often involves lymph nodes and then viscera, and it follows a rapid fulminant course.⁹

The treatment of cutaneous lesions of African KS is the same as for European classical KS. Children and young adults with lymphadenopathic and visceral KS require aggressive systemic chemotherapy (*Tables 1 and 2*).

Kaposi's sarcoma in immunosuppressed individuals

Non-AIDS-related KS can also occur among patients receiving immunosuppression therapy, such as renal transplant patients and patients receiving systemic steroids.¹⁰ Renal transplant patients have 400–500% greater incidence of KS than the general population. It has been estimated that Kaposi's sarcoma will develop in approximately 0.4% of all patients undergoing renal transplantation.⁷ So far, there have been no reports of liver and heart transplant patients with KS; however, as the number of these operations increases one may expect to see KS in these patients. Renal transplant patients who have KS are generally young, with an average age of 42, and a male to female ratio of 2.3:1.

KS in these immunosuppressed individuals frequently involves visceral noncutaneous sites. It often regresses after withdrawal of the immunosuppressive agent. However, prognosis may be poor and the mortality rate is 30%. The treatment must be individualized and risk of death from generalized KS must be balanced against the risk of death due to renal rejection or complications of renal failure if immunosuppressive therapy is stopped⁷ (*Tables 1 and 2*).

Kaposi's sarcoma in AIDS patients

AIDS-related KS has been reported among all groups at risk for AIDS, including children and hemophiliacs. However, it is seen most frequently among homosexual men.²

Clinically, in AIDS-related KS the cutaneous lesions occur more often on the upper half of the body, such as the tip of the nose or forehead, and on the mucous membranes, such as the hard palate.² Viscera, especially the gastrointestinal tract and lymph nodes, are also common sites of involvement.² The biological behavior differs considerably; it can be indolent or rapid and fulminant.² Spontaneous regression of KS tumors has been recently reported in 3.8% of patients

Table 3. Light-microscopy criteria for diagnosis of Kaposi's sarcoma

1. Intact epidermal layer
2. Proliferation of capillaries with atypical endothelial cells
3. Proliferation of spindle-shaped cells around capillaries
4. Inflammatory cell infiltrate
5. Extravasated erythrocytes and hemosiderin in spindle-cell-containing tissue

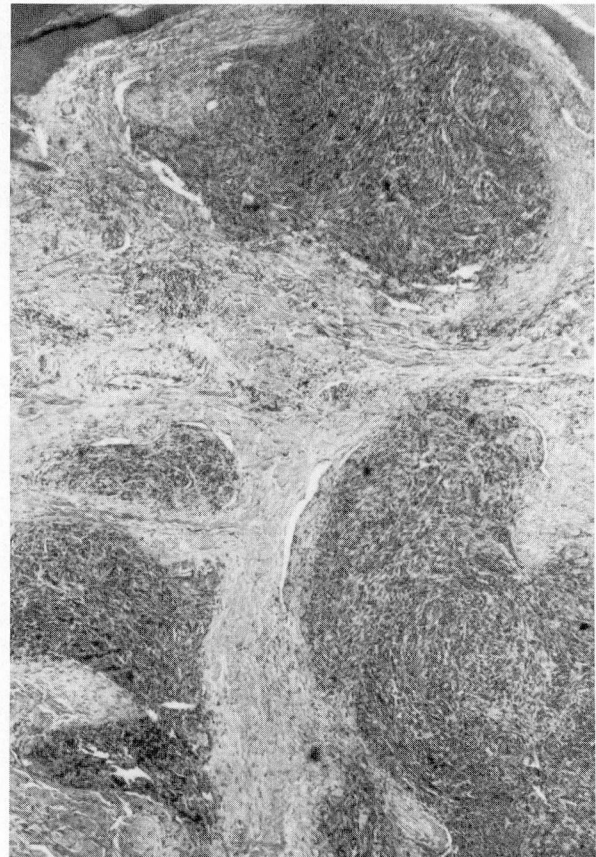


Fig. 1. Low-power magnification of Kaposi's sarcoma lesion. The epidermal layer is intact. The lesion is poorly circumscribed and is spreading into the surrounding tissue. ×200

with AIDS-related KS.¹¹ However, this regression is not necessarily accompanied by improvement in clinical status.

In AIDS-related KS chemotherapy is normally reserved for patients with life-threatening visceral involvement (*Tables 1 and 2*).

The KS lesions in patients with AIDS have generally been believed to be histopathologically identical to those in patients with non-AIDS KS when those lesions were evaluated by light and

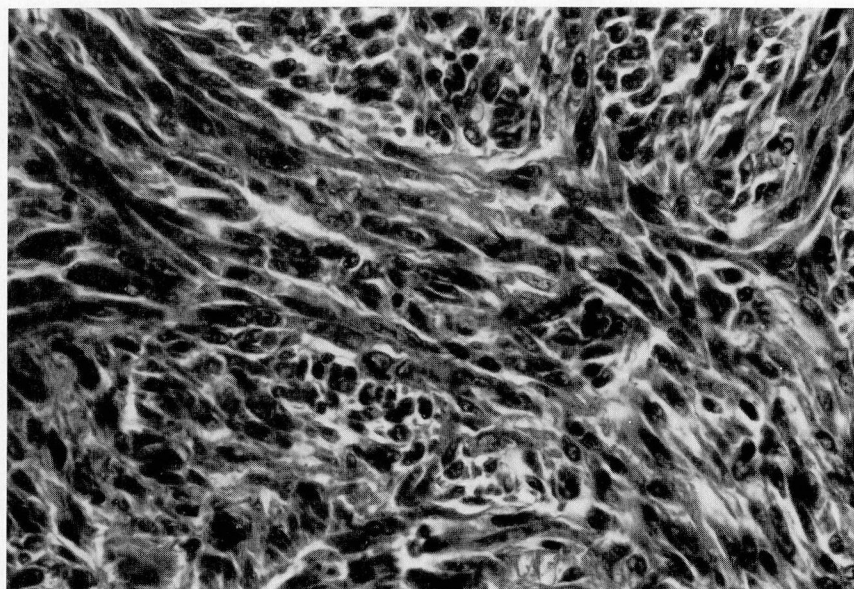


Fig. 2. High-power magnification of spindle-shaped cells. $\times 400$

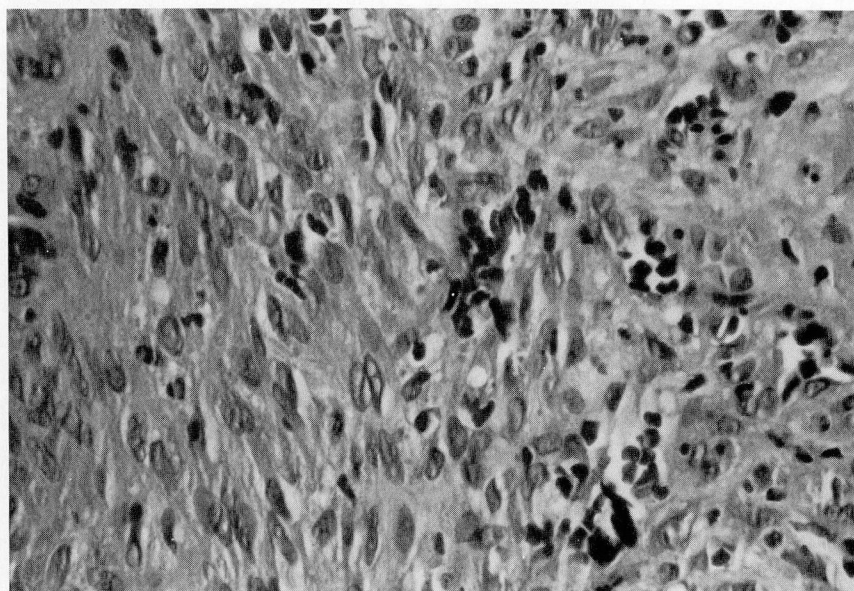


Fig. 3. High-power magnification of capillary proliferation with abnormal endothelial cells. Note extravasated erythrocytes between spindle cells. $\times 400$

electron microscopy.⁴ On light microscopy KS tumors are characterized by an intact epidermal layer; the lesions are sometimes circumscribed but never encapsulated, and frequently spread into the surrounding tissue. The tumor itself contains two components: proliferating capillaries with atypical plump polymorphous endothelial cells, and spindle-shaped cells that have elon-

gated blunt-ended nuclei and that surround the capillaries to form "stromal" tissue.⁴ The mitotic rate of both these tumor cell types is low. Inflammatory cell infiltrate is normally present and tissue with spindle-shaped cells often contains extravasated erythrocytes and deposits of hemosiderin. These criteria are summarized in *Table 3* (see also *Figs. 1–3*)

Recently, a group of Austrian researchers reported that on electron microscopic examination AIDS-related KS specimens have tubuloreticular structures (TRS), which are commonly present in a variety of autoimmune, viral, and neoplastic diseases, while non-AIDS-related KS specimens have no TRS.¹² A group of British pathologists claims that in their experience lymphangiomas changes seen on light microscopy and characterized by a network of proliferating angulated spaces are mostly found in AIDS-related KS.¹³

Conclusion

Increasing research on AIDS and the HIV retrovirus may help explain the etiology and pathophysiology of KS. Since at the moment it is nearly impossible to distinguish histopathologically between AIDS-related and non-AIDS-related KS, the authors of this paper believe that a patient with the diagnosis of KS should always be tested for AIDS whenever there is any doubt. However, the clinician should bear in mind that negative findings on the initial serologic test and confirmatory Western Blot test do not always exclude the diagnosis of AIDS.

Alexander Zemtsov, M.D.
Department of Dermatology
The Cleveland Clinic Foundation
9500 Euclid Avenue
Cleveland, Ohio 44106

References

1. Modlin RL, Crissey JT, Rea TH. Kaposi's sarcoma. *Int J Derm* 1983; **22**:443-448.
2. Safai B, Johnson KG, Myskowski PL, et al. The natural history of Kaposi's sarcoma in the acquired immunodeficiency syndrome. *Ann Int Med* 1985; **103**:744-750.
3. Center for Disease Control. Kaposi's sarcoma and Pneumocystis pneumonia among homosexual men—New York and California. *MMWR* 1981; **25**:305-308.
4. Leu HT, Odermatt B. Multicentric angiosarcoma (Kaposi's sarcoma). *Virchows Arch A* 1985; **408**:29-41.
5. DiGiovanna JJ, Safai B. Kaposi's sarcoma: retrospective study of 90 cases with particular emphasis on the familial occurrence, ethnic background and prevalence of other diseases. *Am J Med* 1981; **71**:779-783.
6. O'Brien PH, Brasfield RD. Kaposi's sarcoma. *Cancer* 1966; **19**:1497-1502.
7. Friedman-Kien AE, Laubenstein LJ. AIDS. New York, Masson Publishing USA, Inc., 1984, pp 23-45.
8. Slavin G, Cameron HMCD, Singh H. Kaposi's sarcoma in mainland Tanzania: a report of 117 cases. *Br J Cancer* 1969; **13**:349-357.
9. Slavin G, Cameron HMCD, Forbes C, Mitchell RM. Kaposi's sarcoma in East African children: a report of 51 cases. *J Pathol* 1970; **100**:187-199.
10. Klepp O, Dahl O, Stenwig JT. Association of Kaposi's sarcoma and prior immunosuppressive therapy: a 5-year material of Kaposi's sarcoma in Norway. *Cancer* 1978; **42**:2626-2630.
11. Real FX, Krown SE. Spontaneous regression of Kaposi's sarcoma in patients with AIDS. *NEJM* 1985; **313**:1659.
12. Konrad K, Schenk P, Rappersberger K. Tubuloreticular structures in Kaposi's sarcoma: a comparison of the classical and AIDS-associated forms. *Acta Derm Venereol (Stockh)* 1986; **66**:207-212.
13. Jones RR, Spaul J, Spry C, Jones EW. Histogenesis of Kaposi's sarcoma in patient with and without acquired immune deficiency syndrome (AIDS). *J Clin Pathol* 1986; **39**:742-749.