

Extracardiac mass causing cardiac tamponade in a patient with disseminated lymphoma¹

Freidoon Ghazi, M.D.
Donald A. Underwood, M.D.

The case of a young man with disseminated lymphocytic lymphoma, including involvement of the anterior mediastinum, resulting in compression of the heart and paradoxical pulse, is discussed. Echocardiography showed dynamic respiration-related changes in right ventricular and left ventricular filling and a retrosternal mass thought to be responsible for the clinical and echocardiographic abnormalities. Paradoxical pulse did not respond to thoracentesis, but resolved soon after the initiation of systemic chemotherapy and a reduction in the size of the anterior mediastinal mass. Causes of tamponade and echocardiographic signs of the process are reviewed.

Index terms: Cardiac tamponade • Case reports
Cleve Clin J Med 54:311–313, July/August 1987

Cardiac tamponade can be a life-threatening process. The usual cause is pericardial effusion, but it can result from cardiac compression due to an extracardiac mass in rare instances. Echocardiography is a useful tool for study of patients suspected of having this problem. The following case illustrates an example of cardiac compression due to an anterior mediastinal mass.

Case report

A 23-year-old white man was admitted to the hospital for therapy for a disseminated lymphoma. Eight weeks before admission, he noted right- and left-sided subcostal pleuritic

pain which resolved spontaneously. Three weeks later, a dry cough and shortness of breath developed which were unresponsive to therapy with antibiotics. His cough persisted and nodules developed on his abdomen, axilla, and head. He also noted swelling of his testicles. A biopsy specimen of one of the skin nodules revealed well-differentiated lymphocytic lymphoma. The patient had noted fever, sweats, and a reduced appetite. His weight, however, had been stable, and there were no difficulties with pruritis or rash. On examination at admission, he was uncomfortable and short of breath. The respiratory rate was 24. His blood pressure was 120/80 mm Hg, and there was a 22-mm paradoxical pulse. The pulse itself was 110 and regular. There were several 1–2-cm bilateral cervical lymph nodes in the anterior and posterior chains. Jugular venous elevation was not noted. The lungs had decreased sounds and dullness at both bases. There were normal first and second heart sounds, but no extra sounds or murmurs. The abdomen was soft and nontender, with the liver felt 8 cm below the costal margin and the spleen felt 6 cm below the left costal margin. Several 1–2-cm nodules were present on the abdominal wall. Both testicles were markedly swollen without tenderness.

On the day of admission, a thoracentesis was performed which normalized the respiratory status. The paradoxical pulse remained unchanged. A two-dimensional echocardiogram was obtained to exclude pericardial effusion causing tamponade. The valves were normal, as were the chambers. There was a minimal pericardial effusion and a large pleural effusion. There was increased density anterior to the heart. The septum showed downward motion during inspiration with reduction of the left ventricular dimensions (*Fig. 1*). The diagnosis of an extracardiac mass causing tamponade was suggested and the patient was started on chemotherapy. Symptoms improved during the gradual reduction in the size of the subcutaneous nodules. The paradoxical pulse gradually diminished to 10 mmHg over the next two weeks. Repeat two-dimensional echocardiography showed a significant reduction in the size of the anterior mediastinal mass lesion. The respiratory changes of the septum and compromise of the left ventricular cavity resolved (*Fig. 2*). He was admitted several more times for courses of chemotherapy. Additional or recurrent signs of the cardiac compression

¹ Department of Cardiology, The Cleveland Clinic Foundation. Submitted for publication June 1986; accepted Sept 1986.

0891-1150/87/04/0311/03/\$1.75/0

Copyright © 1987, The Cleveland Clinic Foundation

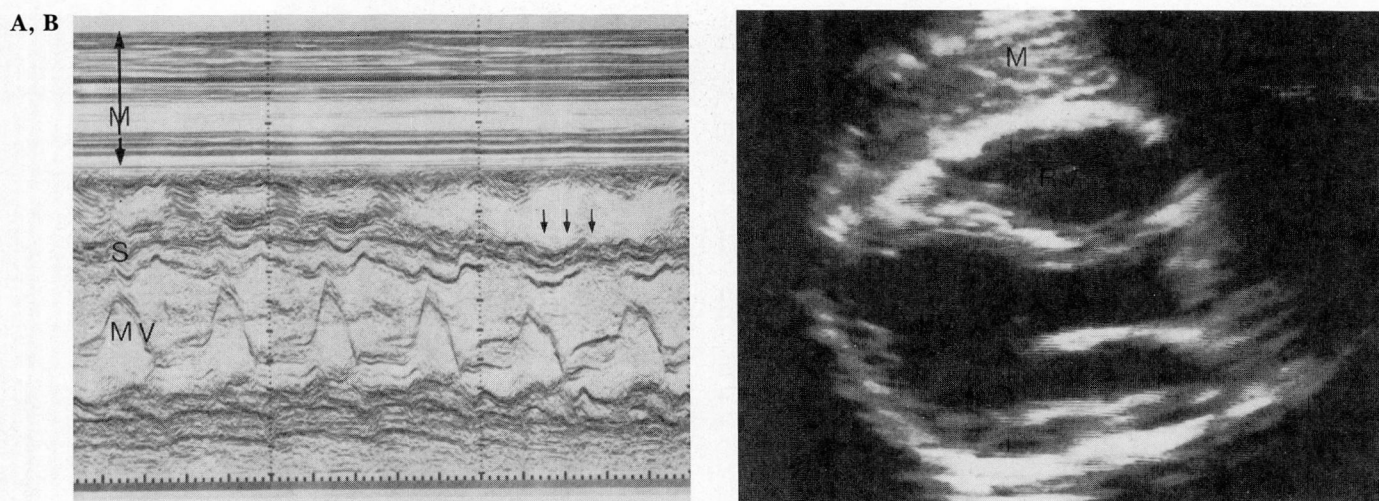


Fig. 1. A. M-mode echocardiogram at the level of the mitral valve obtained on admission. There is a tissue density anterior to the heart. Septum shows downward motion during inspiration, resulting in reduction of the left ventricular dimensions. *M* = mass and chest wall, *MV* = mitral valve, and *S* = septum.

B. Two-dimensional echocardiogram (left parasternal long-axis view). A tissue density is seen anterior to the heart. *M* = mass, *LV* = left ventricle, and *RV* = right ventricle.

did not develop, but he finally died of a disseminated lymphoma unresponsive to chemotherapy, severe leukopenia, and a terminal septic spell.

Discussion

"Pulses paradoxus" is an important clinical sign in cardiac tamponade.¹ It is defined as an inspiratory reduction in systolic blood pressure by 10 mmHg or more. Paradoxical pulse occurs in several other conditions including pulmonary embolization, chronic obstructive lung disease, and other forms of airway obstruction. Two mechanisms seem to be involved in the development of the sign. The first is a direct consequence of changes in pleural pressure associated with exaggerated breathing. The second is the result of the intimate relation between the two ventricular chambers such that altered filling of one influences the filling characteristics of the other. To varying degrees, these two mechanisms account for almost all forms of paradoxical pulse.

Echocardiographic findings in patients with paradoxical pulse, regardless of the etiology, are variable. Echocardiographic changes in tamponade have been outlined in a recent review on pericardial disease.² In one study done by Kronzon et al,³ eight patients without pericardial disease but with significant pulsus paradoxus were assessed echocardiographically. Findings included reduction in the left ventricular internal dimensions, left ventricular stroke volume, mitral

valve E to F slope, and mitral valve D to E excursion. Engel et al⁴ reported 21 patients who had cardiac tamponade secondary to pericardial effusion. Seventeen had a posterior motion of the right ventricular endocardium in early diastole. D'Cruz et al⁵ reported three cases of cardiac tamponade due to pericardial effusion. The echocardiographic findings included posterior diastolic movement of the anterior mitral leaflet during inspiration and decreased mitral E to F slope. The inspiratory alteration in mitral valve motion was accompanied by an increase in right ventricular dimensions and a reciprocal decrease in left ventricular dimensions. Echocardiography immediately after pericardiocentesis showed normalization of the E to F slope and that respiratory variations in the diastolic motion of the anterior mitral leaflet had resolved. Extracardiac masses are rare causes of tamponade without pericardial effusion. The pathology includes mediastinal cyst, thymomas, and a variety of pericardial tumors. These tumors can be either anterior or posterior to the heart.⁶⁻⁸

In the present case, the tumor was located in the retrosternal space, anterior to the heart. The echocardiogram obtained prior to chemotherapy showed a retrosternal tissue density with the septum encroaching on the left ventricular cavity during inspiration, causing a reduction in the left ventricular chamber size. This change persisted following successful thoracentesis, with an in-

creased sense of well being, a reduction in dyspnea, and reduction in respiratory rate. The second echocardiogram, which was obtained approximately two weeks after the initiation of chemotherapy, showed a reduction in the size of the retrosternal mass and clearing of the respiratory-related septal motion abnormalities. Echocardiography is a sensitive tool for identifying dynamic changes during compression of the heart. This case emphasizes the importance of echocardiography as a noninvasive modality for characterization of these patients and also the need to keep other than the usual causes of important clinical signs in mind when evaluating patients with acute distress of any type.

Donald A. Underwood, M.D.
Department of Cardiology
The Cleveland Clinic Foundation
9500 Euclid Avenue
Cleveland, OH 44106

References

1. McGregor M. Pulsus paradoxus. *N Engl J Med* 1979; **301**:480-482.
2. Spodick DH. The normal and diseased pericardium: current concepts of pericardial physiology, diagnosis and treatment. *J Am Coll Cardiol* 1983; **1**:240-251.
3. Kronzon I, Winer HE, Weiss EC, Berger AR. Echocardiographic observations of paradoxical pulse without pericardial disease. *Chest* 1980; **78**:474-479.
4. Engel PJ, Hon H, Fowler NO, Plummer S. Echocardiographic study of right ventricular wall motion in cardiac tamponade. *Am J Cardiol* 1982; **50**:1018-1021.
5. D'Cruz IA, Cohen HC, Prabhu R, Glick G. Diagnosis of cardiac tamponade by echocardiography: changes in mitral valve motion and ventricular dimensions, with special reference to paradoxical pulse. *Circulation* 1975; **52**:460-465.
6. Canedo MI, Otken L, Stefadouros MA. Echocardiographic features of cardiac compression by a thymoma simulating cardiac tamponade and obstruction of the superior vena cava. *Br Heart J* 1977; **39**:1038-1042.
7. Chandraratna PAN, Littman BB, Serafini A, Wayne T, Robinson H. Echocardiographic evaluation of extracardiac masses. *Br Heart J* 1978; **40**:741-749.
8. Farooki ZQ, Hakimi N, Arciniegas E, Green EW. Echocardiographic features in a case of intrapericardial teratoma. *J Clin Ultrasound* 1978; **6**:108-110.

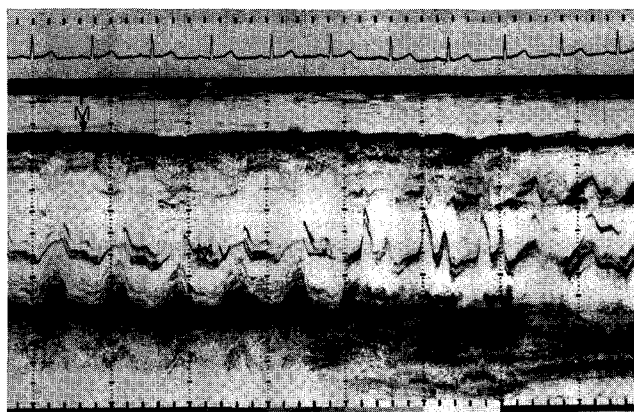


Fig. 2. Repeat M-mode echocardiogram two weeks after the initiation of systemic chemotherapy, showing a reduction in the size of the anterior mediastinal mass and disappearance of downward motion of the septum during inspiration. *M* = mass and chest wall, *MV* = mitral valve, and *S* = septum.