

# Primary malignant melanoma of the lower respiratory tract: endoscopic identification<sup>1</sup>

Stephen L. Demeter, M.D., F.A.C.A., F.A.C.P.<sup>2</sup>  
Charles Fuenning, M.D.<sup>3</sup>  
Joel B. Miller, M.D.<sup>4</sup>

**Primary malignant melanoma of the lower respiratory tract is a very rare disease (fewer than 15 reported cases). An autopsy-documented case is presented, along with a discussion of endoscopic and pathologic features.**

**Index terms:** Bronchoscopy • Lung neoplasms  
• Melanoma

**Cleve Clin J Med 54:305-308, July/Aug 1987**

Primary melanoma of the lower respiratory tract has been recognized in the medical literature since the first description by Todd in 1888.<sup>1</sup> That report and the reports that followed were poorly documented<sup>2-4</sup> until a case by Salm in 1963<sup>5</sup> that was well supported by microscopic findings. There have been several case reports

since then but only a few documented by autopsy.<sup>6-10</sup> A case is presented of malignant melanoma of the respiratory tract with no antemortem or postmortem evidence to indicate anything but a primary lesion. In addition, endoscopic findings are discussed.

## Case report

A 56-year-old man fell off a ladder. He presented to the emergency room with pain in his right side due to rib injury. His medical history was significant for intermittent hemoptysis associated with acute respiratory illnesses; the last episode had occurred approximately two years prior to admission. He had smoked three packs of cigarettes per day for 25 years but had stopped smoking 12 years prior to admission. His medical history included the removal of pilonidal cyst and hemorrhoids as a young man, essential hypertension, and adult-onset diabetes mellitus. He specifically denied removal of any skin or mucosal membrane lesions aside from the pilonidal cyst. Other than a sore chest, physical examination revealed only bilateral inguinal hernias. The initial laboratory examination showed a hemoglobin level of 12.0 g/dL with normal red cell indices and a white cell count of  $12.9 \times 10^3/\mu\text{L}$  with a slight left shift. The remainder of his screening laboratory examination was normal except for a urinary tract infection with *Escherichia coli*. A chest radiograph showed a 4-cm lobulated mass in the right hilar region (Fig. 1).

Bronchoscopy was performed. A black lesion filling the right upper lobe bronchus was identified (Fig. 2). The results of both brushing and biopsy were consistent with malignant melanoma. No complications were encountered and the tumor did not bleed easily.

A search for a primary lesion as well as the extent of the disease was undertaken. Dermatological and ophthalmological assessments were both negative. A CT scan of the

<sup>1</sup> Submitted for publication Sep 1986; accepted Jan 1987.

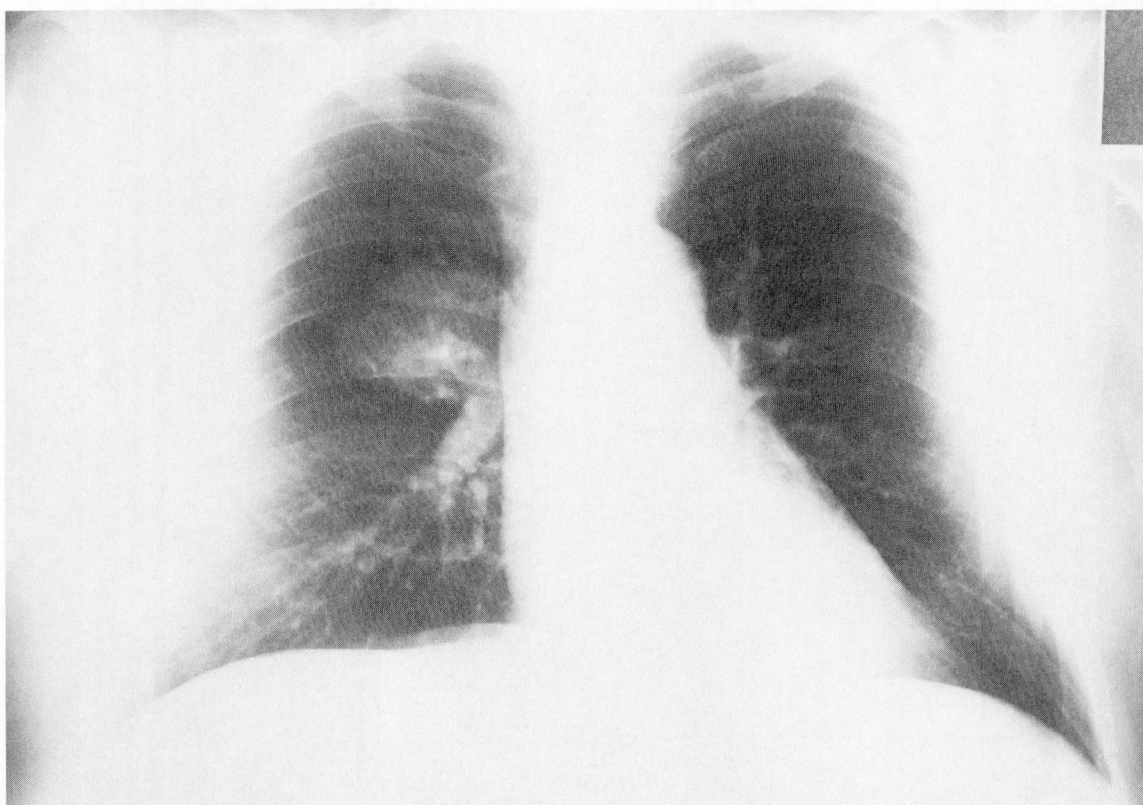<sup>2</sup> Associate Professor of Medicine and Head of Pulmonary Division, Northeastern Ohio Universities College of Medicine, and Akron General Hospital, Akron, Ohio. Former fellow, The Cleveland Clinic Foundation, Department of Pulmonary Disease.

<sup>3</sup> Assistant Professor of Medicine, Northeastern Ohio Universities College of Medicine, Head of Pulmonary Medicine, St. Thomas Hospital, Akron, Ohio.

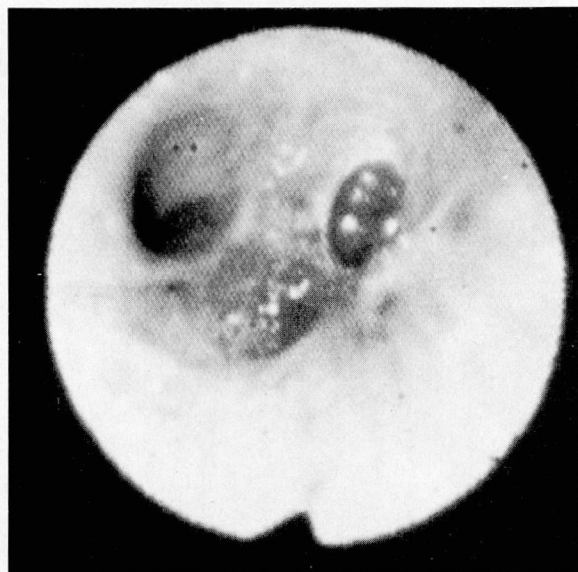<sup>4</sup> Associate Pathologist, Barberton Citizens Hospital, Barberton, Ohio, Assistant Professor of Pathology, Northeastern Ohio Universities College of Medicine, Rootstown, Ohio.

0891-1150/87/04/0305/04/\$2.00/0

Copyright © 1987, The Cleveland Clinic Foundation



**Fig. 1.** Chest radiograph showing a mass in the right hilar region.



**Fig. 2.** Bronchoscopic image showing lesion in the right upper lobe bronchus.

abdomen and pelvis was normal with the exception of a solitary gallstone. A bone scan showed increased uptake consistent with a degenerative joint disease. No other abnormalities were identified.

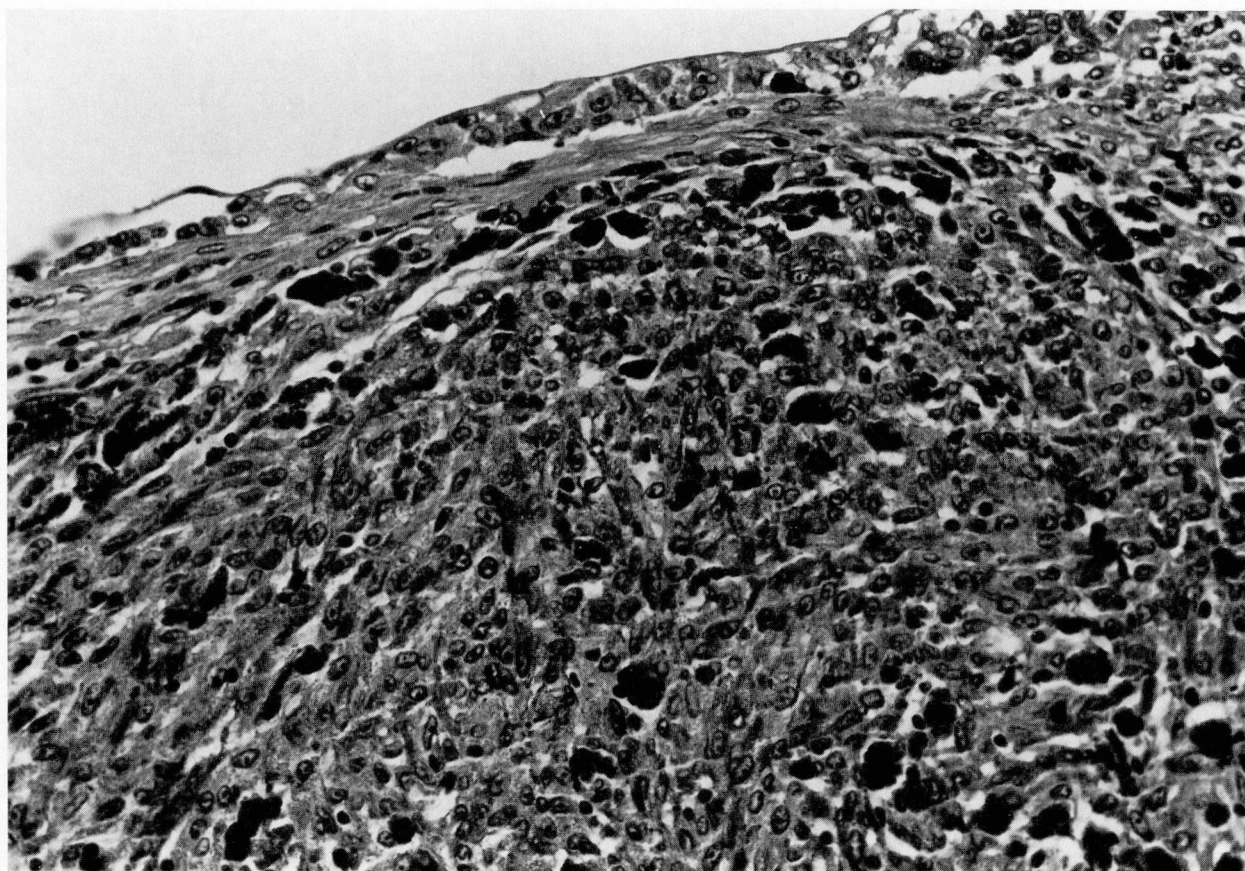
He subsequently underwent a right pneumonectomy. Mediastinal lymph nodes were positive for metastatic tumor. His postoperative course was uneventful with the exception of premature ventricular contractions, which prompted a transfer to the coronary care unit. After recovery from surgery, he received one dose of chemotherapy. Within one month he was readmitted and died soon thereafter. A metastatic focus was found in the interventricular cardiac septum; the cause of death was presumed to be a ventricular arrhythmia.

### Autopsy findings

A black mass, 4.1 cm at its greatest diameter, with extensions into the bronchial wall, was found upon opening the upper lobe bronchus of the right lung. The tumor cells were spindle-shaped to oval with hyperchromatic nuclei and prominent nucleoli (*Fig. 3*). Most of the cells contained brown granular pigment within their cytoplasm that stained positively with melanin stains (*Fig. 4*). The surrounding parenchyma revealed many pigment-laden macrophages. The mass was bounded on its surface by respiratory epithelium but no junctional activity was seen in the surrounding bronchial epithelium.

The only skin lesions noted at autopsy were





**Fig. 3.** Spindle-shaped to oval tumor cells with hyperchromatic nuclei and prominent nucleoli. (H & E stain)

several seborrheic keratoses over the chest, a squamous papilloma on the right side of the face, and scars consistent with the previous thoracotomy and chest tube insertion sites. Examination of all internal organs revealed only a metastatic focus in the intraventricular septum, and multiple microscopic foci in the left lung.

### Discussion

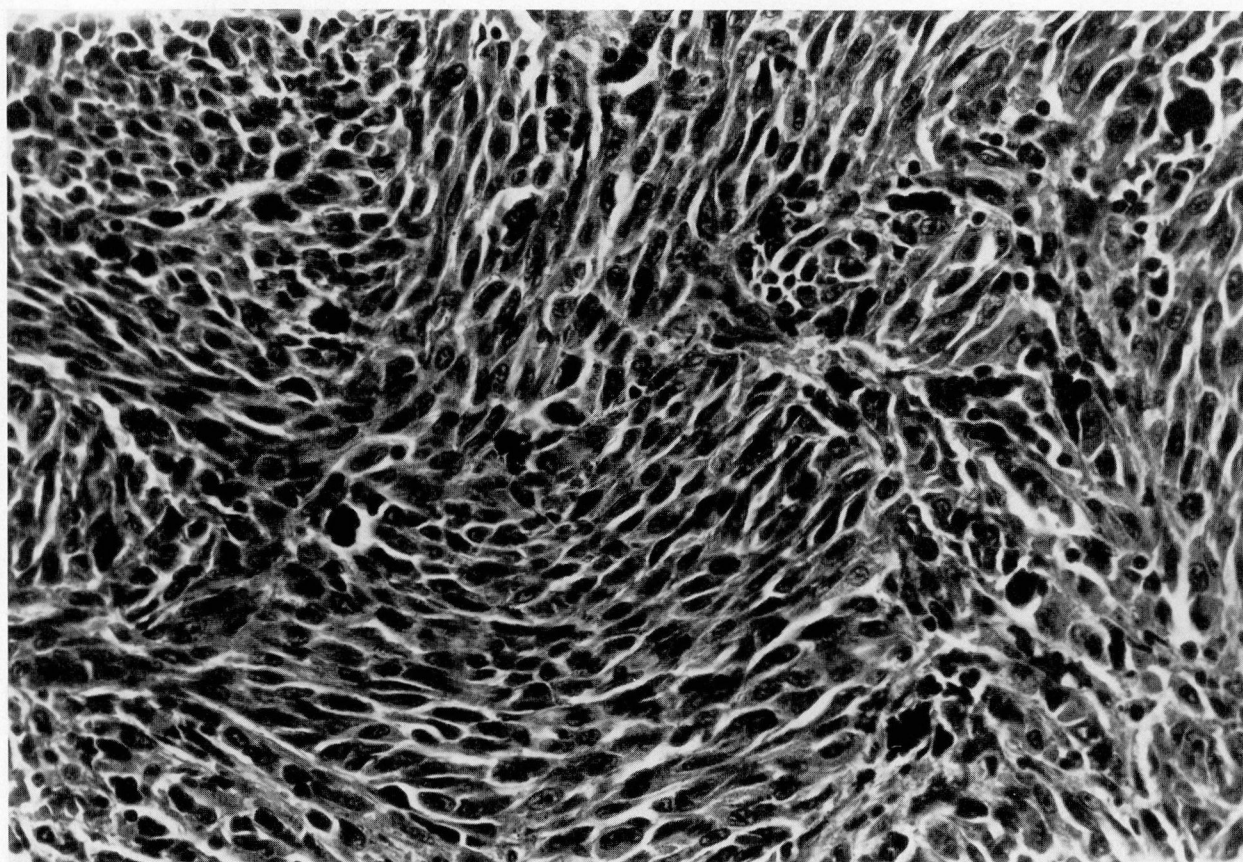
Criteria have been suggested for the diagnosis of primary versus metastatic melanocarcinoma. These include color, size, integrity of epidermis, the presence of junctional change in the surrounding epithelium, and the absence of other lesions. With respect to bronchial lesions, Jensen and Egedorf<sup>7</sup> thought primary occurrence required: no previously removed pigmented skin tumors, no ocular tumors, a solitary tumor in the surgical specimen, tumor pathology compatible with a primary tumor (i.e., considerable polymorphism would favor metastatic disease), and no demonstrable melanoma in other organs at the time of the operation or at autopsy. Allen

and Drash<sup>8</sup> furnished other criteria: junctional changes in the epithelium, invasion of the bronchial epithelium by the melanoma cells in an area where the bronchial epithelium is not ulcerated, and no obvious melanoma beneath these changes in the epithelium.

The case herein presented fulfills the above-mentioned criteria for a pulmonary lesion except for the presence of junctional change (the presence of melanocytes in the basal layer of the mucosal epithelium). This may represent a problem with sampling or it may mean that the junctional changes seen in other epithelial surfaces are not a consistent finding in bronchial lesions. The few documented cases do not represent a large enough case population to establish these concerns as definite criteria. Spontaneous regression of the primary tumor also occurs,<sup>11</sup> and obviously leaves the issue of primary lesion versus metastasis unsettled in cases of primary melanomas in unusual locations.

Melanoma of the bronchus, whether primary or secondary, is associated with other organ me-





**Fig. 4.** Cells containing brown granular pigment that stained with melanin stains. (Fontana-Masson stain for melanin, with bleach)

tastases and may lead to further problems, as it did in our patient. We did not find another primary source in our patient. The identification and biopsy of the tumor by flexible fiberoptic bronchoscopy presented no unusual problems. Caution has been expressed regarding the biopsy of some endobronchial tumors, especially bronchial carcinoids; however, no bleeding was encountered during the biopsy of this particular tumor. The patient had no adverse reactions to the procedure and cardiac monitoring revealed no arrhythmias. Likewise, no special problems were encountered during his perioperative course other than the presence of premature ventricular contractions, which were responsive to standard treatment and retrospectively were presumably due to myocardial metastasis.

Stephen L. Demeter, M.D.  
157 W. Cedar Street, Suite 209  
Akron, OH 44307

## References

1. Todd FW. Two cases of melanotic tumors in the lungs. *JAMA* 1888; **11**:53-54.
2. Kunkel OF, Torrey E. Report of a case of primary melanotic sarcoma of lung presenting difficulties in differentiating from tuberculosis. *New York State J Med* 1916; **16**:198-201.
3. Carlucci GA, Schleussner RC. Primary (?) melanoma of the lung: a case report. *J Thoracic Surg* 1942; **11**:643-649.
4. Allen AC, Spitz S. Malignant melanoma. *Cancer* 1953; **6**:1-45.
5. Salm R. A primary malignant melanoma of the bronchus. *J Path Bact* 1963; **85**:121-126.
6. Reid JD, Mehta VT. Melanoma of the lower respiratory tract. *Cancer* 1966; **19**:627-631.
7. Jensen OA, Egedorf J. Primary malignant melanoma of the lung. *Scand J Resp Dis* 1967; **48**:127-135.
8. Allen MS, Drash EC. Primary melanoma of the lung. *Cancer* 1968; **21**:154-159.
9. Robertson AJ, Sinclair DJM, Sutton PP, Guthrie W. Primary melanocarcinoma of the lower respiratory tract. *Thorax* 1980; **35**:158-159.
10. Cagle P, Mace ML, Judge DM, Teague RB, Wilson RK, Greenberg SD. Pulmonary melanoma: primary vs metastatic. *Chest* 1984; **85**:125-126.
11. Smith JL, Stehlin JS. Spontaneous regression of primary malignant melanomas with regional metastases. *Cancer* 1965; **18**:1399-1415.