

Carcinoid myopathy¹

Richard J. Lederman, M.D., Ph.D.
Ronald M. Bukowski, M.D.
Paul Nickerson, M.D.

Myopathy with malignant carcinoid syndrome appears to be rare. A 52-year-old woman with a 9-year history of carcinoid symptoms and biopsy-proven metastatic carcinoid of the liver is reported. After 6 months of chemotherapy, proximal weakness and atrophy with electromyographic and histological evidence of myopathy developed. Urinary 5-HIAA and plasma serotonin levels were markedly elevated. Charts of 44 patients with malignant carcinoid tumors were reviewed; six of these had symptoms of neuromuscular disease but only one had objective weakness. Five of six had moderate to marked elevation of blood serotonin; the sixth had no assay. Only one other patient had high serotonin levels but had no weakness. The findings support a pathogenetic role for circulating serotonin in this unusual myopathy, although the mechanism remains uncertain.

Index terms: Carcinoid tumor • Muscular diseases

Cleve Clin J Med 54:299-303, July/Aug 1987

Carcinoid tumors are uncommon, but not rare, neoplasms belonging to the neuroendocrine or APUD (amine precursor uptake and decarboxylation) group. The majority of carcinoid tumors arise in the gastrointestinal tract. They are usually small benign lesions found incidentally in the

appendix or rectum. Malignant carcinoid tumors cannot be differentiated histologically from benign lesions but are defined by the presence of local invasion or spread to regional or distant sites, most commonly the liver.

Approximately 10% of all patients with carcinoid tumors will exhibit symptoms of the carcinoid syndrome, consisting of episodic cutaneous flushing, diarrhea, right-sided valvular heart disease, and bronchospastic attacks. This syndrome almost always occurs in the presence of extensive hepatic metastases. It is generally attributed to tumor-produced serotonin gaining access to the circulation without passing through the liver, where it would ordinarily be detoxified. Circulating serotonin may be measured directly by assay of the blood or, more often, is noted by the presence of its breakdown product, 5-hydroxyindoleacetic acid (5-HIAA), in the urine.

While generalized weakness and cachexia can be seen in advanced cases of malignant carcinoid, true myopathy is rare. We present a patient with metastatic carcinoid tumor, the carcinoid syndrome, and severe myopathy. Further, we have identified, by retrospective chart review of 44 patients with malignant carcinoid tumors, six additional patients with symptoms suggestive of neuromuscular disease and we present evidence to support a pathogenetic role for serotonin in the myopathic syndrome.

Case report

A 52-year-old right-handed woman had a 9-year history of crampy abdominal pain and diarrhea, treated symptomatically with diphenoxylate with atropine and chlordiazepoxide with clidinium. For 2-3 years, diarrhea had been

¹ Departments of Neurology (R.J.L.), Hematology and Medical Oncology (R.M.B.), and Internal Medicine (P.N.), The Cleveland Clinic Foundation. Submitted for publication Nov 1986; accepted Jan 1987.

0891-1150/87/04/0299/05/\$2.25/0

Copyright © 1987, The Cleveland Clinic Foundation

present 5 days per week with up to five loose stools per day. A history of rare flushing episodes during the previous 3 years was later elicited. Evaluation at another institution had included a gastrointestinal series and endoscopy; this was unrevealing and she was treated with tincture of opium. In the previous 5 months there had been progressive swelling of the legs and abdomen.

Examination revealed jugular venous distension, hepatomegaly, and peripheral edema. On cardiac auscultation, holosystolic and diastolic murmurs were identified. Neuromuscular examination was normal.

Echocardiography showed tricuspid stenosis and insufficiency as well as right ventricular enlargement. Liver-spleen scanning and abdominal CT scanning revealed multiple defects in the liver. Percutaneous liver biopsy showed carcinoid tumor. The urinary 5-HIAA level was 306 $\mu\text{g}/\text{mg}$ creatinine (normal, $<10 \mu\text{g}/\text{mg}$), blood histamine level was 10.3 $\mu\text{g}/\text{dL}$ (normal, 3–9 $\mu\text{g}/\text{dL}$), and serotonin levels of 1,568 and 2,028 ng/mL were measured in consecutive blood samples (normal, 50–200 ng/mL).

The patient was treated with digoxin and diuretics. Cyproheptadine for diarrhea was poorly tolerated. Chemotherapy with 5-fluorouracil, streptozotocin, and cytoxan was administered. She improved symptomatically over the next several months but approximately 6 months later complained of rapidly progressing weakness, particularly of shoulder and pelvic girdle muscles. There was marked weight loss.

On examination at that time she had profound wasting, especially in the shoulder girdle muscles, and moderate to marked weakness that was worse proximally than distally. Bulbar muscles were spared and sensory examination was normal. The tendon reflexes were preserved.

The serum CPK level was 36 U/L (normal, 20–180 U/L). Thyroid function was normal. Urinary free cortisol and serum ACTH levels were normal. The urinary 5-HIAA level was 382 $\mu\text{g}/\text{mg}$ creatinine, blood histamine level was 3.8 $\mu\text{g}/\text{dL}$, and blood serotonin level was 1,916 ng/mL .

On electrodiagnostic study, sensory-nerve action potentials were of normal amplitude and conduction velocity was normal. Motor-nerve conduction studies, including median, ulnar, peroneal, and posterior tibial nerves, revealed low-amplitude responses with normal latency and conduction velocity. Needle electromyography showed prominent post-insertional myotonic and waning discharges. No spontaneous activity was noted. Motor unit potentials were of short duration and low amplitude; there was moderate to marked polyphasia, especially in the proximal muscles of the extremities, and this was more marked in the lower extremities.

Muscle biopsy from the right quadriceps showed variation in fiber size and normal position of the nuclei. There were no degenerating fibers and no signs of inflammation. There were multiple atrophic fibers, almost exclusively of type II. Several fibers contained round to irregular intracytoplasmic inclusions, 10–30 μm , devoid of enzymatic activity (Fig.). Endomysial and perivascular amyloid deposits were seen and were immunohistochemically identified as containing kappa light chains.

Patients with malignant carcinoid tumors

We identified 44 patients with malignant carcinoid tumors seen at the Cleveland Clinic Foundation between 1976 and 1984. The diagnosis

was made by liver biopsy in 27 patients and lymph node biopsy in 15 patients. Two patients were considered to have malignant carcinoid tumors on the basis of a primary tumor biopsy (1 ovary, 1 lung) plus CT or radionuclide scan evidence of distant metastases and elevated urinary 5-HIAA or blood serotonin levels. Of these 44 patients, 27 had elevated urinary 5-HIAA or blood serotonin or both. Twenty-two of these 27 had symptoms of carcinoid syndrome consisting of flushing and/or diarrhea. One had right-sided valvular heart lesions and one had wheezing. Five patients were asymptomatic despite the chemical abnormality. The remaining 17 patients had no symptoms of carcinoid syndrome and either had normal 5-HIAA levels (eight cases) or no assay was performed (nine cases). Only four of these 17 had evidence of hepatic metastasis.

Among these 44 patients with malignant carcinoid tumors, six had symptoms suggestive of muscle disease. These patients are further described in the *Table*. Four of the patients complained of weakness, either proximal or generalized, two of these noting particular difficulty in climbing stairs and one extreme fatigability of muscle. Three patients complained persistently of muscle cramps. Five of the six were females and all five had moderate to marked elevation of blood serotonin. The one male patient with both clinical and electrodiagnostic features of myopathy had a normal muscle biopsy result and three urine samples negative for 5-HIAA screening. No 24-hour urinary assay or blood serotonin testing had been performed, unfortunately.

Among the 44 patients, a total of 15 had at least one blood serotonin assay. Eleven of these 15 had symptoms of carcinoid syndrome and nine of the 15 had a moderate to marked elevation of serotonin, defined as $>400 \text{ ng}/\text{mL}$, on at least one occasion. Of these nine patients with elevated serotonin levels, only four had apparently no muscular complaints, at least as recorded in the chart. One of the four had serotonin levels of 292 and 404 ng/mL shortly after initiation of chemotherapy and three subsequent levels of 67, 90, and 45 ng/mL . Two of the others had little or no information recorded in their charts regarding neuromuscular status.

Discussion

In 1964, Green et al¹ described a 60-year-old woman with regionally metastatic carcinoid. She had clinical, electrodiagnostic, and histological evidence of “neuromyopathy.” Urinary 5-HIAA

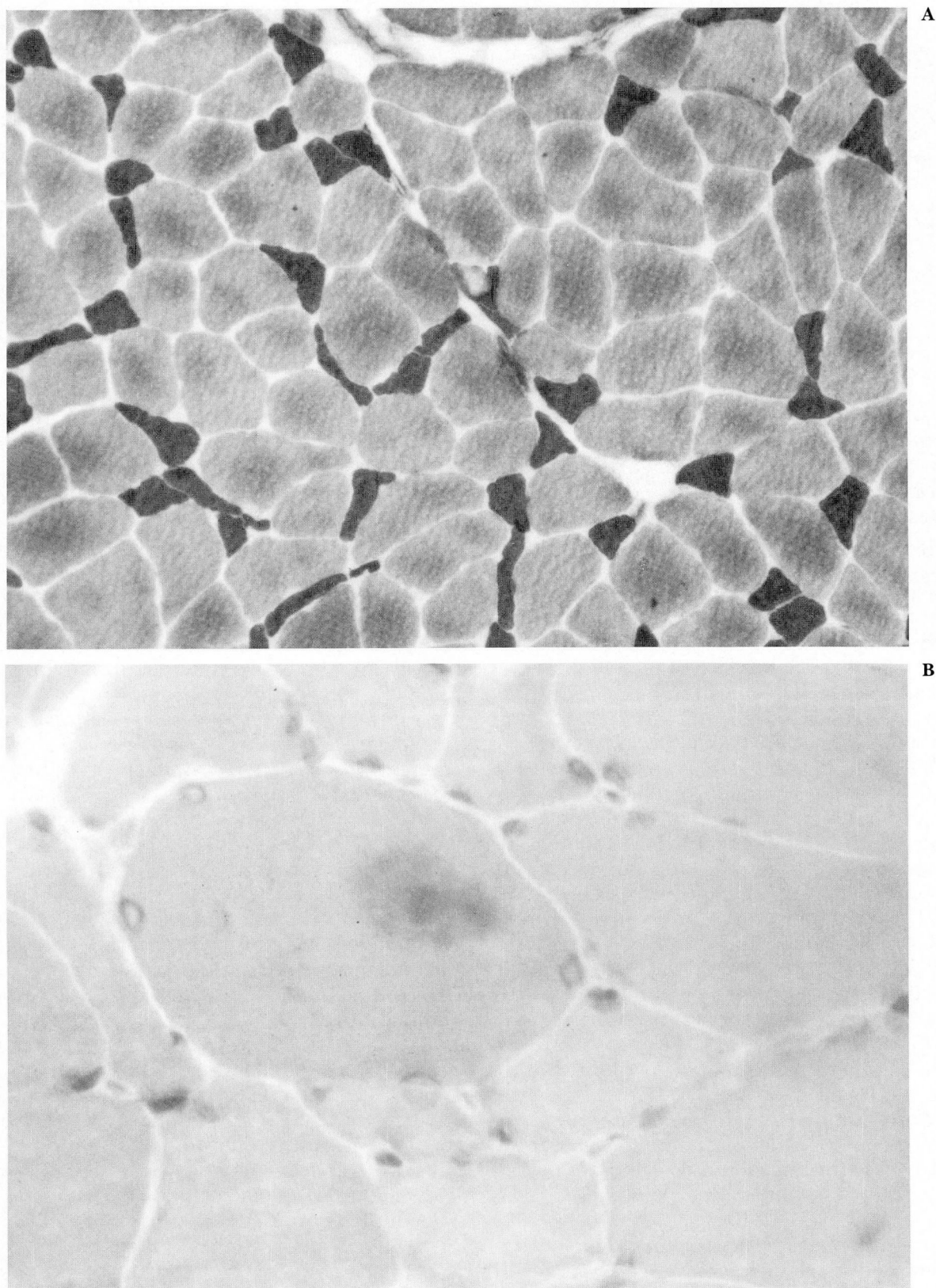


Figure. A. Myofibrillar ATP-ase stain showing type II fiber atrophy.
B. Gomori trichrome stain showing a cytoplasmic inclusion body.

Table. Patients with malignant carcinoid tumors and muscular symptoms

Sex	Age at onset of carcinoid (symptoms or diagnosis; yr)	Duration of carcinoid at onset of muscular symptoms (yr)	Total duration of illness (to last visit or death; yr)	Primary site	Carcinoid symptoms	Muscular symptoms or signs	Blood serotonin (range; ng/mL)
F	61	5	6	small intestine	+	proximal weakness	448–471
F	41	1	2	uncertain	+	weakness, extreme fatigability	108–578
F	62	1	3	lung	–	weakness, difficulty climbing stairs	269–919
F	54	1.5	4	small intestine	+	cramps, difficulty climbing stairs	1056–1400
F	55	8	15	small intestine	+	cramps, weakness	413–751
M	76	simultaneous	2	lung	–	weakness	not done

levels were reported as 2–5 times normal. They hypothesized a causative role for serotonin or its by-products in the development of this clinical syndrome. Ten years later, Berry et al² reported a 47-year-old woman with longstanding carcinoid syndrome and clinical as well as histological evidence of myopathy. Electromyography was reported to be normal. Urinary 5-HIAA and blood serotonin levels were markedly elevated. She improved symptomatically with cyproheptadine. These authors speculated that the myopathy was either a direct result of serotonin or was a “non-metastatic” complication of carcinoid tumor. Swash et al³ described a 41-year-old woman, again with longstanding carcinoid syndrome, and clinical, electromyographic, and histological evidence of myopathy. Urinary 5-HIAA was markedly elevated. A combination of cyproheptadine and methysergide apparently produced symptomatic improvement; these authors also suggested circulating serotonin as the cause of the myopathy. Recently, Patchell and Posner⁴ described a single patient with carcinoid myopathy among 219 patients treated for carcinoid tumors at the Memorial Sloan-Kettering Cancer Center from 1974 to 1984. This was a 49-year-old man with hepatic carcinoid metastasis of 37 months duration and urinary 5-HIAA levels twice normal. Electromyography showed a decreased interference pattern but short-duration low-amplitude polyphasic motor-unit potentials, and nerve conduction study showed mild slowing. Muscle biopsy revealed type II fiber atrophy as well as changes suggestive of neurogenic muscle atrophy. He appeared to improve symptomatically with cyproheptadine treatment.

Our patient had a malignant carcinoid tumor

with biopsy-proven hepatic metastasis and markedly elevated levels of blood serotonin on several occasions. Clinically she had profound myopathy and this diagnosis was further substantiated by typical electromyographic findings. Muscle biopsy showed some variation in fiber size and a moderate degree of type II fiber atrophy. The significance of the intracytoplasmic inclusions and the amyloid deposits is uncertain. By the time our patient was examined because of her myopathy, she was terminally ill. She had tolerated cyproheptadine poorly when it had been administered almost a year before in an attempt to control her diarrhea and she again became quite drowsy with small doses. No further treatment was attempted.

Muscle weakness with histological evidence of myopathy can be produced in rodents by intra-arterial infusion of serotonin⁵ or by intravenous or intraperitoneal injection, with or without the addition of a tricyclic antidepressant such as imipramine.^{6,7} Serotonin has been presumed to exert its damaging effect by producing localized ischemia within muscle. A direct toxic effect, however, cannot be excluded. Both Mendell et al⁶ and Munsat et al⁷ utilized repeated injection of serotonin to produce chronic muscle changes, consisting of degenerating and regenerating muscle fibers as well as variation in fiber size and central nucleation. In the rats studied by Munsat et al,⁷ fibers of high oxidative capacity (types I and II A) were preferentially affected. Mendell et al⁶ did not specify preferential involvement of any fiber type. They did note a striking proximal localization whereas Munsat et al⁷ found both distal and proximal muscles involved. In both models, the findings were interpreted as suggest-

ing an ischemic mechanism for the muscle injury. The relationship between these experimental preparations and the myopathy associated with malignant carcinoid syndrome is uncertain. Clearly there are substantial differences between the clinical and histologic pictures seen in the experimental animal model and the naturally occurring human disorder.

The circumstantial evidence we present, however, does suggest that serotonin may be a major factor in the clinical myopathy seen in patients. Of the six patients with malignant carcinoid tumors who were found to have complained of neuromuscular symptoms, five had moderate to marked elevation of blood serotonin and the sixth was not adequately tested, although urinary screening for 5-HIAA had been performed three times. It is well recognized that serotonin output may be paroxysmal and random samples of urine may not show elevation of the degradation product 5-HIAA. Five of the patients with symptoms suggestive of muscle disease were in the group of nine who had moderate to marked elevation of blood serotonin levels on at least one occasion. Similar complaints were not voiced by any of the six other patients who had normal or slightly elevated serotonin levels or among the group who had single or repeated quantitative or screening urine sample for 5-HIAA that were normal or only mildly elevated. While these findings cannot be considered conclusive, in view of the retrospective nature of the chart review we think that they provide suggestive evidence that symptoms of neuromuscular disease may be more prominent in those with high levels of circulating serotonin and hence suggest a role for serotonin in the pathogenesis of this unusual myopathy. Why the myopathy develops only after prolonged exposure to high levels of circulating serotonin is unclear. Perhaps the threshold for injury is high and the effects cumulative.

The findings also would suggest that myopathic symptoms may be more common than has been previously recognized. Patchell and Posner⁴ found only one patient with myopathy among 90 patients with malignant carcinoid tumors. Our identification of one documented patient with myopathy and six with suspicious symp-

toms among a group of 45 patients with malignant carcinoid tumors clearly suggests a much higher incidence, although actual evidence of myopathy was only seen in two of these cases overall. The association must therefore be proposed with appropriate reservation.

On the basis of our review, we recommend that patients with malignant carcinoid tumors be questioned specifically about muscle weakness and cramps. If suggestive symptoms are noted, these patients should be carefully evaluated clinically, electromyographically, and by muscle biopsy for evidence of myopathy. The disorder is at least potentially treatable with medication and the prolonged survival of some patients even with widespread metastases makes it even more desirable to identify those who might improve symptomatically.

Acknowledgment

The authors would like to thank Samuel M. Chou, M.D., Ph.D., Head, Section of Neuropathology, Department of Pathology for providing the photomicrographs.

Richard J. Lederman, M.D., Ph.D.
Department of Neurology
Cleveland Clinic Foundation
9500 Euclid Avenue
Cleveland, OH 44106

References

1. Green D, Joynt RJ, Van Allen MW. Neuromyopathy associated with a malignant carcinoid tumor: a case report. *Arch Int Med* 1964; **114**:494-496.
2. Berry EM, Maunder C, Wilson M. Carcinoid myopathy and treatment with cyproheptadine (Periactin). *Gut* 1974; **15**:34-38.
3. Swash M, Fox KP, Davidson AR. Carcinoid myopathy: serotonin-induced muscle weakness in man? *Arch Neurol* 1975; **32**:572-574.
4. Patchell RA, Posner JB. Neurologic complications of carcinoid. *Neurology (Cleve)* 1986; **36**:745-749.
5. Patten BM, Oliver KL, Engel WK. Serotonin-induced muscle weakness. *Arch Neurol* 1974; **31**:347-349.
6. Mendell JR, Silverman LM, Verrill HL, Parker JM, Olson WH. Imipramine-serotonin induced myopathy. *Neurology (Minneap)* 1976; **26**:968-974.
7. Munsat TL, Hudgson P, Johnson MA. Experimental serotonin myopathy. *Neurology (Minneap)* 1977; **27**:772-782.