

# Partial pancreas divisum<sup>1</sup>

Douglas C. Wolf, M.D.<sup>2</sup>  
Michael V. Sivak, Jr., M.D.

**Pancreas divisum is a well known condition that results when the embryologic dorsal and ventral pancreatic buds fail to fuse. An association between pancreas divisum and acute recurrent pancreatitis has been suggested. The authors report the radiographic finding of partial pancreas divisum in which a rudimentary connection persists between the ventral and dorsal portions of the pancreatic ductal system. Its clinical significance is uncertain but may be similar to that of pancreas divisum proper.**

**Index terms:** Abnormalities • Pancreatic ducts

**Cleve Clin J Med 54:33-37, Jan/Feb 1987**

Anatomic variations of the pancreatic ducts have been recognized since the ducts of Wirsung and Santorini were identified in the 17th and 18th centuries. Meckel was among the first to recognize the aberrant embryologic events responsible for ductal anomalies, and since then many variations have been described, the prototype being pancreas divisum.<sup>1-4</sup>

Pancreas divisum results when the embryologic dorsal and ventral pancreatic buds fail to fuse. This normally occurs at about 8 weeks gestation. As a result, the duct of Wirsung drains a small portion of the pancreatic head through the major papilla, and the duct of Santorini drains the greater portion of the pancreatic parenchyma through the minor papilla.<sup>5</sup> Although data are somewhat equivocal,<sup>6</sup> some reports suggest that pancreas divisum is not simply an anatomic peculiarity but a clinicopathological entity.<sup>5,7-9</sup> Pancreas divisum has been associated with acute

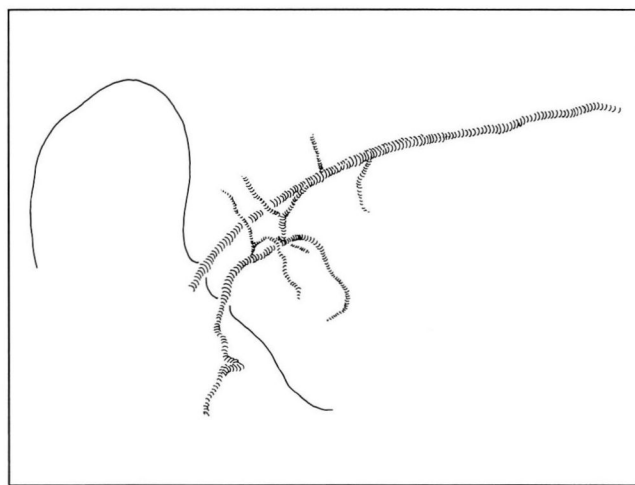
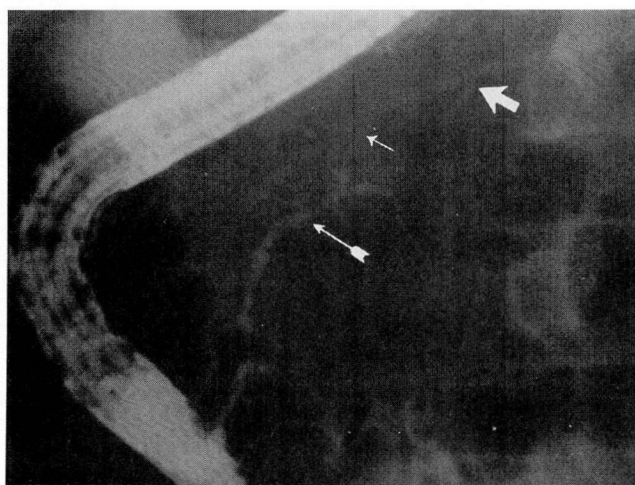
<sup>1</sup> Section of Gastrointestinal Endoscopy, Department of Gastroenterology, The Cleveland Clinic Foundation. Submitted Jan 1986; accepted Sept 1986.

<sup>2</sup> Present address: The Emory Clinic, 1365 Clifton Road, N.E., Atlanta, GA 30322. pa

0891-1150/87/01/0033/05/\$2.25/0

Copyright © 1987, The Cleveland Clinic Foundation

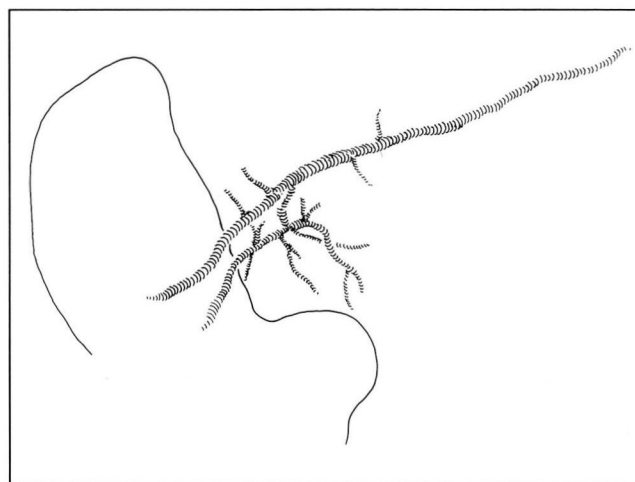
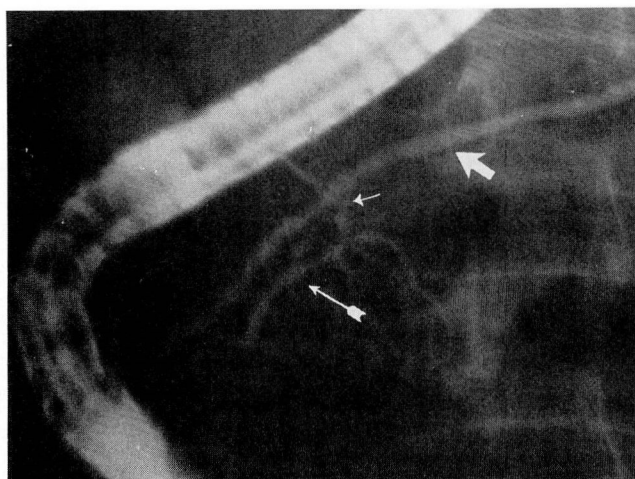
A, B



**Fig. 1. A.** ERCP in case 1. Note filling of the ventral (arrow with tail) and dorsal (wide arrow) portions of the pancreatic duct with only a faint connection (thin arrow) between them.

**B.** Line drawing of pancreatogram.

A, B



**Fig. 2. A.** ERCP in case 1. With greater filling pressure, note complete filling of connecting segment (thin arrow) and dorsal ductal system (wide arrow).

**B.** Line drawing of pancreatogram.

recurrent pancreatitis in at least two reports in which the anomaly was identified by endoscopic retrograde pancreatography.<sup>7,9</sup>

This report discusses two cases in which only a rudimentary ductular connection occurred between the ventral and dorsal embryologic portions of the pancreas, a state that we term *partial pancreas divisum* in the adult gland. The two patients presented with upper abdominal pain, and laboratory test results suggested pancreatic or biliary disease.

## Case reports

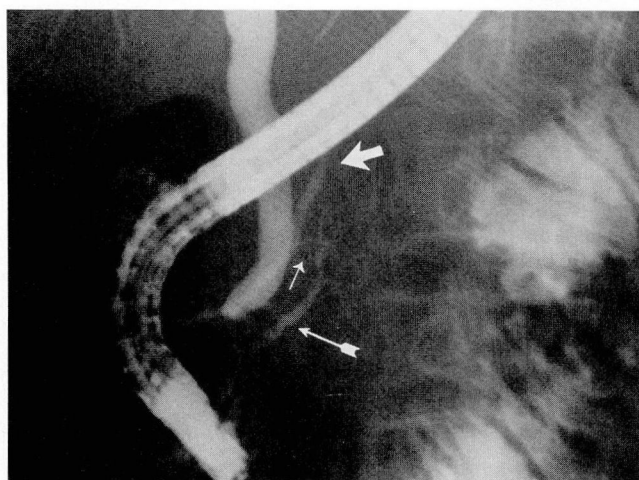
### Patient 1

A 49-year-old man with a history of ischemic cardiomyopathy and congestive heart failure had upper abdominal

pain of several weeks duration. Auscultation of the heart and lungs revealed an S-3 and S-4 gallop rhythm and bibasilar rales. The abdomen was normal. Biochemical determinations included a serum bilirubin level of 7.2 mg/dL (normal, 0.2–1.0 mg/dL), alkaline phosphatase level of 254 u/L (normal, 20–210 u/L), and SGOT level of 196 units (normal 7–40 units). The serum amylase level was normal.

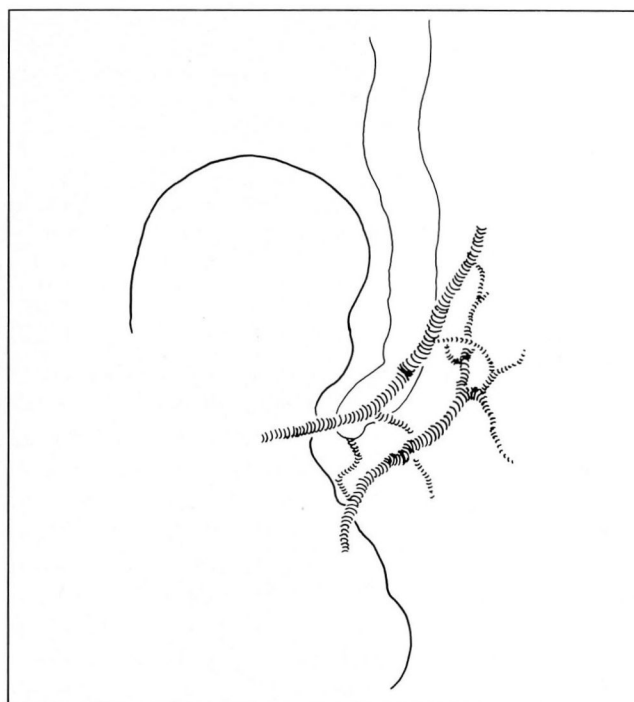
The possibility of biliary obstruction was raised, and ultrasonography revealed a contracted gallbladder containing calculi. The common hepatic and intrahepatic ducts were normal in caliber. Intraductal calculi were not defined. Therefore, endoscopic retrograde cholangiopancreatography (ERCP) was performed to exclude choledocholithiasis, with endoscopic sphincterotomy and possible extraction of bile duct stones as a contingency. Calculi were not demonstrated in the bile duct, which was also normal in diameter. When the pancreatic duct was selectively cannulated and injected with contrast medium, it initially appeared that there was a short ventral ductal system and that the patient



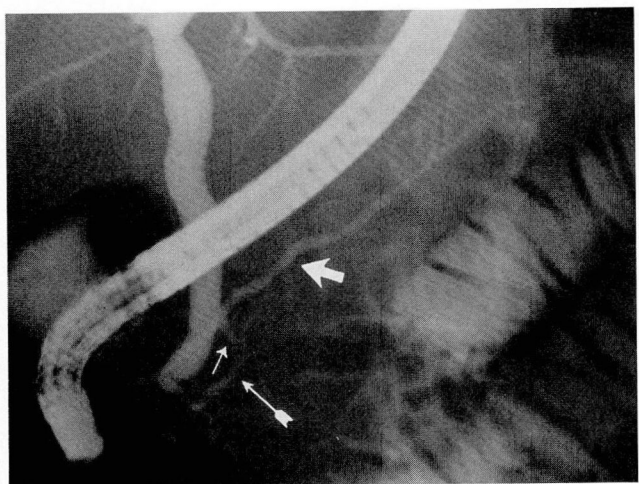


**Fig. 3. A.** ERCP in case 2. Note narrow-diameter connecting segment (thin arrow) between the ventral (arrow with tail) and dorsal (wide arrow) portions of the pancreatic ductal system.

**B.** Line drawing of pancreatogram.

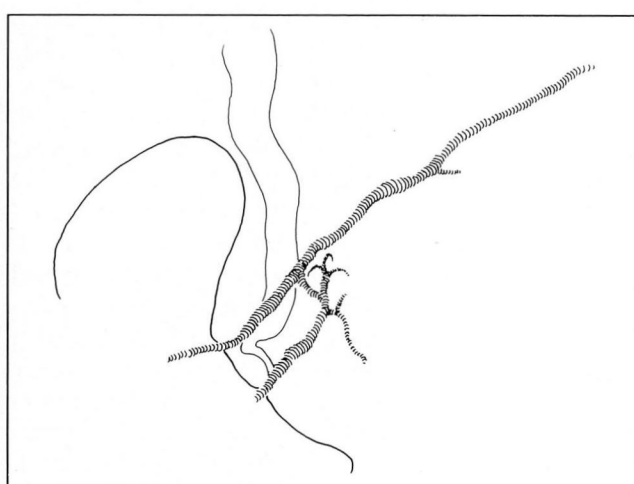


**A, B**



**Fig. 4. A.** ERCP in case 2. With increased filling pressure, widening of the connecting segment (thin arrow) occurs, and there is increased filling of the dorsal duct (wide arrow).

**B.** Line drawing of pancreatogram.



**A, B**

had pancreas divisum. As the injection was continued, the dorsal ductal system became faintly opaque (*Fig. 1*). The injection pressure was maintained for a few more seconds, which resulted in filling of a dorsal ductal system with a straight configuration and a maximum diameter greater than that of the duct in the ventrally derived portion of the gland (*Fig. 2*).

#### Patient 2

A 55-year-old woman, who had had a coronary artery bypass graft two years earlier, was referred because of progressive abdominal pain over the past three years localized to the right upper quadrant and midepigastic area. The pain worsened with eating. She noted a five-pound

weight loss over the past year. She had had a cholecystectomy 20 years earlier. Her abdomen was flat with a right upper-quadrant scar, normal bowel sound, and epigastric and right upper-quadrant tenderness. Routine laboratory screening revealed slightly elevated cholesterol and glucose levels. A complete blood count was normal. The serum amylase level was 147 units/L, the upper limit of normal being 135 units/L.

Further evaluation included esophagogastroduodenoscopy and ultrasonography of the pancreas and biliary tract, both of which were normal. Retrograde cholangiography disclosed no abnormalities. Initially, opacification of the pancreatic duct demonstrated a short, tapering duct with a normal branching pattern, which was thought to be consist-

ent with the ventral portion of a pancreas divisum. Further injection of a small amount of contrast medium revealed a narrow, filamentous ductular connection between this duct and a straight, normal-caliber dorsal duct (Fig. 3). Injection of additional contrast medium widened the short connecting segment and satisfactorily filled the dorsal pancreatic ductal segment (Fig. 4). During the injection the patient noted abdominal pain, which was the same pain she described in the history. This disappeared over a period of about 10 hours.

## Discussion

ERCP has led to a greater awareness and recognition of anatomic abnormalities of the pancreatic ductal system. The incidence of pancreas divisum is estimated at 3.6–5%.<sup>5,7</sup> Pancreas divisum is said to be associated with symptoms in a number of reports, most commonly those of recurrent pancreatitis. Cotton found that, among 78 patients with unexplained recurrent pancreatitis, 25.6% had pancreas divisum.<sup>7</sup> Sahel et al found acute pancreatitis to be significantly more frequent among patients with pancreas divisum (8 of 41 cases, 19.5%) than in those with normal ductal anatomy (31 of 771 cases, 4%).<sup>5</sup> Although Mitchell et al state that pancreas divisum does not predispose the patient to pancreatitis, they found pancreatitis in 19% of patients with pancreas divisum and abdominal pain.<sup>10</sup> However, there was also an unusually high incidence of pancreatitis (27.1%) in patients with normal ductal anatomy and abdominal pain.<sup>10</sup>

Partial pancreas divisum is a rarely described condition in which the dorsal and ventral pancreatic ducts are incompletely fused.<sup>10</sup> Belber and Bill noted that, on occasion, the two ducts may be nearly separate except for a trivial connection.<sup>12</sup> Taken separately, the two ductal systems in partial pancreas divisum have the same roentgenographic appearance as the separate ductal systems found with pancreas divisum proper; i.e., the dorsal system is rather long and straight and has a normal diameter, including that portion nearest the duodenum, which would ordinarily comprise the accessory pancreatic duct. The ventral system consists of a short duct, often of smaller-than-usual diameter, which tapers rapidly upstream from the papilla of Vater and has a normal branching pattern. With partial pancreas divisum, these two systems are joined by a rudimentary, short, narrow-diameter ductular segment. Whether this connecting segment is functional under normal circumstances is problematic. For practical purposes patients might be considered as having pancreas divisum, that is to

say, no functional connection between the dorsal and ventral ducts. This seems to be supported by the manner in which the dorsal duct filled when contrast medium was injected via the ventral duct. This was especially so in the second patient, where the diameter of the connecting segment actually seemed to increase as additional contrast medium was injected.

The exact significance of partial pancreas divisum will be difficult to establish, given the apparent rarity of this condition. The existence of this anomaly makes it somewhat more difficult to correctly terminate an injection of a ventral duct in pancreas divisum proper since further filling via the connecting segment may be possible, albeit very rare. Note that in the second patient abdominal pain developed after the procedure, but procedure-related pancreatitis did not. However, the additional injection pressure required to fill the dorsal duct via the connecting segment seems to be trivial. In fact, the additional pressure was slight and was applied to ensure the contrast medium reached the terminal portion of the ventral duct, pancreas divisum, or another suspected ductal abnormality. The short connecting segment may also be misinterpreted roentgenographically as a short stricture, and consequently a misdiagnosis of tumor or other pathologic process may occur.

It is interesting to speculate on the relationship between partial pancreas divisum and pancreas divisum proper. It would seem that the partial anomaly may have the same significance as pancreas divisum proper, i.e., that it may be associated with abdominal pain and recurrent acute pancreatitis. Although both patients complained of abdominal pain, there was no strong history of pancreatitis in either case. It is also a theoretic possibility that in pancreas divisum proper a vestigial connection exists between the two ductal systems that in some cases may be “opened” during ERCP, perhaps by the intraductal pressure produced by retrograde injection.

In summary, we describe a variant of the pancreatic ductal anatomy, which we term *partial pancreas divisum*. This threadlike, narrow-caliber connection between the two ductal systems may not be immediately opacified as contrast medium is injected via the major papilla. Indeed, the connecting ductule may be vestigial, with its patency only established by the pressure generated during retrograde injection. The anomaly may be overlooked or the pancreatographic appearance misinterpreted if one is unaware of its exist-

ence. Its clinical significance is uncertain, but may be similar to that of pancreas divisum.

Michael V. Sivak, Jr. M.D.  
Department of Gastroenterology  
The Cleveland Clinic Foundation  
9500 Euclid Avenue  
Cleveland, OH 44106

## References

1. Berman LG, Prior JT, Abramow SM, Ziegler DD. A study of the pancreatic duct system in man by use of vinyl acetate casts of postmortem preparations. *Surg Gynecol Obstet* 1960; **110**:391-403.
2. Kleitsch WP. Anatomy of the pancreas: study with special reference to duct system. *Arch Surg* 1955; **71**:795-802.
3. MacCarty RL, Stephens DH, Brown AL, Carlson HC. Retrograde pancreatography in autopsy specimens. *Am J Roentgenol Rad Ther Nuc Med* 1975; **123**:359-366.
4. Rienhoff WF, Pickrell KL. Pancreatitis—An anatomic study of the pancreatic and extrahepatic biliary systems. *Arch Surg* 1945; **51**:205-219.
5. Sahel J, Cros RC, Bourry J, Sarles H. Clinico-pathological conditions associated with pancreas divisum. *Digestion* 1982; **23**:1-8.
6. Delhaye M, Engelholm L, Cremer M. Pancreas divisum: congenital anatomic variant or anomaly? Contribution of endoscopic retrograde dorsal pancreatography. *Gastroenterology* 1985; **89**:951-958.
7. Cotton PB. Congenital anomaly of pancreas divisum as a cause of obstructive pain and pancreatitis. *Gut* 1980; **21**:105-114.
8. Mairose UB, Wurbs D, Classen M. Santorini's duct—an insignificant variant from normal or an important overflow valve? *Endoscopy* 1978; **10**:24-29.
9. Richter JM, Schapiro RH, Mulley AG, Warshaw AL. Association of pancreas divisum and pancreatitis, and its treatment by sphincteroplasty of the accessory ampulla. *Gastroenterology* 1981; **81**:1104-1110.
10. Mitchell CJ, Lintott DJ, Ruddell WSJ, Losowsky MS, Axon ATR. Clinical relevance of an unfused pancreatic duct system. *Gut* 1979; **20**:1066-1071.
11. Warshaw AL, Richter JM, Schapiro RH. The cause and treatment of pancreatitis associated with pancreas divisum. *Ann Surg* 1983; **198**:443-452.
12. Belber JP, Bill K. Fusion anomalies of the pancreatic ductal system: differentiation from pathologic states. *Radiology* 1977; **122**:637-642.