

# The sensitivity and specificity of monoclonal antibodies URO-2 and 19-9 in the immunohistochemical classification of primary adenocarcinomas<sup>1</sup>

Daniel D. Sedmak, M.D.  
Raymond R. Tubbs, D.O.

The specificity and sensitivity of commercially available monoclonal antibodies (McAb) to tumor antigens were tested using McAb 19-9, derived from a colorectal adenocarcinoma, and URO-2, derived from a renal adenocarcinoma. Using the avidin-biotin-complex technique and frozen tissue, 53 adenocarcinomas representing lung, breast, colorectal, ovarian, renal, and uterine origin were studied. All slides were randomized and subsequently evaluated for staining intensity and percent tumor-area positivity. The sensitivity and specificity of 19-9 for colorectal adenocarcinoma were 74% and 54%, respectively. The sensitivity and specificity of URO-2 for renal adenocarcinoma were 100% and 87.5%, respectively. In most cases, URO-2 stained greater than 75% of the renal tumor area; however, 19-9 stained less than 50% of the colorectal tumor area.

**Index terms:** Adenocarcinoma, classification • Antibodies, monoclonal

**Cleve Clin Q** 53:277-282, Fall 1986

<sup>1</sup> Department of Pathology, Ohio State University College of Medicine (D.D.S.) and The Cleveland Clinic Foundation (R.R.T.). Submitted for publication Nov 1985; accepted Feb 1986.

0009-8787/86/03/0277/06/\$2.50/0

Copyright © 1986, The Cleveland Clinic Foundation

Surgical pathologists have long used histochemical stains, such as the periodic acid Schiff and colloidal iron stains, for the diagnosis and classification of neoplasms. Use of special stains has evolved to include immunohistochemical procedures to detect tumor antigens. These tumor-associated antigens vary greatly in their biochemical and functional characteristics; they range from cytoskeletal elements, such as keratin, to alpha-fetoprotein, an oncofetal antigen.<sup>1</sup>

In 1975, Köhler and Milstein<sup>2</sup> reported the development of mouse hybridomas capable of secreting monoclonal antibodies (McAb) of defined specificity. Since then, a large number of McAbs to tumor-specific antigens has been reported.<sup>3</sup> Although most have subsequently proved to be oncofetal or tissue-specific antigens, they may nonetheless be valuable in defining the histogenesis of a carcinoma.<sup>4</sup>

Two commercially available tumor-specific McAbs developed as a result of hybridoma technology are URO-2 and 19-9. URO-2 is McAb specific for the glomerular and proximal tubular epithelium of the kidney and appears to be relatively specific for carcinomas of renal origin.<sup>5</sup> A McAb generated from immunization of mice with human colorectal carcinoma cells, 19-9 was initially reported to be specific for gastrointestinal adenocarcinomas.<sup>6</sup>

It is the purpose of this study to compare and evaluate, in a retrospective and randomized manner, the specificity and sensitivity of URO-2 and 19-9 for renal and gastrointestinal adenocarcinomas, respectively.

## Materials and methods

### *Specimens*

Fifty-three cases of adenocarcinoma were retrieved from the frozen tumor bank of The Cleveland Clinic Foundation. These adenocarcinomas were of the lung (8), breast (9), colon (12), ovary (7), endometrium (9), and kidney (8). The presence of tumor in each frozen block was confirmed by hematoxylin and eosin-stained, 4- $\mu$  sections. All tumors had initially been snap frozen in isopentane in liquid nitrogen and stored at  $-70^{\circ}\text{C}$ . The length of storage did not exceed 17 months.

### *Antibodies*

All antibodies were obtained from commercial sources and included URO-2 (Ortho Diagnostic Systems; Cambridge, Mass.) and 19-9 (Centacor; Malverne, Pa.).

### *Immunoperoxidase procedure*

The immunoperoxidase assay was performed by the avidin-biotin-complex method of Hsu et al.<sup>7</sup> Four-micron sections were cut in a cryostat and air dried onto glass slides. Primary antibodies were used at a dilution previously determined to give maximal specific staining intensity with minimal background staining. Sections were incu-

bated with primary antibody, washed in modified phosphate-buffered saline, and incubated with biotinylated, affinity-purified, horse anti-mouse IgG (Vector Laboratories; Burlingame, Calif.). Sections were rewashed and incubated with a preformed avidin-DH/biotinylated peroxidase complex (Vector Laboratories). The color reaction was developed with 3-amino-9-ethylcarbazole and hydrogen peroxide in 0.02 M acetate buffer, counterstained with Mayer's hematoxylin, and mounted with aquamount (Lerner Laboratories; New Haven, Conn.). Immunoreactive tissue was red-brown against a blue background.

Known 19-9 and URO-2 positive colon and renal adenocarcinomas, respectively, served as positive controls. A negative control was included on all 53 adenocarcinomas by substituting the primary antibody with an equivalently diluted IgG containing mouse ascitic fluid.

### *Slide scoring system*

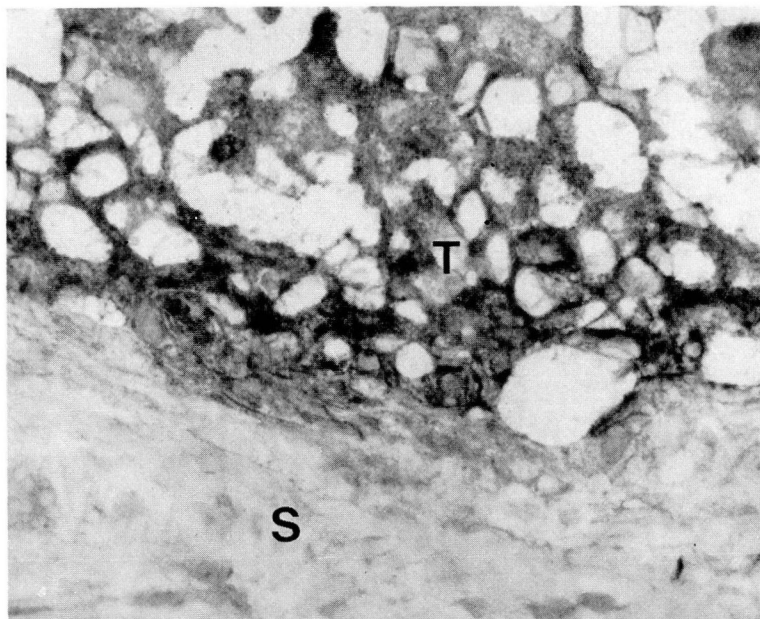
All 159 slides were labeled and paired with a random number by an independent third party who had no knowledge of either the primary antibody or tumor diagnosis. The random number code was not broken until all slides had been scored independently by two pathologists. Each slide was assessed for presence or absence of neoplastic cell staining and percent of neoplastic tissue staining. Staining was graded on a 0-2+ scale with 0 representing no staining and 2+ intense tumor staining. Tumors were divided into four subgroups according to percent of neoplastic tissue staining. Those tumors in which less than or equal to 25% of the neoplastic cells stained were given the score of 1, those with between 26%-50% positivity were given the score of 2, those with 51%-75% staining were given the score of 3, and those with greater than 75% staining were given the score of 4.

### *Statistics*

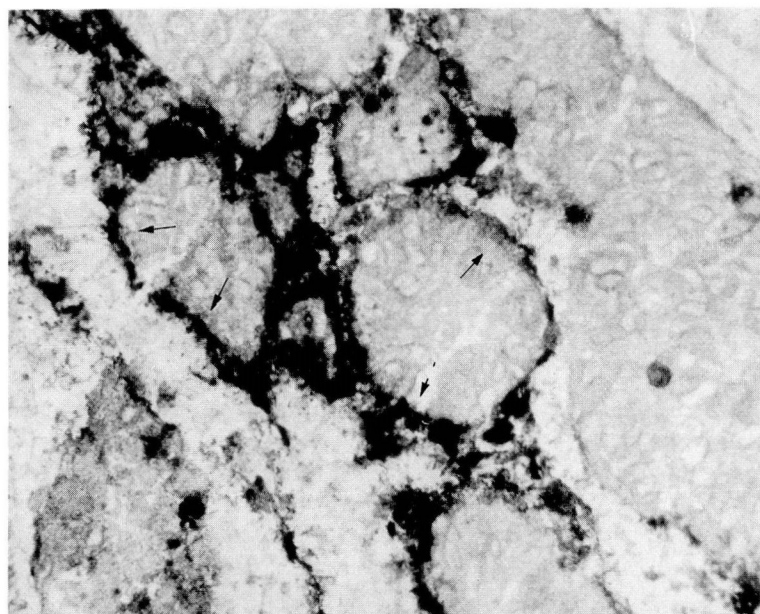
The sensitivity and specificity of each antibody for its tumor of origin were calculated using standard equations.<sup>8,9</sup>

## Results

All positive controls exhibited intense tumor staining with minimal background positivity. Although all slides were randomized, it was possible to discern the origin of many of the sections from the histology outlined by the hematoxylin counterstain. In addition, it was apparent which



**Fig. 1.** Photomicrograph of renal adenocarcinoma immunostained with McAb URO-2. The stroma (S) is negative, and the tumor (T) is positive (aminoethylcarbazole chromogen with hematoxylin counterstain,  $\times 150$ ).



**Fig. 2.** Photomicrograph of colorectal adenocarcinoma immunostained with McAb 19-9. The tumor cells exhibit intense membrane positivity (arrows) (aminoethylcarbazole chromogen with hematoxylin counterstain,  $\times 100$ ).

sections had been immunostained with URO-2 because of vessel-wall positivity. There was 100% concordance that 53 of 53 tumor sections exhibited no positivity on the negative control.

Seven of eight primary renal adenocarcinomas were positive for URO-2 (*Fig. 1*). The single negative renal tumor was a clear-cell adenocarcinoma of which only a granular cell focus had



**Table.** Immunoreactivity of primary adenocarcinomas with monoclonal antibody 19-9

Adenocarcinomas	Number of positives		Observer agreement (individual sections)	
	Observer 1	Observer 2	Positive	Negative
Colorectal (12)	8	5	5	4
Lung (8)	3	0	0	5
Breast (9)	3	3	3	6
Ovary (7)	2	2	2	5
Endometrium (9)	4	3	3	5
Kidney (8)	1	0	0	7

been frozen and stained. There was 100% observer agreement for all 53 tumors on the presence or absence of staining. All positive renal carcinomas stained intensely (2+) with 100% observer agreement. There was complete agreement that all seven cases exhibited greater than 75% tumor-area positivity. The remaining 45 non-renal adenocarcinomas failed to show any staining. Therefore, the specificity and sensitivity of URO-2 positivity for the diagnosis of renal cell adenocarcinoma were 100% and 87.5%, respectively.

There was less than 100% concordance on colorectal and noncolorectal tumor positivity with 19-9 (*Table*). Both observers agreed that five of 12 colorectal tumors exhibited positivity (*Fig. 2*) and that four of the 12 were negative. All of the colorectal cancers were moderately differentiated with the exception of a single well-differentiated tumor. Both observers agreed that the well-differentiated cancer did not stain.

Eight of the 41 noncolorectal cancers were graded as positive by both observers; there was agreement that 28 were negative. Most positive cases were of endometrial, ovarian, or breast origin. There was a low number of lung and renal positives and no observer agreement on positivity (*Table*).

All colorectal tumors exhibited 2+ staining intensity, as did all noncolorectal tumors on which the observers agreed staining was present. The percent tumor-area positive was  $\leq 50$  for the majority of colorectal tumors for both observers. Two of the three colorectal tumors in which observers disagreed on the presence of staining exhibited  $< 25\%$  tumor area positivity. There was never any disagreement on tumor positivity for both colorectal and noncolorectal tumors when at least one observer noted  $> 50\%$  tumor positivity.

The mean specificity and sensitivity of 19-9 for colorectal adenocarcinoma were 74% (range, 68%–80%) and 54% (range, 42%–67%), respectively.

### Discussion

Using the ABC immunoperoxidase technique on frozen tissue, we have determined the specificity and sensitivity of McAbs URO-2 and 19-9 for renal and colorectal adenocarcinomas, respectively.

There are several levels of specificity at which a monoclonal antibody to a tumor-associated antigen may be evaluated. The most specific assays either compare tumors of similar histogenesis (i.e., those of renal origin) or compare tumors with similar architectural features (i.e., adenocarcinomas). The latter is of value in surgical pathology when the determination of the primary origin for a metastatic adenocarcinoma is important. Using this definition of specificity, URO-2 and 19-9 were tested against 53 different adenocarcinomas representing six different primary sites.

McAb 19-9 is an IgG1 antibody secreted by a hybridoma generated from mice immunized with colon-carcinoma cell-line SW111G.<sup>6</sup> This McAb reacts with a sialylated lacto-*N*-fucopentaose II, a carbohydrate antigenic determinant which shares structural features with Lewis blood group antigens.<sup>10</sup> The antigen was first detected in the sera of patients with colorectal, gastric, and pancreatic cancers. Although it has been consistently absent from the sera of normal individuals, it has subsequently been found in the sera of patients with a number of benign diseases. In addition, 19-9 has been found in the sera of patients with breast, bronchial, renal, and thyroid carcinomas.<sup>11</sup>

Several studies have detected 19-9 in tissue. Atkinson et al<sup>12</sup> detected 19-9 in paraffin-em-

bedded tissue with an indirect PAP technique. Fifty-nine percent of colonic, 86% of pancreatic, 89% of gastric, 9% of hepatic, and 40% of gallbladder adenocarcinomas exhibited positivity. In addition, positivity was found in lung, breast, thyroid, prostatic, ovarian, and renal adenocarcinomas. In an earlier immunoperoxidase study using frozen tissue,<sup>13</sup> 19-9 was detected in 90% of colorectal, 100% of gastric, 100% of endometrial, 33% of renal, 50% of ovarian, 33% of lung, and 20% of breast adenocarcinomas. The study described here found a mean specificity of 74%. The sensitivity of this McAb was 54%, approximating the value given by Atkinson et al.<sup>12</sup>

Specificity and sensitivity are often inversely related; therefore, it may have been possible to increase the specificity of 19-9 with a less sensitive assay. Monoclonal antibodies are initially selected by their reaction with fresh or frozen tissue.<sup>14</sup> Antigens may be masked or destroyed when tissue is fixed and embedded.<sup>15</sup> Thus, frozen tissue is the substrate of choice for maximum sensitivity. The use of paraffin-embedded tissue in the study of Atkinson et al<sup>12</sup> did not appear to increase the specificity of 19-9 for colorectal adenocarcinoma.

McAb URO-2 is an IgG2 antibody secreted by a hybridoma established from the splenocytes of mice immunized with the human renal cancer cell line SK-RC-7.<sup>5</sup> The antigen is a glycoprotein found in glomerular and proximal tubular epithelium, the interstitial matrix of the kidney, vessel walls, placental tissue, and myometrium.<sup>16</sup>

Using frozen tissue, Finstad et al<sup>17</sup> found URO-2 antigen in 13 of 16 primary and three of four metastatic renal adenocarcinomas. It was not detected in colonic, breast, ovarian, or prostatic adenocarcinomas. Tomaszewski et al<sup>18</sup> found URO-2 antigen in seven of seven primary renal adenocarcinomas. One metastatic renal cell was negative. Breast adenocarcinomas were negative, as was a single colon primary. URO-2 antigen was found within a mesonephric adenocarcinoma of the bladder. This present study showed that the presence of URO-2 antigen was 100% specific for renal adenocarcinomas, a finding in accord with the work by Finstad et al<sup>17</sup> and Tomaszewski et al.<sup>18</sup>

The sensitivity of URO-2 antigen was 87.5%. That the sensitivity was not 100% may have been related to the granular cell nature of the single negative renal tumor. It is possible that the non-

frozen remainder of the tumor, a classic clear-cell adenocarcinoma, would have immunostained. Vesoulis et al<sup>19</sup> reported granular cell positivity with URO-2. Finstad et al did not disclose the histology of their reactive and nonreactive primary renal adenocarcinomas.<sup>17</sup>

Our study shows that there can be marked differences in interpretation of positive versus negative staining. This phenomenon appears to correlate with both antibody specificity and percent tumor positivity; thus, this variability was not seen with the highly specific URO-2. Second, differences in interpretation with 19-9 only occurred when percent tumor-area positivity was <50. Furthermore, 62% of discordant interpretations of colorectal and noncolorectal positivity occurred when percent tumor-area positivity was <25.

The sensitivity and specificity of the McAbs in our study are based upon evaluation with primary adenocarcinomas. These data cannot be directly extrapolated to metastatic lesions. Metastatic tumors have been shown to lose primary tumor antigens.<sup>20</sup>

## Conclusion

This study demonstrates that monoclonal antibodies to tumor-associated antigens, despite their hybridoma inception or commercial availability, are not intrinsically specific for their tumor of origin. However, within the confines of this study, McAb URO-2 is 100% specific and may be of practical value in surgical pathology.

Daniel D. Sedmak, M.D.  
Department of Pathology  
Ohio State University College of Medicine  
4170 Graves Hall  
333 W. 10th Ave.  
Columbus, OH 43210

## References

1. Mukai K, Rosai J. Applications of immunoperoxidase techniques in surgical pathology. [In] Fenoglio CM, Wolff M, eds. *Progress in Surgical Pathology*. New York, Masson, vol 1, 1980, p 15.
2. Köhler G, Milstein C. Continuous cultures of fused cells secreting antibody of predefined specificity. *Nature* 1975; 256:495-497.

3. Damjanov I, Knowles BB. Biology of disease: monoclonal antibodies and tumor-associated antigens. *Lab Invest* 1983; **48**:510-525.
4. Borowitz MJ, Stein RB. Diagnostic applications of monoclonal antibodies to human cancer. *Arch Pathol Lab Med* 1984; **108**:101-105.
5. Ueda R, Ogata S-I, Morrissey DM, et al. Cell surface antigens of human renal cancer defined by mouse monoclonal antibodies: identification of tissue-specific kidney glycoproteins. *Proc Natl Acad Sci USA* 1981; **78**:5122-5126.
6. Koprowski H, Herlyn M, Stepkowski Z, Sears HF. Specific antigen in serum of patients with colon carcinoma. *Science* 1981; **212**:53-55.
7. Hsu S-M, Raine L, Fanger H. A comparative study of the peroxidase-antiperoxidase method and an avidin-biotin complex method for studying polypeptide hormones with radioimmunoassay antibodies. *Am J Clin Pathol* 1981; **75**:734-738.
8. Galen RS, Gambino SR. *Beyond Normality*. New York, John Wiley and Sons, 1975, p 13.
9. Marchand A, Van Lente F, Galen RS. The assessment of laboratory tests in the diagnosis of acute appendicitis. *Am J Clin Pathol* 1983; **80**:369-374.
10. Magnani JL, Nilsson B, Brockhaus M, et al. A monoclonal antibody-defined antigen associated with gastrointestinal cancer is a ganglioside containing sialylated lacto-*N*-fucopentaose II. *J Biol Chem* 1982; **257**:14365-14369.
11. Ritts DE, Del Villano BC, Go VLW, Herberman RB, Klug TL, Zurawski VR Jr. Initial clinical evaluation of an immunoradiometric assay for CA 19-9 using the NCI serum bank. *Int J Cancer* 1984; **33**:339-345.
12. Atkinson BF, Ernst CS, Herlyn M, Stepkowski Z, Sears HF, Koprowski H. Gastrointestinal cancer-associated antigen in immunoperoxidase assay. *Cancer Res* 1982; **42**:4820-4823.
13. Sedmak D, Fishleder A, Tubbs R, Del Villano B, Bukowski R. An immunoperoxidase study of tumor specificity and tissue localization of gastrointestinal-associated carbohydrate determined 19-9. *Clin Res* 1983; **31**:412A.
14. Naiem M, Gerdes J, Abdulaziz Z, et al. The value of immunohistological screening in the production of monoclonal antibodies. *J Immunol Methods* 1982; **50**:145.
15. Naritoku WY, Taylor CR. A comparative study of the use of monoclonal antibodies using three different immunohistochemical methods: an evaluation of monoclonal and polyclonal antibodies against human prostatic acid phosphatase. *J Histochem Cytochem* 1982; **30**:253-260.
16. Cordon-Cardo C, Bander NH, Fradet Y, et al. Immunohistochemical dissection of the human urinary tract by monoclonal antibodies. *J Histochem Cytochem* 1984; **32**:1035-1040.
17. Finstad CL, Cordon-Cardo C, Bander MH, Whitmore WF, Melamed MR, Old LJ. Specificity analysis of mouse monoclonal antibodies defining cell surface antigens of human renal cancer. *Proc Natl Acad Sci USA* 1985; **82**:2955-2959.
18. Tomaszewski JE, Kornstein MJ. Sensitivity and specificity of URO antibodies in diagnostic surgical pathology. *Lab Invest* 1985; **52**:68A.
19. Vesoulis Z, Tancino B, Levin HS, Tubbs RR. Renal oncocytoma: unusual variants and immunohistochemistry (abst). *Lab Invest* 1984; **50**:63A.
20. Starling JJ, Beckett ML, Wright GL. Monoclonal antibodies to prostate adenocarcinoma antigens. [In] Wright GL, ed. *Monoclonal Antibodies and Cancer*. New York, Marcel Dekker, 1984, p 53.