

Catheter ablation of the atrioventricular conduction system to treat patients with atrial tachyarrhythmias, including patients with pacemakers¹

Eric Drummer, M.D.
James D. Maloney, M.D.
Lon W. Castle, M.D.
Richard Sterba, M.D.
Eugene Yeh, B.S.

Electrical catheter ablation of the AV conduction system is a safe and effective procedure for patients with intractable atrial tachyarrhythmias, including patients with previously implanted pacemakers. Seven such patients were treated with this procedure, and there were no complications. All seven patients' tachycardia was relieved, and six had sustained, chronic, complete AV block at follow-up (mean 7.4 months). Production of chronic, complete AV block appears to require two shocks at initial ablation and a unipolar His-bundle electrogram ≥ 0.4 mV. Electrical ablation of the AV conduction system seems to have permanently converted one patient's chronic atrial fibrillation to sinus rhythm. This procedure caused no adverse sequelae in previously implanted pacemakers or leads. In one patient, the procedure temporarily elevated pacing thresholds in the ventricle and the atrium.

Index terms: Heart block • Tachycardia

Cleve Clin Q 53:151-157, Summer 1986

¹Department of Cardiology, The Cleveland Clinic Foundation. Submitted for publication Dec 1985; accepted Feb 1986. pa

0009-8787/86/02/0151/07/\$2.75/0

Copyright © 1986, The Cleveland Clinic Foundation

Most patients with chronic, recurrent supraventricular tachycardias can be successfully treated with various medications that prevent arrhythmia or control ventricular response. Occasionally, antitachycardia devices are also indicated. For the rare patient who does not respond to or tolerate medical management, interrupting the AV node-His conduction system is often considered an alternative therapy. Until recently, this could only be accomplished surgically.¹⁻³ Closed-chest electrical catheter ablation was first performed in dogs,⁴⁻⁶ and since then has been performed in a number of carefully selected patients⁷⁻¹⁴ with good success and rare complications.

The procedure has not been carried out uniformly: some investigators have used specialized catheters,⁸ various amplitudes of electrical discharge, or different catheter positions.⁸⁻¹¹ Data regarding long-term follow-up and properties of the escape rhythm are still being compiled.¹⁴ Until now there have been no reports on ablation in patients with previously implanted pacemakers.

In this report we describe our experience with this relatively new procedure and provide our follow-up of these patients, some of whom had prior pacemaker implants.

Methods

The seven patients in this report were referred for catheter ablation of the AV node–His conduction system because of intractable atrial fibrillation-flutter with rapid ventricular response or other atrial tachyarrhythmias. Pertinent background data on these patients are given in *Table 1*. All patients had persistent symptoms or could not tolerate multiple medications, including many type I agents, beta blockers, and high doses of digoxin. Amiodarone was used in four patients. At the time of the procedure, five of the seven patients had previously implanted pacemakers, indicated for by tachycardia-bradycardia syndrome or symptomatic, drug-induced bradycardia. One of them had an antitachycardia device that could scan as well as deliver two programmed extra stimuli.¹⁵ All patients had electrophysiologic evaluation before the procedure, as summarized in *Table 1*.

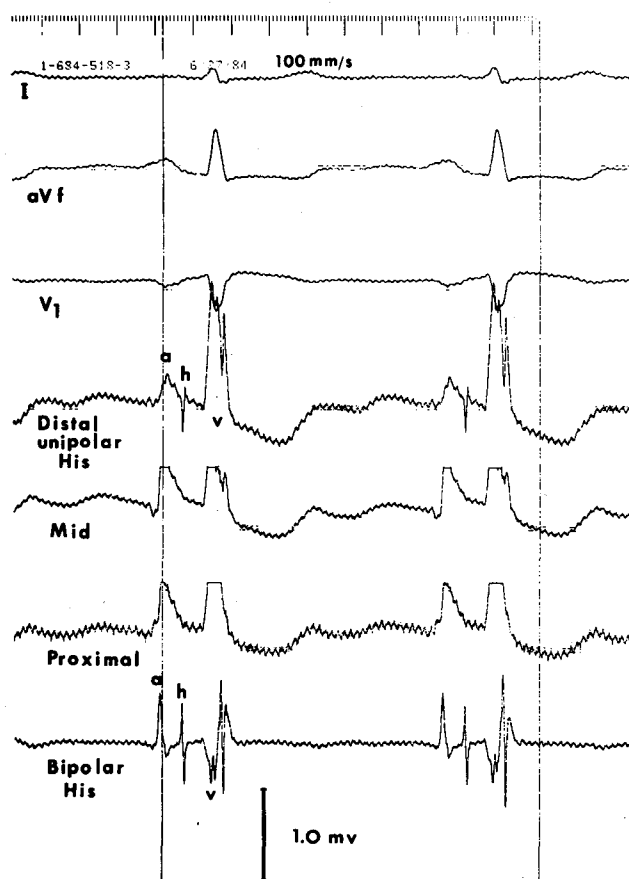


Fig. 1. Recordings from patient 2 just before ablation. The three ECG recordings are at the top. These are followed by the three unipolar electrograms (EGM) from each electrode of the tripolar His-bundle catheter. The shock was delivered through the distal electrode, which displays the highest-amplitude signal (0.5 mV).

a = atrial EGM; h = His-bundle EGM; v = ventricular EGM.

Table 1. Patient background data

Pt. no.	Age/Sex	Cardiac disease*	Rhythm†	Drug trials‡	Electrophysiologic study§
1	56 F	PMD	AF, LBBB	D, Q, PA, V, A	HV = 70, AF, AAVNC
2	53 F	none	PSVT, normal ECG	D, Q, PA, DI, V, P	HV = 60, AVNRT
3	57 M	PMD	AF, normal ECG	D, V, PA, A	HV = 50, AF, AAVNC
4	60 F	PMD	AF, LBBB	D, I, V, Q, PA, DI, A	HV = 100, AT, AF
5	37 M	Friedrich's ataxia, PMD	AT	D, M	HV = 60, AT
6	50 F	RHD	AF	D, A	HV = 64, AF
7	70 F	mitral valve prolapse	AF	D, Q, P	HV = 55, AF

* PMD = primary myocardial disease; RHD = rheumatic heart disease.

† AF = atrial fibrillation-flutter; LBBB = left bundle-branch block; PSVT = paroxysmal supraventricular tachycardia; AT = atrial tachycardia (ectopic or intraatrial reentry).

‡ D = digoxin; Q = quinidine; PA = procainamide; DI = disopyramide; V = verapamil; A = amiodarone; P = propranolol; M = metoprolol.

§ HV = interval from His deflection to earliest recorded ventricular electrogram in milliseconds; AAVNC = accelerated AV nodal conduction; AVNRT = AV nodal reentry tachycardia.




Fig. 2. The apparatus for the ablation procedure. The tripolar His-bundle ablation catheter and unipolar anodal catheter are on the left. The switching device in the center allows the pole on the His-bundle catheter to be switched from the recording device on the right to the defibrillator patch above. The anode of the defibrillator is connected to the large back patch (upper left), which is positioned just adjacent to the left scapula.

Before the ablation procedure, a quadripolar catheter was placed in the right ventricular apex for recording and temporary pacing. A standard no. 6 or 7 French tripolar catheter (USCI, Billerica, MA) was placed in the His-bundle region, where bipolar and unipolar recordings were obtained. A skin electrode served as the indifferent electrode for the recordings in the first ablation patient, and a catheter electrode was used in the inferior vena cava just below the right atrium in the others. All catheters were placed from the femoral vein. The His-bundle catheter was positioned to obtain the highest-amplitude bipolar and then unipolar His-bundle electrogram as well as a high-amplitude atrial electrogram from the distal pole. A representative recording from patient 2 is shown in *Fig. 1*.

When the catheters were positioned appropriately, the patient received either methohexital sodium (Brevital) or general anesthesia (patient 5). A switching device allowed the distal pole of the tripolar catheter to be connected to the cathode of the cardioversion unit (Physio-Control Life Pack-6, Redmond, WA). The anode was attached to a patch electrode (R-2 Corp., Skokie, IL) on the patient's back, just adjacent to the left scapula (*Fig. 2*). Then, one or two shocks of 200 to 360 J were administered (*Table 2*).

All patients were observed initially in the laboratory for postablation arrhythmias and return of AV conduction as well as for hemodynamic instability. It was difficult to record His-bundle electrograms after ablation. The response of ventricular rate to atropine (2 to 3 mg IV) was assessed. Following the procedure, all patients were monitored by telemetry for several days before their discharge. Patients 3 and 7, who did not have pacemakers implanted previously, had one implanted within 48 hours of the His-bundle ablation.

All patients were seen as outpatients several weeks after the procedure and then several months later (*Table 3*). Only three patients had Holter-monitor recordings performed. Patients 1, 2, 3, and 4 had a routine stress test. All patients' intrinsic rhythms were assessed by reprogramming their pacemakers to below the escape rate and/or by exercise stress testing. Before patients were discharged and at followup, the pacing and sensing thresholds of their pacemakers were assessed thoroughly.

Results

After ablation

Patients 1 and 5 had one shock on two separate occasions because AV conduction or tachycardia

Table 2. Ablation procedure data

Pt. no.	Unipolar His-bundle EGM* (mV)	Unipolar atrial EGM* (mV)	Preablation QRS†	(No. shocks)/strength (joules)	Postablation rhythm [acute] (beats/min)‡	Postablation QRS
1	0.16	0.18	LBBB	(1) 300	(CHB) 60	LBBB
At 4 mos	—	—	LBBB	(2) 360	(CHB) 42	LBBB
2	0.5	0.38	normal	(2) 300	(CHB) 55	IVCD
3	0.4	0.5	normal	(2) 300	(CHB/SR) 30	normal
4	0.6	0.8	LBBB	(2) 200	(CHB) 60 atrial asystole	LBBB
5	0.55	1.0	normal	(1) 200	(CHB) 33	RBBB
At 5 days	0.30	0.70	RBBB	(2) 300	(CHB) 33	RBBB
6	0.5	—	normal	(2) 200	(CHB) 45	IVCD
7	—	—	IVCD	(2) 300	(CHB) 40	IVCD
At 2 wks	—	—		(2) 360, 300		IVCD
At 5 wks	—	—		(2) 300		IVCD

* EGM = electrogram.

† LBBB = left bundle-branch block; RBBB = right bundle-branch block; IVCD = nonspecific intraventricular conduction delay.

‡ CHB = complete AV block; SR = sinus rhythm.

recurred after the first shock. Patient 7 also required multiple shocks on separate occasions. All others received two successive shocks during one procedure with the same catheter in the same position. All patients had complete AV block immediately after the first shock. The escape rate varied from 30 to 60 beats per minute (mean 46.1 beats per minute). Three patients had new intraventricular conduction delays; two of them had a nonspecific conduction delay and the other had complete right bundle-branch block. Two patients had preexisting left bundle-branch block, which did not change. All patients except 1, 5 (second attempt), and 7 had unipolar His-bundle electrograms ≥ 0.4 mV (average 0.51 mV). No patient had complications. After ablation patient 4's slow atrial flutter converted to atrial asystole and a wide, complex escape rhythm. Her atrium could not be paced with up to 12-mA and 2-msec pulse-width impulses. Two days later, her atrial arrhythmia returned with paced ventricular rhythm, but it was temporarily converted by esophageal pacing in an attempt to restore a sinus rhythm. Patient 3 had a 13-year history of persistent atrial fibrillation. Following ablation, his fibrillation converted to sinus rhythm with complete AV block. Immediately after ablation, no patient had significant abnormalities involving the implanted pacemakers. Only patient 4's permanent pacemaker was transiently unable to capture the ventricle, so the temporary pacing catheter was used for one to two minutes during this time.

At follow-up

All patients were followed for two to 15 months (mean 7.4 months) (Table 3). All except patient 5 had complete AV block at follow-up. Their QRS complexes were unchanged from the immediate postablation rhythm, and their intrinsic heart rates ranged from 36 to 50 (mean 43.6 beats per minute). None of the patients had clinical recurrence of tachycardia, and the three patients who had Holter monitors had no tachycardia recorded. At follow-up, five patients were taking no specific antiarrhythmic medications, and patient 1's medications were discontinued. Her medications were the same ones that were unsuccessful in controlling atrial fibrillation before ablation. Patient 5 is still taking 100 mg amiodarone every other day as well as digoxin. All patients felt significantly better, and none had had palpitations or tachycardia. In patients who had stress tests, heart rate with exercise did not increase significantly, suggesting a low junctional escape rhythm. Most patients' heart rates rose from between 3 to 40 beats per minute higher than their resting rates (mean 18 beats per minute increase from rest); however, in the two patients with sinus rhythm, atrial rates increased normally with exercise.

At follow-up, all patients' pacemakers were functioning normally, with evidence of normal lead integrity, and all had routine evaluation of pacing and sensing thresholds as well as fluoroscopy of leads. Patient 1's pacemaker had an

Table 3. Patient data at follow-up

Pt. no.	Follow-up at (mos.)	Resting rhythm (beats/min)*	QRS pattern†	Exercise rhythm (beats/min)*	Medications‡	Pacemaker type
1	6	(CHB) 42	LBBB	(CHB) 45	A, D (discontinued)	VVI
2	8	(CHB/SR) 50	IVCD	(CHB) 58	none	DVI
3	15	(CHB/SR) 40	normal	(CHB) 80	none	DDD
4	9	(CHB/AF) 36	LBBB	(CHB) 55	none	VVI
5	9	—	1° AV block, RBBB	—	A, D	DVI
6	3	(CHB/AF) 50	IVCD	—	none	VVI
7	2	(CHB/AF) 45	IVCD	paced	none	VVI‡

* CHB = complete AV block; SR = sinus rhythm; IVCD = nonspecific intraventricular conduction delay; AF = atrial fibrillation/flutter.

† LBBB = left bundle-branch block; IVCD = nonspecific intraventricular conduction delay; RBBB = right bundle-branch block.

‡ A = amiodarone; D = digoxin.

§ Medtronic #8400 Activitrax.

oversensing problem seven months after ablation, so the pacemaker was explanted and another implanted at another hospital. She had no symptoms of pacemaker dysfunction following His ablation. The types of pacemakers each patient had are shown in Table 3. Patient 7 had an activity-tracking pacemaker (Medtronic #8400 Activitrax), a VVI unit that increases its rate depending on the patient's activity, which is sensed by a piezoelectric crystal in the pacemaker that detects chest-wall vibration.

Discussion

In our series of patients, successfully producing complete AV block was related to the number of shocks and the amplitude of the unipolar, His-bundle electrogram, which depends on the catheter position. Of three patients who had only temporary complete AV block, two (patients 1 and 5) had one shock initially. Patient 1 also had a low-amplitude His-bundle electrogram at the initial attempt. The second attempt in patient 5 was done at a time when the unipolar His-bundle electrogram was also of low amplitude. Patient 7 had very low-amplitude electrograms from the first attempt. Two shocks of 200 to 360 J each produced chronic, complete AV block in all other patients. In patients receiving two shocks, the His-bundle electrogram is poorly recorded following the first shock. Other authors also suggest that one shock may not be adequate,^{7,8,11,12} and even recommend two shocks at higher energies than we have used.⁸ In dogs, single shocks produced chronic, complete AV block in only 50% of the animals.^{5,6}

The ratio of atrial to His-bundle electrograms in our study is lower than that suggested for optimal AV conduction damage and production

of bundle-branch block.^{6,7,9} Also, our His-bundle electrograms were usually of higher amplitude than those in these reports. These discrepancies may be due to our technique of using the anode in the inferior vena cava electrode to record unipolar electrograms. In addition, five of our patients were in atrial fibrillation and had low-amplitude fibrillation or flutter waves. Good-quality unipolar electrograms could only be obtained in five of our patients.

Patient 3 demonstrates an interesting phenomenon: his chronic atrial fibrillation resolved following successful ablation of the AV conduction system. His electrocardiogram (Fig. 3) at follow-up during a stress test shows that during exercise he had sinus tachycardia and remained in complete AV block. Since the His ablation, when the shock converted his tachycardia to sinus rhythm, he has retained a sinus mechanism and complete AV block. This patient now has a normally functioning sinus rhythm and a rate-responsive DDD pacemaker. Like him, many other patients with chronic atrial arrhythmias may in fact convert to sinus rhythm permanently after ablation. Why this patient's atrial fibrillation disappeared is unclear, but one explanation is that a part of the atrium involved in the reentry was destroyed. Another possibility is that, with a slower ventricular response, the ventricle can contract more efficiently, thus allowing atrial size to decrease.

Transient atrial standstill and the inability to pace the atrium after ablation is an important feature in patient 4. As was mentioned, this patient also had transient elevation of threshold in the ventricle. It has been shown that intracavitary shocks may raise thresholds, or make it impossible to pace, because of either local or distant effects.^{16,17} It is not known whether a shock applied

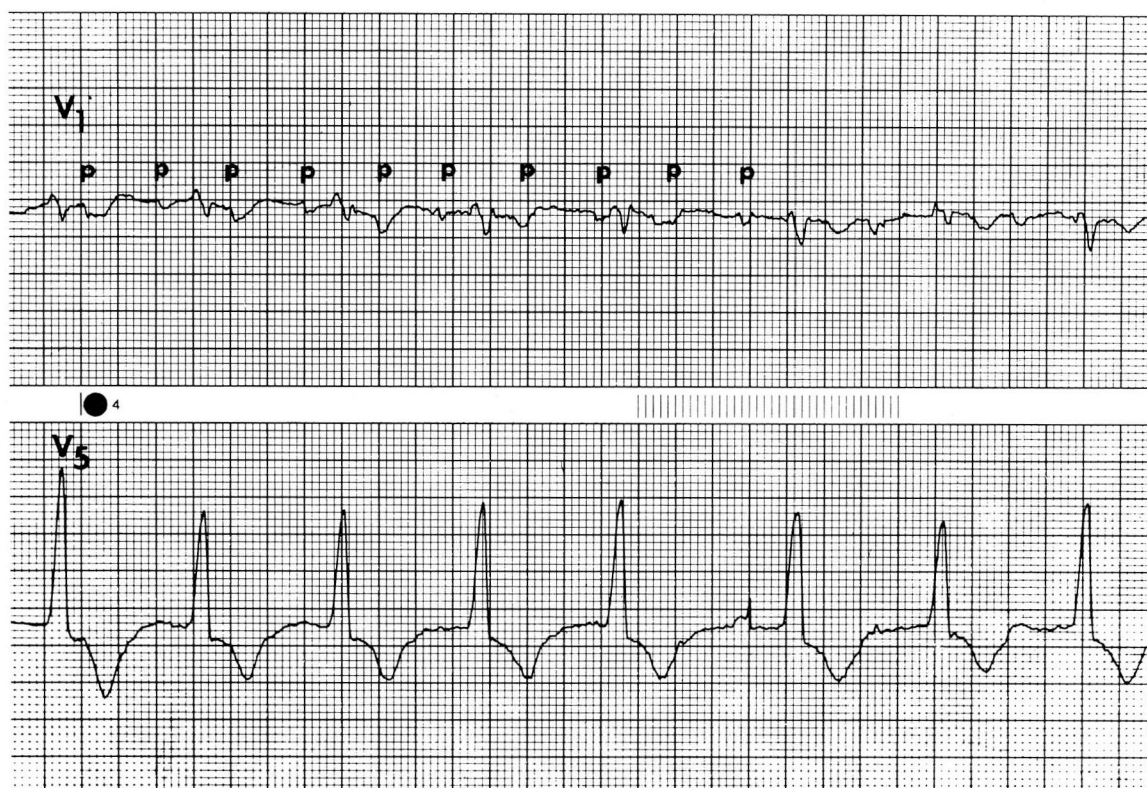


Fig. 3. Patient 3's ECG during follow-up stress test with his pacemaker programmed to below the intrinsic escape rate. Complete AV block is demonstrated with two simultaneously recorded leads, V1 and V5. The atrial rate (denoted as *p*) is approximately 150 beats per minute. The ventricular response is approximately 80 beats per minute.

at the His-bundle area could cause ventricular asystole and inability to pace the ventricle. Conceivably, this could happen if the catheter is too distal and in the ventricle. This again underlines the importance of having backup capability for temporary pacing with higher energy if needed, regardless of the presence of a permanent pacemaker.

It remains unknown whether complete AV block must be induced by catheter ablation to adequately control arrhythmia. One patient who did not sustain chronic, complete AV block (patient 5) has had no recurrence of rapid AV conduction while he has been taking minimal doses of amiodarone and digoxin. Other authors have suggested that only modifying the AV conduction system, without causing complete AV block, effectively controls atrial fibrillation and even eliminates AV nodal reentry tachycardia.^{9,12,13,18}

All seven patients have had significant clinical improvement and relief of tachycardia. Often, patients do not require medications and have

significant improvement in function. Their previously implanted pacemakers exhibited no malfunction on follow-up, as determined by testing the sensing and pacing thresholds of the programmable pulse generators. Escape rhythms appear to be stable, and no exacerbation of any arrhythmia has been documented. Immediately after ablation, however, one patient's pacemaker had transient elevation of thresholds, with loss of capture. Consequently, after His-bundle ablation, pacemaker function should be followed very carefully for any changes in pulse generator function or lead integrity.

Ablation of the AV conduction system is an effective, safe technique for controlling or eliminating various supraventricular arrhythmias. Production of complete AV block appears to depend on the number of shocks delivered and the position of the catheter, as reflected by intracardiac electrograms. Infranodal escape rhythms appear consistent and may show intraventricular conduction defects. At present, permanent pace-

makers are indicated for all patients with complete heart block. Previously implanted pacemakers continue to function normally after the procedure. Modifying the AV conduction system without causing complete AV block may effectively control or eliminate arrhythmias and may obviate permanent pacemakers. Future refinements in this technique may allow predictable alteration of AV conduction without causing complete AV block.

James D. Maloney, M.D.
The Cleveland Clinic Foundation
9500 Euclid Avenue
Cleveland, Ohio 44106

References

1. Sealy WC, Gallagher JJ, Kasell J. His bundle interruption for control of inappropriate ventricular responses to atrial arrhythmias. *Ann Thorac Surg* 1981;**32**:429-438.
2. Sealy WC, Hackel DB, Seaber AV. Study of methods for surgical interruption of the His bundle. *J Thorac Cardiovasc Surg* 1977;**73**:424-430.
3. Klein GJ, Sealy WC, Pritchett ELC, et al. Cryosurgical ablation of the atrioventricular node-His bundle: long-term followup and properties of the junctional pacemaker. *Circulation* 1980;**61**:8-15.
4. Gonzales R, Scheinman MM, Margaretten W, et al. Closed-chest electrode-catheter technique for His bundle ablation in dogs. *Am J Physiol* 1981;**241**:H283-H287.
5. Gonzales R, Scheinman M, Bharati S, Lev M. Closed chest permanent atrioventricular block in dogs. *Am Heart J* 1983;**105**:461-470.
6. Bardy GH, Ideker RE, Kasell J, et al. Transvenous ablation of the atrioventricular conduction system in dogs: electrophysiologic and histologic observations. *Am J Cardiol* 1983;**51**:1775-1782.
7. Josephson ME. Catheter ablation of arrhythmias. *Ann Intern Med* 1984;**101**:234-237.
8. Scheinman MM, Morady F, Hess DS, Gonzalez RG. Catheter-induced ablation of the atrioventricular junction to control refractory supraventricular arrhythmias. *JAMA* 1982;**248**:851-855.
9. Gallagher JJ, Svenson RH, Kassell J, et al. Catheter technique for closed-chest ablation of the atrioventricular conduction system: a therapeutic alternative for the treatment of refractory supraventricular tachycardia. *N Engl J Med* 1982;**306**:194-200.
10. Trantham JL, Gallagher JJ, German LD, Broughton A, Guarnieri T, Kasell J. Effects of energy delivery via a His bundle catheter during closed chest ablation of the atrioventricular conduction system. *J Clin Invest* 1983;**72**:1563-1574.
11. Wood DL, Hammill SC, Holmes DR, et al. Catheter ablation of the atrioventricular conduction system in patients with supraventricular tachycardia. *Mayo Clin Proc* 1983;**58**:791-796.
12. Critelli G, Perticone F, Coltorti F, Monda V, Gallagher J. Closed chest modification of atrioventricular conduction system in man for treatment of refractory supraventricular tachycardia. *Br Heart J* 1983;**49**:544-549.
13. Johns JA, Black AJ, Harper RW, et al. Control of refractory supraventricular arrhythmias after unsuccessful closed-chest His bundle ablation. *PACE* 1985;**8**:85-93.
14. Scheinman MM, Evans-Bell T, Executive Committee of the Percutaneous Cardiac Mapping and Ablation Registry. Catheter ablation of the atrioventricular junction: a report of the percutaneous mapping and ablation registry. *Circulation* 1984;**70**:1024-1029.
15. Spurrell RA, Nathan AW, Camm AJ. Clinical experience with implantable scanning tachycardia reversion pacemakers. *PACE* 1984;**7**:1296-1300.
16. Huang SK, Marcus FI, Ewy GA. Clinical experience with endocardial catheter ablation for refractory ventricular tachycardia (abstract). *J Am Coll Card* 1985;**5**:473.
17. Yee R, Jones DL, Klein GJ. Pacing threshold changes after transvenous catheter countershock. *Am J Cardiol* 1984;**53**:503-507.
18. McComb JM, McGovern BA, Garan H, Ruskin JN. Modification of atrioventricular conduction using low energy transcatheter shocks (abstract). *J Am Coll Card* 1985;**5**:454.