

Essential hyperhidrosis

Current therapy¹

Jean-Claude M. Tabet, M.D.
Janet W. Bay, M.D.
Michele Magdinec, R.N., C.N.R.N.

Essential hyperhidrosis, the idiopathic production of excessive sweat, continues to be a much misunderstood ailment. Its recognition as a benign disorder has often restricted its treatment to nonsurgical modalities, many times with unsatisfactory results. Surgical intervention has provided excellent results in patients suffering from hyperhidrosis and should certainly be considered an alternative method of treatment. The authors review the clinical condition of essential hyperhidrosis including current treatment options, with special emphasis on surgical therapy.

Index term: Hyperhidrosis

Cleve Clin Q 53:83-88, Spring 1986

¹ Department of Neurosurgery, The Cleveland Clinic Foundation. Submitted for publication Apr 1985; accepted Nov 1985.

0009-8787/86/01/0083/06/\$2.50/0

Copyright © 1986, The Cleveland Clinic Foundation

Essential hyperhidrosis, the idiopathic production of excessive sweat, is a recognized clinical entity afflicting a small minority of the general population. Typically, the condition is bilaterally symmetric, often most pronounced on the palmar surface of the hand. Perspiration literally pools onto a cupped palmar surface or drips profusely off the fingertips (*Fig. 1*). The feet and axillae are also frequently involved. Socks and shoes become soaked and, as with other clothing, become quickly ruined. This excessive perspiration may be aggravated by warm temperatures, exercise, and by anxiety or other forms of psychic stress.¹

The condition is often an occupational handicap to draftsmen, stenographers, dentists, and salesmen, for example. Regardless of their occupation, however, those afflicted frequently must alter their life-styles to accommodate the handicap. While writing, many don gloves and use



Fig. 1. Visible perspiration on the dorsum of the fingers.

two sheets of paper, one sheet acting as an absorbent shield over the written copy. Many avoid shaking hands or apologize after having done so. One embarrassed patient would adjust her store purchases to an even dollar so as to prevent having to receive change in her hand. Most find it necessary to wear absorbent undergarments, layered clothing, and dark coordinates as camouflage. Some have even undergone serious personality changes and still others have withdrawn from society altogether.^{2,3}

Anatomy and physiology

The sweat glands of the body are of two types: eccrine and apocrine.

Eccrine glands, numbering two to five million, are distributed over the entire surface of the skin, although most numerous on the palms and soles.⁴ Eccrine secretion consists of a hypotonic solution whose chief solid component is sodium chloride. Along with an abundant vascular supply, eccrine glands receive a generous supply of sympathetic innervation, paradoxically supplied by cholinergic nerve fibers. Because of this, acetylcholine and other cholinergic agents (i.e., pilocarpine) accentuate the sweating response, while atropine and propantheline bromide inhibit sweating. Eccrine glands serve primarily a thermoregulatory function, although those glands restricted to palms and soles respond to anxiety and mental and emotional stress rather than a rise in body temperature. When ambient temperature exceeds 29° C, heat loss by radiation convection and insensible evaporation is inadequate, neces-

sitating cooling through evaporation of eccrine gland secretions.⁵ Pronounced thermoregulatory sweating is found on the forehead, chest, neck, and dorsae of the hands.

Apocrine sweat glands are found in the lower dermis and upper layer of the subcutaneous fat in the mammary areolar region, external auditory meatus, axillae, and pelvic areas.⁴ They serve no thermoregulatory function. Decomposition of cuboidal cells lining the gland comprise their secretion. Bacterial attack of this organic material is responsible for its offensive odor. Apocrine glands begin functioning at puberty and fail to be influenced by any innervation, acetylcholine, pilocarpine, or heat. Unlike eccrine glands, their function is unaffected by sympathectomy.⁴

Sympathetic innervation of sweat glands to the upper extremities originates in the hypothalamus and descends in the brainstem to the spinal cord. From the skull base to the coccyx extend two symmetrical ganglionated cords in the anterolateral aspects of either side of the vertebral body. The eight cervical ganglia fuse into superior, middle, and inferior cervical ganglia. This inferior cervical ganglia, when fused with the first thoracic ganglion, forms the cervicothoracic or stellate ganglion. These ganglionated cords accept the sympathetic outflow from the first thoracic to upper lumbar spinal cord. These connections are made via white rami communicantes which originate from the intermediolateral nucleus and exit with the ventral motor root. From their synapse in the ganglion, postganglionic gray rami communicantes enter the spinal nerve to innervate their target organs. The sweat glands of the upper extremity derive their sympathetic innervation from the first to third thoracic ganglia.⁶ Sympathectomy of the second ganglion is sufficient to induce relief of hyperhidrosis of the palms,^{7,8} although many surgeons also advocate simultaneous removal of the T3 ganglion.^{1-3,9,10}

Of particular interest is the cervicothoracic or stellate ganglion. Pupillodilator fibers and fibers to nonstriated muscles of the upper eyelids are present in cervical sympathetic efferent fibers of this cervicothoracic ganglion. Therefore, although some authors advocate sacrifice of the ganglion to achieve total denervation of the upper extremity¹ and to prevent postoperative gustatory hyperhidrosis,⁶ its excision frequently leaves the patient with Horner's syndrome.

Classification

Hyperhidrosis may be divided into the essential (primary or idiopathic) and secondary types.

Secondary hyperhidrosis may be associated with a number of systemic illnesses. Familiar examples include hyperthyroidism,^{5,6,11,12} obesity,^{6,12} diabetes,¹² pheochromocytoma,^{4,6,11} carcinoma of the lung,¹³ and menopause.⁴ Also reported are rarer cases such as spinal tumor producing a unilateral hyperhidrosis.¹³ Central nervous system (CNS) diseases have also induced secondary hyperhidrosis: Parkinsonism,⁶ traumatic CNS injury,^{1,4,6} encephalitis,^{4,14} or other infections,⁶ syringomyelia,⁴ and hypothalamic and glomus tumors.⁴ Secondary hyperhidrosis can be restricted to a unilateral distribution of the face or extremity.^{1,11} It is also frequently associated with causalgia or Raynaud's disease.¹

Essential hyperhidrosis has no known etiology. Because no difference in response to acetylcholine between normal people and hyperhidrotic patients was found, Chalmers and Keele¹⁵ concluded that hyperhidrosis was a central phenomenon and due to hyperactivity in the CNS. Its diagnosis is one of exclusion and can usually be made without difficulty by history. Hyperhidrosis is believed to be of equal sexual distribution,^{4,12} although women may find the condition less acceptable^{2,14} and present more frequently for treatment. Nearly 40% of the patients note a family history of excessive sweating.

Cloward² has noted that those of Japanese ancestry are 20 times more likely to suffer from the affliction than those of Caucasian origin. In addition, epidemiological studies have found a prevalence of the condition among Jews originating from North Africa, Yemen, and the Balkan.¹¹ Onset of hyperhidrosis is usually in childhood, with the youngest reported age of onset being three months.⁴ In some patients, onset may have coincided with puberty.^{11,16} Patients usually present for treatment in the second or third decades of life.¹⁶ Because there does not appear to be a tendency for spontaneous regression, older patients may also present for treatment.⁸

Patients with palmar hyperhidrosis may also complain to a lesser degree of plantar hyperhidrosis. Axillary hyperhidrosis is a common association as well. The condition is accentuated during hot summer months in most patients. Emotional and gustatory stimuli are also responsible

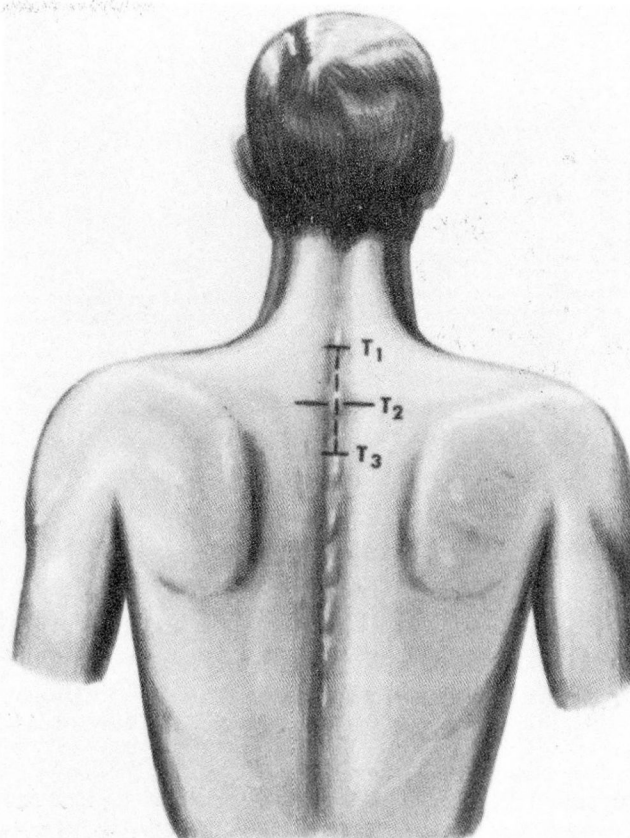


Fig. 2. Midline costotransversectomy incision.

for provoking the condition, with the former being the most powerful physiological stimuli.¹¹ Patients often deny accentuation with exercise. Excessive sweating ceases altogether during sleep.^{11,12}

Various methods have been devised to support and quantitate the diagnosis of hyperhidrosis. Metal corrosion tests,¹⁷ resistance hydrometry,⁵ sweat collection methods,⁵ quinizarin compound powder, and Minor's starch-iodine test have all been used in the investigation of hyperhidrotic patients. These tests may provide a quantitative or qualitative assessment of a patient with hyperhidrosis. Most experts would agree, however, that the diagnosis of hyperhidrosis can be accurately made solely on the basis of a complete history and careful physical examination.

Treatment

Most patients who present for surgical treatment of hyperhidrosis have also previously com-

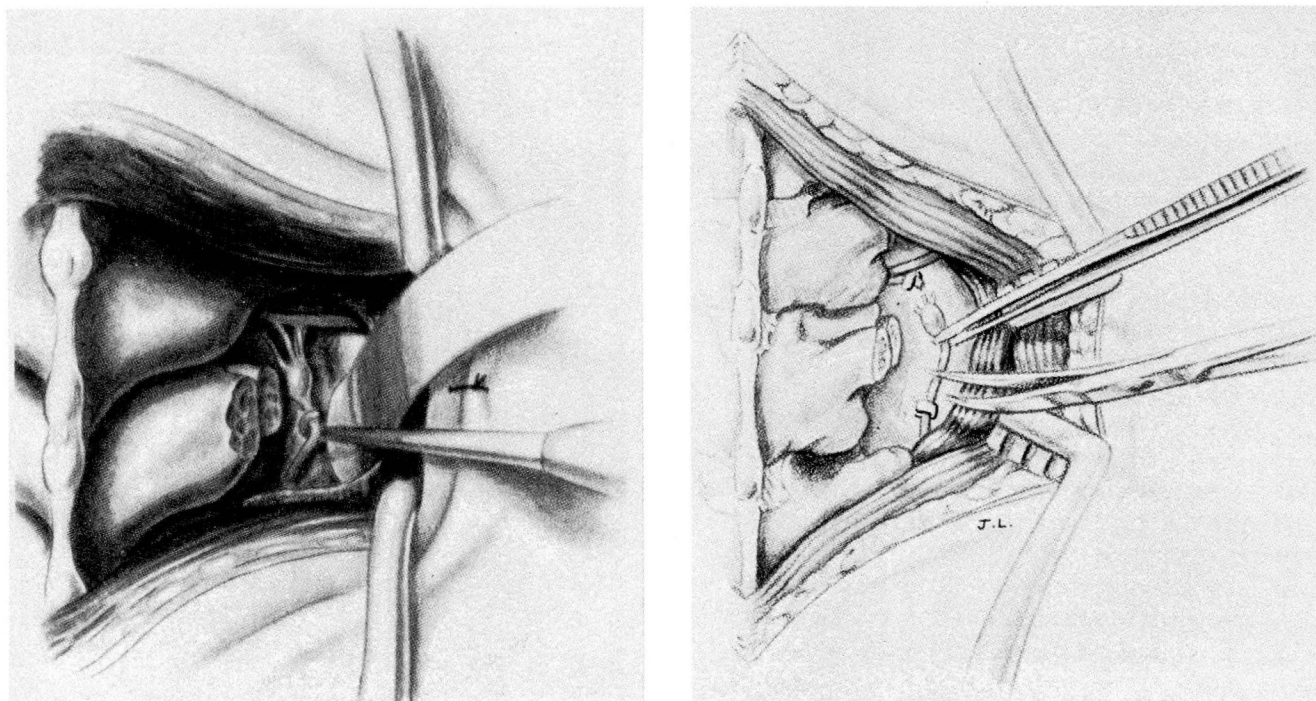


Fig. 3. A. Following costotransversectomy, the T2 ganglion is identified and isolated from underlying contiguous structures. B. Excision of the T2 ganglion from the sympathetic chain is completed with sharp dissection.

pleted a host of conservative therapies. Locally applied astringents such as formaldehyde, potassium permanganate, tannic acid, and glutaraldehyde have all been used. The locus of action of these drugs is restricted to the epithelium and sweat ducts, resulting in only temporary local relief. Resultant contact dermatitis in susceptible patients also limits their use. Antiperspirants, many containing aluminum salts which block excretory ducts by epithelial coagulation, have similar disadvantages. Systemically administered anticholinergic medications have included atropine, methanthelin bromide, hydegerine, and propantheline bromide. Unfortunately, intolerable side effects such as dry mouth, blurred vision, or constipation may result from the high dosages necessary to control sweating. Tranquilizers are of little use in alleviating sweating, but may control the attendant anxiety. Biofeedback, hypnosis, or psychotherapy are beneficial in certain patients. Irradiation of the skin, now considered an outmoded treatment, was used early in this century to induce atrophy of the sweat glands. In addition to the unnecessary radiation exposure, x-ray therapy was also associated with risk of severe dermatitis.⁸ Alcohol block of the stellate ganglia is technically unpredictable and usually not permanent. The resultant intercostal neu-

ralgia may, however, persist for years.¹⁶ Tap water iontophoresis, a form of electrolysis, produces anhidrosis of the treated part.¹⁸ Although relatively free of serious side effects, the necessity for repetitive frequent treatments is a drawback.

When a refractory case of palmar hyperhidrosis is encountered, surgical sympathectomy should be considered. Surgical treatment of palmar hyperhidrosis produces excellent results with a minimum of morbidity. Upper thoracic sympathectomy may be performed by a variety of techniques, each of which has advantages and disadvantages. Advocates of the transaxillary route, as originally described by Atkins,¹⁹ emphasize the cosmetic benefit of a hidden axillary incision and excellent surgical visualization of the sympathetic chain. However, its disadvantages include the need for two separate axillary incisions and staged procedures in bilateral sympathectomy,²⁰ increased risk of long thoracic nerve damage,³ and frequent postoperative neuralgias.⁸ This approach is relatively contraindicated in patients with severe chronic lung diseases and pleural adhesions.^{3,20} Telford^{21,22} described another approach to thoracic sympathectomy via the supraclavicular approach. Advocates claim that its extrapleural route results in fewer pulmonary complications compared to the trans-

pleural approach of Atkins. Bilateral sympathectomy may be performed at one stage because risk of pneumothorax is reduced. The major disadvantage of this approach is potential risk to the contiguous structures such as the subclavian and vertebral arteries, brachial plexus, thoracic duct, and phrenic nerve. Unsightly scars and a higher incidence of Horner's syndrome are other disadvantages.³

Since the 1960s, the posterior midline approach for upper thoracic sympathectomy has been used at the Cleveland Clinic (*Fig. 2*).^{8,23} This procedure, which is a modification of that described by Cloward,² involves resection of a portion of each third rib posteriorly and total excision of the second thoracic ganglion (*Fig. 3*). Advantages of this approach include bilateral exposure through a single incision, excellent visualization of the ganglia, and low incidence of pneumothorax or Horner's syndrome.²³ Disadvantages include a painful interscapular incision and the risk of persistent intercostal neuralgia. To date, 398 patients have undergone this procedure for treatment of essential hyperhidrosis at the Cleveland Clinic (unpublished data). This surgical procedure lasts two to three hours and requires four to five days of hospitalization. Normal activities, including return to school or work, can be resumed in four to six weeks. Bilateral T2 ganglionectomy has resulted in 100% immediate relief of palmar sweating with minimal morbidity. There has been no operative mortality and complications have been largely wound related. Complications have included symptomatic pneumothorax (0.7%), wound infections (1%), and Horner's syndrome (0.5%). In long-term follow-up studies (longest 14 years), our patient satisfaction rate is 88%. Compensatory sweating, or increase in sweating, in nondenervated areas such as the feet, perineum, and thorax is the most common postoperative complication. Nearly 84% of patients experience this side effect to a mild degree, with 5% complaining of a severe amount of compensatory sweating. Rarely, however, do patients believe that the compensatory sweating is more of a problem than the palmar hyperhidrosis. Other causes of dissatisfaction include intercostal neuralgia (17%), persistent wound pain (<2%), or scar appearance (7%). Late recurrence of palmar hyperhidrosis has been less than 1%.

Wilkinson²⁴ has recently reported percutaneous radiofrequency destruction of the T2 gan-

glion as an alternative to an open operation for upper thoracic sympathectomy. Of 3 patients undergoing the bilateral procedure for palmar hyperhidrosis, excellent results were achieved in five of the six hands with the remaining hand achieving partial relief. Further study of this procedure will better assess its successes, risks, and complication rate.

Summary

Essential hyperhidrosis remains a common and disabling problem. When medical treatment fails, surgical sympathectomy should be offered to the patient. Based on our experience with nearly 400 patients, we have found that bilateral T2 ganglionectomy via the posterior approach is a safe and effective treatment.

Janet W. Bay, M.D.
Department of Neurosurgery
The Cleveland Clinic Foundation
9500 Euclid Ave.
Cleveland, OH 44106

References

1. Peddie GH, Longmore DB. The treatment of hyperhidrosis by upper dorsal sympathectomy through an axillary approach. *Am Surg* 1958; **24**:959-963.
2. Cloward RB. Hyperhidrosis. *J Neurosurg* 1969; **30**:545-551.
3. Kurchin A, Zweig A, Adar R, Mozes M. Upper dorsal sympathectomy for palmar primary hyperhidrosis by the supraclavicular approach. *World J Surg* 1977; **1**:667-674.
4. Ellis H. Hyperhidrosis and its surgical management. *Postgrad Med* 1975; **58**:191-196.
5. Frewin DB, Downey JA. Sweating—physiology and pathophysiology. *Australas J Dermatol* 1976; **17**:82-86.
6. Gjerris F, Olesen HP. Palmar hyperhidrosis. Long-term results following high thoracic sympathectomy. *Acta Neurol Scand* 1975; **51**:167-172.
7. Hyndman OR, Wolkin J. Sympathectomy of the upper extremity: evidence that only the second dorsal ganglion need be removed for complete sympathectomy. *Arch Surg* 1942; **45**:145-155.
8. Dohn DF, Sava GM. Sympathectomy for vascular syndromes and hyperhidrosis of the upper extremities. *Clin Neurosurg* 1977; **25**:637-650.
9. Khanna SK, Sahariah S, Mittal VK. Supraclavicular approach for upper dorsal sympathectomy. *Vasc Surg* 1975; **9**:151-159.
10. Bogokowsky H, Slutzki S, Bacalu L, Abramssohn R, Negri M. Surgical treatment of primary hyperhidrosis. A report of 42 cases. *Arch Surg* 1983; **118**:1065-1067.
11. Adar R, Kurchin A, Zweig A, Mozes M. Palmer hyperhidrosis and its surgical treatment. *Ann Surg* 1977; **186**:34-41.

12. Ellis H. Transaxillary sympathectomy in the treatment of hyperhidrosis of the upper limb. *Am Surg* 1979; **45**:546-551.
13. Pleet DL, Mandel S, Neilan B. Paroxysmal unilateral hyperhidrosis and malignant mesothelioma. *Arch Neurol* 1983; **40**:256.
14. Adson AW, Craig WM, Brown GE. Essential hyperhidrosis cured by sympathetic ganglionectomy and trunk resection. *Arch Surg* 1935; **31**:794-806.
15. Chalmers TM, Keele CA. The nervous and chemical control of sweating. *Br J Dermatol* 1952; **64**:43-54.
16. Hartfall WG, Jochimsen PA. Hyperhidrosis of the upper extremity and its treatment. *Surg Gynecol Obstet* 1972; **135**:586-588.
17. Jensen O, Nielsen E. 'Rusters'. The corrosive action of palmar sweat: II. Physical and chemical factors in palmar hyperhidrosis. *Acta Derm Venerol (Stockh)* 1979; **59**:139-143.
18. Shrivastava SN, Singh G. Tap water iontophoresis in palmo-plantar hyperhidrosis. *Br J Dermatol* 1977; **96**:189-195.
19. Atkins HJB. Per axillary approach to the stellate and upper thoracic sympathetic ganglia. *Lancet* 1949; **2**:1152.
20. Man B, Kraus L, Motovic A. Axillary sympathectomy for upper extremities. *Vasc Surg* 1976; **10**:138-143.
21. Telford ED. The technique of sympathectomy. *Br J Surg* 1935; **23**:448-480.
22. Telford ED. Sympathetic denervation of the upper extremity. *Lancet* 1938; **1**:70-72.
23. Bay JW, Dohn DF. Surgical sympathectomy. [In] Wilkins RH, Rengacharz SS, eds, *Neurosurgery*. New York, McGraw-Hill, 1985, pp 1912-1917.
24. Wilkinson HA. Radiofrequency percutaneous upper-thoracic sympathectomy: technique and review of indications. *N Eng J Med* 1984; **311**:34-36.