

# Evaluation of cardiac tumors with digital subtraction angiography<sup>1</sup>

Kenneth J. Ramsey, D.O.  
Robert Detrano, M.D.  
Conrad C. Simpfendorfer, M.D.  
Ernesto E. Salcedo, M.D.  
Douglas S. Moodie, M.D.

This study outlines the authors' experience to date with digital subtraction angiography (DSA) for the evaluation of cardiac tumors. DSA demonstrated seven of eight cardiac tumors previously demonstrated with echocardiography. DSA is a safe and useful adjunct to echocardiography in evaluating cardiac tumors.

**Index terms:** Angiography • Heart neoplasms • Heart, ultrasound studies • Subtraction technic

**Cleve Clin Q 52:** 573-577, Winter 1985

Intravenous digital subtraction angiography (DSA) is a useful technique for evaluating the cardiovascular system.<sup>1-3</sup> Yiannikas et al<sup>4</sup> and Detrano et al<sup>5</sup> have reported their experience using DSA in the evaluation of intracardiac masses. We report our continued experience with DSA in this application.

## Material and methods

Patients were referred to The Cleveland Clinic Foundation for evaluation of suspected intracardiac masses. Cardiac abnormalities were suspected based on physical examination and echocardiography. In addition, 6 of the 8 patients underwent cardiac catheterization as part of their evaluation.

DSA was performed using a Phillips DVI-1 or Technicare DR 960 unit. The 30° right anterior oblique (RAO) and occasionally the 50° left anterior oblique (LAO) and frontal projections were employed. A precontrast blurred mask radiograph obtained over 320 msec served as the

<sup>1</sup> Department of Cardiology, The Cleveland Clinic Foundation. Submitted for publication May 1985; accepted Sept 1985.

0009-8787/85/04/0573/05/\$2.25/0

Copyright © 1985, The Cleveland Clinic Foundation

**Table.** Pertinent data\*

Case No.	Sex/Age	Physical examination	DSA identification	Clinical diagnosis	Pathological findings
1	M/5 mo	II/VI harsh systolic murmur, right ventricular uplift, decreased P2	Right ventricular mass obstructing outflow tract	Tuberous sclerosis, pulmonary outflow obstruction	Rhabdomyoma
2	F/20 mo	II/VI short systolic murmur	No DSA identification	Tuberous sclerosis	No surgery done
3	M/57 yrs	Normal	Left atrial mass	Myxoma	Myxoma
4	F/61 yrs	II/VI holosystolic murmur, II/VI diastolic	Large immobile left intra-atrial mass	Myxoma	Myxoma (4 cm)
5	F/63 yrs	I/VI systolic murmur	Left atrial mass prolapsing to left ventricle	Myxoma	Myxoma (6 cm)
6	M/52 yrs	II/VI diastolic murmur, probable tumor plop	Calcified right atrial mass prolapsing to right ventricle	Myxoma	Calcified myxoma (6 cm)
7	F/29 yrs	II/VI systolic murmur, II/VI diastolic murmur	Right atrial-right ventricular mass arising from the inferior vena cava and prolapsing into the pulmonary artery	Metastatic uterine sarcoma	Endometrial stromal sarcoma (30 cm × 2.5 cm)
8	M/42 yrs	S4 midsystolic click, I/VI diastolic murmur	Calcified right atrial mass prolapsing to right ventricle, arising from the inferior vena cava	Hypernephroma	Right atrial-inferior vena cava thrombus and hypernephroma

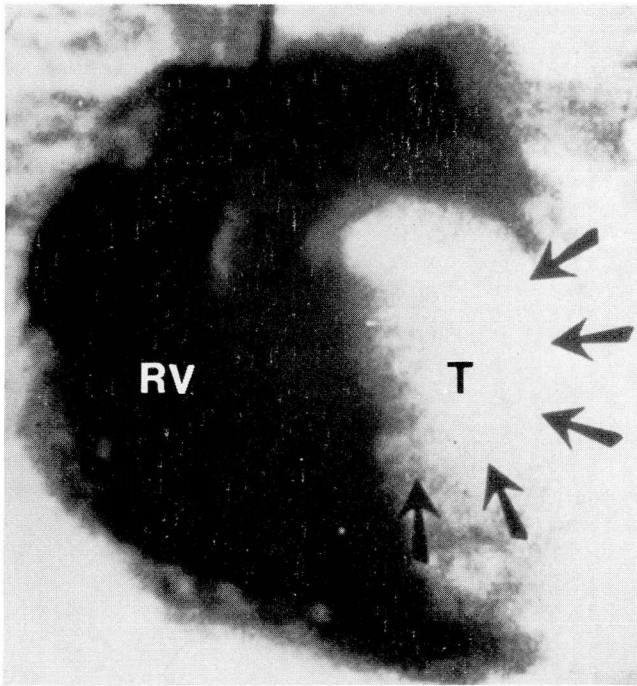
\* Cardiac abnormalities were demonstrated echocardiographically in all cases. Cardiac catheterization was performed in all but cases 2 and 7.

initial mask. Renografin 76 was injected at a concentration of 0.5 to 0.75 mL/kg into a peripheral or central vein via a standard side-hole catheter. Images were acquired at 30 frames/sec and stored on videotape for replay and post-processing, including late mask subtraction.

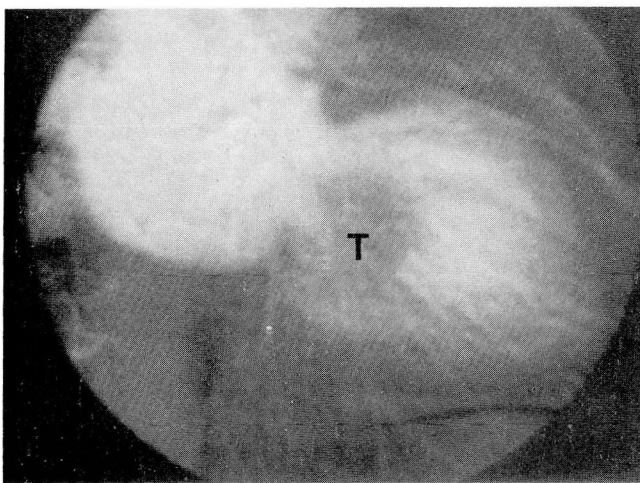
## Results

The *Table* outlines the characteristics of the 8 patients studied and the findings. *Figure 1* is a frontal ventriculogram of a 5-month-old boy (Case 1) with tuberous sclerosis. DSA was done to rule out pulmonary stenosis and showed a mass arising from the right ventricular septum into the outflow tract. Subsequent surgery demonstrated a rhabdomyoma. *Figure 2* shows a left atrial myxoma in a 57-year-old man (Case 3) who was being evaluated for recurrent cerebral vascular

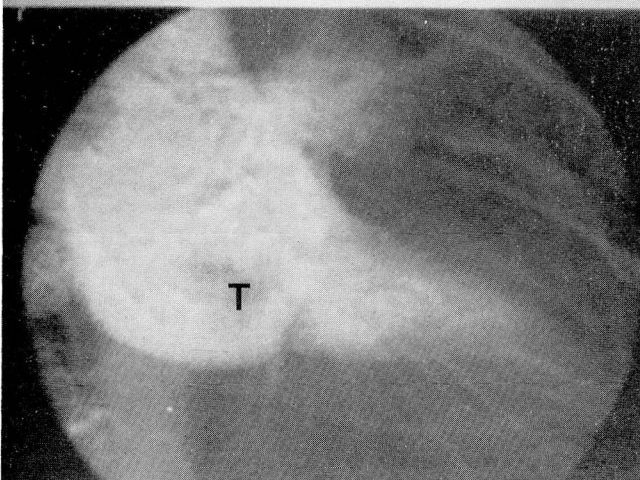
accident, dizziness, dyspnea, and palpitations. *Figure 3* is a ventriculogram of a 52-year-old man (Case 6) who, during the routine physical examination, was noted to have a grade II/VI soft diastolic murmur and probable tumor plop. DSA clearly demonstrated a large calcified right atrial mass which prolapsed into the right ventricle. At surgery, a 75-g, 4 × 6-cm calcified atrial myxoma was removed. *Figure 4A* shows an oblong mass originating from the inferior vena cava with the distal portion curled in the right ventricle in a 29-year-old woman (Case 7) who had a low-grade endometrial sarcoma two years previously. *Figure 4B* shows the mass as its tip prolapsed through the pulmonary valve. A 30 × 2.5-cm endometrial stromal sarcoma was removed through a right atriotomy. *Figure 5* is a ventriculogram of a 42-year-old man (Case 8) admitted because of he-



**Fig. 1.** Case 1. A 5-month-old boy with tuberous sclerosis and harsh systolic murmur (anteroposterior projection). Rhabdomyoma is seen in the right ventricle (*RV*). *T* = tumor (rhabdomyoma).



**A**



**B**

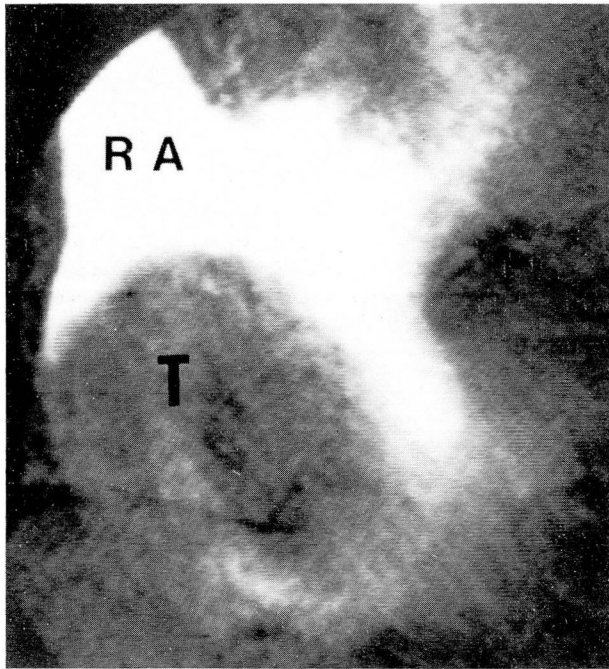
**Fig. 2.** Case 3. A 57-year-old man with recurrent cerebral vascular accident and short systolic murmur.

**A.** Myxoma in the left ventricle during diastole.

**B.** Myxoma in the left atrium during systole.

*T* = tumor (myxoma).





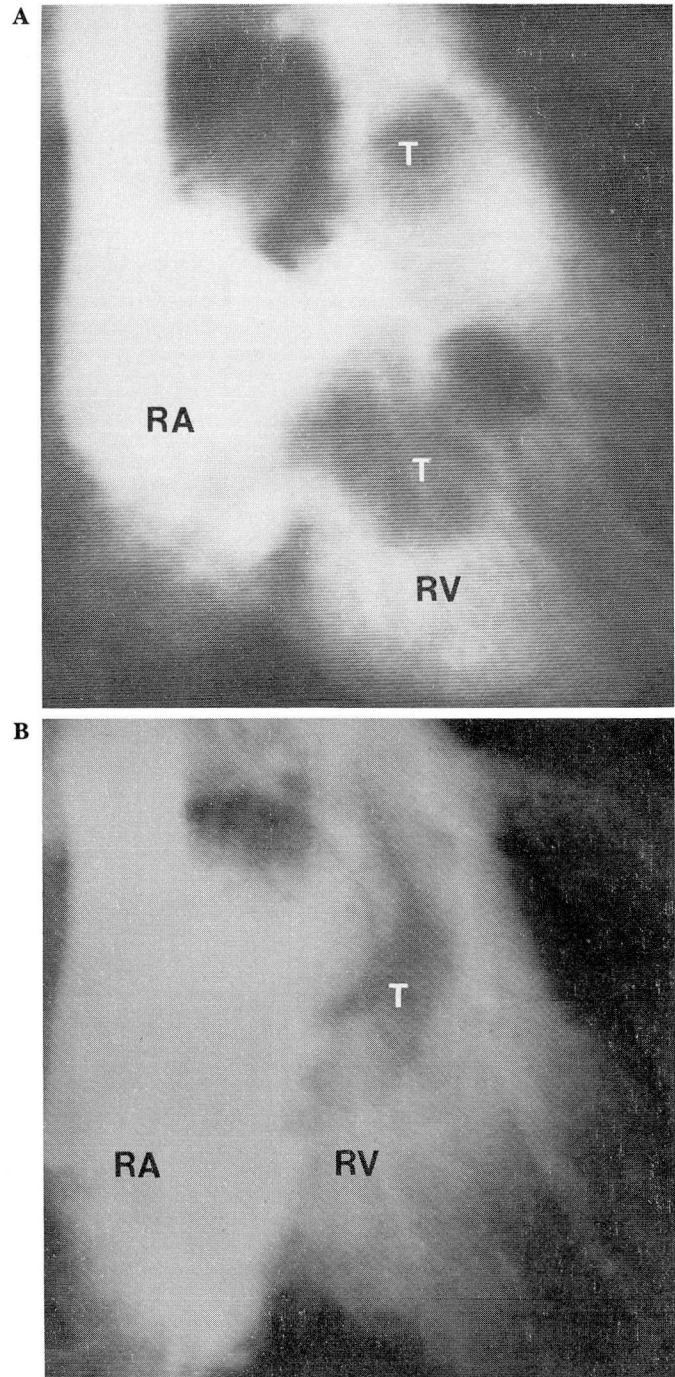
**Fig. 3.** Case 6. A 52-year-old man with grade II/VI diastolic murmur (right anterior oblique projection). Myxoma is seen in the right atrium (RA). T = tumor (myxoma).

maturia. His physical examination revealed a fourth heart sound, a mid-systolic click, and a grade I/VI diastolic murmur. DSA showed a mass in the inferior vena cava and right atrium which prolapsed into the right ventricle during diastole. A metastatic hypernephroma was removed from the right atrium and inferior vena cava.

In all cases, cardiac abnormalities were demonstrated with echocardiography. DSA correctly identified seven of the eight cardiac masses. In Case 2, a 1-cm mass identified by echocardiography was not visualized with DSA. In 2 patients (Cases 7 and 8), the metastatic nature of the tumor was demonstrated with DSA but not with echocardiography. When performed, standard cardiac angiography did not improve visualization. In no case was significant coronary artery disease diagnosed during coronary angiography. There were no complications during any of the DSA studies.

### Discussion

Two-dimensional echocardiography has proved reliable in the demonstration of intracardiac masses.<sup>6-8</sup> However, difficulty may be en-



**Fig. 4.** Case 7. A 29-year-old woman with a history of uterine sarcoma and II/VI systolic and diastolic murmur.

**A.** A diastolic frame (right anterior oblique projection) shows the tumor in the right ventricle (RV).

**B.** A systolic frame (right anterior oblique projection) shows the tumor prolapsing through the pulmonary valve.

RA = right atrium and T = tumor (metastatic uterine sarcoma).

countered in visualizing retrosternal structures.<sup>9,10</sup> In addition, general body appearance



or associated pulmonary pathology may hinder the echocardiographic examination. Generally, these problems do not limit an adequate DSA study. In addition, DSA may delineate the points of attachment of tumors and/or their relationship to the cardiac chamber.

Compared with standard cardiac angiography, DSA offers a lower risk of embolic, arrhythmic, or hemorrhagic complications. In approximately 1,000 DSA studies, we have had only one complication: catheter breakage at the peripheral insertion site. Although DSA does not provide good visualization of the coronary arteries, this is insignificant in young patients or in patients with a low risk for coronary artery disease.

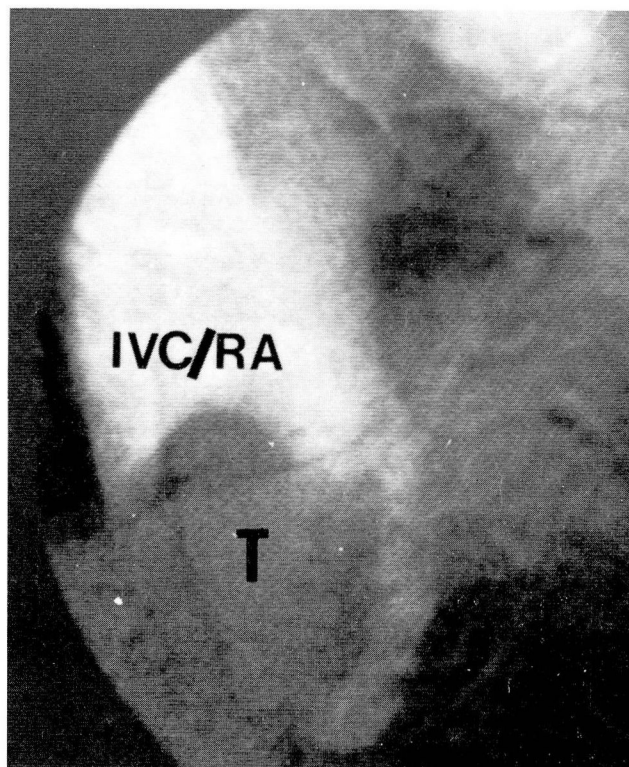
The failure of DSA to detect a tumor in the second patient may have been due to the small size of the tumor (1-cm) as demonstrated with echocardiography and the difficulty in controlling motion artifacts in an infant.

The noninvasive nature of echocardiography and its ability to visualize small and intramyocardial masses make it the preferred initial method of evaluation of suspected cardiac tumors.<sup>11</sup> However, DSA may help to confirm the presence of cardiac masses when the echocardiogram is suboptimal or technically difficult to obtain. In addition, DSA better delineates the extension of metastatic tumors to other vascular structures (i.e., pulmonary outflow tract, superior vena cava, and inferior vena cava). DSA is a useful and safe adjunct to echocardiography. In addition, image quality is comparable to direct cardiac angiograms, thus obviating the need for the latter.

Douglas S. Moodie, M.D.  
Department of Cardiology  
The Cleveland Clinic Foundation  
9500 Euclid Ave.  
Cleveland, OH 44106

## References

1. Meaney TF, Weinstein MA, Buonocore E, et al. Digital subtraction angiography of the human cardiovascular system. *AJR* 1980; **135**:1153-1160.
2. Myerowitz PD. Digital subtraction angiography: present and future uses in cardiovascular diagnosis. *Clin Cardiol* 1980; **5**:623-629.
3. Tobis JM, Nalcioglu O, Henry WL. Digital subtraction angiography. *Chest* 1983; **84**:68-75.
4. Yiannikas J, Zaidi AR, Moodie DS. Evaluation of intracardiac masses by digital subtraction angiography (brief communication). *Am Heart J* 1984; **108**:600-603.
5. Detrano R, Moodie DS, Salcedo E. Cardiomyopathic and cardiac neoplastic disease. [In] Moodie DS, Yiannikas J. *Digital Subtraction Angiography of the Heart and Lungs*. Orlando, Fla., Gruen & Stratton (in press).
6. Wolfe SB, Popp RL, Feigenbaum H. Diagnosis of atrial tumors by ultrasound. *Circulation* 1969; **39**:615-622.
7. DePace NL, Soulen RL, Kotler MN, Mintz GS. Two dimensional echocardiographic detection of intraatrial masses. *Am J Cardiol* 1981; **48**:954-960.
8. Salcedo EE, Adams KV, Lever HM, Gill CC, Lombardo H. Echocardiographic findings in 25 patients with left atrial myxoma. *J Am Coll Cardiol* 1983; **1**:1162-1166.
9. Feigenbaum HC. *Echocardiography*. Philadelphia, Lea & Febiger, 3rd ed, 1981, p 159.
10. Come PC, Riley MF, Markis JE, Malagold M. Limitations of echocardiographic techniques in evaluation of left atrial masses. *Am J Cardiol* 1981; **48**:947-953.
11. Mattern H, Fricke G, Orellano L, et al. Klinik und nichtinvasive Diagnostik von kardialen Myxomen. *Z Kardiol* 1983; **72**:286-291.



**Fig. 5.** Case 8. A 42-year-old man with a hypernephroma, I/VI diastolic murmur, and mid-systolic click (right anterior oblique projection). Metastatic hypernephroma is seen in the inferior vena cava (IVC). RA = right atrium and T = tumor (hypernephroma).