

Metastatic cecal adenocarcinoma presenting as a testicular adnexal mass¹

Howard S. Levin, M.D.
James T. McMahon, Ph.D.
Gary E. Barnett, M.D.

A case is reported of an occult primary adenocarcinoma of the cecum that presented as a testicular adnexal mass. The histochemical, immunohistochemical, and ultrastructural characteristics of the tumor are described, and should enable the lesion to be accurately identified.

Index terms: Cecal neoplasms • Genital neoplasms, male

Cleve Clin Q 52:429-436, Fall 1985

Metastatic carcinomas involving the testis and testicular adnexa occur only rarely.¹⁻⁴ It is even more unusual when the metastasis is associated with an occult primary tumor.⁴ In these circumstances, the correct diagnosis may not be made. The purpose of this report is to describe an asymptomatic primary adenocarcinoma of the cecum that presented as a testicular adnexal mass and to demonstrate that histochemical, immunohistochemical, and ultrastructural features may be of great value in arriving at the diagnosis of metastatic adenocarcinoma.

Clinical history

A 38-year-old white male discovered an intra-scrotal nodule and was examined by a urologist

for a mass involving the right epididymal area. A bilateral vasectomy had been performed several years earlier. Right orchiectomy was performed on June 21, 1981 and a 1-cm adnexal mass identified. The microscopic sections were reviewed by two consultants. One consultant interpreted the lesion as an atypical glandular proliferation and the differential diagnosis was among atypical adenomatoid tumor, primary or secondary adenocarcinoma, and an atypical reactive epithelial proliferation. The second consultant interpreted the lesion as vasitis nodosum. The patient was discharged and followed up, and in March 1982 complained of painless, bright-red rectal bleeding for one day, right upper quadrant abdominal discomfort for one week, and a weak and washed-out feeling for three to four months. There was no history of weight loss or loss of appetite. Examination revealed right-sided abdominal tenderness and a palpable, firm, slightly tender, fixed, irregular mass in the right upper quadrant. Fresh blood was present on digital examination of the rectum. Sigmoidoscopic examination revealed blood coming from above the 22-cm level. The right testis was absent and the left testis was palpably normal. A barium enema examination on April 1, 1982 showed an irregular, incomplete filling of the cecum. Colonoscopic examination revealed a friable, granular mass in the cecum that on biopsy proved to be adenocarcinoma. On April 22, 1982 a right hemicolectomy was performed. The specimen contained a large adenocarcinoma of the cecum that involved the adjacent ileum, with regional lymph node, mesenteric, and omental metastases.

¹ From the Department of Pathology, The Cleveland Clinic Foundation, Cleveland, OH, and the Department of Pathology, Grant Hospital, Columbus, OH. Submitted for publication April 1985; accepted May 1985. ht

0009-8787/85/03/0429/08/\$3.00/0

Copyright © 1985, The Cleveland Clinic Foundation

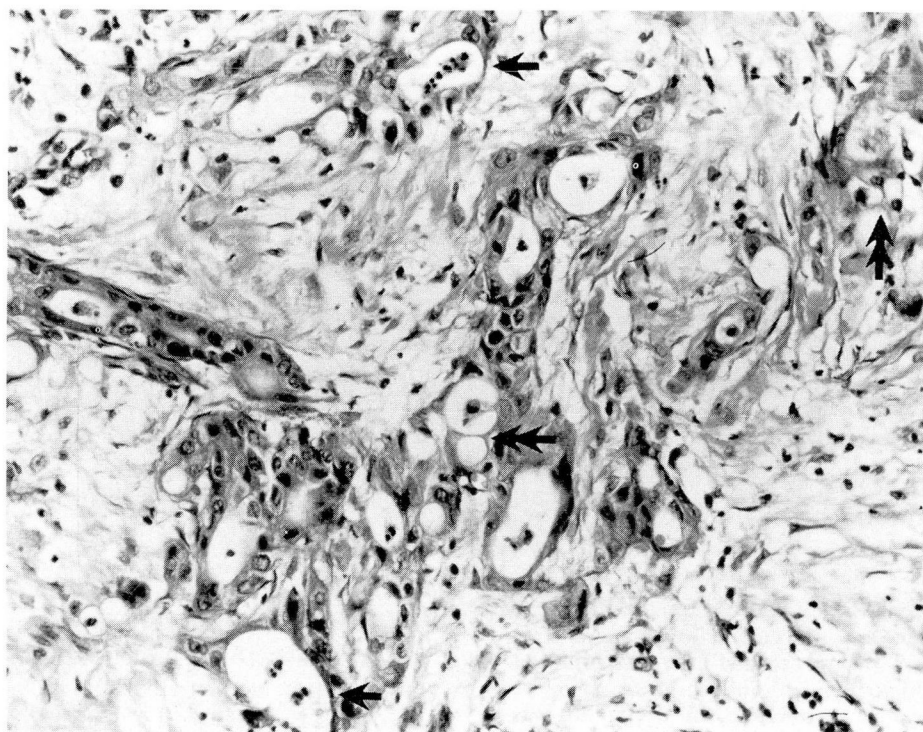


Fig. 1. Testicular adnexal tumor. The glandular neoplasm is growing in a plexiform pattern surrounded by collagen. Neoplastic cells vary in height from flattened attenuated cells to cuboidal and columnar cells that contain vacuoles. Polymorphonuclear leukocytes are present in gland lumina (arrows). A spider-web effect is focally present (double arrows). (H&E \times 200.)

The patient was treated with chemotherapy. On November 5, 1982 at the time of exploratory laparotomy for right hydronephrosis, abdominal carcinomatosis was identified. A transverse loop colostomy was performed on November 29, 1982 in an attempt to decompress a sigmoid obstruction. The patient died on December 17, 1982.

Pathologic findings

The original specimen consisted of right testis, epididymis, and spermatic cord. The testis measured $5 \times 3.5 \times 3$ cm. A 1-cm bulging nodular mass was attached to the tunica albuginea, with grayish-white, firm tissue attached and adjacent to it. The testicular parenchyma was unremarkable, as was the epididymis. Firm, gray-white, ill-defined tissue was present in the spermatic cord nearest the epididymis. The site of previous vasectomy was not identified.

Multiple sections of epididymis and adjacent tissue showed a complex proliferation of luminated epithelial structures involving fibroadipose

tissue and extending to the epididymis (*Fig. 1*). Rare mitotic figures were identified. The glandular structures were moderately differentiated, with round to somewhat irregular nuclei and eosinophilic cytoplasm. Some of the nuclei contained small nucleoli. Occasional nuclei had a somewhat vesicular appearance. Some of the epithelial cells had attenuated cytoplasm and others had cytoplasmic vacuoles. Polymorphonuclear leukocytes were present focally within gland lumina and small hyperchromatic intraluminal structures were interpreted as polymorphonuclear leukocytic debris. No definite spermatozoa were identified within gland lumina. Microfocal neural invasion was present (*Fig. 2*) and rare tumor cells were present in vein walls (*Fig. 3*).

Material in gland lumina was positive with diastase-digested periodic acid-Schiff (PAS) stain, alcian blue at pH 2.5, mucicarmine, and colloidal iron stains (*Fig. 3*). After hyaluronidase digestion, interstitial mucin disappeared but gland lumina retained their alcian blue and colloidal iron pos-

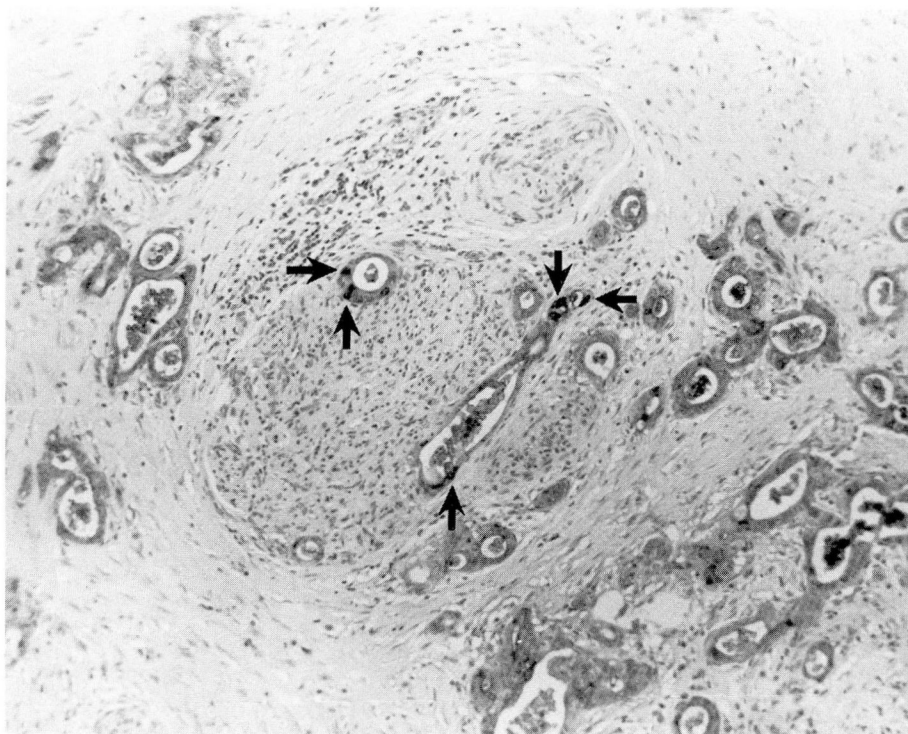


Fig. 2. Testicular adnexal tumor. Infiltrating glands invade nerve. Stain is positive for carcinoembryonic antigen, particularly in cells with blackened cytoplasm (arrows). (Immunoperoxidase stain for carcinoembryonic antigen $\times 200$.)

itivity. PAS and alcian blue positivity was demonstrated in intracytoplasmic vacuoles after diastase and hyaluronidase digestion, respectively. Immunoperoxidase staining for carcinoembryonic antigen was performed after the metastasis was discovered and was found to be markedly positive in epithelial cell cytoplasm (*Fig. 2*). Immunoperoxidase staining for AE1 and AE3 keratin following pronase treatment was performed at this time and was positive.

Ultrastructural examination

Tissue was removed from formalin fixative and processed for electron microscopy. The neoplastic cells were supported on a basal lamina and were attached to one another by desmosomes, zonula adherens, and zonula occludens. The cells formed acini into which short (0.5 to $1.0\ \mu\text{m}$) microvilli projected from the apical surface of the epithelial cells. These microvilli contained parallel aligned filamentous cores that extended into the apical cytoplasm as long, prominent rootlets, measuring up to $4.5\ \mu\text{m}$ (*Fig. 4*). The plas-

malemma of microvilli was covered by a pelage of delicate branching filaments (glycocalyx) measuring $0.1\ \mu\text{m}$ long and 2.5 to $5\ \text{nm}$ wide (*Fig. 4* inset).

The colonoscopic biopsy specimen of the cecum contained numerous neoplastic glands, some of which were present in the large intestinal mucosa (*Fig. 5*). The majority of the biopsy specimen contained an invasive, well to moderately differentiated adenocarcinoma. Within the submucosa the invasive neoplastic glands had an appearance identical to that in the testicular adnexa.

The ileo-colectomy specimen consisted of $9\ \text{cm}$ of ileum and $30\ \text{cm}$ of attached colon. A $6 \times 6\text{-cm}$ cecal mass extended through the cecal wall into the mesentery and in a contiguous fashion into the distal ileum. The neoplasm was annular and ulcerated. Multiple neoplastic nodules were present in the omentum. Microscopic sections demonstrated the mucosal origin of the tumor. While there were areas identical to those seen in the testicular adnexal lesion, the majority of the

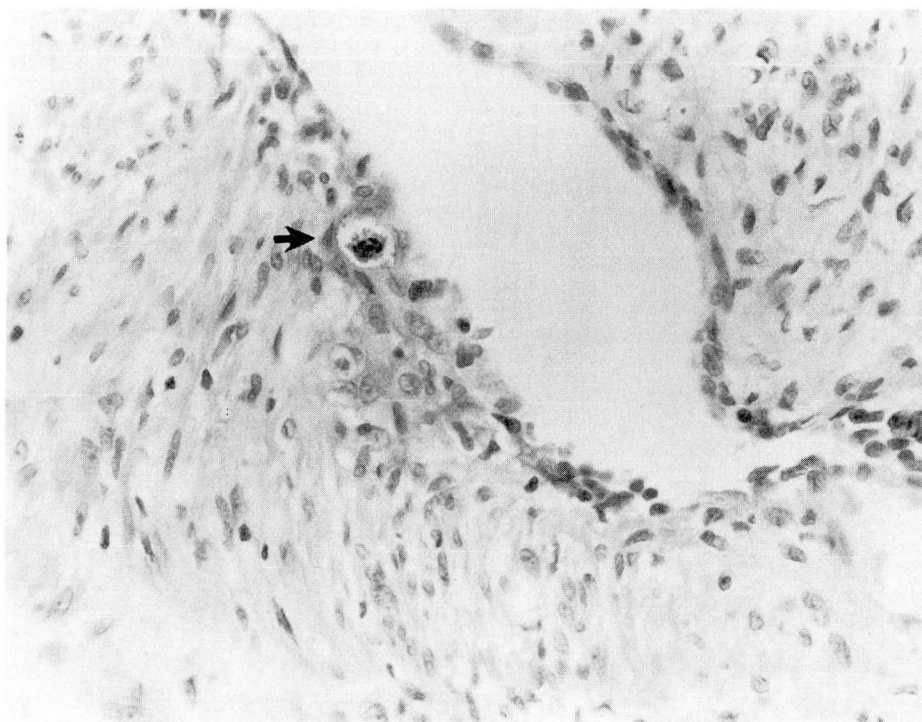


Fig. 3. Testicular adnexal tumor. Adenocarcinoma in vein wall (arrow). Neoplastic gland contains alcian-blue-positive material in gland lumen. (Alcian blue stain at pH 2.5 \times 320.)

tumor was less differentiated and in some areas was growing in cords and poorly differentiated glands (*Fig. 6*). Ulceration and necrosis were present within the substance of the tumor.

Discussion

Nodular masses of the testicular adnexa usually do not pose a diagnostic problem. In general, the clinical history is consistent with the pathologic diagnosis. Lesions of vasitis nodosum in the spermatic cord almost invariably involve a history of vasectomy, although Taxy et al⁵ reported a case of vasitis nodosum at the junction of the vas deferens and epididymis without an antecedent history of vasectomy or trauma. Adenomatoid tumors (mesothelioma, adenomatoid type) in general are slowly growing, nontender epididymal lesions smaller than 5 cm. Metastatic carcinomas involving the testis and adnexa occur only rarely and are usually discovered at postmortem examination. Price and Mostofi¹ identified only 38 metastatic tumors involving the testis at a time when the Testicular Tumor Registry listed more than 1,600 primary testicular tumors. Only six

metastatic tumors were symptomatic. The majority of these tumors, discovered mostly at autopsy, were from lung or prostate gland. Haupt et al⁴ reviewed 127 cases of metastatic carcinoma involving the testis that had been cited in the medical literature, and added two cases. In only nine of these cases was the initial manifestation in the testis. In four of seven cases in which diagnoses were recorded, they were incorrect.

Metastatic tumors involving the epididymis and spermatic cord are even less frequent than metastatic tumors involving the testis. Algaba et al³ reviewed 22 confirmed cases of metastatic cancer involving epididymis and spermatic cord that had been cited in the literature; in only two of these was the initial manifestation in the testicular adnexa. The frequency of primary sites in this review was as follows: stomach 9, prostate 6, ileal carcinoid 3, kidney 2, pancreas 1, and colon 1. Smallman and Odedra⁶ reported a metastatic adenocarcinoma to the right epididymis from an occult carcinoma of the sigmoid and indicated that there had been two prior reports of colonic adenocarcinoma metastasizing to the epididymis.

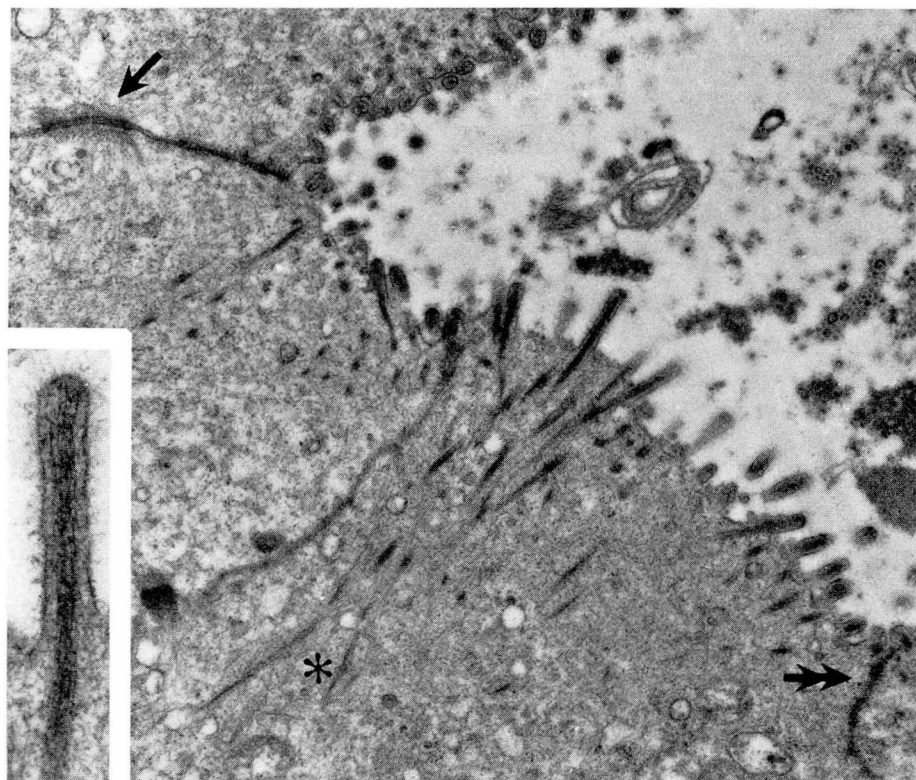


Fig. 4. Electron microscopy image of testicular adnexal tumor. Gland-forming neoplastic cells are characterized by rigid microvillar processes projecting into glandular lumina and long filamentous rootlets extending deep into the apical cytoplasm (asterisk). Microvilli contain parallel-aligned microfilaments and are covered by a glycocalyx of short branching filaments (inset). Tumor cells are joined laterally by well-developed desmosomal junctions (arrow), and apically by junctional complexes (double arrow). (Uranyl acetate and lead citrate $\times 14,500$; inset $\times 53,000$.)

Monn and Poticha² reviewed 13 cases of carcinoma metastatic to the spermatic cord, one of which was from rectum and a second from colon. Other cases originated in stomach, prostate, appendix, and kidney. Three of the cases originating in the stomach were also reviewed by Algaba et al.³ In the last 14 years we have seen one patient with a metastatic adenocarcinoma of the colon that involved testis and epididymis. In that patient, there was a known, previously resected primary colonic adenocarcinoma. Metastasis to testicular appendages presumably occurs as a result of retrograde venous or lymphatic spread, arterial embolism, direct invasion, or drop metastasis. In the present case, rare neoplastic cells were identified in vein walls, possibly due to vascular spread. In addition, tumor extended transmurally through bowel wall

and was present in peritoneum and omentum. The testicular adnexal neoplasm may have resulted from drop metastasis since the tumor originated in the cecum and the right testicular adnexa were involved. It is not known if the processus vaginalis was patent.

The histochemical findings should have indicated that the neoplasm was of epithelial origin. Mucin stains (PAS, alcian blue at pH 2.5, colloidal iron, and mucicarmine) demonstrated the presence of acid and neutral mucopolysaccharides in gland lumina and cytoplasmic vacuoles. Hyaluronidase virtually completely digested the interstitial mucins. These findings are strongly suggestive of a metastatic carcinoma although Taxy,⁵ in a case of vasitis nodosum unassociated with previous vasectomy, described weakly positive mucicarmine, PAS, and hyaluronidase resistant

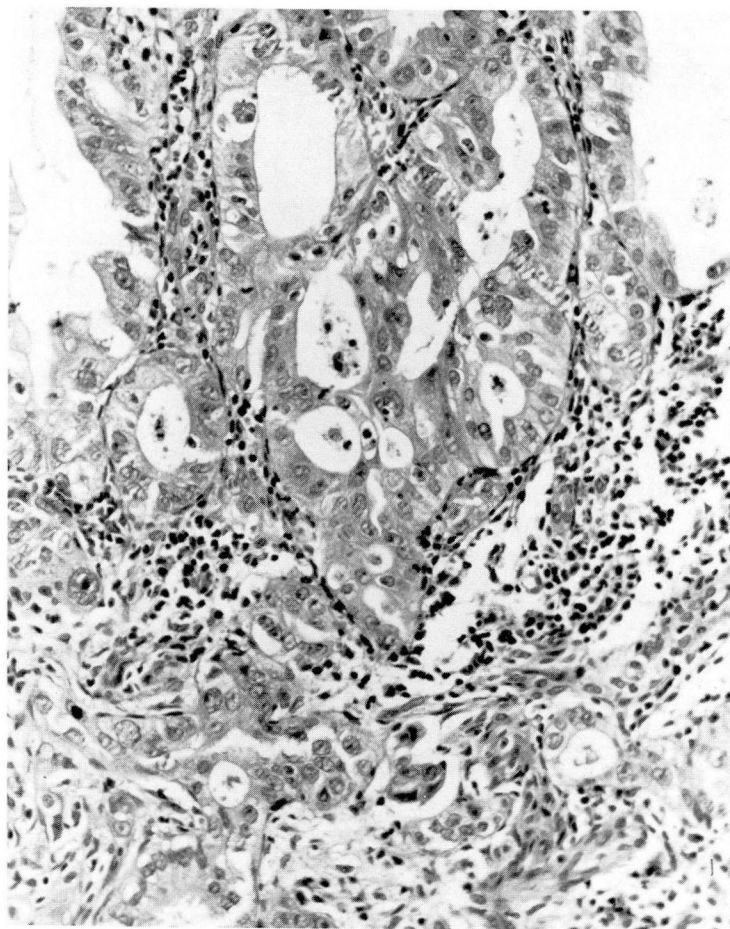


Fig. 5. Colonoscopic biopsy specimen of cecal tumor. Adenocarcinoma growing in a cribriform pattern in mucosa. Less well differentiated adenocarcinoma in lower third of micrograph invades muscularis mucosa and submucosa. (H&E $\times 200$.)

alcian blue material focally present along luminal borders of some tubules. Primary epididymal adenocarcinomas are of such rarity that Mostofi and Price⁷ were not able to document a single case at the time of preparation of the most recent fascicle of the Armed Forces Institute of Pathology *Atlas of Tumor Pathology*.

Adenomatoid tumors of testicular adnexa and other areas are accepted as being of mesothelial origin.⁸⁻¹¹ These tumors may have a tubular, plexiform, or canalicular morphology.⁸ Clear vacuoles are often identifiable in the cell cytoplasm, sometimes producing a spider-web appearance, as was seen in this case (*Fig. 1*). Acid mucopolysaccharides present in the cell cytoplasm of adenomatoid tumors are at least partially digested with hyaluronidase.^{11,12} The intra-

luminal and intracytoplasmic acid mucopolysaccharide in the present case was not appreciably digested with hyaluronidase, favoring a diagnosis of adenocarcinoma and militating against a diagnosis of adenomatoid tumor. Ultrastructural study is useful in distinguishing cells of mesothelial from those of epithelial origin. Adenomatoid tumors show the characteristics of mesothelial cells with lumen formation, long microvilli projecting into free spaces, intracellular vacuoles, desmosomal junctions, tonofilaments, and basement membrane formation.^{13,14} In the present case, the short microvilli, long rootlets, and glycocalyx were not characteristic of a tumor of mesothelial origin. The ultrastructural appearance of the tumor in this case is characteristic of a tumor of colonic origin.^{15,16} At the time this

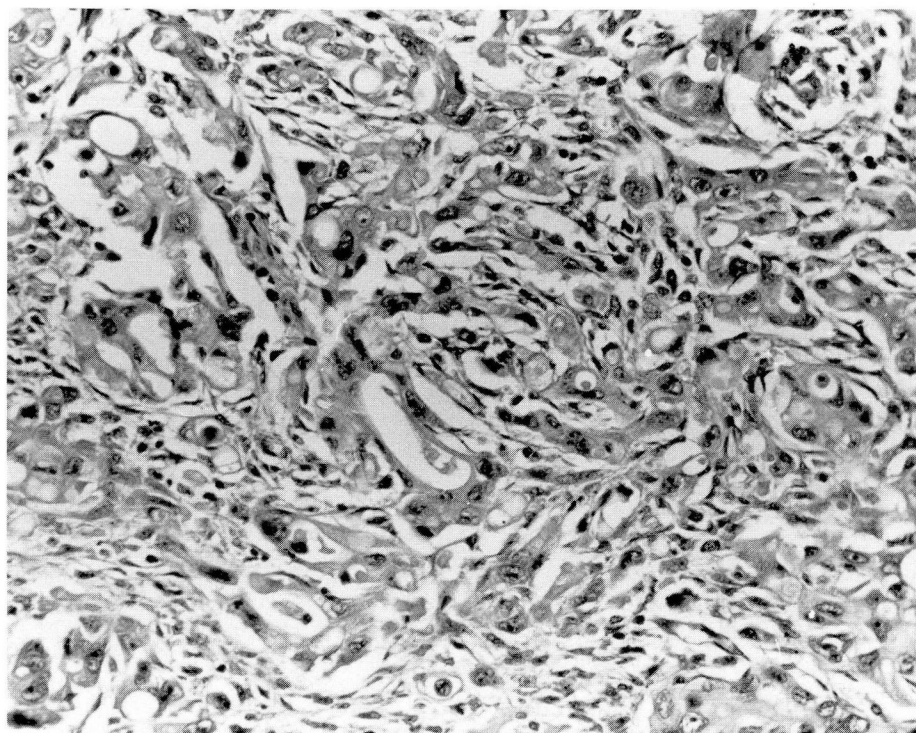


Fig. 6. Colectomy specimen. Infiltration of cecal wall by moderately to poorly differentiated glands. Numerous lumina and intracytoplasmic vacuoles are present. The morphology is similar to Figure 1. (H&E $\times 200$.)

patient was originally seen, the authors did not appreciate the characteristic ultrastructural appearance of colonic adenocarcinoma. Subsequently, the tumor was also studied with immunoperoxidase stains for carcinoembryonic antigen and pronase-treated AE1 and AE3; these studies were markedly positive. Colonic adenocarcinoma stains positively and mesothelial cells stain negatively for carcinoembryonic antigen. All mesothelial and epithelial lesions will stain with monoclonal keratin. Vaginitis nodosum was strongly considered as a diagnosis, partly because of the patient's youth and good health. Vaginitis nodosum consists of a pseudoneoplastic proliferation of ductal structures into connective tissue at the site of previous ligation of the vas deferens. These ducts may show perineural invasion.¹⁷ In other organs perineural invasion may be strongly suggestive or pathognomonic of malignancy. Thus, the presence of perineural invasion per se in this case did not absolutely militate against diagnosis of a benign lesion. The history of vasectomy and an inflammatory reaction were fur-

ther suggestive of vaginitis nodosum. The markedly positive mucin stains and tumor ultrastructure, however, are inconsistent with this diagnosis.

The presentation of this tumor was extremely unusual. The existence of a primary tumor is usually known at the time a metastasis to the testis or testicular adnexa occurs. This patient had a history of vasectomy and was in good health. Notwithstanding, the histologic, ultrastructural, and histochemical findings should have indicated that this was an adenocarcinoma rather than adenomatoid tumor or vaginitis nodosum. Furthermore, the ultrastructural findings have been shown to be characteristic of colonic adenocarcinoma, as is the presence of carcinoembryonic antigen in the tumor cells.^{15,16}

Although only palliative therapy can be given to patients with metastatic tumors, an important reason for accurate diagnosis is to avoid incorrect and unnecessary surgery, radiation, or chemotherapy and to provide accurate prognosis and appropriate therapy. In view of the presentation of the tumor in this case, it is unlikely that the

correct diagnosis at the time of orchiectomy would have significantly altered the clinical course.

Acknowledgment

We express appreciation to James E. Williams, M.D., and Pedro S. Aguilar M.D. for permission to publish this case.

Department of Pathology
Cleveland Clinic Foundation
9500 Euclid Avenue
Cleveland, OH 44106

References

1. Price EB Jr, Mostofi FK. Secondary carcinoma of the testis. *Cancer* 1957; **10**:592-595.
2. Monn L, Poticha SM. Metastatic tumors of spermatic cord. *Urol* 1975; **5**:821-823.
3. Algaba F, Santaularia JM, Villavicencio H. Metastatic tumor of the epididymis and spermatic cord. *Eur Urol* 1983; **9**:56-59.
4. Haupt HM, Mann RB, Trump DL, Abeloff MD. Metastatic carcinoma involving the testis. Clinical and pathological distinction from primary testicular neoplasms. *Cancer* 1984; **54**:709-714.
5. Taxy JB. Vaginitis nodosa. *Arch Pathol Lab Med* 1978; **102**:643-647.
6. Smallman LA, Odedra JK. Primary carcinoma of sigmoid colon metastasizing to epididymis. *Urol* 1984; **23**:598-599.
7. Mostofi FK, Price EB Jr. Tumors and tumor-like conditions of testicular adnexal structures (epididymis, spermatic cord, capsule, and supporting structures). [In] *Tumors of the Male Genital System. Atlas of Tumor Pathology. Second series, fasc. 8.* Washington D.C., Armed Forces Institute of Pathology. 1973; p 143.
8. Taxy JB, Battifora H, Oyasu R. Adenomatoid tumors: A light microscopic, histochemical, and ultrastructural study. *Cancer* 1974; **34**:306-316.
9. Stavrides A, Hutcheson JB. Benign mesotheliomas of testicular appendages: A morphologic and histochemical study of seven cases and review of theories of histogenesis. *J Urol* 1960; **83**:448-453.
10. Nistal M, Contreras F, Paniagua R. Adenomatoid tumour of the epididymis: Histochemical and ultrastructural study of 2 cases. *Brit J Urol* 1978; **50**:121-125.
11. Craig JR, Hart WR. Extragenital adenomatoid tumor: Evidence for mesothelial theory of origin. *Cancer* 1979; **43**:1678-1681.
12. Yasuma T, Saito S. Adenomatoid tumor of the male genital tract. A pathological study of eight cases and review of the literature. *Acta Pathol Jpn* 1980; **30**:883-906.
13. Mackay B, Bennington JL, Skoglund RW. The adenomatoid tumor: Fine structure evidence for a mesothelial origin. *Cancer* 1971; **27**:109-115.
14. Marcus JB, Lynn JA. Ultrastructural comparison of an adenomatoid tumor lymphangioma, hemangioma, and mesothelioma. *Cancer* 1970; **25**:171-175.
15. Dvorak AM, Monahan RA. Metastatic adenocarcinoma of unknown primary site. Diagnostic electron microscopy to determine the site of tumor origin. *Arch Pathol Lab Med* 1982; **106**:21-24.
16. Hickey WF, Seiler MW. Ultrastructural markers of colonic adenocarcinoma. *Cancer* 1981; **47**:140-145.
17. Zimmerman KG, Johnson PC, Paplanus SH. Nerve invasion by benign proliferating ductules in vaginitis nodosum. *Cancer* 1983; **51**:2066-2069.