

Total repair of tetralogy of Fallot in the adult

The Cleveland Clinic experience 1951–1981¹

Mark S. Kreindel, M.D.
Douglas S. Moodie, M.D.
Richard Sterba, M.D.
Carl C. Gill, M.D.

Between 1951 and 1981, 13 adult patients underwent total intracardiac repair of tetralogy of Fallot at the Cleveland Clinic. Mean age at the time of repair was 29.4 years (range 18–44 years). Eighty-five percent of the patients were classified preoperatively as New York Heart Association Functional Class III or IV. Three of the patients had had no previous palliation. Mean duration of follow-up was 49.4 months. There was no early or late mortality. Postoperatively all patients experienced a dramatic fall in right ventricular systolic pressure with no right ventricular outflow tract gradient. Postoperative arrhythmias severe enough to require treatment occurred in only two patients. These findings suggest that an aggressive surgical approach can be undertaken in adults with uncorrected tetralogy of Fallot.

Index terms: Heart defects, congenital • Heart surgery • Tetralogy of Fallot

Cleve Clin Q 52:375–381, Fall 1985

¹ Departments of Cardiology and Thoracic and Cardiovascular Surgery, The Cleveland Clinic Foundation. Submitted for publication Dec 1984; accepted March 1985. ht

0009-8787/85/03/0375/07/\$2.75/0

Copyright © 1985, The Cleveland Clinic Foundation

Tetralogy of Fallot is the most common form of cyanotic congenital heart disease. It is estimated that without surgical intervention, only about 10% of the patients survive beyond 21 years of age.^{1–3} Several studies^{4–8} have examined the adult with tetralogy of Fallot, but few have documented the hemodynamic benefit of surgery. We report our experience with 13 patients who were over the age of 18 years at the time of total intracardiac repair at the Cleveland Clinic Foundation between 1951 and 1981.

The 13 patients in our series included eight males and five females. Three had had no previous palliation. Of the 10 who had undergone previous palliation, six had had

Table 1. Preoperative symptoms

Symptom	No.	%
Cyanosis	11	84.6
Dyspnea on exertion	11	84.6
Fatigue	7	53.8
Restricted activity	3	21.4
Hemoptysis	2	14.3
Pneumonia	2	14.3
Headache	2	14.3
Syncope	1	7.1
Subacute bacterial endocarditis	1	7.1
Cerebrovascular accident	0	0

Table 2. Preoperative physical findings

Finding	No.	%
Cyanosis	11	84.6
Clubbing	10	76.9
Right ventricular lift	9	64.3
Systolic thrill	5	38.5
Systolic click	3	21.5
Single S ₂	8	61.5
Diminished P ₂	4	30.7
S ₄	1	7.1
Systolic murmur	13	100.0
Continuous murmur	4	28.6
Diastolic murmur	0	0

Table 3. Preoperative hemodynamic data

Patient	RVSP (mmHg)	RVOG (mmHg)	PAP (mmHg)
1	82	57	25/15
2			
3	130		
4	130	112	18 (systolic)
5	110		
6	115	90	25/15
7	110	85	25/20
8	115	*	85/65
9	120	100	20 (systolic)
10	95	75	20 (systolic)
11			
12	70	50	20/15
13	125	85	40/25

PAP = pulmonary artery pressure; RVOG = right ventricular out-flow tract gradient; RVSP = right ventricular systolic pressure.

* Previous Potts shunt.

Potts anastomoses and three had had Blalock shunts. One patient had had an aortopulmonary artery graft. Their age at palliation had ranged from 5 months to 19 years. The time from palliation to total repair ranged from 2–30 years with a mean of 19.9 years. The age at intracardiac repair ranged from 18–42 years with a mean of 29.6 years.

Materials and methods

The charts of all patients were examined. In addition to a full clinical evaluation, preoperative assessment included echocardiography (8 patients), right and left ventricular ejection fractions as determined by radionuclide techniques (7 patients), exercise stress testing (7 patients), and holter monitor recordings (2 patients). All patients underwent cardiac catheterization preoperatively, although hemodynamic data were only available in 12.

Nine of the 13 patients returned for postoperative evaluation between January and June 1983. Of the five patients who did not return, three had moved away from the Cleveland area, one patient refused, and one patient was lost to follow-up. The evaluation of three patients who were unable to return was carried out through their local physician.

Postoperative evaluation included echocardiography (11 patients), exercise stress testing (8 patients), nuclear ejection fraction determinations (8 patients), and holter monitor recordings (6 patients). Ten patients underwent repeat catheterization including hemodynamic measurements.

Results

Preoperative findings

Symptoms: Cyanosis (84.6%) and dyspnea on exertion (84.6%) were the most common symptoms prior to total repair. Other less frequent findings are as listed in *Table 1*. On the New York Heart Association Functional classification, one patient was Class I, one was Class II, 10 were Class III, and one was Class IV.

Physical examination: The physical findings are summarized in *Table 2*. Cyanosis was apparent in 84.6% and clubbing was present in 76.9%. None of the patients had congestive heart failure. All patients had a systolic murmur.

Hemoglobin and hematocrit: The preoperative hemoglobin level ranged from 12.3–25.8 g/dl

with a mean of 19.6 g/dl. Hematocrits ranged between 36.5–75.3% with a mean of 58.5%.

Chest radiography: Cardiomegaly was present in five patients (38.5%). Seven (53.8%) patients had evidence of right ventricular enlargement, while only two (15.4%) patients had evidence of left ventricular enlargement. Decreased pulmonary vascularity was apparent in only one (7.7%) patient.

Electrocardiography: Preoperatively, all patients had normal sinus rhythm. Eleven (84.6%) had electrocardiographic evidence of right ventricular hypertrophy. Nine (69.2%) showed right axis deviation. Three (23%) of the patients had complete right bundle branch block and one (7.7%) patient had first-degree atrioventricular block. None of the patients were noted to have premature ventricular contractions (PVCs) on the resting electrocardiogram.

Echocardiography: Eight of the 14 patients had preoperative echocardiography. Seven (87.5%) showed evidence of right ventricular enlargement. In four patients (50%) overriding of the aorta was apparent. Three (37.5%) demonstrated abnormal septal motion. In only one (12.5%) patient was this ventricular septal defect visualized and this patient also demonstrated an atrial septal defect. None of the patients showed either left ventricular or left atrial enlargement.

Radionuclide ejection fraction: Seven patients had preoperative radionuclide ejection fraction determinations. All seven had first-pass right ventricular ejection fraction (RVEF) studies and six had concomitant left ventricular ejection fraction (LVEF) studies. RVEF ranged from 22–50% (normal >45%) with a mean of 38%, while LVEF ranged from 30–70% (normal >50%) with a mean of 56%. All studies were performed at rest.

Exercise stress testing: Seven patients underwent exercise stress testing according to the standard Bruce protocol. Six (85.7%) had normal heart rate and blood pressure response to exercise. The other patient showed a diminished response. Two (28.6%) patients had occasional unifocal PVCs during exercise; none had ventricular tachycardia. None of the patients had ST segment changes or chest pain during exercise.

Holter monitor: Only two patients had preoperative ambulatory electrocardiographic monitoring. One had documented ventricular tachycardia, which was easily inducible during electrophysiologic study, and the other showed only rare unifocal PVCs.

CLEVELAND CLINIC ADULT TETRALOGY OF FALLOT 13 PATIENTS

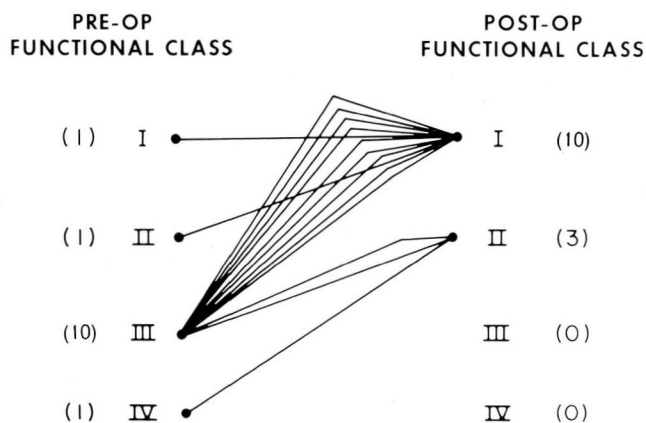


Fig. 1. Preoperative and postoperative New York Heart Association functional class in 13 adult patients.

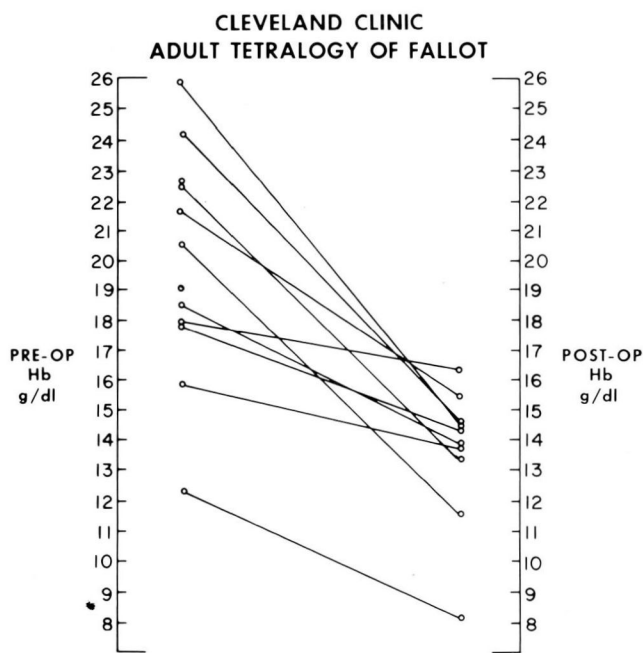


Fig. 2. Fall in hemoglobin (Hb) concentration following total correction of tetralogy of Fallot.

Table 4. Postoperative physical findings

Finding	No.	%
Cyanosis	0	—
Clubbing	4	30.7%
Right ventricular lift	8	61.5%
Thrill	0	—
Click	1	7.7%
Single S ₂	3	23.0%
Decreased P ₂	3	23.0%
S ₄	3	23.0%
Systolic murmur	13	100.0%
Continuous murmur	0	—
Diastolic murmur	4	30.7%

Hemodynamics: Preoperative hemodynamic data were available for 11 of the 13 patients (Table 3). Right ventricular systolic pressure ranged from 70–130 mmHg with a mean of 109 mmHg. One patient had no demonstrable communication between the right ventricle and pulmonary artery and survived because of a previous Potts shunt. Right ventricular outflow tract gradient was measured in nine of the patients. The gradient ranged from 50–112 mmHg with a mean of 76.5 mmHg. Pulmonary artery pressures were measured in 10 patients. Systolic pressures ranged from 18–85 mmHg with a mean of 29.8 mmHg, while diastolic pressures ranged from 15–65 mmHg with a mean of 28.8 mmHg.

Surgical procedure: All functioning aortopulmonary shunts were surgically closed and one

patient had closure of a patent ductus arteriosus. Twelve (92.3%) patients had pulmonary infundibulectomy and all ventricular septal defects were closed by a patch. Six patients had excision of their pulmonary valve; four of these had pulmonary valve replacement. Eight (61.5%) of the patients required a right ventricular outflow tract patch and two of these were extended across the pulmonary annulus without valve replacement. In two patients, a right ventricular-to-pulmonary artery valve conduit was inserted. Three (21.5%) of the patients had closure of an atrial septal defect.

Surgical mortality: There was no early or late mortality in our series of 13 patients undergoing total intracardiac repair for tetralogy of Fallot as adults.

Postoperative findings

Follow-up after total repair ranged between 2 months and 11 years with a mean of 49.4 months.

Symptoms: Following total repair, none of the patients were cyanotic and only two (15.4%) complained of dyspnea on exertion. All patients had dramatic improvement in their functional capabilities (Fig. 1). Ten of the patients were New York Heart Association Functional Class I and three (23%) were Functional Class II.

Physical examination: All patients had a systolic murmur and four (30.7%) patients had a diastolic murmur. Eight (61.5%) patients had a palpable right ventricular lift. Clubbing persisted in four (30.7%) patients. The remainder of the postoperative physical findings are presented in Table 4.

Hemoglobin and hematocrit: Following total repair, a significant fall of hemoglobin and hematocrit levels from preoperative levels was noted (Fig. 2). Postoperative hemoglobin levels ranged from 8.0–16.4 g/dl with a mean of 13.7 g/dl, while hematocrit ranged from 23.6–46.7% with a mean of 40.4%.

Chest radiography: Vascularity was thought to be normal in 11 (84.6%) patients. Seven (53.8%) had evidence of cardiomegaly, five (38.5%) had right ventricular enlargement, and one (7.7%) had left ventricular enlargement.

Electrocardiography: All but one patient (92.3%) remained in sinus rhythm postoperatively. The one exception had atrial fibrillation. Ten (76.9%) patients had a pattern of complete right bundle branch block. One patient showed incomplete right bundle branch block, one pa-

Table 5. Postoperative hemodynamic data

Patient	RVSP (mmHg)	RVOG (mmHg)	MPAP (mmHg)
2	75	40	55*
3	45	—	38
4	31	0–4	26
7	32	—	36
8	50	—	35
9	30	—	30
11	50	—	30
12	30	—	—
13	30	—	18
14	34	—	24†

MPAP = mean pulmonary artery pressure; RVOG = right ventricular outflow gradient; RVSP = right ventricular systolic pressure.

* Residual ventricular septal defect requiring second operation for closure.

† Residual ventricular septal defect 8 months postoperatively, trivial at 3 years.

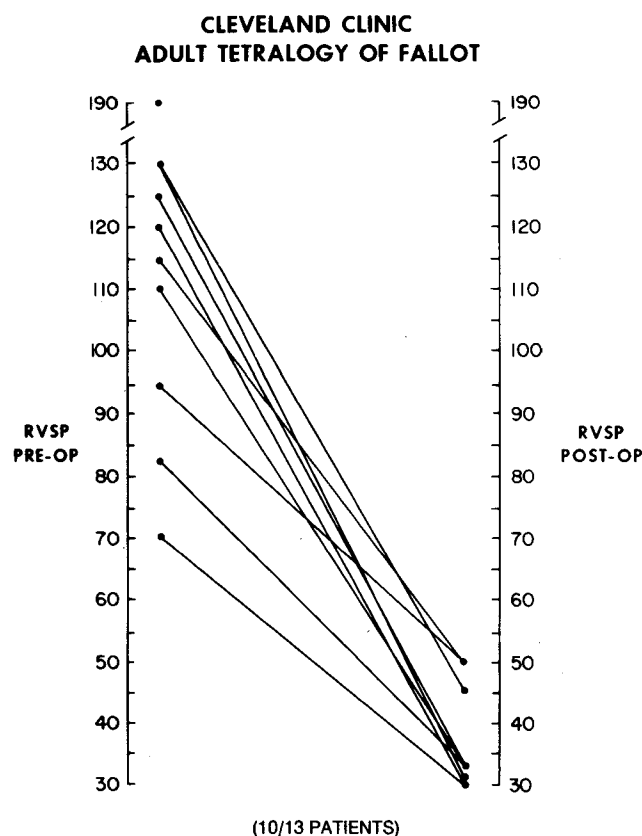


Fig. 3. Comparison of preoperative and postoperative right ventricular systolic pressures (RVSP).

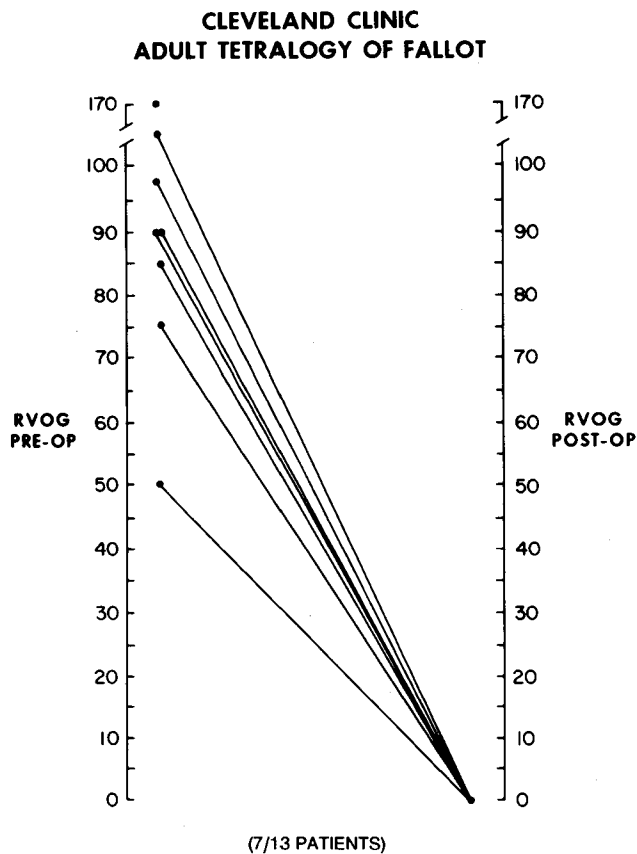


Fig. 4. Comparison of preoperative and postoperative right ventricular outflow tract gradients (RVOG).

tient showed first-degree atrioventricular block, and one had complete right bundle branch block and left anterior hemiblock. None of the patients demonstrated ventricular premature beats on routine electrocardiography.

Echocardiography: Eleven of the 13 patients were assessed echocardiographically during follow-up. Ten (91%) demonstrated abnormal septal motion, seven (63.6%) had right ventricular enlargement, and three (27.3%) showed evidence of left ventricular enlargement. One patient was noted to have mitral valve prolapse.

Radionuclide ejection fraction: Eight of 13 patients had left and right ejection fraction determinations by radionuclide technique. Postoperative right ventricular ejection fraction ranged from 27–53% with a mean of 45%, while left ventricular ejection fraction ranged from 41–63% with a mean of 50.3%.

Exercise stress testing: Eight patients were assessed postoperatively by exercise stress testing

according to the standard Bruce protocol. All had normal heart rate and blood pressure responses. Three patients had ventricular premature beats induced by exercise; of these, two had occasional unifocal PVCs and one patient had multifocal PVCs with couplets. None of the patients demonstrated ST segment changes or had chest pain during exercise.

Holter monitor: Of the eight patients assessed postoperatively by ambulatory electrocardiographic monitoring, seven demonstrated sinus rhythm while one remained in atrial fibrillation. Five patients demonstrated ventricular premature beats, only two of which required treatment. One patient had PACs and 1 showed a 20-beat run of paroxysmal supraventricular tachycardia. One patient had periods of Type II second-degree atrioventricular conduction.

Hemodynamics: Postoperative hemodynamic data were available in 10 of the 14 patients and are summarized in Table 5. All but one patient

showed a marked reduction in right ventricular systolic pressure (*Fig. 3*) and virtually no gradient across the right ventricular outflow tract (*Fig. 4*). One patient demonstrated persistently elevated right ventricular systolic pressure postoperatively (75 mmHg) with a 40-mmHg outflow tract gradient. This individual was subsequently found to have a residual ventricular septal defect and required a second operation for closure. Another patient was thought to have a residual ventricular septal defect at 8 months postoperatively, but 3 years later this was thought to have undergone spontaneous closure.

Discussion

Controversy exists with regard to the actual operative mortality in the adult undergoing total repair of tetralogy of Fallot. Previous studies^{7,9-12} reported mortalities ranging from 0-29%. In our experience with 13 adult patients, three of whom had no previous palliation, there was no operative mortality. Although no single reason is known, previous reports have ascribed this mortality to a poor hemodynamic result, endocarditis, pulmonary edema, hemorrhage, and neurologic complications. None of the 13 patients in our series had any of these complications. One possible explanation for the improved hemodynamics and no mortality in our series is the proved dramatic fall in right-sided pressures postoperatively. In addition, nine patients had a competent pulmonary valve. Of the four patients with a postoperative diastolic murmur, two had had a pulmonic valvulotomy at the time of surgery and two had the pulmonary valve excised.

In recent years, sudden death has become a recognized late complication in patients undergoing total repair of tetralogy of Fallot. Kulbertus et al^{13,14} were the first to report the association between right bundle branch block and left anterior hemiblock with intracardiac repair of tetralogy of Fallot. Concern was expressed at that time about the possibility of late complete heart block. Wolf et al¹⁵ and Moss et al¹⁶ noted an increased incidence of late complete heart block and sudden death in these patients. In a report by Cairns et al¹⁷ 75% of patients with late-onset complete heart block could be demonstrated to have had early transient complete heart block postoperatively. However, more recent studies suggest that patients manifesting ventricular arrhythmias are at higher risk for sudden death.¹⁸⁻²¹ Garson et al⁵ noted the association

between ventricular premature beats and elevated right ventricular systolic or end diastolic pressure and their presence in the postoperative period, which was thought to represent a poor surgical result. Thirty-eight percent of their patients with documented ventricular premature beats in the postoperative period later died suddenly. However, Tamer et al²² refuted the association between ventricular premature beats, sudden death, and residual right ventricular systolic hypertension, and thought that it might reflect the poor tolerance of patients with impaired hemodynamic function to the circulatory effects of arrhythmias. In addition, two studies^{22,23} showed ventricular dysrhythmias in patients undergoing repair at an older age, possibly reflecting progressive fibrotic change in a right ventricle previously subjected to a prolonged period of systemic level hypertension. The ventriculotomy scar itself may well lead to localized increased automaticity in the development of a re-entrant mechanism for ventricular tachycardia.²⁴⁻²⁷ Eight of our patients received a right ventricular outflow tract patch and this may contribute to the low incidence of postoperative arrhythmias, inasmuch as the patch may interrupt any latent reentry mechanism. Three of our patients demonstrated ventricular dysrhythmias preoperatively as assessed by electrocardiography, ambulatory electrocardiography, or exercise stress testing. Only two of our 13 patients who had ventricular premature beats postoperatively, detected by ambulatory electrocardiographic monitoring, exercise stress testing, or both, required treatment. Perhaps the low incidence of postoperative ventricular premature beats in our series reflects the lower right ventricular systolic pressures when compared with previous studies.⁵ Even in the presence of low right ventricular systolic pressures, two of our patients required treatment for postoperative ventricular premature beats. We therefore think that the association between postoperative ventricular premature beats and right ventricular systolic pressure is tenuous. If right ventricular fibrosis and scarring are to be implicated as causative factors of ventricular irritability, further long-term follow-up will be necessary.

Finally, we have demonstrated a significant hemodynamic and symptomatic benefit in adults undergoing total intracardiac repair of tetralogy of Fallot. All of our patients experienced a dramatic reduction in right ventricular systolic pres-

sure and right ventricular outflow tract gradient, an improved RVEF, and improved physical work capacity.

We conclude, therefore, that (1) adults can safely undergo total intracardiac repair of tetralogy of Fallot with no operative mortality, (2) patients demonstrate dramatic improvement in symptoms, hemodynamics, and exercise capability following such intracardiac repair, and (3) postoperative evaluation should include electrocardiography, exercise stress testing, and ambulatory electrocardiographic monitoring in order to identify those patients in whom ventricular arrhythmias may develop. Based on our data, aggressive surgical therapy in adult patients with uncorrected tetralogy of Fallot should be pursued.

Douglas S. Moodie, M.D.
Department of Cardiology
Cleveland Clinic Foundation
9500 Euclid Avenue
Cleveland, Ohio 44106

References

- Freisinger GC, Bahnson HT. Tetralogy of Fallot. Report of case with total correction at 54 years of age. *Am Heart J* 1966; **71**:107-111.
- Holladay WE, Witham AC. The tetralogy of Fallot. *Arch Int Med* 1957; **100**:400-414.
- Higgins CB, Mulder DC. Tetralogy of Fallot in the adult. *Am J Cardiol* 1972; **29**:837-846.
- Abraham KA, Cherian G, Rao VD, Sukumar IP, Krishnaswami S, John S. Tetralogy of Fallot in adults. A report on 147 patients. *Am J Med* 1979; **66**:811-816.
- Garson A Jr, Nihill MR, McNamara DG, Cooley DA. Status of the adult and adolescent after repair of tetralogy of Fallot. *Circulation* 1979; **59**:1232-1240.
- Garson A, McNamara DG, Cooley DA. Tetralogy of Fallot in adults. *Cardiovasc Clin* 1979; **10**:341-364.
- Beach PM, Bowman FO, Kaiser GA, Malm JR. Total correction of tetralogy of Fallot in adolescents and adults. *Circulation* (suppl I) 1971:37-44.
- Abraham KA, Cherian G, Sukumar IP, Krishnaswami S, John S. Haemodynamics in adult tetralogy of Fallot. *Indian Heart J* 1979; **31**:88-91.
- Ochsner JL, Jordan JD, Moore CB. Congenital heart disease in adults. *Southern Med J* 1967; **60**:164-170.
- Cooley DA, Hallman GL, Hamman AS. Congenital cardiovascular anomalies in adults. Result of surgical treatment in 167 patients over age 35. *Am J Cardiol* 1966; **17**:303-309.
- Aytac A, Saylam A, Yurdakul Y, Ikizler C, Olga R. Total correction for tetralogy of Fallot in adolescents and adults. *Turk J Pediatr* 1980; **22**:45-49.
- Charles RG, Commerford PJ, Beck W, Barnard CN. Tetralogy of Fallot in adults—clinical features and long term surgical results. *Br Heart J* 1982; **47**:195.
- Kulbertus H, Coyne J, Hallidie-Smith KA. Left axis deviation with right bundle-branch block in ventricular septal defect before and after surgical closure. *Br Heart J* 1968; **30**:422-423.
- Kulbertus HE, Coyne JJ, Hallidie-Smith KA. Conduction disturbances before and after surgical closure of ventricular septal defect. *Am Heart J* 1969; **77**:123-131.
- Wolff GS, Rowland TW, Ellison RC. Surgically induced right bundle-branch block with left anterior hemiblock. An ominous sign in postoperative tetralogy of Fallot. *Circulation* 1972; **46**:587-594.
- Moss AJ, Klyman G, Emmanouilides GC. Late onset complete heart block: newly recognized sequela of cardiac surgery. *Am J Cardiol* 1972; **30**:884-887.
- Cairns JA, Dobell ARC, Gibbons JE, Tessler I. Prognosis of right bundle branch block and left anterior hemiblock after intracardiac repair of tetralogy of Fallot. *Am Heart J* 1975; **90**:549-554.
- Gillette PC, Yeoman MA, Mullins CE, McNamara DG. Sudden death after repair of tetralogy of Fallot: Electrocardiographic and electrophysiologic abnormalities. *Circulation* 1977; **56**:566-571.
- Quattlebaum TG, Varghese PJ, Neill CA, Donahoo JS. Sudden death among postoperative patients with tetralogy of Fallot. A follow-up study of 243 patients for an average of twelve years. *Circulation* 1976; **54**:289-293.
- James FW, Kaplan S, Chou TC. Unexpected cardiac arrest in patients after surgical correction of tetralogy of Fallot. *Circulation* 1975; **52**:691-695.
- Garson A Jr, Gillette PC, Gutgesell HP, McNamara DG. Stress-induced ventricular arrhythmia after repair of tetralogy of Fallot. *Am J Cardiol* 1980; **46**:1006-1012.
- Tamer D, Wolff GS, Ferrer P, et al. Hemodynamics and intracardiac conduction after operative repair of tetralogy of Fallot. *Am J Cardiol* 1983; **51**:552-556.
- James FW, Kaplan S, Schwartz DC, Chou TC, Sandler ET, Naylor V. Response to exercise in patients after total surgical correction of tetralogy of Fallot. *Circulation* 1976; **54**:671-679.
- Horowitz LN, Vetter VL, Harken AH, Josephson ME. Electrophysiologic characteristics of sustained ventricular tachycardia occurring after repair of tetralogy of Fallot. *Am J Cardiol* 1980; **46**:446-452.
- Byrum CS, Dick M, Stein A, Rosenthal A. Mechanism and therapy of exercise-induced ventricular tachycardia after repair of tetralogy of Fallot. Proceedings of the 49th Scientific Sessions of the American Academy of Pediatrics, Detroit, 1980, p 14.
- Kavey REW, Blackman MS, Sondheimer HM. Incidence and severity of chronic ventricular dysrhythmias after repair of tetralogy of Fallot. *Am Heart J* 1982; **103**:342-350.
- Kavey REW, Blackman MS, Sondheimer HM. Ventricular dysrhythmias after repair of tetralogy of Fallot (abstr). *Circulation* 1980; **62**(suppl III):III-72.