

The initial case at The Cleveland Clinic Foundation of the automatic implantable cardioverter-defibrillator and review of the literature¹

Marilyn King-Rankine, M.D.
James D. Maloney, M.D.
Leonard A. R. Golding, M.D.
Richard Morris, R.N.

A survivor of multiple cardiac arrest unresponsive or partially responsive to pharmacologic therapy received an automatic implantable defibrillator-cardioverter (AID-B) on May 7, 1984. Six months after implantation, the patient was alive and had had nine spontaneous episodes of ventricular tachycardia that were automatically converted. The device has been implanted in more than 300 patients at other centers between 1980 and May 1984. Clinical trials are still in progress and the results to date are favorable. The AID-B is emerging as an adjunct to the treatment of lethal ventricular arrhythmias.

Index terms: Arrhythmia, therapy • Case reports
• Electric countershock

Cleve Clin Q 52:75-80, Spring 1985

Cobb et al¹ have demonstrated that approximately two thirds of all patients experiencing sudden death die outside the hospital. In most cases, sudden cardiac arrest represents electrical

instability presenting as ventricular tachycardia and culminating in ventricular fibrillation²—a potentially reversible arrhythmia. These observations led Mirowski et al^{3,4} to originally propose the concept of the automatic implantable defibrillator (AID), the design of which was subsequently modified to an automatic implantable cardioverter-defibrillator (AICD) system.⁵ After more than a decade of preclinical testing, the first human implant took place on February 4, 1980, at The Johns Hopkins Hospital in Baltimore.⁶ As of May 1984, more than 300 patients have received this device. We report our initial case and early follow-up.

Material and Methods

Equipment

We used the automatic implantable cardioverter-defibrillator (AID-B, Intec Systems, Pittsburgh), consisting of a pulse generator and three leads. The pulse generator is hermetically sealed in a titanium case. Special batteries characterized by low internal impedance and high energy density provide an estimated monitoring life of three years or a capability of delivering over 100 discharges. The device weighs 298 g and has a volume of 162 mL (*Fig. 1*). The two defibrillation lead electrodes, which are also sensors, are the

¹ Departments of Cardiology (M.K.-R., J.D.M., R.M.) and Thoracic and Cardiovascular Surgery (L.A.R.G.), The Cleveland Clinic Foundation. Submitted for publication Sept 1984; revision accepted Jan 1985.

1p

0009-8787/85/01/0075/06/\$2.50/0

Copyright © 1985, The Cleveland Clinic Foundation

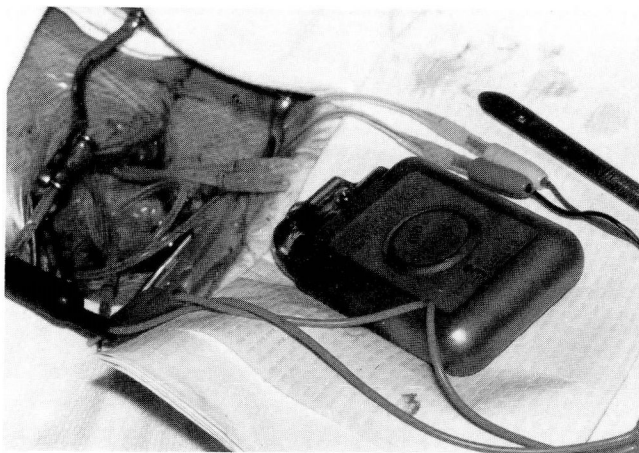


Fig. 1. Pulse generator on operative field. Note the size compared to the scalp.

superior vena cava lead electrode designed for transvenous placement with the tip in the middle of the right atrium and the epimyocardial flexible patch for placement on the apex of the heart. A right ventricular endocardial bipolar lead is used for rate counting and R-wave synchronization. Two epicardial leads may be used instead of this transvenous bipolar lead.

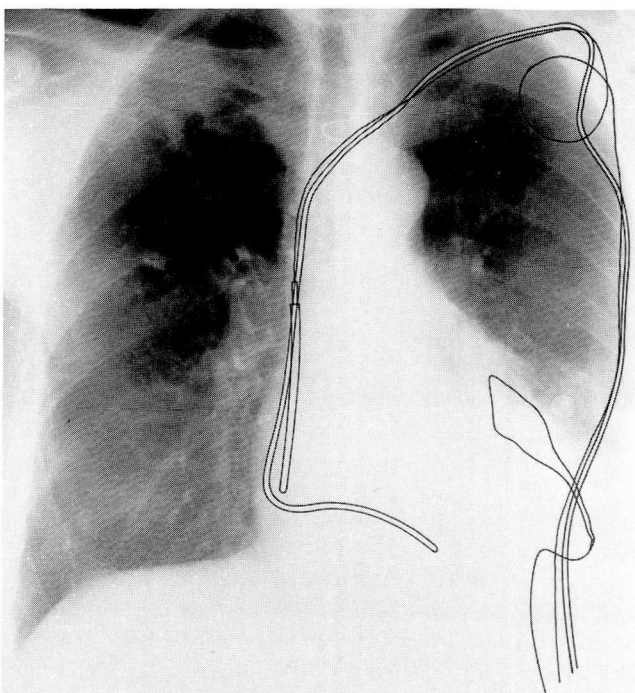


Fig. 2. Chest radiograph shows the patch lead on the ventricular apex, the bipolar lead in the right ventricular apex, and the spring lead in the right atrium. The leads have been redrawn for clarity.

Operation of the AID Check B

An external analyzer system (AID Check B) is used to noninvasively monitor the AICD system before, during, and after implantation.⁷ A display indicates the number of defibrillating shocks received by the patient and the length of time it takes to charge the AICD. Proper placement of a magnet over the device initiates the noninvasive magnet test and can activate and deactivate the AICD. The arrhythmia detectors constantly monitor the ventricular rate (right ventricular lead) and the morphology of ventricular electrical activity (the superior vena cava/patch electrode system). The morphology of ventricular activity is characterized by the probability density function. In sinus rhythm, most of the signal input, such as the PR and TP intervals, is at the baseline. However, in ventricular fibrillation, the signal input is rarely at the baseline. This absence of isoelectric activity fulfills the PDF criterion. The tachy-detection algorithm incorporates both PDF as well as rate. Both these criteria must be met for the AICD to function. The total elapsed time from onset of malignant arrhythmia to delivery of the first shock is approximately 10–30 seconds, depending on the arrhythmia and energy delivered. The initial pulse is approximately 25 J. If this discharge is ineffective, the device recycles for three more shocks, the last three pulses increasing to 30 J. The precise output can be adjusted if a specifically high output is needed. Thirty-five seconds of nonfibrillatory rhythm are required to reset the device after a set of four shocks.

Surgical implantation

Watkins et al⁸ described the initial surgical implantation of an automatic defibrillator. The superior vena cava lead and the right ventricular endocardial electrode are usually introduced percutaneously via the subclavian veins and positioned under fluoroscopy. The patch lead may be sutured to the cardiac apex or the posterior left ventricular wall (*Fig. 2*).

An alternative approach is to use two epimyocardial patch leads, one on each ventricle. Although a left lateral thoracotomy is the usual access route, patch placement can be performed using a median sternotomy, subxiphoid, or subcostal approach. The transvenous and epimyocardial leads are then tunneled to a paraumbilical pocket (*Fig. 3*), analyzed for thresholds, and connected to the generator.

Case report

Our patient, a 60-year-old white man, with a history of inferior and anterior myocardial infarction, presented to the Cleveland Clinic on August 27, 1981. Prolonged electrocardiographic (ECG) monitoring and electrophysiological study documented spontaneous and inducible ventricular tachycardia despite therapeutic dosages of disopyramide and procainamide hydrochloride. Cardiac catheterization revealed marked left ventricular impairment, absence of aneurysm, and severe triple vessel coronary artery disease; however, he was not considered a surgical candidate for revascularization. Although initial observation with lidocaine suggested suppressibility of ventricular ectopy, clinical trials of mexiletine and tocainide were ineffective, as was serial electrophysiological drug testing.

In March 1982, the patient was admitted to another hospital after a "seizurelike" episode. On reevaluation, vulnerability to spontaneous ventricular tachycardia/ventricular fibrillation was identified despite combinations of various antiarrhythmic agents; therefore, myocardial revascularization and electrophysiological-guided subendocardial resection of the tachycardia substrate were performed on September 30, 1982. The earliest area of activation was found in the midposterior septum, a location prohibiting complete subendocardial resection of the heterogeneous scar. Electrophysiological drug testing with amiodarone, postoperatively, revealed inducible ventricular tachycardia; although, clinically, partial control of ventricular tachycardia was achieved with amiodarone and propranolol. Unfortunately, severe pulmonary toxicity secondary to amiodarone developed one year later and necessitated discontinuance of the drug.

Despite subsequent trials with all conventional and other investigational drugs, recurrent sustained ventricular tachycardia at a rate of 180 to 220 beats/minute occurred every one to two months. On April 21, 1984, an external transvenous cardioverter (Medtronic 5350) was used in the Cardiac Care Unit of the Cleveland Clinic to manage repetitive episodes of ventricular tachycardia/ventricular fibrillation. The patient underwent transvenous cardioversion and defibrillation more than 20 times that day. Because of the ineffectiveness of these measures to control the ventricular tachycardia/ventricular fibrillation, it was decided to proceed with implantation of the AICD.

On May 7, 1984, the patient was taken to the Electrophysiology Laboratory and the transvenous superior vena cava lead and right ventricular bipolar lead were placed percutaneously via the left subclavian vein under fluoroscopic control. The following day, a left lateral thoracotomy incision was made, the left ventricle was exposed, and the epimyocardial patch lead was placed. Defibrillation thresholds were determined by multiple inductions of ventricular tachycardia/ventricular fibrillation using alternating current.⁹ The tachycardia recognition and charge time was 13 seconds followed by delivery of 27 J from the AICD with successful cardioversion (Fig. 4).

Early postoperative recovery was uneventful, and the AICD was retested in the Electrophysiology Laboratory on the fourth postoperative day. Alternating current was used to induce tachycardia. The device successfully terminated the hemodynamically unstable rapid ventricular tachycardia. This was perceived by the patient as something suddenly striking him in the chest—a painful but tolerable event. He was discharged from the hospital to be followed up every

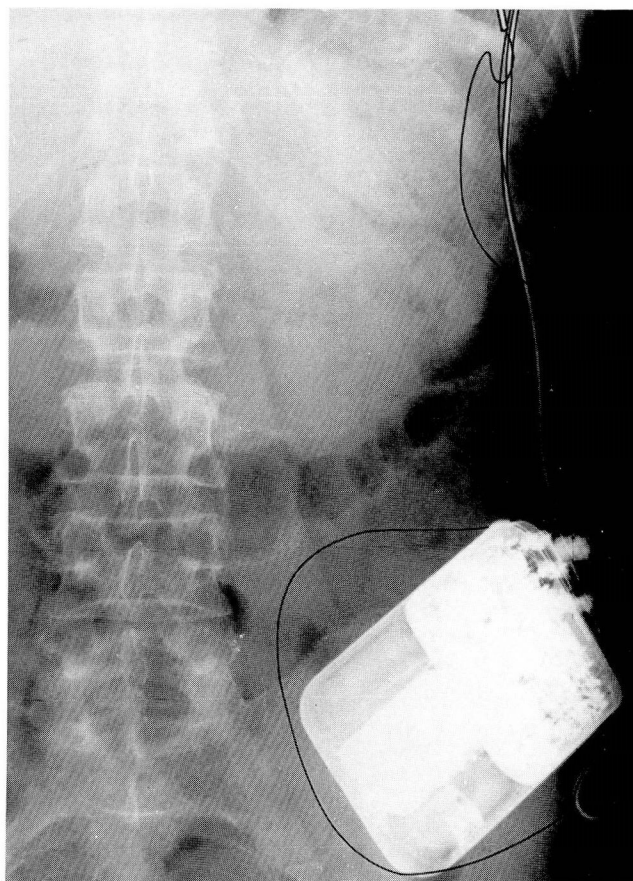


Fig. 3. Abdominal radiograph with the generator in a paramedian pocket. The leads have been redrawn for clarity.

two months for the first year and every month thereafter as an outpatient

Six weeks after implantation, the patient experienced a near syncope episode at home followed by a witnessed observation of much musculoskeletal activity and subsequent sense of well being by the patient. He was hospitalized for 10 days for readjustment of his medicines. While in the hospital, two spontaneous episodes of rapid ventricular tachycardia were converted by the AICD. During the subsequent four months, the patient experienced five additional cardioversion-defibrillation events.

Discussion

It has been estimated that 400,000 deaths occur annually from malignant ventricular arrhythmias. Available data suggest that many of these patients can be protected by proper selection of antiarrhythmic agents with techniques such as electrophysiological study. However, for the significant number who fail to respond to antiarrhythmic therapy, electrophysiological-guided endocardial resection, and other available thera-

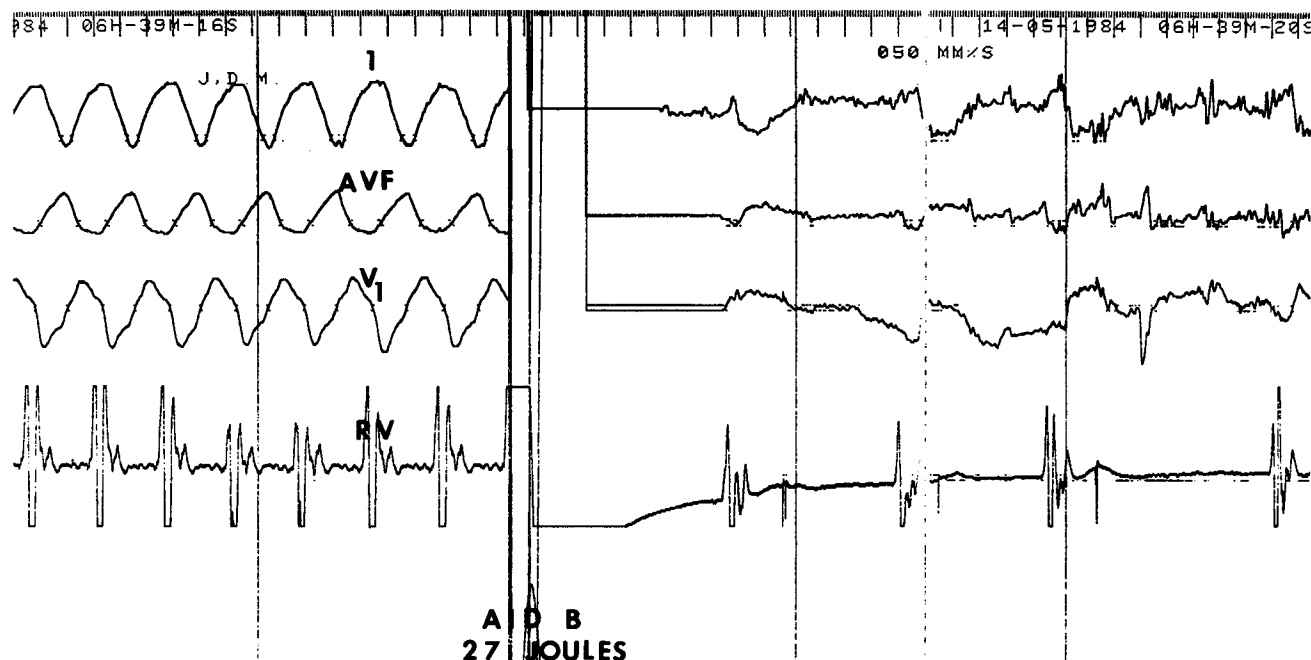


Fig. 4. Patient in ventricular flutter terminated by AID-B. Musculoskeletal activity is noted on surface ECG leads after cardioversion. I, AVF, V1 are the standard ECG leads. RV = right ventricular intracardiac recording.

peutic modalities, AICD provides protection from episodes of otherwise lethal ventricular arrhythmias.

The initial criteria for the clinical use of the investigational AICD (AID) were stringent. The patient requirements included survival of at least two cardiac arrest episodes not associated with acute myocardial infarction. Malignant ventricular tachycardia/ventricular fibrillation had to be electrocardiographically documented on at least one occasion despite antiarrhythmic therapy. The criteria has now been relaxed, and at present, only one episode of spontaneous ventricular tachycardia/ventricular fibrillation is required, along with additional evidence of drug refractoriness and inducibility of ventricular tachycardia/ventricular fibrillation at electrophysiological study.

Although there are no known contraindications at this time to the implantation of the AICD, careful patient selection is essential. Clinical protocol is limited to the previously described patient population. The efficacy and safety of the device are still being investigated. There is patient awareness of the implanted device. The surgical risk, although minimal, is present, as well as the risk of malfunction. The device, therefore,

should not be implanted in every patient with ventricular tachycardia. The AICD's rate criteria must be carefully selected in relationship to the patient's potential for sinus tachycardia and the expected rates of paroxysmal ventricular tachycardia.

In 1983, Watkins et al¹⁰ published a three-year report of the 65 cardiac arrest survivors who received implantation of the AID and AID-B devices. The AID-B device has been used since April 1982. The patients were divided into two groups. Group 1 consisted of 37 patients who underwent implantation of the device alone via thoracotomy or the subxiphoid technique. There were no surgical deaths. Twenty-eight patients in group 2 underwent implantation of the defibrillator combined with coronary artery bypass grafting in 7, coronary artery bypass grafting and mitral valve replacement in 4, and endocardial resection and aneurysmectomy in 17. In group 2, there were 4 operative deaths. One patient required reexploration for mediastinal bleeding. Forty-four spontaneous out-of-hospital resuscitations occurred in 11 group 1 patients, and 4 out-of-hospital resuscitations occurred in 2 group 2 patients. Using the Kaplan-Meier method of analysis, Watkins et al¹⁰ found that the one-year

survival rates in group 1 increased from 45% to 75% and in group 2 patients from 80% to 95% (Fig. 5). The AICD seemed to increase survival when implanted alone or in combination with other surgical cardiac procedures.

In the earlier models of the AID device, design problems led to certain operative deficiencies. Design modification included a bipolar right ventricular catheter for efficient rate counting and right-ventricle synchronizing (AID-B). R-wave synchronizing ensures delivery of the shock outside the vulnerable part of the cardiac cycle. This minimizes the likelihood of acceleration of the arrhythmia.

The model AID-B was implanted in a series of 12 patients with ventricular tachycardia resistant to surgical and medical therapy.¹¹ The device successfully converted malignant ventricular tachycardia in all 12 patients. In 9 of 12 patients, this was done with a single discharge. In three cases, a second pulse restored the patient to sinus rhythm. In no case was there acceleration of the ventricular tachycardia or degeneration to ventricular fibrillation. Animal studies revealed that the mean defibrillation threshold (the lowest energy measured in joules required to successfully defibrillate the patient in 100% of the trials) of the spring and patch leads did not change significantly over 54 weeks.¹² Therapeutic doses of digoxin, procainamide, or propranolol had no effect on the defibrillation threshold.¹³ Six dogs underwent 200 defibrillation attempts before they were killed. Histologically, there was no damage to the ventricular myocardium, the intima of the superior vena cava, or the endocardium of the right atrium.

In one series of 52 patients followed for three years with a mean follow-up of 14.4 months, there were 12 deaths.¹⁴ Eight deaths were secondary to the underlying disease, and four deaths were not witnessed and thought to be secondary to arrhythmia. Autopsies performed in 8 of these patients confirmed absence of myocardial damage secondary to the implanted device.

As of May 1982, two devices have been explanted because of infection. One patient experienced venous insufficiency of the upper extremity for three days. Current deficiencies of the device include lack of back up pacing, large size, and absence of programmability. With further clinical experience, there will be technological changes. The results to date are encouraging. The device should play a complementary role with antiarrhythmic drugs and/or surgery.

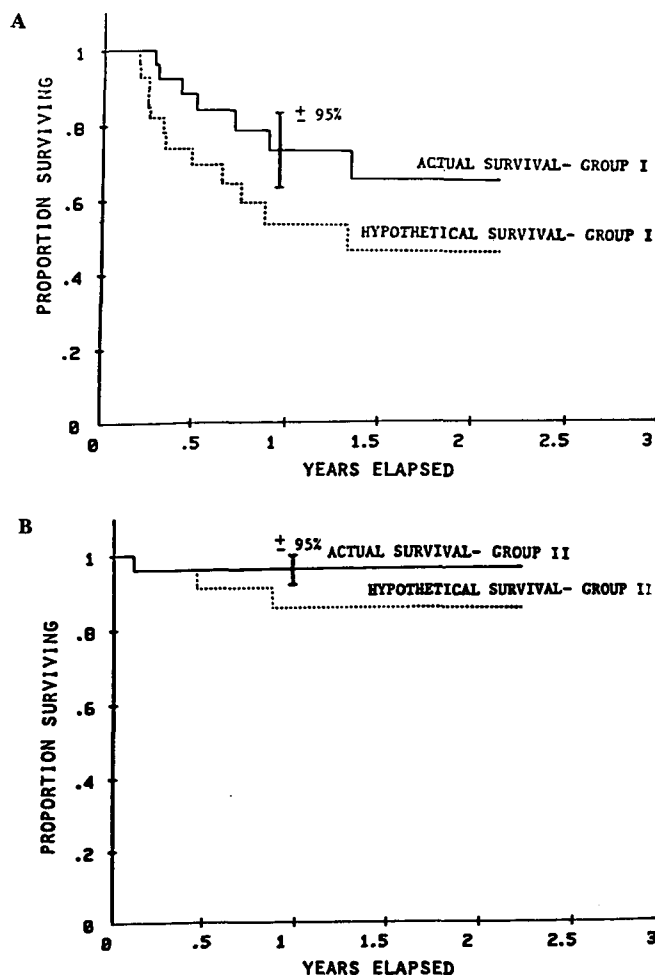


Fig. 5. Group 1 survival at one and two years (A) and group 2 survival at one and two years (B), as reported by Watkins et al.¹⁰

This figure is reproduced with permission from the C. V. Mosby Company.

Conclusion

The AICD is not the definitive treatment for recurrent ventricular arrhythmias, but is a practical alternative for a select group of high-risk patients.

James D. Maloney, M.D.
Department of Cardiology
The Cleveland Clinic Foundation
9500 Euclid Ave.
Cleveland OH 44106

References

1. Cobb LA, Werner JA, Trobaugh GB. Sudden cardiac death. I. A decade's experience with out-of-hospital resuscitation. *Mod Concepts Cardiovasc Dis* 1980; **49**:31-36.
2. Lown B, Wolf M. Approaches to sudden death from coronary heart disease. *Circulation* 1971; **44**:130-142.

3. Mirowski M, Mower MM, Staewen WS, Tabatznik B, Mendeloff AI. Standby automatic defibrillator: an approach to prevention of sudden coronary death. *Arch Intern Med* 1970; **126**:158–161.
4. Mirowski M, Mower MM, Staewen WS, Denniston RH, Mendeloff AI. The development of the transvenous automatic defibrillator. *Arch Intern Med* 1972; **129**:773–779.
5. Winkle RA, Bach SM Jr, Echt DS, et al. The automatic implantable defibrillator: local ventricular bipolar sensing to detect ventricular tachycardia and fibrillation. *Am J Cardiol* 1983; **52**:265–270.
6. Mirowski M, Reid PR, Mower MM, et al. Termination of malignant ventricular arrhythmias with an implanted automatic defibrillation in human beings. *N Engl J Med* 1980; **303**:322–324.
7. Intec Operation Manual for the AID®-B. Pittsburgh, Intec Systems.
8. Watkins L Jr, Mirowski M, Mower MM, et al. Automatic defibrillation in man: the initial surgical experience. *J Thorac Cardiovasc Surg* 1981; **82**:492–500.
9. Mower MM, Reid PR, Watkins L Jr, Mirowski M. Use of alternating current during diagnostic electrophysiologic studies. *Circulation* 1983; **67**:69–72.
10. Watkins L, Mower MM, Reid PR, Platia EV, Griffith LS, Mirowski M. Trials of the automatic implantable defibrillator in man: a three-year program report. *J Thorac Cardiovasc Surg* 1983; **86**:381–387.
11. Reid PR, Mirowski M, Mower MM, et al. Clinical evaluation of the internal automatic cardioverter-defibrillator in survivors of sudden cardiac death. *Am J Cardiol* 1983; **51**:1608–1613.
12. Deeb GM, Griffith BP, Thompson ME, Langer A, Heilman S, Hardesty RL. Lead systems for internal ventricular fibrillation. *Circulation* 1981; **64**:242–245.
13. Deeb GM, Hardesty RL, Griffith BP, Thompson ME, Heilman MS, Myerowitz RL. The effects of cardiovascular drugs on the defibrillation threshold and the pathological effects on the heart using an automatic implantable defibrillator. *Ann Thorac Surg* 1983; **35**:361–366.
14. Mirowski M, Reid PR, Winkle RA, et al. Mortality in patients with implanted automatic defibrillators. *Ann Intern Med* 1983; **98**:585–588.
15. Brodman R, Furman S, Fisher J. Implantation of automatic defibrillators via the median sternotomy (abst). *JACC* 1984; **2**:536.

Addendum: Since the submission of this paper, 12 additional devices have been implanted at the Cleveland Clinic. All patients were survivors of sudden out-of-hospital cardiac arrest, refractory to conventional and investigational antiarrhythmic therapy (alone and in combination) and deemed unsuitable for electrically guided ablation of the ventricular arrhythmia substrate.