

# Thoracic aspergillosis (part III)

## Invasive pulmonary and disseminated aspergillosis<sup>1</sup>

Atul C. Mehta, M.D.  
Mohammad A. Dar, M.D.  
Muzaffar Ahmad, M.D.  
Allan J. Weinstein, M.D.  
Joseph A. Golish, M.D.

With the increase in the number of patients receiving immuno-suppressive therapy, the incidence of fungal infection is also on the rise. The fungus *Aspergillus*, a ubiquitous saprophyte, can produce pulmonary as well as systemic infection in several different forms. These include aspergilloma, primary pulmonary aspergillosis, allergic bronchopulmonary aspergillosis, invasive aspergillosis, and disseminated aspergillosis. The manifestations and treatment of these forms of infection vary greatly from one to another. In part III, the authors review and discuss invasive pulmonary and disseminated aspergillosis.

**Index terms:** Aspergillosis • Fungi • Review articles

**Cleveland Clin Q** 51:655–665, Winter 1984

### INVASIVE PULMONARY ASPERGILLOSIS

Invasive pulmonary aspergillosis, which was found in less than 1% of patients in the general hospital population before 1950, has become an important cause of morbidity and mortality in immunocompromised patients.<sup>1–8</sup> After candidiasis, it is the second most common fungal infection in patients with acute leukemia and lymphoma.<sup>9,10</sup> Virtually any species of *Aspergillus* may produce infection in an immunocompromised host. *Aspergillus fumigatus* has been isolated more frequently than other species,<sup>3,11,12</sup> such as *Aspergillus flavus*, *Aspergillus niger*, *Aspergillus nidulans*, *Aspergillus oryzae*, *Aspergillus versicolor*, *Aspergillus glaucus*, and *Aspergillus clavatus*.<sup>3</sup> In a series of 98 patients with

<sup>1</sup> Departments of Pulmonary Disease (A.C.M., M.A.D., M.A., J.A.G.) and Infectious Diseases (A.J.W.), The Cleveland Clinic Foundation. Submitted for publication Dec 1983; revision accepted June 1984.

0009-8787/84/04/0655/11/\$3.75/0

Copyright © 1984, The Cleveland Clinic Foundation

**Table.** Predisposing factors of invasive aspergillosis

Immunosuppressive drugs
1. Cytotoxic agents
2. Corticosteroids
Antibiotics
Radiation therapy
Antilymphocytic sera
Hemopoietic malignancy
Lymphoreticular malignancy
Aplastic anemia
Granulocytopenia
Immunodeficiency
1. Congenital
2. Acquired
Recent bacterial infection
Uremia
Diabetes mellitus
Miliary tuberculosis

aspergillosis reported by Young et al,<sup>1</sup> 61 cultures of autopsy tissue were performed. Cultures obtained from 43 (70%) of these patients grew *Aspergillus*; 18 had *A fumigatus*, 5 had *A flavus*, 3 had *A glaucus*, 2 had *A niger*, and 14 had unidentified *Aspergillus* species. In another study reported by Young et al,<sup>12</sup> cultures of autopsy tissue from 39 patients with invasive aspergillosis were performed. Twenty-three (59%) of the 39 patients had infection with *A fumigatus*, 12 (30%) with *A flavus*, and 2 (5%) with *A glaucus*. Five percent had simultaneous infection with two species of *Aspergillus*. A threefold to fourfold increase in the incidence of invasive aspergillosis in acute leukemic patients was detected by Aisner et al<sup>13</sup> on moving to a new hospital facility found to be heavily contaminated with *A fumigatus* and *A flavus*. In 17 patients reviewed by Aisner et al,<sup>11</sup> 8 patients had positive cultures for *Aspergillus*. Seven of these 8 grew *A flavus* and 1 grew *A fumigatus*. The higher incidence of *A flavus* in this series may have been related to environmental contamination.<sup>13</sup> Infection with several species of *Aspergillus* and several genera of fungi have been reported in the same patient.<sup>1,6,12</sup>

### Predisposing factors

Many factors predispose patients to invasive aspergillosis (Table). Patients with leukemia, particularly acute lymphocytic leukemia and acute myelocytic leukemia, are more susceptible to this infection. Mirsky and Cuttner<sup>14</sup> found a 15.4% (10 of 65 patients) incidence of invasive aspergillosis in acute leukemic patients. In another study,

lymphoma was the second most common malignancy in patients in whom invasive aspergillosis developed.<sup>1</sup> The incidence of aspergillosis has increased in recent years. In one cancer hospital, only 30 patients were found to have aspergillosis at autopsy between 1951 and 1963. During the subsequent 10-year period, 93 cases of invasive aspergillosis were found in the same institution, and twice as many were observed in 1969–1970 than in 1964–1965. The patients with acute leukemia in this survey had a 31% incidence of aspergillosis in 1970–1971, compared to an 11% incidence in 1964–1965.<sup>15</sup> In a series of 98 patients, Young et al<sup>1</sup> reported that 90% of the patients had underlying hematologic and lymphoreticular malignancies. In three combined series, the incidence of invasive aspergillosis was about 60% in patients with acute leukemia, 20% in patients with lymphoma, and 12% in patients with chronic leukemia.<sup>15</sup> Patients receiving renal and cardiac transplantation also are at high risk for invasive aspergillosis, particularly during the episodes of organ rejection, when immunosuppressive therapy usually is intensified.<sup>16,17</sup> Boggs<sup>18</sup> reported that fungal infections developed in 15 of 51 patients who underwent renal transplantations. Eleven of the 15 patients had infections produced by *A fumigatus*, and the development of the infection appeared to correlate with treatment for a rejection crisis. Seventy percent of the patients have tissue damage produced either by preceding or concomitant infections, which often were due to *Pseudomonas aeruginosa* or *Candida albicans*.<sup>9,15</sup> In one series, 29% of patients with invasive aspergillosis had had a previous pneumonia that was either resolving or had resolved. Only 26% of patients with invasive aspergillosis had no prior pulmonary pathology.<sup>6</sup>

Neutropenia is associated with a high risk of infection. This develops frequently in patients with hematologic malignancies and in patients receiving chemotherapy. Granulocytopenia is a major factor in patients with lymphoma, but seems less important in patients with metastatic carcinoma.<sup>3</sup> Young et al<sup>1</sup> observed that 70% of patients with invasive aspergillosis had an absolute neutrophil count of less than 500/mm<sup>3</sup>. Boggs,<sup>18</sup> however, suggested that invasive aspergillosis may develop in susceptible patients with abnormal phagocytosis even if the neutrophil count is normal. Many investigators have emphasized the role that neutropenia plays in host resistance against *Aspergillus* infection.<sup>1,19–22</sup> Gran-

ulocytopenia may be primary, as in aplastic anemia or chronic granulomatous disease of childhood, or secondary, as the result of chemotherapy or metabolic disorders.

It has been well established that drugs may play an important role in enhancing the susceptibility of patients to invasive aspergillosis.<sup>1,4,5,21,23-31</sup> According to Bodey,<sup>3</sup> more than 90% of patients with aspergillosis had received corticosteroids and that most of these patients also had received anticancer agents, which cause myelosuppression and immune suppression. Young et al<sup>1</sup> reported that 87% of 98 patients who developed aspergillosis had received corticosteroids. Corticosteroids have been shown to increase the incidence of pulmonary aspergillosis in experimental animals.<sup>32</sup> It has been suggested that corticosteroids inhibit the lysosomal membrane fusion in pulmonary macrophages, which in turn leads to the germination of *Aspergillus* spores engulfed by these macrophages.<sup>10</sup> Similarly, antineoplastic agents, by inducing leukopenia and immunosuppression, predispose to invasive aspergillosis.<sup>1,4,5,21,23-31</sup> Invasive aspergillosis in renal transplantation has been observed more frequently in patients who received antilymphocytic serum.<sup>2,18</sup> It is thought that antilymphocytic serum increases the susceptibility to *Aspergillus* infection by decreasing cellular immunity, inhibiting antibody formation, and depressing immunologic memory. Experimentally, it has been demonstrated that antilymphocytic serum abrogates established delayed hypersensitivity reactions.<sup>18</sup> The role of antibiotics in increasing susceptibility to fungal infection remains controversial. Okudaira et al,<sup>33</sup> who performed an ecological study on fungal flora in human lungs during 159 autopsies, observed that isolation of filamentous fungi was little influenced by antibiotic therapy, while the isolation rate of yeasts was remarkably high in cases treated with antibiotics. In contrast, Bodey,<sup>6</sup> who studied a group of 454 leukemic patients with fungal infection and 50 control patients with underlying leukemia, found that antibiotics had been no more frequently administered to patients with fungal infection than to the control group.

The lung is involved in about 90% of *Aspergillus* infections, and in 70%, it is the only site of infection. It is also an important site of infection in cardiac and renal transplant patients.<sup>3,34</sup> Hematogenous dissemination occurs in 30% of patients, and the organs most often involved, in

addition to the lungs, are the gastrointestinal tract, brain, kidney, heart, liver, and thyroid. Skin involvement may occur; this is manifested as characteristic lesions, which appear as large areas of necrosis covered by black eschar.<sup>6,35</sup>

Invasive pulmonary aspergillosis most frequently is manifested as a necrotizing bronchopneumonia or hemorrhagic infarction, but occasionally there are single or multiple abscesses, granulomas, or lobar pneumonia. According to Pennington<sup>36</sup> and Orr et al,<sup>37</sup> pulmonary infection with *Aspergillus* may be as common or even more common than that due to *Candida*. In 38 patients with aspergillosis described by Bodey,<sup>6</sup> the lung was involved in all of the patients. Twenty-five patients had infection localized solely to the lung. Most of these pulmonary infections were manifested as pneumonia, but a few patients had pulmonary abscesses, and pulmonary infection was present in every patient with disseminated disease (7 patients). Young et al,<sup>1</sup> who investigated 98 patients, found 92 with pulmonary involvement identifiable at autopsy. The lung was the only organ involved in 60 of the 92 patients.

Transbronchial colonization is the most common mechanism preceding the proliferation of *Aspergillus*. Another important predisposing factor is nasopharyngeal colonization. It recently has been demonstrated in leukopenic leukemic patients that positive surveillance nasal cultures for *Aspergillus* frequently antedate the development of invasive pulmonary aspergillosis.<sup>38</sup> Endobronchial proliferation of *Aspergillus* results in superficial erosions and ulcerations of the bronchial mucosa. If the disease is limited to this stage, it is referred to as aspergillary bronchitis.<sup>1,39,40</sup> Extensive mucosal ulcerations and black membrane formation may develop in such patients.<sup>1</sup> In one series, 8 of 98 patients had aspergillary bronchitis; these were the least immunocompromised. Three of the 8 patients had focal parenchymal involvement with consolidation and abscess formation.<sup>1</sup> In severely immunocompromised patients, endobronchial proliferation is followed by transbronchial invasion with parenchymal involvement. Small arteries adjacent to the involved parenchyma may be invaded, leading to thrombosis, which in turn may give rise to small hemorrhagic infarctions. Large hemorrhagic pulmonary infarctions can occur if large arteries are involved by the fungus.<sup>37</sup> The fungal invasion may, therefore, give rise to necrotizing broncho-

pneumonia, lobar pneumonia, or hemorrhagic pulmonary infarction. Young et al<sup>1</sup> reported these three clinical states in 67 of 82 patients with severe pulmonary aspergillosis. The other mechanisms responsible for the development of invasive pulmonary aspergillosis are those associated with colonization of necrotic lung tissue resulting from concomitant bacterial infection, pulmonary embolism, a silent preexisting cavitary or cystic lung disease, and direct hematogenous spread.<sup>1,41-43</sup>

### Pathology

**Macroscopic.** According to Orr et al,<sup>37</sup> two types of lesions may be observed on gross examination: nodular and hemorrhagic infarction. Nodular lesions appear as target lesions and have a central gray-yellow necrotic area surrounded by a rim of hemorrhage. These lesions vary in size from 1 to 3 cm.

**Microscopic.** Vascular invasion by fungal hyphae is observed in the necrotic center and the purulent inflammatory infiltrate in the bronchi and the peribronchial tissues. The typical microscopic appearance of a purulent bronchopneumonia also is present. Orr et al<sup>37</sup> described target lesions in 15 of 25 patients (60%); these were multiple in 9 patients and single in 6 patients. Hemorrhagic infarctions were wedge-shaped, pleural-based lesions. Thrombosis of major pulmonary arteries with fungal invasion from an adjacent bronchus was demonstrated histologically in all 25 cases. Young et al<sup>1</sup> described necrotizing bronchopneumonia in 30 patients. This ranged from focal necrotic pneumonitis to bilateral hemorrhagic consolidation. The macroscopic findings in 29 patients with hemorrhagic infarction included dark-red nodular areas of consolidation, often surrounded by hemorrhage. Central abscesses also were present in some areas of infarction. Eight patients had lobar pneumonia, and in these, consolidated lobes with necrotizing hemorrhage contained masses of fungal hyphae. Microscopic examination demonstrated vascular invasion by mycelia, resulting in occlusion and thrombosis of pulmonary vessels. According to Williams et al,<sup>34</sup> necrotizing bronchopneumonia, including necrotizing bronchitis and invasion of small blood vessels and pulmonary infarction due to invasion and occlusion of large- or medium-sized vessels, are the two most common lesions, each being present in approximately one third of patients. Other lesions observed by

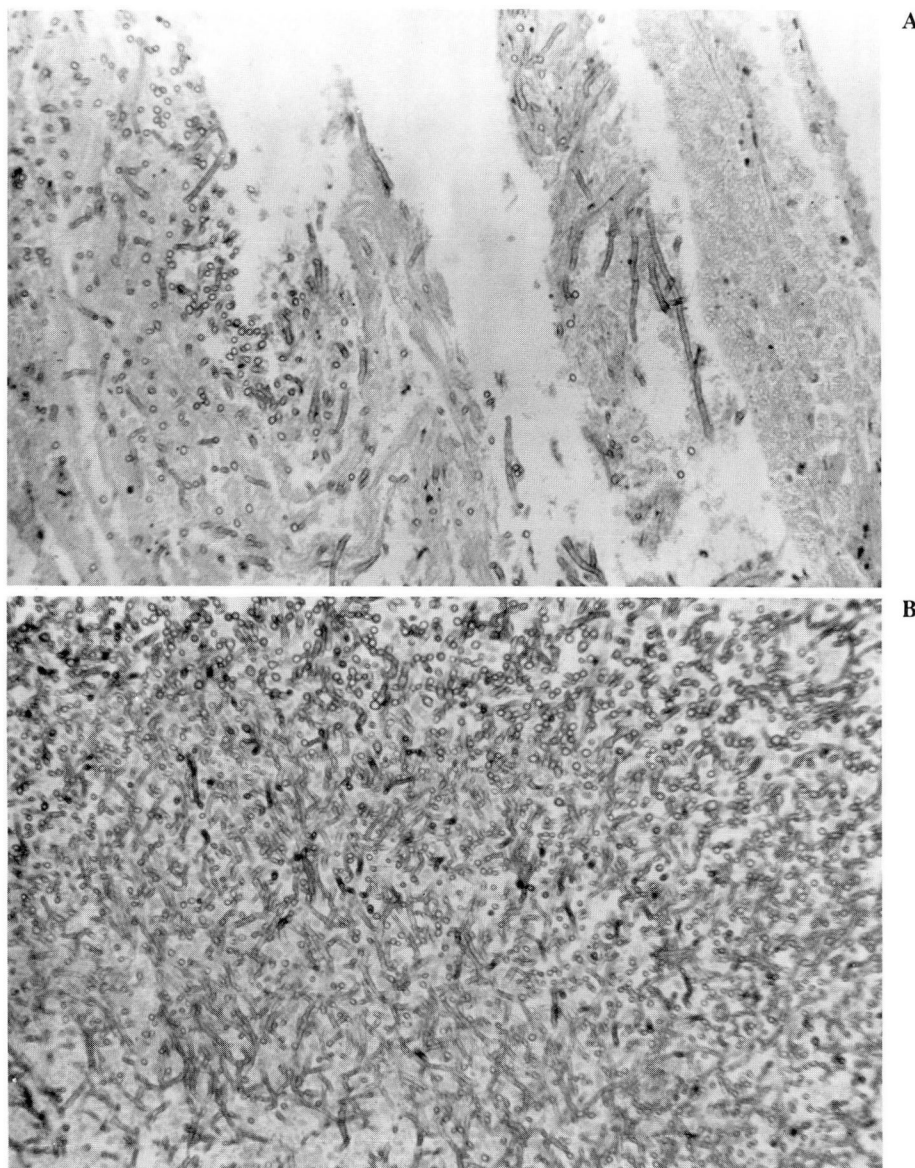
these investigators were microabscesses, bronchitis, lobular and lobar pneumonia, aspergillomas, solitary granulomas, and lung abscesses (Fig. 1, A and B). Rarely, multiple cavitating aspergillomas have been described. Robboy et al<sup>44</sup> reported a patient with microangiopathic hemolytic anemia associated with *Aspergillus* invasion of the blood vessels and suggested that the invading fungus, anchored to arterial walls forming a trellis of interweaving hyphae in the lumina of the arteries, was responsible for this disorder.

### Clinical features

The symptoms and signs are nonspecific and overlap with other infections and noninfectious processes. According to Bodey,<sup>6</sup> in 74% of leukemic patients reviewed at autopsy, pulmonary aspergillosis had developed, in proximity of time or place, to other pulmonary infections. Necrotizing bronchopneumonia and pulmonary infarction have been the most frequent clinical presentations. Fever, dyspnea, and nonproductive cough are commonly observed. Bronchospasm may be present. Pleuritic chest pain is more prominent in patients with hemorrhagic pulmonary infarction. Young et al<sup>1</sup> reported that 61% of 29 patients with hemorrhagic pulmonary infarction detected at autopsy had experienced pleuritic chest pain. These patients frequently were noted to have had a sudden onset of breathlessness, tachycardia, cough, and signs of sudden cardiac decompensation. Of 93 patients with aspergillosis studied by Meyer et al,<sup>35</sup> 6 had the sudden onset of pleuritic chest pain and 2 had hemoptysis. Three of the patients had hemorrhagic infarction, 2 had necrotizing pneumonia, and 1 had lobar consolidation. Minor hemoptysis (<150 mL/24 hr) has been described infrequently. In a series of 20 patients with invasive pulmonary aspergillosis, only 1 patient had hemoptysis.<sup>45</sup> Young et al<sup>1</sup> reported that of 29 patients with hemorrhagic pulmonary infarction due to invasive pulmonary aspergillosis, 3 had mild hemoptysis. Aslam et al,<sup>46</sup> in a review of 21 patients with pulmonary aspergillosis, including 5 patients with lymphoproliferative disorders, reported that hemoptysis was common in all patients except those with lymphoma and leukemia. Massive hemoptysis rarely occurs.<sup>45</sup> Other clinical features include cough, rales on physical examination, and a pleural friction rub.

Positive antemortem cultures for *Aspergillus* are difficult to obtain in such patients. In 38





**Fig. 1** Invasive aspergillosis.

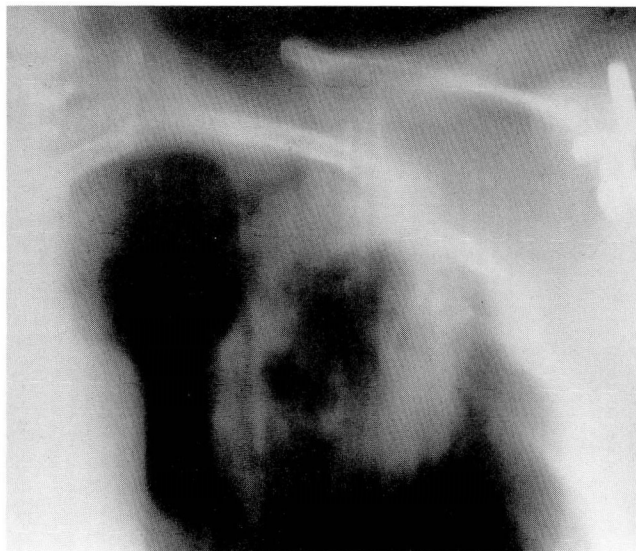**A and B.** Note *Aspergillus* hyphae invading lung parenchyma, as shown by this lung biopsy specimen.

leukemic patients observed by Bodey,<sup>6</sup> the diagnosis was established before death in only 1. Young et al<sup>1</sup> reported 34 patients with one positive culture and 9 with more than one positive culture. Only 4 of 25 patients had positive sputum cultures. Aisner et al<sup>11</sup> reported that fungal cultures of the throat, sputum, or tracheal aspiration in 59 patients documented as having aspergillosis were positive in only 12%. Aisner et al,<sup>38</sup> who followed 125 patients with surveillance nasal cultures, observed 18 patients in whom invasive aspergillosis developed. Ten of the 18

patients were from the group of 11 patients who had nasal cultures that yielded *A. flavus* and *A. fumigatus*. The remaining 8 were from 114 patients who did not have positive nasal cultures. Carbenicillin had been administered for a longer period of time among patients with positive nasal cultures than among those without aspergillosis. The authors also noted that the negative nasal cultures did not preclude the development of infection.

Routine laboratory studies usually do not help to establish the diagnosis of invasive pulmonary





**Fig. 2.** Tomogram demonstrates the left-upper-lobe cavitating infiltrate in a 50-year-old woman who was taking steroids.

aspergillosis. Ramsay et al,<sup>41</sup> who reviewed 272 renal transplant patients with fever and pulmonary infiltrates, suggested that a relatively well-preserved arterial  $\text{PaO}_2$  on room air, despite extreme involvement demonstrated radiographically, might indicate the presence of fungal or Nocardial disease. Blood cultures, even in disseminated disease, are almost always negative.<sup>1,6,35,36,47</sup> In 7 patients with cardiac aspergillosis reported by Young et al,<sup>1</sup> none had positive blood cultures, either antemortem or postmortem. The chest radiograph is abnormal in 75% to 100% of patients with invasive pulmonary aspergillosis. In its earliest phase, aspergillary bronchitis produces no radiographic signs. Single or multiple nodules (approximately 1–3 cm in diameter) appear as the disease progresses. These nodules correspond to histopathologic target lesions. The chest radiograph may show the following:<sup>37</sup>

1. Cavitation of the existing nodules,
2. Progression and enlargement of the nodules to produce diffuse bilateral pulmonary consolidation, and
3. The rapid development of large wedge-shaped, pleural-based lesions simulating pulmonary infarction (Fig. 2).

The consolidation usually remains stable or progresses slowly over several weeks. Young et al<sup>1</sup> reported that 7 of 30 patients with necrotizing

bronchopneumonia remained stable as shown by radiographs for 19–43 days. Radiographic findings may be absent in patients with hemorrhagic infarction if radiography is performed within one or two days of the onset of symptoms.<sup>1</sup> Orr et al<sup>37</sup> correlated autopsy findings and antemortem radiographic abnormalities in 20 patients with invasive pulmonary aspergillosis. Sixteen (80%) of the patients had radiographic abnormalities attributable to aspergillosis. Fifty-nine percent of the radiographic abnormalities seen produced by anatomic lesions of aspergillosis and 67% of such anatomic lesions were radiographically definable. These investigators concluded that unlike candidiasis, which is usually radiographically undetectable, invasive pulmonary aspergillosis produces radiographically visible lesions.<sup>37</sup> The pulmonary radiographic patterns of aspergillosis progress more gradually than do those of both bacterial and pneumocystis carinii pneumonias and involves smaller lung volumes.<sup>48</sup>

Serologic studies have not been useful in the diagnosis of invasive pulmonary aspergillosis. The importance of the presence of *Aspergillus* antibodies in invasive aspergillosis remains controversial. Young and Bennett<sup>49</sup> obtained serum late in the course of the disease from 16 patients, 14 of whom had underlying leukemia or lymphoma; no antibodies were detected by double diffusion in agar gel, complement fixation, immune electrophoresis, or indirect fluorescent antibody methods. Gurwith et al<sup>5</sup> reported that 1 of 5 cardiac transplant patients with proved invasive aspergillosis had positive precipitins. Coleman and Kaufman<sup>50</sup> reported that 14 of 16 patients with invasive aspergillosis had positive precipitating antibodies when tested by the immunodiffusion method and suggested that the immunodiffusion test is specific. Holmberg et al<sup>51</sup> described 80 hospitalized patients with acute leukemia who had immunodiffusion performed biweekly for one year to determine if serologic conversion accompanied clinical aspergillosis. Ten of the 80 patients were documented to have invasive aspergillosis. The immunodiffusion test converted from negative to positive in 7; 4 of these 7 had early successful treatment with amphotericin B. Bardana et al,<sup>52</sup> in a study of pulmonary infection in cancer patients, surveyed immunologic techniques for demonstrating antibodies in the serum of 79 patients with pulmonary aspergillosis. Immunodiffusion was the most valuable test for demonstrating precipitins in the

invasive or disseminated form of the disease, with positive tests in four of seven sera. In contrast, complement fixation demonstrated antibodies in only one of five serum samples from patients with invasive disease.<sup>52</sup> Some investigators have suggested that immunodiffusion and indirect immunofluorescence are more specific in detecting antibodies against *Aspergillus* than are indirect hemagglutination, enzyme-linked immunosorbent assay (ELISA), or radioassay.<sup>53</sup> Recently, several groups have examined assays to detect *Aspergillus* antigenemia. Weiner<sup>54</sup> reported that demonstration of antigenemia to *A fumigatus* cell-wall carbohydrate by radioimmunoassay is an early sign of infection. Antigenemia was detected in the sera of 4 of 7 patients with systemic aspergillosis and in the pleural fluid from a patient with an *Aspergillus* empyema. There were no false-positive reactions in the sera or pleural fluid of 43 patients or 27 normal donors. It was concluded that the predictive value of the positive radioimmunoassay result for aspergillosis is 100%. By contrast, counterimmune electrophoresis failed to demonstrate *Aspergillus* antigen in any patient.<sup>54</sup>

An immunologic monitoring system consisting of quantitative and qualitative examination of T lymphocytes has been employed in renal transplant recipients. A reduction in the number of T lymphocytes associated with an increase in spontaneous blastogenesis was believed to indicate an infectious process and proved helpful in detecting invasive aspergillosis in three renal transplantations.<sup>55</sup>

Factors that may delay an early diagnosis are difficulty in culturing *Aspergillus* from antemortem specimens and the presence of concomitant pulmonary bacterial infections that overshadow the underlying *Aspergillus* infection.<sup>2</sup> Demonstration of parenchymal invasion of the lung by *Aspergillus* is the only reliable method by which to establish a definitive diagnosis of invasive pulmonary aspergillosis. Bronchial brushings and transbronchial biopsy may be undertaken if there are no contraindications, such as thrombocytopenia or coagulation disorders. Some investigators have recommended transtracheal aspiration in all susceptible patients with new, unexplained pulmonary infiltrates.<sup>11,38</sup> Most, however, recommend an open lung biopsy in order to obtain adequate tissue for histopathologic examination and to delineate concomitant infection with organisms such as *C albicans*, cytomegalovirus, and

*Pneumocystis carinii*.<sup>56,57</sup> An open lung biopsy is the procedure of choice if the patient's clinical status does not permit the adoption of less invasive diagnostic procedures or if the patient is being artificially ventilated.

### Treatment

The success of treatment appears to be directly related to early diagnosis. Once the diagnosis has been established, the treatment of choice is the intravenous administration of amphotericin B. Amphotericin B may be initially administered at a dose of 0.3 mg/kg/body weight after a test dose to determine the patient's sensitivity. The dose may then be increased to 0.6 mg/kg/body weight. The dosage may be changed to 1.0 mg/kg/body weight every other day after an initial two-week daily treatment, provided there has been definite improvement or stabilization of the infection.<sup>11</sup> Peak serum levels of 0.5 to 3.5 µg/mL are achieved if the drug is administered at this dosage.<sup>58</sup> The optimal duration of amphotericin B therapy is unknown and the total dose received by responding patients has varied between 400 mg and 3 g.<sup>10</sup> The penetration of amphotericin B in the cerebrospinal fluid and ocular media is poor. The half-life of amphotericin B is about 24 hours. Minimal inhibitory concentration values for *Aspergillus* range from 1.0 to 40 µg/mL. A 15 µg/mL minimum inhibitory concentration of amphotericin B against one human isolate increased to 500 µg/mL soon after the institution of therapy.<sup>59</sup> Martinez et al<sup>60</sup> reported that the minimal inhibitory concentration of amphotericin B was determined for 21 strains of *Aspergillus*, consisting of 11 *A fumigatus*, 8 *A niger*, and 2 *A flavus*. The minimum inhibitory concentration varied from 0.25 µg/mL (two strains) to 1.25 µg/mL (five strains) at 48 hours to 1.5 µg/mL (one strain) to 50 µg/mL (one strain) at 10 days. *A flavus* strains tend to have minimal inhibitory concentrations above clinically attainable serum amphotericin B levels.<sup>61</sup> A combination of amphotericin B and rifampin has in vitro synergy against *Aspergillus*.<sup>61</sup> Similarly, several clinical reports indicate that the combined use of amphotericin B and aerosolized nystatin or flucytosine may improve results compared to therapy with amphotericin B alone.<sup>35,36,62,63</sup> A reduction in cytotoxic and corticosteroid dosage is an important element in the management of invasive pulmonary aspergillosis in susceptible patients. Surgical treatment may be used in pa-



tients who have localized disease and relapsing invasive pulmonary aspergillosis despite appropriate medical therapy, provided that the patients are not poor surgical risks and that their underlying disease either is in remission or is remitting. Lang et al<sup>64</sup> reported a case of invasive pulmonary aspergillosis successfully treated by surgical excision alone. Several determinations of anti-*Aspergillus* precipitin antibody titer by ELISA are useful prognostic indicators in patients with invasive pulmonary aspergillosis who are receiving systemic antifungal therapy. A serial rise in ELISA titer correlates well with histologically documented recovery from infection, while declining or persistent intermediate titers indicate dissemination of aspergillosis, as subsequently confirmed at autopsy.<sup>51</sup>

The prognosis of invasive pulmonary aspergillosis in a compromised host is directly related to early diagnosis and treatment, remission of the underlying disease, and reversal of chemotherapy-induced bone marrow suppression. In general, patients with invasive pulmonary aspergillosis complicating renal or cardiac transplantation and receiving antifungal therapy have a lower mortality (about 25%) than patients with invasive pulmonary aspergillosis complicating hematopoietic or lymphoreticular malignancies (70%).<sup>11,16,17,35,36</sup>

## DISSEMINATED ASPERGILLOSIS

Disseminated aspergillosis is defined as infection of two or more noncontiguous organs. The disseminated forms of aspergillosis is a fulminant disease that often has a fatal outcome. The incidence of disseminated aspergillosis has increased in recent years, indicating its relationship to the advent of transplantation, the use of chemotherapy in patients with underlying malignancy, and the expanding use of corticosteroids and antibiotics.<sup>1,65,30</sup> Most patients with disseminated aspergillosis have multiple organ involvement, the most prominent being the lung. The other organs involved are (in the order of frequency) the gastrointestinal tract, the central nervous system, the kidney, the liver, and the thyroid gland. Young et al<sup>1</sup> were the first to report extensive gastrointestinal involvement. They postulated that aggressive chemotherapy results in bowel toxicity and the development of a new portal of entry for *Aspergillus*. *A fumigatus* is the most

common species implicated in disseminated aspergillosis. Other species reported are *A flavus*, *A glaucous*, *A niger*, *Aspergillus sydowi*, and *A nidulans*.<sup>1</sup> However, any species of *Aspergillus* may produce the infection in a susceptible host. Patients with disseminated aspergillosis may have an associated bacterial infection or evidence of a second fungal infection.<sup>66</sup> *C albicans* is the most commonly associated fungus. Pulmonary manifestations of disseminated aspergillosis may consist of miliary microabscesses, pulmonary infarction, diffuse bilateral pneumonitis, and multiple aspergillomata.

## Gastrointestinal involvement

In a series of 34 cases with disseminated aspergillosis reported by Young et al,<sup>1</sup> 21 had gastrointestinal involvement and 11 had multiple enteric disease sites. Ulcerative esophagitis with associated necrosis was the most common lesion. Ulcerative lesions also were present in the stomach and the small and large bowel, with confluent areas of necrosis. Most had lesions in the jejunum; none had duodenal involvement. Perforation developed in 3 patients who were being treated with corticosteroids; their acute symptoms were masked by corticosteroid therapy. Sixteen of 21 patients underwent cultures for fungi and only 3 had positive cultures. *Aspergillus* was isolated from the soft palate in 1 patient.<sup>1</sup>

## Central nervous system involvement

Infection of the central nervous system occurs frequently in disseminated aspergillosis. In the series reported by Young et al,<sup>1</sup> 13 of 34 patients with disseminated aspergillosis had central nervous system involvement. Central nervous system involvement usually is the result of hematogenous dissemination. The primary focus usually is a lesion in the lung. The infection may be manifested as meningitis, meningoencephalitis, single or multiple brain abscesses, or isolated granulomas without abscess formation.<sup>67</sup> In the patients described by Young et al,<sup>1</sup> multiple central nervous system lesions were found in 7 patients and solitary lesions in 6. None of the patients had spinal cord involvement. Involvement of the base of the brain, cerebellum, and areas supplied by the posterior circulation was present in 10 patients. Eight patients had lesions in areas supplied by the anterior circulation. The authors suggested that in patients with hematogenous



dissemination, *Aspergillus* appears to commonly involve the central nervous system via the posterior circulation.

Clinical features consist of headache, lethargy, seizures, obtundation, and localizing neurological signs. Results of cerebrospinal fluid examination vary. They may be normal or may show leukocytosis, monocytosis, or increased protein.<sup>1,65,67-71</sup> Cerebrospinal fluid cultures for *Aspergillus* generally are negative. In two combined series, 15 of 16 cerebrospinal fluid cultures were negative.<sup>1,67</sup> The disease is almost universally fatal. Rarely, surgical drainage and amphotericin B therapy have been successful.<sup>72</sup>

### Kidney involvement

Renal involvement by hematogenous spread occurs commonly in disseminated aspergillosis. All patients with renal involvement reported by Young et al<sup>1</sup> had disseminated aspergillosis. Multiple focal abscesses may be present. Papillary necrosis may also occur. Clinical manifestations include hematuria and pyuria. Isolation of the fungus from urine cultures is uncommon.

### Liver involvement

Liver involvement is manifested as small localized abscesses that usually are asymptomatic. Invasion of the hepatic vein may occur and may be manifested as Budd-Chiari syndrome.<sup>1</sup> Liver function tests may not be strikingly abnormal.

### Thyroid involvement

Thyroid involvement may occur frequently in disseminated aspergillosis.<sup>1,30</sup> Of 34 patients with disseminated aspergillosis reported by Young et al,<sup>1</sup> 9 had thyroid involvement. The lesions consist of microabscesses, patchy hemorrhagic necrosis with vascular invasion, and diffuse necrotizing thyroiditis with widespread vascular involvement.<sup>65</sup> Clinical features indicating thyroiditis may not be present.

### Heart involvement

Cardiac involvement is a common manifestation of disseminated aspergillosis. Khoo et al<sup>30</sup> found that 12 of 23 cases with disseminated aspergillosis reported in the literature had cardiac involvement. Young et al<sup>1</sup> noted 7 of 34 patients with disseminated aspergillosis to have involvement of the pericardium and/or myocardium. Cardiac involvement may be manifested as peri-

carditis, small myocardial abscesses, myocarditis, coronary vascular occlusion, and endocarditis. Patients may have clinical features indicative of congestive heart failure. Electrocardiographic changes generally are nonspecific, but there may occasionally be changes consistent with myocardial ischemia or infarction.

### Skin involvement

Cutaneous invasion of the skin is rare in disseminated aspergillosis and occurrence has been estimated as less than 5%.<sup>73</sup> Skin involvement may present as a solitary necrotizing dermal plaque; a subcutaneous granuloma or abscess; persistent macular papules, which may develop necrosis or suppurate; erythema that fades without granuloma formation; and progressive confluent aspergillomas. *Aspergillus* may be cultured from the skin lesions.<sup>74,75</sup>

### Other involvement

Other organs that may be involved in disseminated aspergillosis are the spleen, the paranasal sinuses, bone, the testes, the adrenals, and the diaphragm.

### Treatment

Treatment with intravenous amphotericin B alone or in combination with flucytosine or rifampin has been unsuccessful.<sup>1,4-6,30,35,43,65</sup> An ante-mortem diagnosis of disseminated aspergillosis is rarely made.

Atul C. Mehta, M.D.  
Department of Pulmonary Disease  
The Cleveland Clinic Foundation  
9500 Euclid Ave.  
Cleveland OH 44106

### References

1. Young RC, Bennett JE, Vogel CL, Carbone PP, Devita VT. Aspergillosis: the spectrum of the disease in 98 patients. *Medicine* 1970; **49**:147-173.
2. Bardana EJ Jr. The clinical spectrum of aspergillosis. Part 2: classification and description of saprophytic, allergic, and invasive variants of human disease. *CRC Crit Rev Clin Lab Sci* 1981; **13**:85-159.
3. Bodey GP. Infections in cancer patients. *Cancer Treat Rev* 1975; **2**:89-128.
4. Rifkind D, Marchioro TL, Schneck SA, Hill RB Jr. Systemic fungal infections complicating renal transplantation and im-

- munosuppressive therapy. Clinical, microbiologic, neurologic and pathologic features. *Am J Med* 1967; **43**:28-38.
5. Gurwith MJ, Stinson EB, Remington JS. *Aspergillus* infection complicating cardiac transplantation. Report of five cases. *Arch Intern Med* 1971; **128**:541-545.
  6. Bodey GP. Fungal infections complicating acute leukemia. *J Chron Dis* 1966; **19**:667-687.
  7. Seres JL, Ono H, Benner EJ. Aspergillosis presenting as spinal cord compression. Case report. *J Neurosurg* 1972; **36**:221-224.
  8. Anderson CJ, Craig S, Bardana EJ Jr. Allergic bronchopulmonary aspergillosis and bilateral fungal balls terminating in disseminated aspergillosis. *J Allergy Clin Immunol* 1980; **65**:140-144.
  9. Levine AS, Schimpff SC, Graw RG Jr, Young RC. Hematologic malignancies and other marrow failure states: progress in the management of complicating infection. *Semin Hematol* 1974; **11**:141-202.
  10. Herbert PA, Bayer AS. Fungal pneumonia (part 4). Invasive pulmonary aspergillosis. *Chest* 1981; **80**:220-225.
  11. Aisner J, Schimpff SC, Wiernik PH. Treatment of invasive aspergillosis: relation of early diagnosis and treatment to response. *Ann Intern Med* 1977; **86**:539-543.
  12. Young RC, Jennings A, Bennet JE. Species identification of invasive aspergillosis in man. *Am J Clin Pathol* 1972; **58**:554-557.
  13. Aisner J, Schimpff SC, Bennett JE, Sutherland JC, Young VM, Wiernik PH. *Aspergillus* infections in cancer patients. Association with fireproofing materials in a new hospital. *JAMA* 1976; **235**:411-412.
  14. Mirsky HS, Cuttner J. Fungal infection in acute leukemia. *Cancer* 1972; **30**:348-352.
  15. Liebow AA, Carrington CB. The eosinophilic pneumonias. *Medicine (Balt)* 1969; **48**:251-285.
  16. Burton JR, Zachery JB, Bessin R, et al. Aspergillosis in four renal transplant recipients: diagnosis and effective treatment with amphotericin B. *Ann Intern Med* 1972; **77**:383-388.
  17. Stinson EB, Bieber CP, Griep RB, Clark DA, Shumway NE, Remington JS. Infectious complications after cardiac transplantation in man. *Ann Intern Med* 1971; **74**:22-36.
  18. Boggs DR. The cellular composition of inflammatory exudates in human leukemias. *Blood* 1960; **15**:466-475.
  19. Halazun JF, Anast CS, Lukens JN. Thyrotoxicosis associated with *Aspergillus* thyroiditis in chronic granulomatous disease. *J Pediatr* 1972; **80**:106-108.
  20. Greenberg D, Ammann AJ, Wara DW, Kaltreider HB. Immunity to *Aspergillus* in patients with chronic granulomatous disease. *J Pediatr* 1977; **90**:601-603.
  21. Hutter RVP, Collins HS. The occurrence of opportunistic fungus infections in a cancer hospital. *Lab Invest* 1962; **11**:1035-1045.
  22. Altman AR. Thoracic wall invasion secondary to pulmonary aspergillosis: a complication of chronic granulomatous disease of childhood. *AJR* 1977; **129**:140-142.
  23. Nath RK. Systemic aspergillosis: report of three cases. *Indian J Pathol Microbiol* 1977; **20**: 105-109.
  24. Naidoff MA, Green WR. Endogenous *Aspergillus* endophthalmitis occurring after kidney transplant. *Am J Ophthalmol* 1975; **79**:502-509.
  25. Rubinstein E, Noriega ER, Simberkoff MS, Holzman R, Rahal JJ Jr. Fungal endocarditis: analysis of 24 cases and review of the literature. *Medicine (Balt)* 1975; **54**:331-344.
  26. Meyer RD, Fox ML. *Aspergillus* endocarditis: therapeutic failure of amphotericin B. *Arch Intern Med* 1973; **132**:102-106.
  27. Roberts WC, Buchbinder NA. Right-sided valvular infective endocarditis: a clinicopathologic study of twelve necropsy patients. *Am J Med* 1972; **53**:7-14.
  28. Wolf FT. Observations on an outbreak of pulmonary aspergillosis. *Mycopathologia* 1969; **38**:359-361.
  29. Wing EJ, Remington JS. Cell-mediated immunity and its role in resistance to infection. *West J Med* 1977; **126**:14-31.
  30. Khoo TK, Sugai K, Leong TK. Disseminated aspergillosis: case report and review of world literature. *Am J Clin Pathol* 1966; **45**:697-703.
  31. Rose HD. Mechanical control of hospital ventilation and *Aspergillus* infections. *Am Rev Resp Dis* 1972; **105**:306-307.
  32. Sidransky H, Friedman L. The effect of cortisone and antibiotic agents on experimental pulmonary aspergillosis. *Am J Pathol* 1959; **35**:169-179.
  33. Okudaira M, Kurata H, Sakabe F. Studies on the fungal flora in the lung of human necropsy cases. A critical survey in connection with the pathogenesis of opportunistic fungal infections. *Mycopathologia* 1977; **61**:3-18.
  34. Williams DM, Krick JA, Remington JS. Pulmonary infection in the compromised host, part 1. *Am Rev Resp Dis* 1976; **114**:359-394.
  35. Meyer RD, Young LS, Armstrong D, Yu B. Aspergillosis complicating neoplastic disease. *Am J Med* 1973; **54**:6-15.
  36. Pennington JE. *Aspergillus* pneumonia in hematologic malignancy. *Arch Intern Med* 1977; **137**:769-771.
  37. Orr DP, Myerowitz RL, Dubois PJ. Patho-radiologic correlation of invasive pulmonary aspergillosis in the compromised host. *Cancer* 1978; **41**:2028-2039.
  38. Aisner J, Murillo J, Schimpf SC, Steere AC. Invasive aspergillosis in acute leukemia: correlation with nose cultures and antibiotic use. *Ann Intern Med* 1979; **90**:4-9.
  39. Lapham ME. Aspergillosis of lungs and its association with tuberculosis. *JAMA* 1926; **87**:1031-1033.
  40. Lurie HI, Duma RJ. Opportunistic infections of the lungs. *Human Pathol* 1970; **1**:233-257.
  41. Ramsay PG, Rubin RH, Tolkoff-Rubin NE, Cosimi AB, Russell PS, Greene R. The renal transplant patients with fever and pulmonary infiltrates: etiology, clinical manifestations, and management. *Medicine* 1980; **59**:206-222.
  42. Symmers WSC. Histopathologic aspects of the pathogenesis of some opportunistic fungal infections, as exemplified in the pathology of aspergillosis and phycomycetoses. *Lab Invest* 1962; **11**(part 2):1073-1090.
  43. Burke PS, Coltman CA Jr. Multiple pulmonary aspergillosis in acute leukemia. *Cancer* 1971; **28**:1289-1292.
  44. Robboy SJ, Salisbury K, Ragsdale B, Bobroff LM, Jacobson BM, Coleman RW. Mechanism of *Aspergillus*-induced microangiopathic hemolytic anemia. *Arch Intern Med* 1971; **128**:790-793.
  45. Borkin MH, Arena FP, Brown AE, Armstrong D. Invasive aspergillosis with massive fatal hemoptysis in patients with neoplastic disease. *Chest* 1980; **78**: 835-839.
  46. Aslam PA, Eastridge CE, Hughes FA Jr. Aspergillosis of the lung, an 18-year experience. *Chest* 1971; **59**:28-32.
  47. Young RC, Bennett JE, Geelhoed GW, Levine AS. Fungemia with compromised host resistance: a study of 70 cases. *Ann Intern Med* 1974; **80**:605-612.
  48. Bragg DG, Janis B. The radiographic presentation of pulmonary opportunistic inflammatory disease. *Radiol Clin North Am* 1973; **11**:357-369.

49. Young RC, Bennett JE. Invasive aspergillosis: absence of detectable antibody response. *Am Rev Resp Dis* 1971; **104**:710-716.
50. Coleman RM, Kaufman L. Use of the immunodiffusion test in the serodiagnosis of aspergillosis. *Appl Microbiol* 1972; **23**:301-308.
51. Holmberg K, Berdischewsky M, Young LS. Serologic immunodiagnosis of invasive aspergillosis. *J Infect Dis* 1980; **92**:793-796.
52. Bardana EJ Jr, Gerber JD, Craig S, Cianciulli FD. The general and specific humoral immune response to pulmonary aspergillosis. *Am Rev Resp Dis* 1975; **112**:799-805.
53. Mogahed A, Daniel-Ribeiro C, Monjour L, Druilhe P, Carme B, Gentilini M. Comparative study of many sero-immunological techniques for the detection of aspergillosis. *Bull Soc Fr-Mycol Med* 1978; **7**:215-222.
54. Weiner MH. Antigenemia detected by radioimmunoassay in systemic aspergillosis. *Ann Intern Med* 1980; **92**:793-796.
55. Kyriakides GK, Zinneman HH, Hall WH, et al. Immunologic monitoring and aspergillosis in renal transplant patients. *Am J Surg* 1976; **131**:246-252.
56. Singer C, Armstrong D, Rosen PP, Walzer PD, Yu B. Diffuse pulmonary infiltrates in immunosuppressed patients: prospective study of 80 cases. *Am J Med* 1979; **66**:110-120.
57. Greenman RL, Goodall PT, King D. Lung biopsy in immunocompromised hosts. *Am J Med* 1975; **59**:488-496.
58. Hermans PE. Antifungal agents used for deep-seated mycotic infections. *Mayo Clin Proc* 1977; **52**:687-693.
59. Ikemoto H. Treatment of pulmonary aspergilloma with amphotericin B. *Arch Intern Med* 1965; **115**:598-601.
60. Martinez J, Torres JM, Arteaga F, Foz-Tena A. Determination of the minimal inhibitory concentration of amphotericin B and miconazole for 21 strains of *Aspergillus*. *Mycopathologia* 1978; **64**:147-151.
61. Kitahara M, Seth VK, Medoff G, Kobayashi GS. Activity of amphotericin B, 5-fluorocytosine, and rifampin against six clinical isolates of *Aspergillus*. *Antimicrob Agents Chemother* 1976; **9**:915-919.
62. Sinclair AJ, Rossof AH, Coltman CA Jr. Recognition and successful management in pulmonary aspergillosis in leukemia. *Cancer* 1978; **42**:2019-2024.
63. Codish SD, Tobias JS, Hannigan M. Combined amphotericin B-flucytosine therapy in *Aspergillus* pneumonia. *JAMA* 1979; **241**:2418-2419.
64. Lang RS, Weinstein AJ, Golish JA, Gephardt GN. Localized invasive pulmonary aspergillosis treated by surgical excision. *South Med J* 1983; **76**:1305-1306.
65. Grcevic N, Matthews WF. Pathologic changes in acute disseminated aspergillosis: particularly involvement of the central nervous system. *Am J Clin Pathol* 1959; **32**:536-551.
66. Reiss E, Lehmann PF. Galactomannan, antigenemia in invasive aspergillosis. *Infect Immun* 1979; **25**:357-365.
67. Mukoyama M, Gimple K, Poser CM. Aspergillosis of the central nervous system: report of a brain abscess due to *A. fumigatus* and review of the literature. *Neurology* 1969; **19**:967-974.
68. Kaufman DM, Thal LJ, Farmer PM. Central nervous system aspergillosis in two young adults. *Neurology* 1976; **26**:484-488.
69. Iyer S, Dodge PR, Adams RD. Two cases of *Aspergillus* infection of central nervous system. *J Neurol Neurosurg Psychiatr* 1952; **15**:152-163.
70. Jackson IJ, Earle KM, Kuri J. Solitary *Aspergillus* granuloma of the brain. *J Neurosurg* 1955; **12**:53-61.
71. Louria DB. Experience with and diagnosis of diseases due to opportunistic fungi. *Ann NY Acad Sci* 1962; **98**:617-627.
72. Conen PE, Walker GR, Turner JA, Field P. Invasive primary pulmonary aspergillosis of the lungs with cerebral metastasis and complete recovery. *Dis Chest* 1962; **42**:88-94.
73. Findlay GH, Roux HF, Simson IW. Skin manifestations in disseminated aspergillosis. *Br J Derm* 1971; **85**(suppl):94-97.
74. Cawley EP. Aspergillosis and aspergilli: report of unique case of the disease. *Arch Intern Med* 1947; **80**:423-434.
75. Utz JP, Andriole VT, Emmons CW. Chemotherapeutic activity of X-5079C in systemic mycoses of man. *Am Rev Resp Dis* 1961; **84**:514-528.